

# Periopic Cyst Distal to Optic Nerve Meningioma: MR Demonstration

Bertil Lindblom,<sup>1,3</sup> David Norman,<sup>2</sup> and William F. Hoyt<sup>1,4</sup>

**Summary:** Dilatation of the subarachnoid space between the distal edge of an optic nerve sheath meningioma and the eyeball has previously been observed during surgery and considered a rare finding. We observed such periopic cysts in seven patients with optic nerve meningioma and describe the MR features of this finding.

**Index terms:** Orbits, neoplasms; Meningioma; Nerves, optic (II); Magnetic resonance, fat suppression

In 1989, McNab and Wright (1) reported the surgical finding of a cystic dilatation of the optic nerve sheath distal to an optic nerve sheath meningioma. They opined that this was a very rare phenomenon. In a review of magnetic resonance (MR) scans of 13 patients with optic nerve sheath meningioma, we observed seven patients with distal periopic cysts. The cyst was best defined on fat-suppressed T1-weighted MR images obtained following gadolinium-diethylenetriaminepentaacetic acid (GD-DTPA) administration.

## Case Reports

MR images from a group of 13 patients with optic nerve sheath meningioma seen in the UCSF Neuro-Ophthalmological Unit during 1990 and 1991 were reviewed. Patient age ranged from 15 to 58 years (mean 40); eight of the patients were women. Patients were examined on a 1.5-T magnet (GE Signa, Milwaukee, WI) using either a head coil and/or a 3-inch surface coil (eight patients). Section thickness was 3 mm in all cases. Imaging techniques included short TR/TE images in all patients prior to and following Gd-DTPA in the axial, sagittal oblique, and coronal planes and long TR, long TE images in the coronal plane only in six patients. Post-gadolinium examinations were performed using a chemical shift fat-suppression technique. In seven of the 13 cases, MR images disclosed a distal periopic cyst. Since orbital surgery is not part of our treatment regimen for this type of lesion, surgical confirmation was not available. The following three case reports illustrate the clinical and imaging findings in patients with periopic

cysts, and are representative of the other four cases encountered as well.

### Case 1

A previously healthy 39-year-old man complained of blurred vision in the right eye. Visual acuity was 20/40, and an afferent pupillary defect and chronic optic disc edema in the right eye were noted. MR revealed a sheath type enhancement of the right optic nerve extending from 6 mm behind the globe, through the optic canal, to the intracranial lip of the optic canal. Cystic dilatation of the nerve sheath was seen between the distal edge of the tumor and the eyeball (Fig. 1). The findings were characteristic of

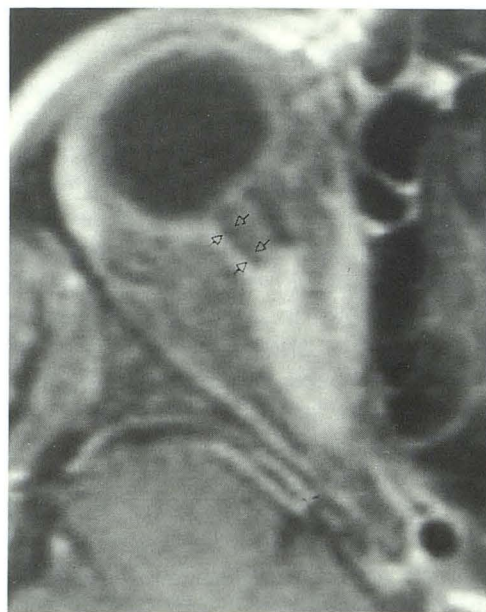


Fig. 1. T1-weighted 700/12/2 (TR/TE/excitations) post-gadolinium 3-mm thick axial scan obtained with fat suppression in a head coil. Note periopic enhancement of the mid portion of the optic nerve which reflects a meningioma. The anterior 6 mm of the nerve appears normal with two adjacent low intensity linear bands representing dilated perineural CSF-containing spaces (arrows).

Received June 28, 1991; revision requested October 22; revision received January 7, 1992 and accepted July 21.

<sup>1</sup> Neuro-Ophthalmology Unit, Department of Neurosurgery, and <sup>2</sup> Department of Radiology, UCSF Medical Center, San Francisco, CA.

<sup>3</sup> B.L. is on leave of absence from the Department of Ophthalmology, University of Göteborg, Sahlgren's Hospital, S-413 45 Göteborg, Sweden. Financial support has been provided by Foreningen De Blindas Vanner, Göteborg, The Sweden-America Foundation, Stockholm, Bertil and Carmen Regners Fond, Stockholm, Karin Sandqvists Stiftelse, Stockholm, and WennerGren Center Foundation, Stockholm.

<sup>4</sup> Address reprint requests to William F. Hoyt, Neuro-Ophthalmology Unit, Department of Neurological Surgery, UCSF Medical Center, San Francisco, CA 94143.

an optic nerve sheath meningioma. Neither surgical nor radiation therapy was felt to be indicated.

### Case 2

As a young girl, a 36-year-old woman gradually lost all vision in the left eye. Bilateral optic nerve meningiomas were diagnosed at age 27, when she presented with symptoms of brief obscurations of vision in her right eye. Visual acuity at the time was 20/15. The right optic disc was chronically swollen with optociliary bypass veins. The left optic disc was atrophic. CT showed intracranial extension of the tumor. Eight years later, the vision in her right eye was progressively compromised. The intracranial portion of the tumor was surgically removed, followed by radiation therapy with 5400 cGy. Vision has remained stable since therapy. Follow-up MR scans confirmed bilateral optic nerve meningiomas (Fig. 2). On the right, there was a cystic dilation of the perioptic space distal to the right optic nerve meningioma. The most anterior edge of the meningioma was 10 mm behind the globe. Previous CT scans did not reveal the cyst; it is not known when in the course of the disease the cyst developed.

### Case 3

A 13-year-old girl complained of blurred vision and an inward turning of the right eye. Visual acuity was 20/400 in the right eye and 20/20 in the left eye. The right optic disc was pale. MR showed tubular enhancing enlargement of the right optic nerve consistent with optic nerve sheath meningioma. There was an intracanalicular but no intracranial tumor extension. A perioptic cyst was seen distal to the meningioma (Fig. 3). No therapy was given.

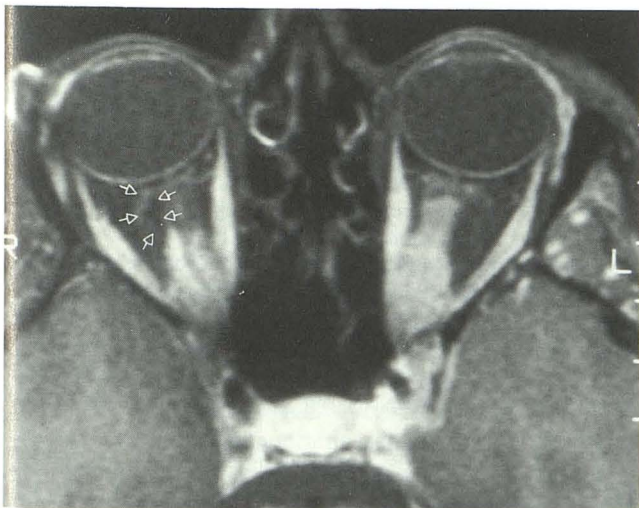


Fig. 2. Axial T1-weighted MR image (600/20/2) (obtained with fat suppression after Gd-DTPA administration) showing bilateral optic nerve meningiomas. The anterior aspect of the right sheath meningioma begins approximately 10 mm posterior to the globe and extends along the optic nerve through the optic canal. Arrows highlight the margins of a fluid accumulation eccentric to the distal right optic nerve. The tumor on the left approximates the posterior aspect of the globe and extends posteriorly to involve the intraorbital and intracranial optic nerve.

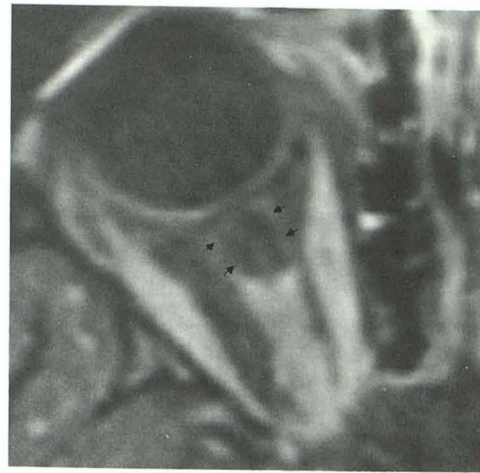


Fig. 3. T1-weighted (600/20/2) post-gadolinium 3-mm axial scan (obtained with fat suppression) demonstrates meningioma of the posterior two thirds of the right optic nerve sheath. Anterior to the meningioma there is dilation of the optic nerve sheath (arrows). In the central portion of the dilated nerve sheath is an atrophic optic nerve.

### Discussion

Contrast between retrobulbar fat and the optic nerve and ocular muscles is quite good on T1-weighted imaging techniques. In the detection of enlargement of the optic nerve-sheath complex, this imaging technique is quite satisfactory, but specificity is limited. The addition of gadolinium contrast agents improves conspicuity and to some degree, specificity, in that benign expansion of the optic nerve sheath will not enhance; however, the ability to visually detect enhancement with gadolinium is limited on standard T1-weighted images, in that both retrobulbar fat and gadolinium have short T1 relaxation times, and contrast resolution between the two is limited. Fat-suppression techniques will increase the contrast between enhancing intraorbital structures and fat (2). Lesions that exhibit high signal due to paramagnetic relaxation enhancement are easily distinguished from the signal suppressed low-intensity lipid. This technique significantly improves sensitivity of MR in the detection and characterization of meningioma and in the demonstration of subtle spread through the intracanalicular course of the nerve (3-5, 7); it was particularly useful in improving our ability to demonstrate dilatation of the perioptic sheath distal the optic nerve meningiomas reviewed.

The normal subarachnoid space around the optic nerve is normally slightly bulbous just behind the eyeball, but the enlargement is never, to our knowledge, as pronounced as was seen in our patients with optic nerve sheath meningioma. In these cases, cystic dilation combined with

atrophic thinning of the optic nerve (Fig. 3) increased the volume of the perioptic space distal to the meningioma. The MR signal in the abnormally enlarged perioptic space had an intensity similar to that of cerebrospinal fluid (CSF) on T1-weighted images in all patients studied. T2-weighted images (three patients) exhibited high signal intensity, identical to CSF. The MR findings, therefore, indicate that the cysts were the result of CSF accumulation in the subarachnoid space. It did not appear that the fluid communicated with the more proximal subarachnoid space as it was obliterated by perioptic nerve tumor. At surgery, McNab and Wright (1) found that the fluid in a similar cyst was under considerable pressure. Therefore, it is possible, but not proven, that the perioptic cyst can compromise optic nerve function, adding to the damage caused by tumor compression. The possible beneficial effect of surgical decompression of these cysts has yet to be demonstrated.

The mechanism for the fluid accumulation is obscure (1). One explanation could be local collection of fluid derived from the tumor or from the surrounding sheaths. Another could be impaired fluid exchange by mechanical factors causing increased pressure in the subarachnoid space. Perioptic cyst with orbital meningioma may be related to cysts associated with intracranial meningioma. Such cysts are relatively rare and the mechanism for their development is speculative. In a review of the literature, Umansky et al found 85 cases of cyst formation related to intracranial meningioma (6). These cysts may be intratumoral or peritumoral (7, 8). They may be associated with all histologic types of meningioma. Intratumoral cysts are rare and probably develop from foci of necrosis. The more common peritumoral cysts may be lined by tumor cells or by reactive gliotic tissue, or they may represent loculation or dilation of the adjacent subarachnoid space. The perioptic cysts described above are most probably of this latter type.

A perioptic cyst must not be confused with the sometimes rounded appearance of the distal part of optic nerve glioma in patients with neurofibromatosis (9). This change in optic nerve contour is seen on MR images in which the image plane cuts the kinked optic nerve at a right angle to its course. The nerve can be differentiated from perioptic cyst by the discontinuity of the optic nerve contour, and also by the prominent deflection of the nerve on the sagittal images.

Ophthalmoscopic findings suggestive of optic nerve meningioma are chronic disc edema, or

optic atrophy with or without optociliary bypass veins (10). These signs are usually interpreted as evidence that the meningioma extends to the back of the globe. In one of our patients (case 2), who had marked chronic disc edema and optociliary bypass vessels on the disc, the distal edge of the tumor, as defined by MR, was 10 mm behind the globe (Fig. 2). Two other patients had mild swelling of the optic disc, although the meningioma did not reach the back of the eyeball. Another case of optic nerve meningioma with optociliary bypass veins was recently reported by Hendrix et al (4), in which the distal tumor edge was 10 mm behind the globe. These cases illustrate that disc edema with or without optociliary bypass veins can occur in association with meningioma that spares the distal part of the optic nerve.

Regardless of the mechanism of the cyst formation, we have shown that the presence of a distal perioptic cyst may now be determined by MR. T1-weighted techniques using gadolinium and fat suppression improve conspicuity and specificity. Our review suggests that this phenomenon is more common than has been previously appreciated. The finding appears thus far to be unique to optic nerve meningiomas. Its role, if any, in clinical symptomatology remains to be clarified.

## References

1. McNab AA, Wright JE. Cysts of optic nerve: three cases associated with meningioma. *Eye* 1989;3:55-359
2. Simon J, Szumowski J, Totterman S, et al. Fat-suppression MR imaging of the orbit. *AJNR* 1988;9:961-968
3. Tien RD, Chu PK, Hesselink JR, Szumowski J. Intra- and paraorbital lesions: value of fat-suppression MR imaging with paramagnet contrast enhancement. *AJNR* 1991;12:245-253
4. Hendrix LE, Kneeland JB, Haughton VM, et al. MR imaging of optic nerve lesions: value of gadopentetate dimeglumine and fat-suppression techniques. *AJNR* 1990;11:749-754
5. Lindblom B, Truwit C, Hoyt WF. Optic nerve sheath meningioma: definition of intraorbital, intracanalicular, and intracranial components with magnetic resonance imaging. *Ophthalmology* (1992;99:560-566)
6. Umansky F, Pappo I, Pizov G, Shalit M. Cystic changes in intracranial meningiomas: a review. *Acta Neurochir (Wien)* 1988;95:13-18
7. Pinna G, Beltramello A, Buffatti P, et al. Cystic meningiomas: an update. *Surg Neurol* 1986;26:441-452
8. Maiuri F, Benvenuti D, De Simone MR, Cirillo S, Corriero G, Giamundo A. Cystic lesions associated with meningiomas. *Surg Neurol* 1986; 26:591-597
9. Imes RK, Hoyt WF. Magnetic resonance imaging signs of optic nerve gliomas in neurofibromatosis I. *Am J Ophthalmol* 1991;111: 729-734
10. Frisen L, Hoyt WF, Tengroth BM. Optociliary veins, disc pallor and visual loss: a triad of signs indicating sphenoorbital meningioma. *Acta Ophthalmol* 1973;51:241-249