

# Prediction of Neurologic Outcome in Acute Spinal Cord Injury: The Role of CT and MR

Morry Silberstein,<sup>1</sup> Brian M. Tress,<sup>2</sup> and Oliver Hennessy<sup>1</sup>

**PURPOSE:** 1) To determine whether MR appearances of the spinal cord in acute trauma correlate with clinical prognosis, and 2) to identify other MR and CT prognostic factors in acute spinal trauma. **METHODS:** Retrospective evaluation of MR, CT, and clinical examinations in 32 acute spinal trauma patients examined between 1987 and 1990. **RESULTS:** All 21 patients with abnormal spinal cords on MR had complete motor paralysis at presentation, compared to only three of 11 patients with normal cords. Whereas cord transection and hemorrhagic contusion had poor prognoses, 73% of patients with cord edema and 100% of patients with normal cord had useful motor function at outcome. At follow-up MR, areas of cord contusion developed into cysts, while edema resolved, leaving residual areas of myelomalacia. Associated spinal fractures, ligament injury, and cord compression were associated ( $P < .05$ ) with a worse prognosis. Spondylotic changes were a significant risk factor for spinal cord injury, mediated by cord compression. **CONCLUSIONS:** MR and CT are valuable techniques for quantifying injury and predicting prognosis in acute spinal trauma.

**Index terms:** Spinal cord, trauma; Spinal cord, computed tomography; Spinal cord, magnetic resonance

AJNR 13:1597-1608, Nov/Dec 1992

Magnetic resonance (MR) imaging has proved to be a significant noninvasive tool in evaluating the spinal cord in the acute stages following injury, and specific correlation has been demonstrated between clinical deficit in the acute stage of injury and specific spinal cord appearances (1-4). The demonstration of a possible correlation between MR appearance of the spinal cord in the acute stages following trauma, and the degree of neurologic recovery, suggests that MR could be used to identify specific prognostic groups (5-9). At time of writing, the results of long-term clinical follow-up of patients with MR examinations soon after trauma have consisted of two separate study

groups, one involving 42 patients (6-8), and the other, 31 patients (9). Most of the published data in this area has reviewed MR at 1.5 T, and it is only recently that data has appeared in the literature suggesting that examinations at lower field strengths yield satisfactory images for correlation between MR appearance and pathologic findings (5, 9, 10).

Our objectives were: 1) to determine whether MR appearances of the spinal cord in the acute trauma stage can be correlated with long-term clinical recovery; 2) to identify imaging parameters, other than the appearance of the spinal cord in the acute stage that can predict long-term prognosis; and 3) to correlate MR appearances at lower field strength with the degree of deficit at presentation.

## Materials and Methods

We reviewed retrospectively the results of imaging studies and clinical examinations performed at presentation and follow-up on patients referred for MR examination between 1987 and 1990. There were 32 patients (20 males and 12 females) with ages ranging from 12 to 70 years, with a mean of 34 years. Patients included in the study had a

---

Received August 14, 1991; revision requested October 10; final revision received on February 26, 1992 and accepted on February 28.

This work was supported in part by the Edith and Viola Reid Trust of the University of Melbourne, and the Austin Hospital Private Consultants Fund.

<sup>1</sup> Department of Radiology, Austin Hospital, Heidelberg, Victoria, Australia 3084. Address reprint requests to Dr Morry Silberstein.

<sup>2</sup> Department of Radiology, Royal Melbourne Hospital, Parkville, Victoria, Australia 3050.

AJNR 13:1597-1608, Nov/Dec 1992 0195-6108/92/1306-1597

© American Society of Neuroradiology

demonstrable neurologic deficit following spinal trauma, admission to the Spinal Injuries Unit, and MR imaging during initial hospital admission. Patients were excluded if they had spinal surgery in the 12 months following injury, MR images were not technically satisfactory, the clinical level was below the conus medullaris, or more than one clinical level of impairment was present. Although over 300 patients with acute spinal cord injury were admitted over the time interval surveyed, only a small percentage had acute MR imaging. This was primarily because referrals were limited to two groups due to the difficulty associated with transporting these critically ill patients from the intensive care unit to the MR facility: patients with clinical deterioration following admission, and patients whose degree of imaging abnormality on other studies failed to explain satisfactorily the degree of clinical impairment. All patients in our group were treated conservatively, with temporary spinal immobilization only, which was the management policy of the Spinal Injuries Unit at that time, but this did enable a uniform comparison to be made between neurologic outcomes. All patients had clinical assessments at presentation and 6 months following injury. Of the 32 patients, 27 had an additional 12-month clinical assessment. Twelve of these patients underwent follow-up MR imaging between 6 months and 48 months from original injury. The early and follow-up images of an additional patient who was originally excluded from the study because she had more than one level of neurologic impairment were also included in the analysis of time-related changes.

The mechanisms of injury were: motor vehicle accident (15 patients), fall (six patients), diving (four patients), recreational sport (three patients), and four miscellaneous including assault. Twenty-two patients had cervical injuries including nine transverse (mean level, C6-C7), 12 central cord (mean level, C5-C6) and one Brown-Séquard syndrome (C6). Ten patients had thoracic injuries of whom nine had transverse levels (mean, T7-T8) and one Brown-Séquard syndrome (T2). Degree of functional deficit was determined by the Frankel classification (11): Grade A—complete motor and sensory loss; Grade B—complete motor loss, but some sensation preserved; Grade C—some motor power preserved, but of no functional use; Grade D—useful motor function, including walking with aids, but less than normal; Grade E—free of neurologic symptoms.

MR imaging was performed on a 0.3-T resistive MR unit (B3000; Fonar, Melville, NY) on 29 patients and a 1.5-T superconducting MR unit (Magnetom 63; Siemens, Germany) on three patients. Average time from injury to MR examination was 11 days (range, 1 day to 42 days), with over 70% performed within 7 days. Images were obtained with a spin-echo technique consisting of two sagittal sequences (repetition time msec/echo time msec = 600/15 and 2500/80) and two axial sequences using similar acquisition times. Flow compensation was used in the long TR sequences. Section thickness was 4 mm with 1-mm intersection gap. A similar technique was used for the follow-up scans, which were all at 0.3 T.

Computed tomography (CT) was performed on all patients, with 28 having noncontrast studies, and four having

CT with intrathecal contrast. Examinations consisted of contiguous 2-mm sections with sagittal reformatting.

The spinal cord in each patient was analyzed for the presence of five characteristics on MR: transection—defined as partial or complete discontinuity of the spinal cord on sagittal images; contusion—either 1) focal high signal on T1 (short TR/short TE) weighted images, or low signal on T2 (long TR/long TE) images, 2) heterogeneous signal from cord on T1 or T2 images, 3) focal area(s) of high signal on T1 image, surrounded by much larger area of high signal on T2 image, or 4) focal sharply defined area of high signal on T2 image; edema—diffuse, poorly defined high signal on T2 image with normal signal on T1 image; and swelling—expansion of cord diameter, whether or not other cord findings were present, using previously published parameters (12, 13). During the collection of data, the presence or absence of cord swelling was noted in all patients, but for the remaining categories the predominant abnormality was assigned. Thus, for example, cords with both edema and contusion were classified as contusion, and cords with both contusion and transection were classified as transection.

The cervical spine and paraspinal soft tissues were analyzed for the presence of eight characteristics: fracture; subluxation; spondylosis—defined as the presence of posterior osteophytes; prevertebral swelling—according to previously published parameters (14); ligament injury—by recognized criteria (1), either discontinuity or focal high signal related to the anterior longitudinal ligament, or focal high signal related to the posterior ligamentous complex; disk herniation; extramedullary hematoma; and spinal cord compression—obliteration of an area of subarachnoid space around the cord. Fracture, subluxation, and spondylosis were assessed on CT; the remainder, on MR.

## Results

### *Dependence of Clinical Deficit on Cord Injury*

The results of presentation and follow-up Frankel grades are presented with the individual cord abnormalities in Tables 1 and 2. The severity of cord injury was directly related to the presentation Frankel grade. Both patients with cord transection (Fig. 1) presented grade A, as did six of the seven patients with cord contusion (Fig. 2). There were 11 patients with cord edema (Fig. 3), all of whom presented grade A.

Conversely, only 27% of the 11 patients with normal cords presented grade A. If the internal cord findings are isolated and cord swelling alone is evaluated (Table 2), the positive predictive value of cord swelling for presentation grade A was 93%, although the sensitivity of this finding was relatively low with over 40% false negative rate. Of the 11 patients with normal cords, 55% presented grade C or D, with all of the patients

TABLE 1: Distribution of spinal cord appearances related to presentation and follow-up Frankel grades

Pres	Follup	No.	Transection	Contusion	Edema	Isolated Swelling	Normal
A	A	7	2	3	2	0	0
	B	2	0	1	1	0	0
	C	2	0	2	0	0	0
	D	10	0	0	8	1	1
	E	2	0	0	0	0	2
B	C	1	0	1	0	0	0
	D	2	0	0	0	0	2
C	D	2	0	0	0	0	2
	E	1	0	0	0	0	1
D	E	3	0	0	0	0	3
Total		32	2	7	11	1	11

Note.—Pres = presentation Frankel grade; Follup = follow-up Frankel grade.

TABLE 2: Initial and follow-up grades related to spinal cord swelling

Pres	Follup	Total Swelling
A	A	5
	B	1
	C	2
	D	5
	E	0
B	C	1
	D	0
C	D	0
	E	0
D	E	0
Total		14

Note.—Pres = presentation Frankel grade; Follup = follow-up Frankel grade.

in the latter grade having normal cords at presentation.

There was an even stronger correlation between spinal cord appearances at presentation and follow-up Frankel grade. The two patients who had cord transection had no recovery, as expected.

Although none of the patients with cord contusion improved beyond grade C, the prognosis of cord contusion was better than that for cord transection. The probability of contusion being associated with at least one Frankel grade of recovery was 42%, as opposed to cord transection where none of the patients improved.

The finding of cord edema was associated with a relatively good prognosis (Fig. 3). The proba-

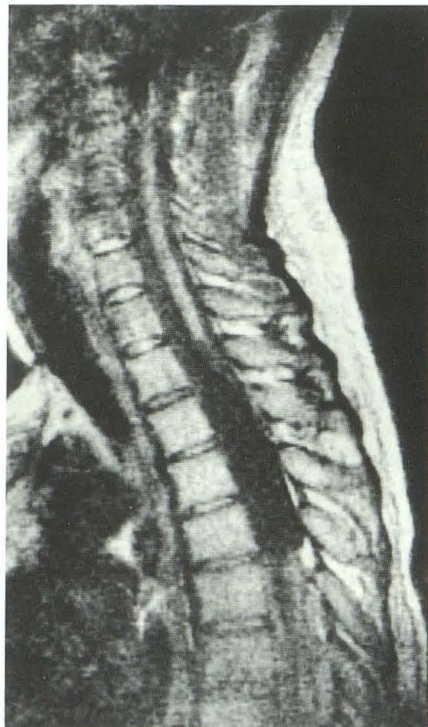bility of patients with edema having useful motor function at follow-up (grade D) was 73%. The finding of cord edema at presentation MR was also relatively specific (83%) for outcome grade D, regardless of presentation grade.

A normal cord at presentation had a positive predictive value of 100% for either useful motor function or complete neurologic recovery (grade D or E) at follow-up. However, the MR finding of a normal cord was not very sensitive for outcome grade D or E with a 45% false negative rate.

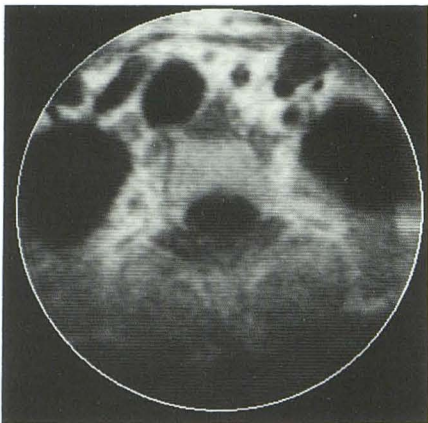
If the presence or absence of cord swelling only is used to predict prognosis, the positive predictive value of cord swelling for outcome grade A is only 35% and, although reasonably sensitive (71%), only has 64% specificity for this outcome. An MR finding of cord transection or contusion had an identical sensitivity (71%) but was far more specific (84%) for outcome grade A.

*Changes in Cord Appearance with Time*

The presentation and follow-up Frankel grades are related to changes in appearances of the spinal cord in Table 3. Both patients with cord transection had little change over time, although, in the second, the margins of the cord had retracted slightly by the second examination (Fig. 4). This patient also had a second lesion on the original examination, compatible with a contusion, excluding her from consideration in the major part of the study. Six of the seven cases of cord contusion subsequently developed well-defined areas of cerebrospinal fluid (CSF) intensity at the site of original abnormality, with all six



A



B

Fig. 1. Spinal cord transection; 26-year-old man presenting grade A T2 paraplegic following a T9-T10 dislocation; MR was performed at 21 days from injury.

A, Sagittal midline T1-weighted 0.3-T image through the upper thoracic spine demonstrates spinal cord transection with retraction of the upper cord. The dislocation was at a lower level.

B, Axial T1-weighted image through T3 confirms cord discontinuity. The patient had no recovery at 12 months.

presenting grade A, and none having useful motor function at outcome (Figs. 2 and 4).

Of the five patients with cord edema, three developed focal well-defined areas of high signal on the T2-weighted images at the site of original abnormality and all had useful motor function at follow-up (Fig. 5). Only one of the patients with

cord edema failed to improve, and, on the follow-up examination, had cord atrophy.

#### *Effect of Other Injuries on Clinical Deficit*

There was a strong correlation between the presence of an associated injury to structures outside the spinal cord and the degree of clinical deficit. The presentation and follow-up clinical grades are presented relative to the eight imaging observations in Table 4.

Whereas all of the imaging observations were far more common in patients with complete motor and sensory loss at presentation, none of the patients with mild impairment (ie, useful motor function) at presentation had a fracture, subluxation, spondylosis, prevertebral swelling, or cord compression.

The degree of impairment at follow-up was also closely related to the presence of certain imaging findings at presentation (Table 4). Fracture, cord compression, extramedullary hematoma, and prevertebral swelling were twice as common, and ligament injury four times as common, in patients with no recovery, than in patients with useful motor function at follow-up.

One or more fractures were present in 47% of patients with grade A at presentation. Grade A was twice as frequent in patients with fractures than other clinical grades. The presence of a fracture also had a significant effect on prognosis. Whereas 28% of the total population failed to improve beyond grade B (complete motor paralysis), 47% of all patients with a fracture failed to improve beyond grade B, and of those presenting grade A with a fracture, 70% failed to improve beyond grade B. There was a statistically significant association ( $\chi^2$  analysis) between the presence of a fracture and clinical outcome at  $P = .04$ .

Subluxation was an infrequent finding (22%), but 86% of patients who had a subluxation presented grade A. Only two of these (33%) improved to grade D or better at follow-up, compared to 63% of the whole patient group.

Spondylosis was present in 31% of patients, and in patients over 40, was found in 80%. Whereas 55% of patients without spondylosis had a fracture, only 30% of those with spondylosis had a fracture (Fig. 5). In contrast, 43% of patients with spondylosis had a subluxation and 70% had cord compression, compared to 14% and 23%, respectively, in patients without spondylosis. However, the degree of clinical impair-

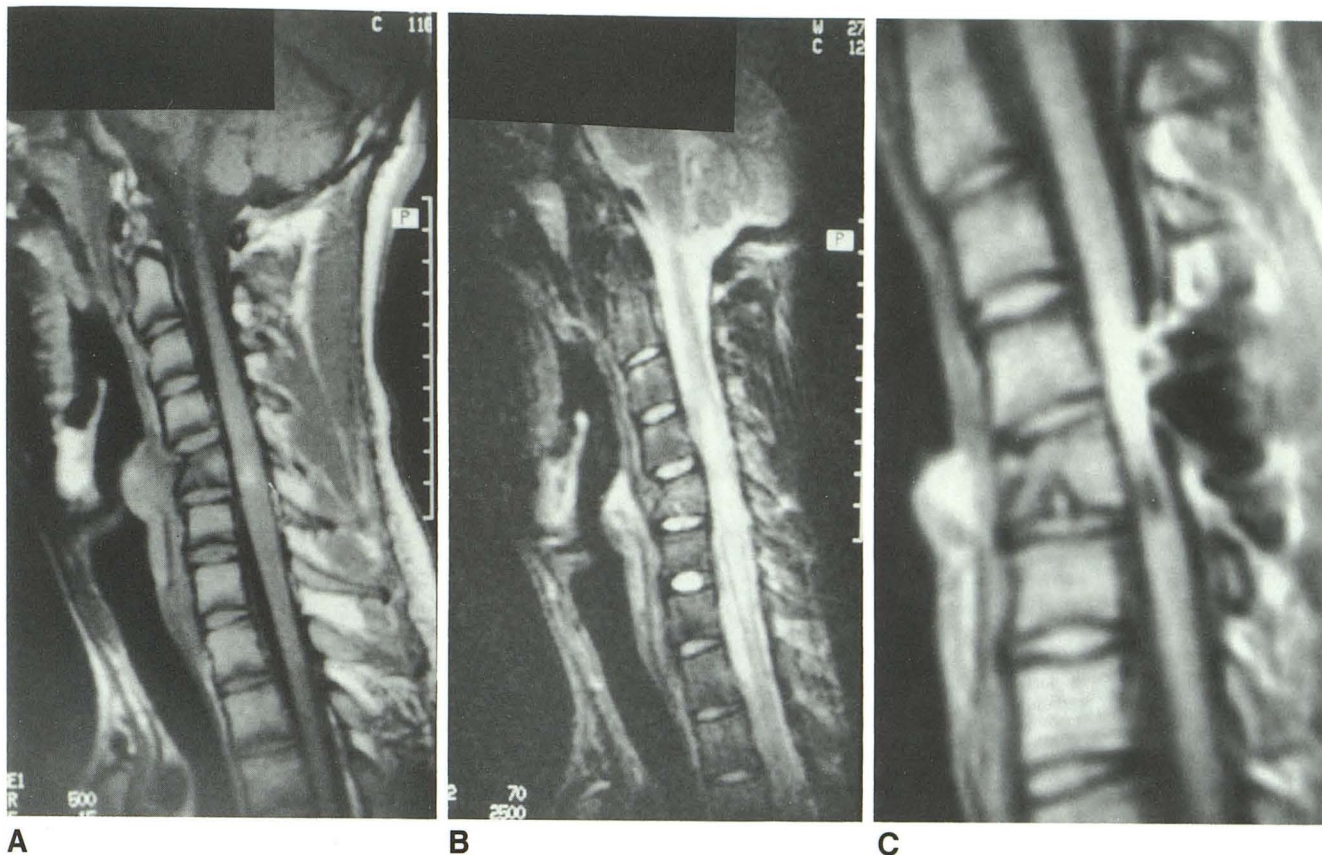


Fig. 2. Spinal cord contusion; 26-year-old man presenting grade A C5 quadriplegic; MR was performed at 9 days from injury.  
 A, Sagittal midline T1-weighted 1.5-T image demonstrates focal area of high signal in the cord opposite C5 associated with compression fracture of C5 vertebral body.  
 B, T2-weighted image shows diffuse high signal in cord from C2 to T1.  
 C, Sagittal T1-weighted image at 12 months from injury, following interspinous wiring, shows a small well-defined area of CSF intensity opposite C5.  
 This patient, with cord contusion, improved to grade C at follow-up.

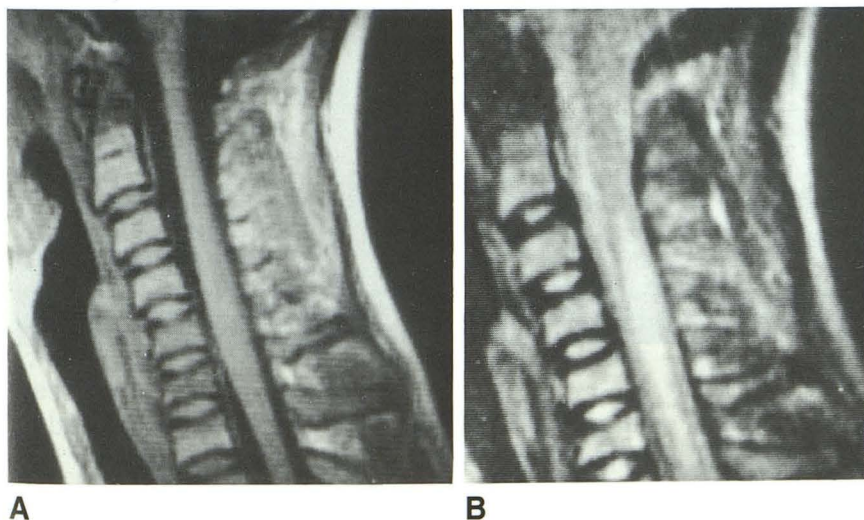


Fig. 3. Spinal cord edema; 12-year-old boy presenting grade A C6 quadriplegic; MR was performed at 2 days from injury.  
 A, Sagittal midline T1-weighted 0.3-T image shows cord swelling opposite C6 compression fracture.  
 B, T2-weighted image shows diffuse high signal in cord from C3 to C7.  
 This patient improved to grade D at follow-up.

ment at either presentation or follow-up was not significantly different between patients with spondylosis and those without, at either presentation ( $P = .15$ ) or follow-up ( $P = .45$ ).

Prevertebral swelling was present in 47% of patients. 80% of patients with prevertebral swelling presented grade A and only 25% improved to D or better.

TABLE 3: Initial and follow-up MR findings related to change in Frankel grade

Patient No.	MR Initial		MR Follow-Up		Clinical Change
	Time (days)	Findings	Time (mo)	Findings	
1	21	Transection	16	Transection	AA
2	15	Transection	7	Transection	AA <sup>a</sup>
		Contusion		Small cyst	
3	9	Contusion	11	Small cyst	AC
4	4	Contusion	13	Small cyst	AB
5	22	Contusion	10	Small cyst	AA
6	14	Contusion	34	Small cyst	AC
7	8	Contusion	26	Small cyst	AA
8	2	Contusion	12	Normal	BC
9	11	Edema	10	Cord atrophy	AA
10	2	Edema	23	Focal high T2	AD
11	3	Edema	28	Focal high T2	AD
12	6	Edema	33	Focal high T2	AD
13	2	Edema	48	Normal	AD

Note.—Small cyst = well-defined CSF intensity lesion in cord on T1, with high signal on T2, images. Patients 10 to 12 had normal T1 images.

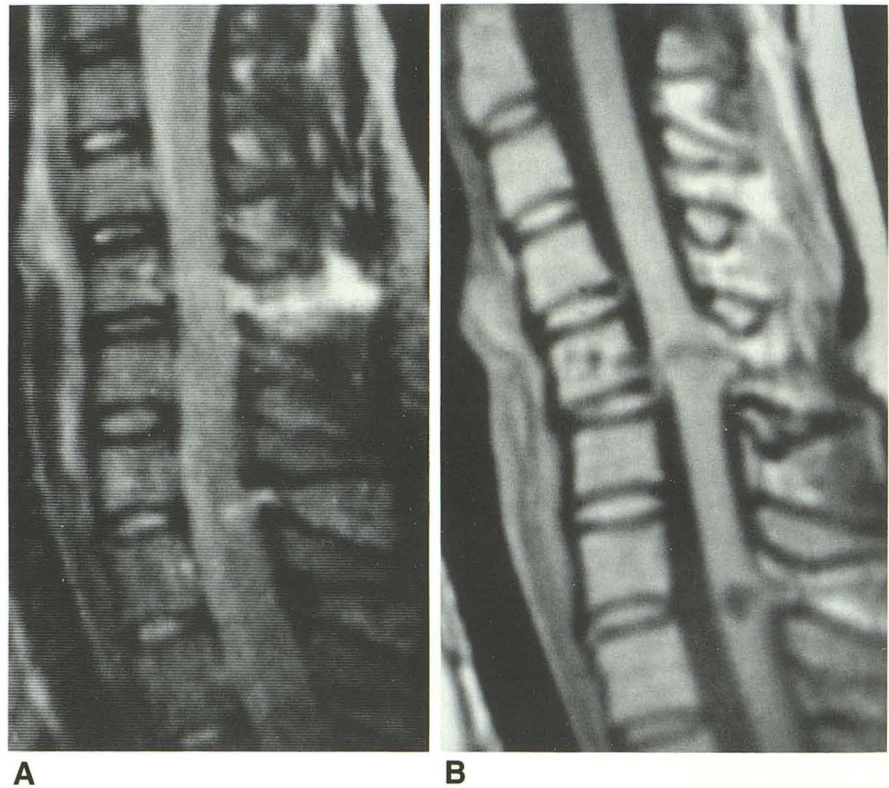
<sup>a</sup> Patient 2 had two clinical levels.

Fig. 4. Partial cord transection and contusion. 19-year-old girl presenting with a Brown-Séquard syndrome following a knife wound to the neck, resulting in complete left-sided motor paralysis, right-sided sensory deficit below C5, and incomplete paralysis of right hand and lower limb. MR was performed at 15 days from injury.

A, Sagittal T2-weighted 0.3-T image shows linear high signal extending through interspinous space, cervical cord, and C4 vertebral body. A small focal area of high signal is present in the cord opposite C7. Axial images confirmed left-sided cord hemisection at C4.

B, Sagittal T1-weighted image at 7 months from injury shows retraction of the cord at the site of transection. A small well-defined area of CSF intensity has developed at C7.

There was some improvement in right upper and lower limbs, but complete left-sided paralysis persisted at 7 months.



Ligament injury was found in 32% of patients, and 80% of these presented grade A (Fig. 6). Only one of these patients improved to grade D or better. A significant association between the presence of ligament injury and follow-up grade was demonstrated at  $P = .045$ .

Disk herniation was present in 25% of patients, 75% presenting grade A. Of these, 67% improved

to grade D or better, similar to the overall patient population (75%).

Extramedullary hematoma was found in 44% of patients of whom the majority presented grade A. Of these, only two (22%) improved to D or better. Significant association between the presence of extramedullary hematoma and follow-up grade was present at  $P = .05$ .

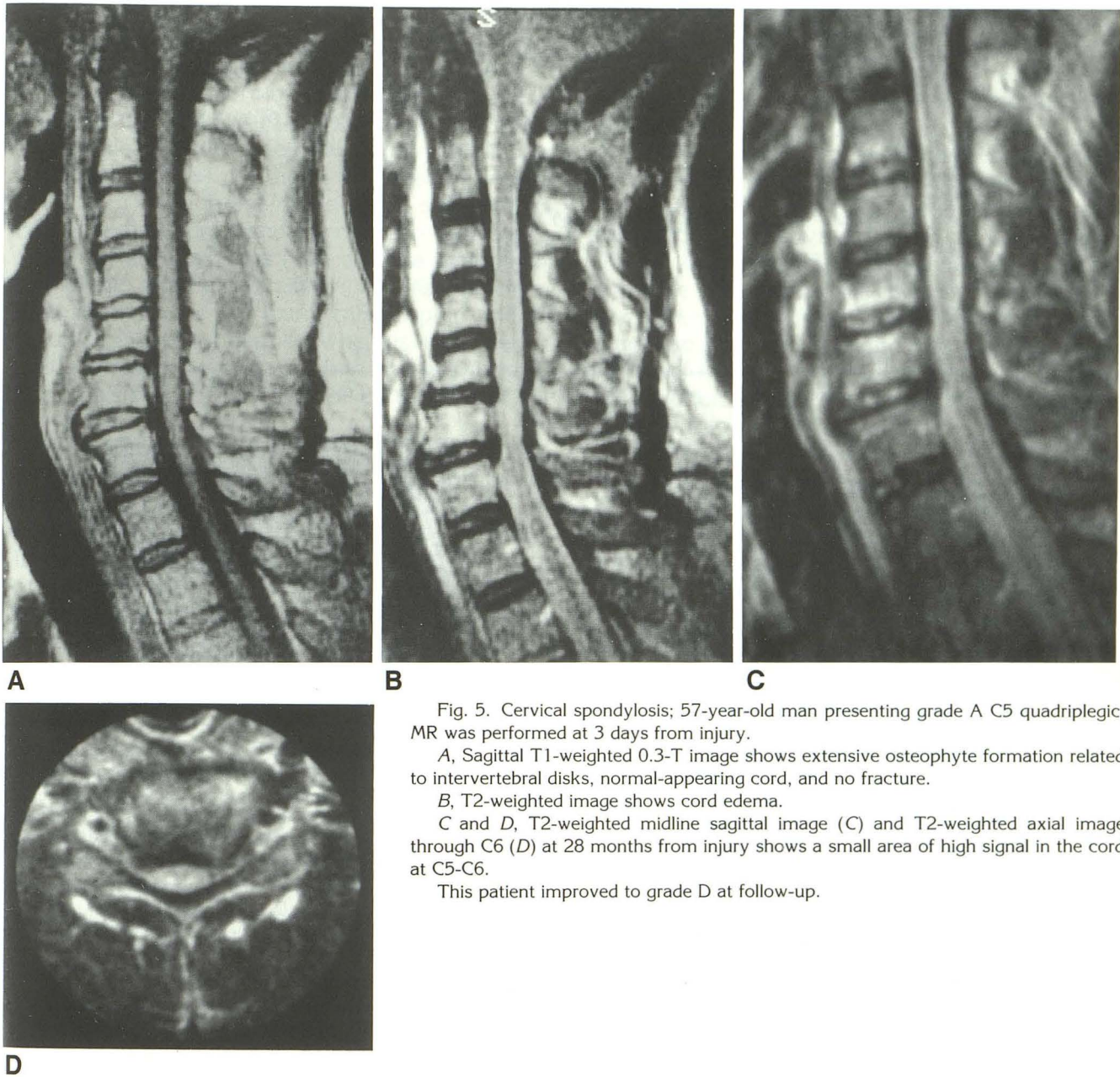


Fig. 5. Cervical spondylosis; 57-year-old man presenting grade A C5 quadriplegic; MR was performed at 3 days from injury.

A, Sagittal T1-weighted 0.3-T image shows extensive osteophyte formation related to intervertebral disks, normal-appearing cord, and no fracture.

B, T2-weighted image shows cord edema.

C and D, T2-weighted midline sagittal image (C) and T2-weighted axial image through C6 (D) at 28 months from injury shows a small area of high signal in the cord at C5-C6.

This patient improved to grade D at follow-up.

Spinal cord compression was found in 38% of patients, of whom 92% presented grade A (Fig. 7). Of these, only 27% improved to grade D or better. Significant association between cord compression and follow-up Frankel grade was present at  $P = .05$ .

#### *Effect of Patient Age on Outcome*

The patients' ages (mean and range) are presented relative to the initial and follow-up Frankel grades in Table 5. Ages were distributed relatively evenly among the different neurologic outcomes, and although the patients with follow-up grade E

were younger than those with lesser recovery, only two of the six patients in the latter group had presented grade A.

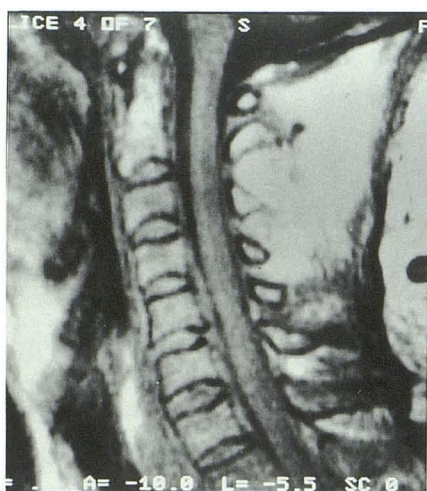
#### **Discussion**

The pathologic appearance of the spinal cord following injury includes a spectrum of findings, from macroscopically normal through cord swelling, punctate, or coalescent hemorrhages, edema, and in the most severe trauma, cord transection (15). In some cases, temporal progression to necrosis occurs, while in others, there is resolution (16). The recent correlation of his-

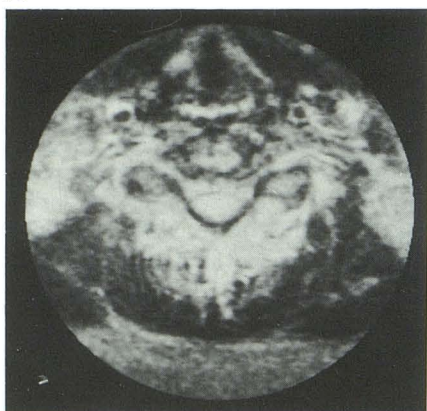
TABLE 4: Percentage of patients in each Frankel grade at presentation and follow-up (columns) related to other injuries (rows)

Frankel Grade	A		B		C		D		E		Total No.
	pre (%)	fol (%)	pre (%)	fol (%)	pre (%)	fol (%)	pre (%)	fol (%)	pre (%)	fol (%)	
Fracture	43	86	100	50	67	67	0	43	0	0	15
Subluxation	26	29	0	50	33	33	0	21	0	0	7
Spondylosis	43	43	0	0	0	33	0	43	0	0	10
Prevertebral swelling	52	86	33	50	67	100	0	36	0	0	15
Ligament injury	43	57	33	50	33	100	0	29	0	0	10
Disk herniation	26	29	0	0	0	0	67	29	0	33	8
Extramedullary hemorrhage	48	71	0	50	67	67	33	36	0	17	14
Cord compression	48	57	0	50	33	67	0	29	0	0	12
Total	23	7	3	2	3	3	3	14	0	6	32

Note.—Pre = Percentage in this grade at presentation. Fol = Percentage in this grade at follow-up.



A



B

Fig. 6. Ligament injury; 70-year-old man presenting grade A C6 quadriplegic; MR was performed at 13 days from injury.

A, Sagittal T1-weighted 0.3-T image shows anterior longitudinal ligament disruption at C5-C6 with anterior intraspinal hematoma and spinal cord compression.

B, Axial T2-weighted image shows cord edema.

This patient failed to improve at 12-month follow-up.

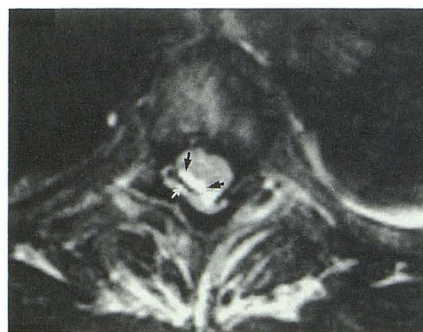

Fig. 7. Spinal cord compression; 35-year-old man presenting grade A T3 paraplegic; MR was performed at 11 days from injury. Axial T2-weighted 1.5-T image through upper thoracic cord shows displacement of cord anteriorly and to the left by epidural hematoma, containing a thin layer of intracellular deoxyhemoglobin (low signal, *white arrow*) with extracellular methemoglobin (high signal, *black arrows*) medially. The patient was not operated upon because of the relatively long elapsed time from injury to MR imaging. There was no improvement at 12 months.

TABLE 5: Effect of patient age on neurologic status

No.	Mean Age	Range	Initial	Follow-Up
7	36.1	15-70	7A	A
2	28.0	16-40	2A	B
3	30.3	12-53	2A 1B	C
14	35.1	18-65	10A 3B 1C	D
6	22.3	12-33	2A 1C 3D	E

topathologic patterns of cord injury with MR appearances (10) confirms three well-known pathologic observations: 1) at postmortem examination, the vast majority of lesions contain both hemorrhage and edema, and are termed contusions; 2) pure cord hemorrhage is rare; and 3) pure cord edema is uncommon at postmortem (15-17). In an attempt to correlate our MR findings with pathologic descriptions, we used the terms contusion and edema, with contusion anal-



ogous to the type I and type III pattern of other authors and including spinal cords with a spectrum of hemorrhagic and necrotic lesions, and edema analogous to the type II pattern used in previous descriptions (6–8). Although rare histopathologically, cord edema was common in our study as well as in those of others, possibly because T2-weighted MR is more sensitive for cord edema than standard microscopic examination of cord sections (10), and the majority of pathologic material available for histologic examination is derived from catastrophic injuries resulting in patient demise, whereas in our series, and in those of others, cord edema has a better prognosis than other types of cord injury (2, 6–9).

The majority (72%) of our patients had a neurologically “complete” lesion at presentation. Eighty-seven percent of these had some spinal cord abnormality demonstrated. This is in keeping with the data of Kulkarni et al (6) and Flanders et al (1). Cord swelling (57%) and cord edema (48%) were the commonest findings in these patients in our series, which is similar to results of previous studies (1–8). Flanders et al do not include a separate category for contusion, but the proportion of patients with contusion in our series (22%) is identical to the proportion with hematoma in the study of Flanders et al (1). The majority of our patients with contusion (86%) presented grade A. In contrast, 26% of Kulkarni’s group had cord hematoma, although almost all presented grade A, but only 50% of patients with contusion and 27% of patients with cord edema were grade A at presentation (6). A frequent finding in our patients was a normal cord with a clinical deficit (34%), which was far more frequent than in the series of Flanders et al (1) or Kulkarni et al (6), (8% and 10%, respectively).

The high predictive value of early MR for patient prognosis was confirmed. Irreversible cord injury, such as transection, has a 100% predictive value for lack of recovery. Lesser injury, such as contusion, yields a better prognosis. In view of the variable degree of edema and hemorrhage found in any contusion, it may be possible to correlate prognosis with both the degree of hemorrhage, and the extent, both longitudinal and transverse, of the cord abnormality, just as recent experimental work has correlated these observations with trauma intensity (10). We do not have sufficient patient numbers to do this. Cord edema was a good prognostic factor in our series, with a 73% predictive value for follow-up grade D.

Similarly, a normal cord at presentation was a very good prognostic marker, and even in patients presenting with “complete” neurology, a normal cord (13%) resulted in useful motor function at follow-up.

A recent report has suggested that the presence of cord swelling on CT-myelography is a strong predictor of a poor prognosis (18). In our series, the predictive value of cord swelling on MR for lack of recovery was only 35%, far less than the use of internal cord characteristics. In our series, 38% of the patients with cord swelling who had “complete” neurology at presentation had useful motor function at follow-up. Intrinsic cord abnormalities are far better predictors of prognosis than cord swelling.

Experimental observations at 0.5 T in dogs have demonstrated the validity of imaging spinal cord injury at this field strength (10). Only one of our patients demonstrated classical low signal intensity indicative of intracellular deoxyhemoglobin in subacute hemorrhage at 0.3 T, consistent with the known differences in imaging at low field strength (19). Diagnosis of hemorrhagic contusion was made on T1-weighted images in our study, similar to others using low to intermediate field strengths (4, 10, 20). However, we did have a lower proportion of cord hematoma, and a higher proportion of symptomatic patients with normal cords than in other series at 1.5 T, suggesting reduced sensitivity for cord abnormality at 0.3 T. Yet the prognoses for the specific observations in our series were very similar to those of Kulkarni and Bondurant (6–8). It may well be that the differences in types of cord abnormality observed in the different series may relate to the nature of the patients examined rather than the field strengths used. The clinical findings in our patients and those of Kulkarni and Flanders are compared with those of the large series of Frankel et al (11) and Maynard et al (21) in Table 6, excluding patients who were asymptomatic at presentation. Whereas the two large series of Frankel et al and Maynard et al demonstrate relative uniformity of presentation and follow-up groups, the three groups with imaging findings include a wider range of presentation and follow-up results, suggesting that each represents only a small sample of the whole population presenting following spinal cord injury. Therefore, the observation that each of our categories predicted follow-up outcome as well as those of previous MR studies at 1.5 T is a valid one, but the variation of MR findings in any one clinical

TABLE 6: Percentage of patients in each clinical category in this series compared with previously reported series

	Presentation				Follow-Up				
	A	B	C	D	A	B	C	D	E
Frankel (11) n = 585	66	12	8	14	52	11	8	24	8
Maynard (21) n = 114	54	16	20	10	44	6	6	33	10
Silberstein n = 32	72	9	9	9	22	6	9	44	19
Kulkarni (6) n = 29	59	7	14	21	38	3	3	14	31
Flanders (1) n = 47	49	21	13	38					

Note.—Relevant references in parentheses.

grade could be explained by the differences in the types of patients sampled in each study.

Descriptions of sequential changes in MR appearance of the spinal cord and correlation with neurologic status have been limited to those provided by Yamashita et al (9, 22) who described a total of 26 patients who underwent follow-up MR imaging following acute trauma. In their series, patients with hyper- or hypointense signal on initial T1-weighted images and hyperintense signal on T2-weighted images had low signal on T1-weighted, and high signal on T2-weighted images at follow-up, with a poor prognosis (22). Patients with normal signal on T1-weighted images and high signal on T2-weighted images at presentation, had lesser initial neurologic deficit, and, at follow-up, those with persistent signal abnormality had lesser improvement than those with return of signal to normal (9). By equating the MR imaging appearances in our patients with pathologic entities, we can expand on the results of Yamashita et al. Six of the seven patients with cord contusion in our series developed well-defined lesions of CSF intensity in the cord at the site of original abnormality, satisfying the criteria for small syrinx cavities (23). In the five patients in this group in whom clinical changes could be assessed, there was no useful motor function at follow-up. In contrast, three of the five patients with cord edema developed focal high signal in the cord on T2-weighted images, with good outcomes. These are likely to represent areas of myelomalacia or gliosis, similar to the N/Hi pattern of Yamashita et al, with a good prognosis (22). The likely pathologic explanations for these changes can be correlated with the MR appearances. In some patients, pathologic examination of the cord at an interval of months or years from trauma shows cystic cavities with fibrous or gliotic walls, while in others, especially with lesser degrees of injury, only small gliotic foci and small cysts are present (15). Our results suggest that the former group had cord contusions originally,

with a poor prognosis and the potential for developing a syrinx in the future, while the latter group had lesser injury such as cord edema, with a better prognosis.

Our study suggests that spondylosis is a risk factor for spinal cord injury following trauma, and also identifies the possible mechanism. In patients over 40, the prevalence of posterior osteophytes has been reported to be between 44% and 64% (24, 25). In our study, 80% of patients over 40 had posterior osteophytes, and only 30% of these had a fracture, in comparison to 55% of patients without spondylosis who had a fracture. Yet cord compression and subluxation were both three times more common patients with spondylosis than in those without.

It would appear that the degenerate spine is predisposed to subluxation, a finding associated with facet degenerative changes in the cervical spine even in the absence of an acute injury (26). As previously suggested, it is likely that the association involves narrowing of the spinal canal (27, 28), in view of our findings of a frequent association between cord compression by spinal osteophytes and presentation with a clinical deficit. Although one report has suggested that the severity of cord injury was less in patients with spondylosis than those without (29), there was no difference in severity at presentation or in the prognosis of the two groups in our study. Cord edema was by far the most common cord lesion in our patients with spondylosis (80%), probably accounting for the relatively good prognosis in this group, as was the case in our patient population as a whole.

The suggestion that patients with fractures have more severe deficits has been made in the past (30, 31), although not confirmed by Flanders et al (1). In our series, the presence of one or more fractures correlated with more severe deficit at presentation and worse prognosis at follow-up. Similarly, subluxation and ligament injury correlated with more severe deficit at presentation and

follow-up in our series. In the series of Flanders et al, the most frequent presentation grade in patients with epidural hematoma was A (50%). Seventy-nine percent of our patients with extramedullary hemorrhage presented grade A and the overall prognosis for patients with this abnormality was worse than for those without it.

Although, for the purposes of image analysis, the individual MR and CT findings were considered in isolation during data collection, this is obviously an artificial situation and is potentially misleading. The type of neurologic deficit experienced by a patient following spinal trauma reflects the nature of the injury to the spinal cord, which is the major clinical manifestation of an injury affecting multiple structures, including the vertebral column, ligaments, and paraspinal soft tissues. There are insufficient numbers in our study to separately analyze the effect of each form of additional injury (such as fracture or subluxation) on the neurologic status associated with each type of spinal cord abnormality. Nevertheless, this study does provide evidence to suggest that the greater the magnitude of initial injury, as manifested by injuries to surrounding structures, the worse the clinical deficit in the long term, an association that has been suggested on the basis of MR of experimental cord injury, where more severe cord injuries were associated with greater trauma intensities (10).

What is the mechanism by which these parameters influence neurologic deficit and long-term outcome? Research on the effects of trauma to the spinal cord has, in the past, focused on two main areas: examination of human necropsy material obtained at varying intervals following trauma, and experimental induction of spinal cord injury in laboratory animals with subsequent histopathologic examination of specimens following sacrifice (16, 32). In the latter technique, the majority of methods have involved direct cord compression, with a number of experiments involving cord stretching (33).

In our patients, when cord compression was demonstrated at MR, presentation neurologic deficit was either A or B, and the prognosis was significantly worse than for patients without cord compression. Sixty-four percent of the patients with cord edema and 60% of those with cord contusion had spinal cord compression. In the series of Flanders et al, the patients with the worst deficits had cord compression (1). Cord compression may still be the mechanism of cord injury even when there is apparent normal bony

alignment at the time of radiography. With ligamentous disruption, momentary dislocation may occur, resulting in transitory cord compression, with spontaneous reduction by muscle action, and maintenance of the reduction by muscle spasm (28). Cord stretching, as well as compression, may play a role in spinal cord injury in humans. In hyperflexion injuries, the spinal cord may be stretched over the anterior wall of the spinal canal "like a string over a violin bridge," causing injury at the site of contact (34).

Our observations with MR and CT suggest that spinal cord injury may result from a combination of factors, including fracture, disk herniation, extramedullary hematoma, ligament injury, and subluxation. As the final common pathway may be cord compression, the prevention of ongoing cord compression in patients with potentially reversible cord abnormality (such as edema) or with normal spinal cords might improve outlook. It may be that the poor prognosis of some of the patients in this series, where early surgical decompression was not performed, could have been improved by early operation, especially the patients with acute disk herniations and extramedullary hematomas. The ability of MR to demonstrate the direction from which compression occurs could guide the surgeon into the nature of the decompression (for example, anterior decompression for osteophytes on the anterior wall of the spinal canal) and ultimately result in an improved outlook for these patients.

In summary, the presence of a spinal cord abnormality on MR imaging following acute spinal cord injury correlates with a more severe neurologic deficit at presentation. The MR appearances of the cord are prognostic, with patients who have cord transection failing to improve, those with cord contusion demonstrating some improvement and developing residual spinal cord cysts, and those with cord edema frequently having useful motor function at follow-up, with resolution of edema and, in some cases, residual small areas of myelomalacia. The presence of a normal spinal cord is a strong predictor of a good outcome. Cord swelling is not, in itself, a useful predictor of poor outcome. The presence of associated spinal fractures, subluxation, ligament injury, prevertebral swelling, or extramedullary haematoma is associated with a greater clinical deficit at presentation and a worse prognosis. The presence of spondylotic changes in the spine is associated with increased risk of cord injury following trauma. Spinal cord compression

is associated with more severe clinical deficits and a worse prognosis, and may be the final pathway by which spinal cord injury occurs following trauma. MR imaging is a valuable method of quantifying cord injury and predicting prognosis following spinal trauma.

## Acknowledgment

We thank Andrew MacKenzie, BSc, for his statistical assistance.

## References

- Flanders AE, Schaefer MD, Dean HT, et al. Acute cervical spine trauma: correlation of MR imaging findings with degree of neurologic deficit. *Radiology* 1990;177:25-33
- Mirvis EE, Geisler FH, Jelinek JJ, et al. Acute cervical spine trauma: evaluation with 1.5 T MR imaging. *Radiology* 1988;166:807-816
- Beers GJ, Raque GH, Wagner GG, et al. MR imaging in acute cervical spine trauma. *J Comput Assist Tomogr* 1988;12:755-761
- Tarr RW, Drolshagen LF, Kerner TC, et al. MR imaging of recent spinal trauma. *J Comput Assist Tomogr* 1987;11:412-417
- Kerslake RW, Jaspan T, Worthington BS. Magnetic resonance imaging of spinal trauma. *Br J Radiol* 1991;64:386-402
- Kulkarni MV, Bondurant FJ, Rose SL, Narayana PA. 1.5 Tesla magnetic resonance imaging of acute spinal trauma. *Radiographics* 1988;8:1059-1082
- Kulkarni MV, McArdle CB, Kopanicky D, et al. Acute spinal cord injury: MR imaging at 1.5 T. *Radiology* 1987;164:837-843
- Bondurant FJ, Cotler HB, Kulkarni MV, et al. Acute spinal cord injury: a study using physical examination and magnetic resonance imaging. *Spine* 1990;15:161-168
- Yamashita Y, Takahashi M, Matsuno Y, et al. Acute spinal cord injury: magnetic resonance imaging correlated with myelopathy. *Br J Radiol* 1991;64:201-209
- Schouman-Claeys E, Friaia G, Cuenod CA, et al. MR imaging of acute spinal cord injury: results of an experimental study in dogs. *AJNR* 1990;11:959-965
- Frankel HL, Hancock DO, Hyslop G, et al. The value of postural reduction in the initial management of closed injuries of the spine with paraplegia and tetraplegia: Part I. *Paraplegia* 1969;7:179-192
- Sherman JL, Nassaux PY, Citrim CM. Measurements of the normal cervical spinal cord on MR imaging. *AJNR* 1990;11:369-372
- Nordquist L. The sagittal diameter of the spinal cord and subarachnoid space in different age groups: a roentgenographic post-mortem study. *Acta Radiol Diagn* 1964;(suppl 227):1-86
- Clark WM, Gehweiler JA Jr, Laib R. Twelve significant signs of cervical spine trauma. *Skeletal Radiol* 1979;3:201-205
- Kakulas BA, Bedbrook GM. Pathology of injuries of the vertebral column. In: Vinkman PJ, Bruyn GW, eds. *Handbook of clinical neurology*. New York: American Elsevier, 1976;25:27-42
- Kakulas BA. Pathology of spinal injuries. *Cent Nerv Syst Trauma* 1984;1:117-126
- De La Torre JC. Spinal cord injury: review of basic and applied research. *Spine* 1981;6:572-582
- Koyanagi I, Iwasaki Y, Isu T, Akino M, Abe H. Significance of spinal cord swelling in the prognosis of acute cervical spinal cord injury. *Paraplegia* 1989;27:190-197
- Zimmerman RD, Heier LA, Snow RB, Liu DPC, Kelly AB, Deck MDF. Acute intracranial hemorrhage: intensity changes on sequential MR scans at 0.5 T. *AJNR* 1988;9:47
- Kalfas I, Wilberger J, Goldberg A, Prostko ER. Magnetic resonance imaging in acute spinal cord trauma. *Neurosurgery* 1988;23:295-299
- Maynard FM, Reynolds GG, Fountain S, Wilmot C, Hamilton R. Neurologic prognosis after traumatic quadriplegia. *J Neurosurg* 1979;50:611-616
- Yamashita Y, Takahashi M, Matsuno Y, et al. Chronic injuries of the spinal cord: assessment with MR imaging. *Radiology* 1990;175:849-854
- Quencer RM. The injured spinal cord: evaluation with magnetic resonance and intraoperative sonography. *Radiol Clin North Am* 1988;26:1025-1045
- Gore DR, Sepic SB, Gardner GM. Roentgenographic findings of the cervical spine in asymptomatic people. *Spine* 1986;11:521-524
- McRae DL. The significance of abnormalities of the cervical spine. *AJR* 1960;84:3-23
- Epstein BS. *The spine: a radiological text and atlas*. 3rd ed. Philadelphia: Lea & Febiger, 1969:524-525
- Hackney DB. Denominators of spinal cord injury (editorial). *Radiology* 1990;177:18-20
- Regenbogen VS, Rogers LF, Atlas SW, Kim KS. Cervical spinal cord injuries in patients with cervical spondylosis. *AJR* 1986;146:277-284
- Rowed DW, Tator CH. Cervical spondylosis in acute cervical cord injuries. In: Tator CH, ed. *Early management of acute spinal cord injury*. New York: Raven, 1982:335-347
- Riggins RS, Kraus JF. The risk of neurologic damage with fractures of the vertebrae. *J Trauma* 1977;17:127-133
- Hardy AG. Cervical spinal cord injury without bony injury. *Paraplegia* 1977;14:296-305
- Janssen L, Hansebout RR. Pathogenesis of spinal cord injury and newer treatments: a review. *Spine* 1989;14:23
- Dohrmann GJ. Experimental spinal cord trauma: a historical review. *Arch Neurol* 1972;27:468-474
- Braakman R, Penning L. Injuries of the cervical spine: In: Vinkman PJ, Bruyn GW, eds. *Handbook of clinical neurology*. New York: American Elsevier, 1976;25:261-262