

Acute Subarachnoid Hemorrhage: In Vitro Comparison of Magnetic Resonance and Computed Tomography

Donald W. Chakeres¹
R. Nick Bryan²

The computed tomographic (CT) attenuation values and magnetic resonance (MR) signal intensities of simulated acute subarachnoid hemorrhage were compared systematically. In vitro MR and CT measurements (T1, T2, and Hounsfield units) were made of mixtures of normal human cerebrospinal fluid (CSF) and normal heparinized blood, ranging from 0% to 100% by volume. The mixtures were measured in a plexiglass phantom with a Siemens DR3 CT scanner for attenuation measurements (Hounsfield units) and in the Baylor Bruker Instruments Proton Scanner (6-MHz) using inversion-recovery and spin-echo pulse sequence techniques for T1- and T2-calculated relaxation times. A PRAXIS II (10.7 MHz permanent magnet) nonimaging unit was used to measure the relaxation times of the CSF/blood mixtures independently for comparison. The Hounsfield measurements of the densest parts of the layered mixtures showed increasing values with increasing amounts of hemorrhage (0% blood, 0 H; 100% blood, 66 H) in a nonlinear pattern. The T1 times of the mixtures decreased with increasing amounts of blood, ranging from 2200 msec to 500 msec for 100% CSF and 100% blood, respectively. The inverse of the T1 relaxation times was proportional to the percentage of blood. The T2 data for the mixtures were similar in character to the T1 relaxation times, except for shorter T2 times at high concentrations of blood. It was concluded the MRI distinguishes varying blood/CSF mixtures on the basis of relaxation times better than does CT on the basis of Hounsfield units. CT still has an imaging advantage, since high-concentration hemorrhage is clearly different from normal brain, while concentrated acute subarachnoid blood has relaxation times similar to normal brain and is nearly isointense on MRI.

Recognition of acute subarachnoid hemorrhage by magnetic resonance imaging (MRI) is an important clinical problem. MRI has been reported to be an excellent screening method for evaluation of a wide range of central nervous system abnormalities [1-4]. The computed tomographic (CT) and MRI appearances of mixtures of spinal fluid and blood have not been studied in detail. MR studies have been made of human blood of varying hematocrits and solutions of varying protein concentrations [5-8]. This work systematically compares the in vitro appearance and intrinsic parameters—longitudinal (T1) and transverse (T2) relaxation times and Hounsfield units—of simulated acute subarachnoid hemorrhage as it is demonstrated by MRI and CT scanning. With this data, predictions as to the expected sensitivity and specificity as well as the best pulse sequence technique for subarachnoid hemorrhage can be made.

Materials and Methods

Volume mixtures of normal volunteer blood (hematocrit \approx 40%) and normal human cerebrospinal fluid (CSF) (collected from a temporary intraventricular shunt tube externally drained) ranged from 0% blood (100% CSF) to 100% whole blood. The blood was heparinized to maintain it in solution, and 1.5 ml of each mixture was then placed into a solid 20-cm-radius, 2.5-cm-thick Plexiglas phantom disk with multiple drilled resources measuring 1.5 cm in depth and 1 cm in diameter. The surfaces of the solutions were covered with melted wax for the

Received March 12, 1985; accepted after revision August 14, 1985.

Presented at the annual meeting of the American Society of Neuroradiology, New Orleans, February 1986.

¹Department of Radiology, Neuroradiology Section, University of Texas Health Science Center, 7703 Floyd Curl Dr., San Antonio, TX 78284. Address reprint requests to D. W. Chakeres.

²Department of Radiology, Neuroradiology Section, Methodist Hospital, Baylor University, Houston, TX 77025.

AJNR 7:223-228, March/April 1986
0195-6108/86/0702-0223

© American Society of Neuroradiology

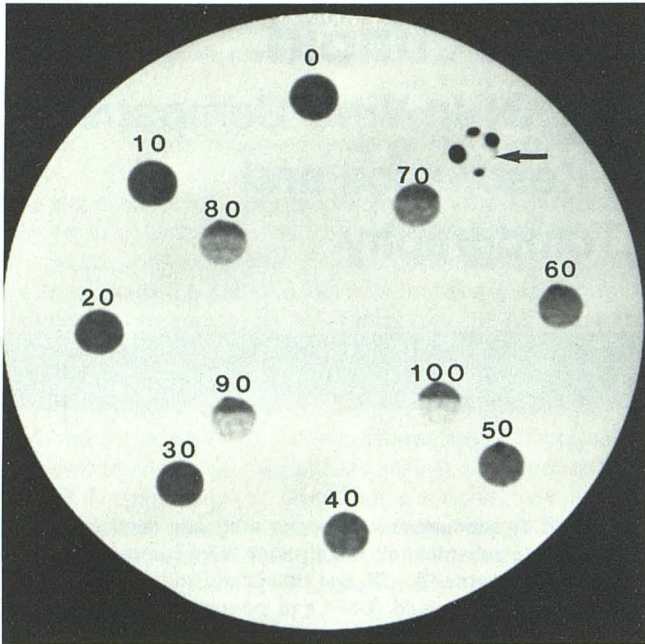


Fig. 1.—CT of blood/CSF mixtures ranging from 0% blood/100% CSF to 100% blood/0% CSF imaged in circular Plexiglas phantom. Concentration (% blood) labeled adjacent to each reservoir. Note gradual increase in apparent density with increasing percentage of blood. Fluid-fluid levels evident in more concentrated mixtures. Visual differentiation of dilute mixtures is poor. Solid clot is densest specimen in single reservoir with few bubbles of surrounding air (arrow).

direct CT images. The mixtures of blood and CSF as well as a pure dense clot (without serum) were then imaged with a Siemens DR3 CT scanner. Sections 4 mm thick made at 120 kVp with high milliamperage settings (719 ma) and a long scan time (14 sec) were made for Hounsfield measurements. Data were obtained using a circular computer cursor range-of-interest (ROI) measurement of the most dependent portion of the solutions that was most dense due to layering. The CT image of the phantom (fig. 1) and a graph of Hounsfield units versus volume percentage blood/CSF (fig. 2) are shown.

Identical mixtures of blood and CSF ranging from pure CSF to whole blood were measured at room temperature using a PRAXIS II permanent magnet system (10.7 MHz, 2.5 kG). T1 measurements were made by the partial-saturation technique: repetition time (TR), 8 sec; multiple 90° radiofrequency detection pulses (TEs), 5–160 msec. T2 measurements were made using the Hahn spin-echo (SE) technique (TR, 8 sec; TE, 1–30 msec). The T1 data versus percentage blood/CSF are plotted in figure 3.

Similar mixtures of blood in the same Plexiglas phantom were imaged using the Baylor Bruker Instruments Proton resistive electromagnet (6 MHz, 1.4 kG) scanner. Using a long TR of 6.1 sec, multiple inversion-recovery (IR) images at 250, 500, 750, 1000, 2000, and 3000 msec inversion times (TIs) (fig. 4) were generated for a calculated T1 image (fig. 5). By using the Carr-Purcell SE technique (TR of 6.1 sec; 32 multiple TEs up to 120 msec), a T2 image was calculated (fig. 6). The T2 data are plotted in figure 7. The same mixtures were imaged using standard patient imaging protocols with SE (TR, 1.1 sec; TE, 30, 60, 90, and 120 msec) (fig. 8) and IR (TR, 1.1 sec; TI, 250, 500, 750, and 1000 msec) sequences. Comparison of the MRI and CT images of the similar mixtures was made. The data were collected by using an ROI cursor. The average of each sample was measured without considering layering of the blood.

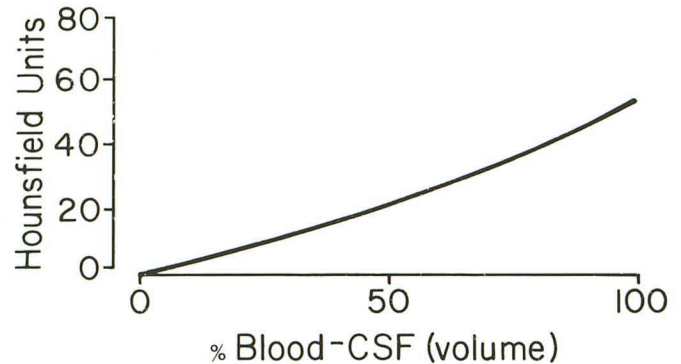
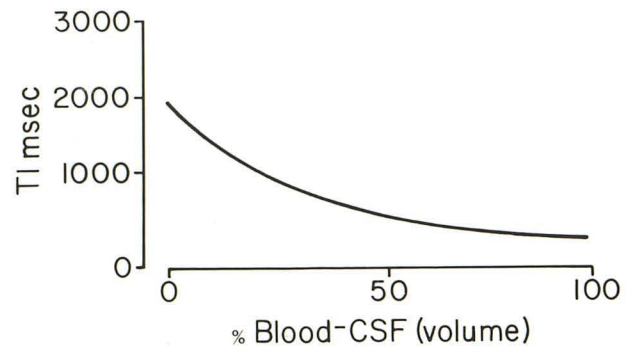
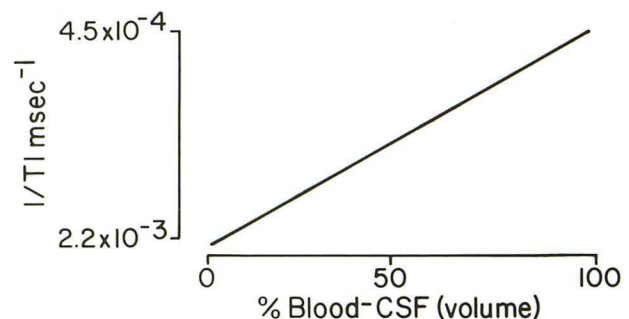


Fig. 2.—Hounsfield units vs. blood/CSF volumes. Hounsfield values for densest parts of layering mixtures of blood and CSF from phantom study in fig. 1 plotted vs. percentage volume of blood/CSF. Hounsfield value is not a simple linear relation of blood concentration; it rises more rapidly in most concentrated mixtures. Hounsfield values of mixtures are not clearly more dense than normal brain (35 H) until blood is 70%.



A



B

Fig. 3.—A, T1 vs. blood/CSF volumes. T1 relaxation times plotted vs. blood/CSF concentrations measured by Praxis II unit. T1 for pure CSF (0% blood/100% CSF) is similar to pure water or saline (2200 msec). Progressive diminution of T1 relaxation times with increasing amounts of blood. In contrast to CT data (fig. 2), greatest incremental changes occur between more dilute mixtures. B, 1/T1 vs. blood/CSF volumes. Inverse of T1 relaxation times in A vs. percentage blood/CSF. Relation is linear, similar to many other liquid systems.

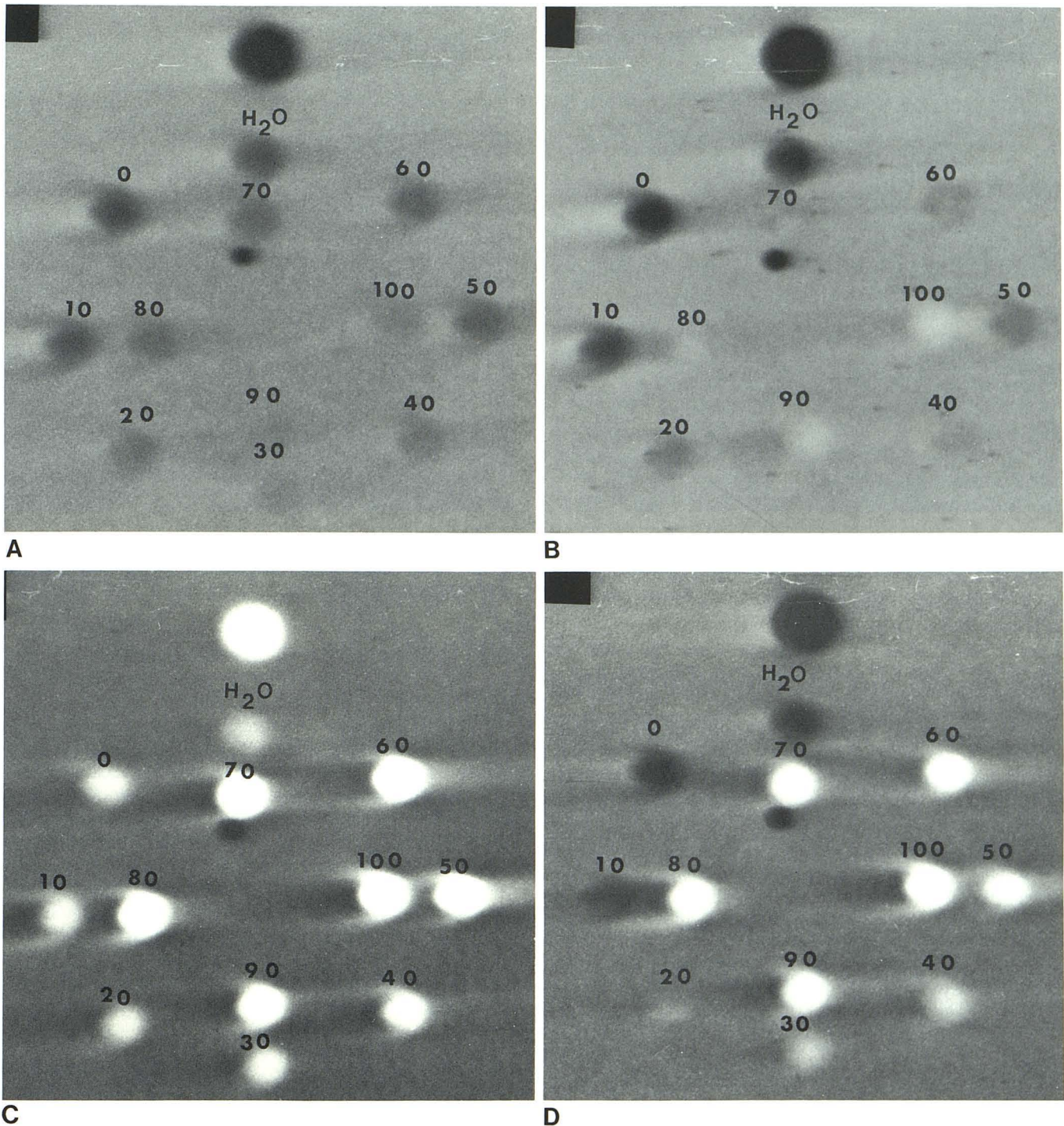


Fig. 4.—IR images. Four free induction decay signal images used to generate calculated T1 image of blood/CSF mixtures (fig. 5) at TR 6.1 sec. TIs were 250 (A), 500 (B), 1000 (C), and 2000 (D) msec. On short TI images, mixtures with highest intensity are those with shortest TI times and highest concentrations

of blood. With increasing TI (500–1000 msec), good contrast of mixtures is seen. ON 2000-msec TI image, all mixtures are bright and lose contrast. Time is sufficient for longitudinal magnetizations for all mixtures to recover. D, Least T1-dependent and least contrast.

Results

With increasing concentrations of blood, the Hounsfield measurements of the dependent portion of the sample increased (fig. 1). Hounsfield units versus percentage blood/

CSF (fig. 2) is not a simple linear relation. The highest Hounsfield unit was measured for a dense solid clot (66 H) and the lowest was zero H for pure CSF. Below 50% blood/50% CSF, the mixture is less dense than normal brain (35 H). At about 60% blood/40% CSF, the mixture is isodense with

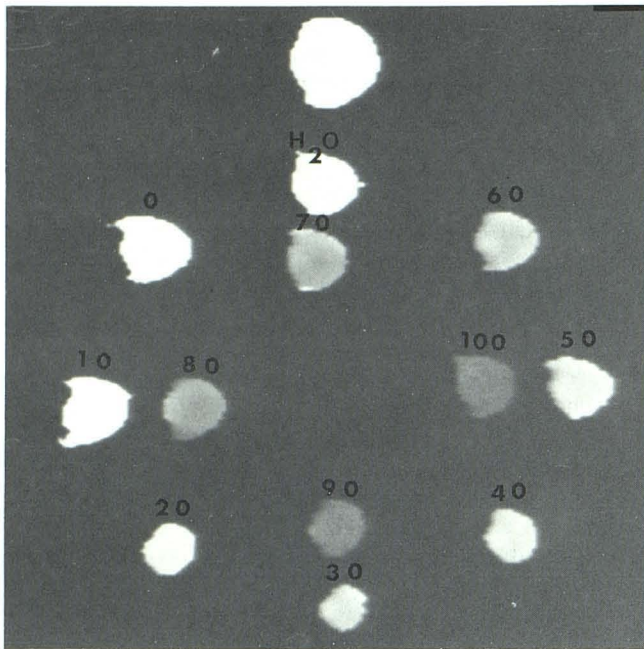


Fig. 5.—T1-calculated image. Phantom and blood/CSF mixtures as seen in figures 1 and 4 displayed as calculated T1 relaxation times generated from multiple IR images (fig. 4) on Bruker imager. Percentage blood/CSF concentrations are labeled. T1 relaxation times and pixel intensities decrease with increasing concentrations of blood.

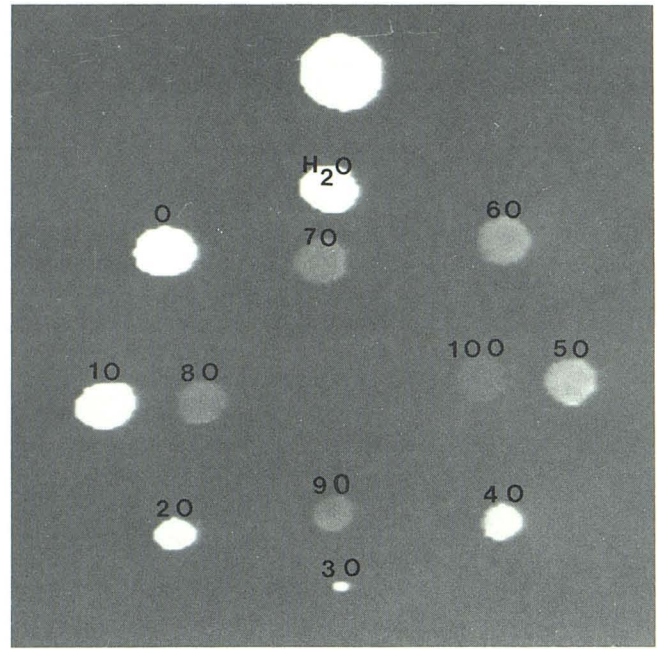


Fig. 6.—T2-calculated image. Blood/CSF mixtures from fig. 5 are displayed with intensities proportional to calculated T2 relaxation times. Intensities are very similar to T1 image, showing decreasing intensity with increasing concentration of blood.

brain. Above 70% blood/30% CSF, the mixture is more dense on CT than normal brain.

The calculated T1 relaxation times for spinal fluid using the Praxis and the Bruker imager were essentially that of water, measuring about 2200 msec. With increasing concentrations of blood there was a decrease in the longitudinal relaxation time measured by both Praxis and Bruker imager (fig. 2). The exact T1 values for the same solution measured by the Praxis and the Bruker imager were different because of different field strengths, computational differences, and pulse sequence techniques. Pure dense clot without serum has the shortest T1 (550 msec) measured by the Praxis II. There was only a small increase of the T1 between immediate, fresh isolated clot (without serum) and the same clot after ultrasonic lysing to a liquid form and then measured within minutes. The T1 of 100% whole heparinized blood is slightly longer (650 msec). The inverse of the T1 of the mixtures is proportional to the volume percentage blood/CSF (fig. 3B), allowing for the approximate prediction of the expected T1 for any percentage blood/CSF mixture.

T2 relaxation times for the blood CSF mixtures on the Bruker imager decreased in a similar fashion to that seen with the T1 data (fig. 7), although the actual relaxation times in general were shorter. The shortest T2 relaxation time was measured for whole blood (150 msec). The T2 relaxation times measured by the PRAXIS unit were substantially shorter than those measured by the Bruker imager and did not follow the same pattern. The PRAXIS T2 data is not believed to be as accurate (secondary to diffusion), and is not valid for comparison. The Hahn SE technique is much less acceptable

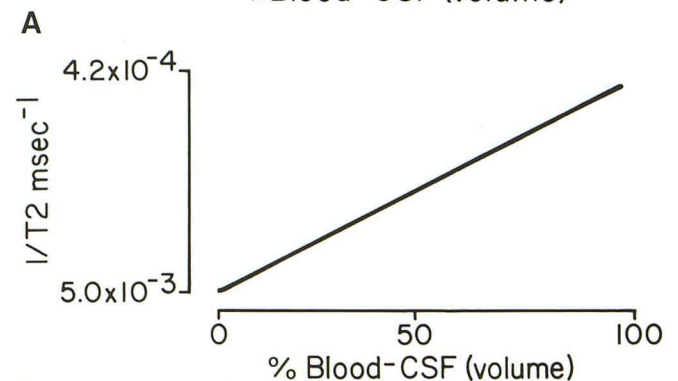
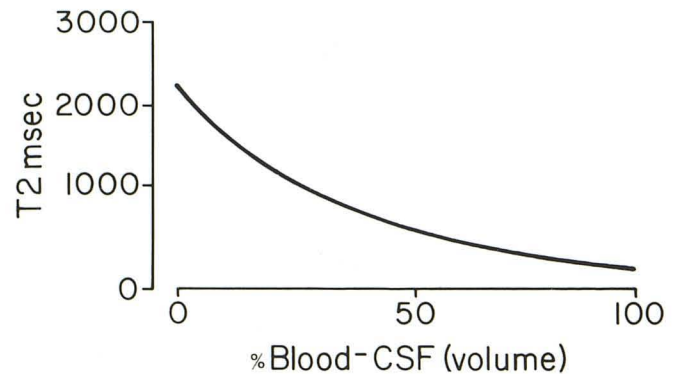


Fig. 7.—A, T2 vs. blood/CSF volumes. Calculated T2 times from Bruker imager vs. percentage blood/CSF produce curve similar to T1 data (fig. 3A). B, $1/T_2$ vs. % blood/CSF volumes. Inverse of T2 vs. percentage blood/CSF is also linear relation as in T1 inverse (fig. 3B).

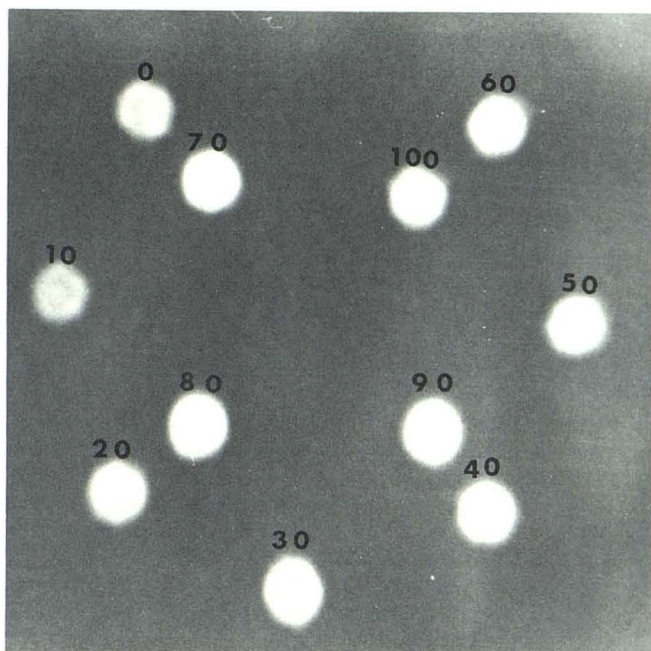


Fig. 8.—Carr-Purcell SE image of same blood-CSF mixtures (TR, 1.1 sec; TE, 60 sec) simulates standard patient study protocol and shows poor contrast among varying percentages of blood/CSF mixtures. Individual T1 and T2 differ for each reservoir, but combined effect leads to little apparent contrast.

than the Carr-Purcell technique for T2 calculations of liquid samples with long T1 and T2 times [9].

CT recognition of small amounts (<50% blood/CSF) and minor differences between various mixtures was difficult, but there was a progressive elevation of the Hounsfield measurements for blood/CSF mixtures (>70% blood/CSF) well above normal brain with high concentrations of blood (fig. 1). MRI recognition of differences between the mixtures of the blood and CSF was easiest on the calculated T1 and T2 images (figs. 5 and 6). On the IR images, decreasing signal was seen with decreasing blood concentration (fig. 4). With lengthening TI intervals, the signal intensities of the mixtures increased until they approached a maximum high signal appearance for long TI times (>2 sec). Contrast between the mixtures was most clearly evident on the 1-sec T1 image. The contrast between the various mixtures on SE was poor (fig. 8).

Discussion

MRI is a very sensitive imaging technique for the definition of many different types of pathology [1]. Although more sensitive than CT for many pathologic states, MRI has been reported to be insensitive in recognition of certain findings such as calcification [10]. Many patients with severe subarachnoid hemorrhage are not candidates for MRI because the life support systems of these critically ill patients are not compatible with strong magnetic fields. Of those patients studied by MRI, recognition of acute subarachnoid hemorrhage is a crucial radiographic finding for patient management, since the therapy and diagnostic workup will significantly change if blood is present. Subarachnoid hemorrhage occurs

in a wide range of varying clinical settings, and early accurate identification is essential for appropriate patient care.

The Hounsfield measurements of blood have been found to be related to the hematocrit [11]. They are related predominantly to the hemoglobin molecule and other proteins, not to the iron content. Hounsfield measurements for mixtures of CSF and blood have not been studied in detail. Our results are slightly different than those reported with blood, since we measured the most dense segment of the sample rather than an average. Also, diluting the blood with CSF is not exactly identical to simply changing the hematocrit with plasma. This study explains why CT frequently fails to identify subarachnoid hemorrhage even though the fluid may have a significant component of blood (<60% blood-CSF). CT recognition of subarachnoid hemorrhage of blood-tinged fluid is not possible. This study shows that the amount of hemorrhage visible on CT is much greater than most radiologists would expect. We suspect that many of the hemorrhages seen on CT are clots rather than dilute liquid hemorrhage. The rise in Hounsfield units for increasing amounts of blood below 40% blood-60% CSF is minor. A small increase is insufficient for accurate recognition, particularly if the blood is nearly isodense with normal brain or CSF.

T1 relaxation times for whole blood have been shown to shorten with increasing hematocrit (Dornbluth NC, Potter JL, Fullerton GD, Joyce J, unpublished data). The inverse of T1 of whole blood is proportional to the hematocrit. Our study generated very similar results, with an increasing percentage of CSF producing a longer T1 and in effect lowering the hematocrit of the blood-CSF mixtures. Our T2 data followed a qualitative pattern similar to the T1 times for similar mixtures. The T2 relaxation times were in general shorter than T1 for the same mixture.

Immediate intracranial hemorrhage in either the parenchyma, subdural or epidural spaces has been reported to be nearly isodense with brain on immediate MRI and CT studies [2-4, 12-14]. With CT scanning, rapid changes in the appearance of hemorrhages, particularly those in the epidural and subdural spaces, have been extensively studied and are noted to progress through a standard pattern. Initially the acute hemorrhage is seen as a nearly isodense lesion; this is rapidly followed by a hyperdense appearance in a period of minutes to hours as the plasma is reabsorbed. Over an interval of days the hemorrhage matures and begins to liquefy. It becomes isodense with brain again, and then may gradually progress to a spinal fluid appearance over a period of days to weeks.

On the Baylor Bruker imager, the normal T1 range for brain is 300-500 msec, and the normal T2 time for brain is 100 msec. Our data show that with increasing amounts of blood in the CSF, T1 (whole blood, 500 msec) approaches normal brain (500-300 msec). The T2 of our whole blood samples (150 msec) were always slightly longer than of normal brain (100 msec).

MRI vs. CT

MRI has a significantly greater inherent change of the relaxation times (2200-150 msec) for mixtures of blood and

CSF than the absolute changes in Hounsfield units seen on CT scans (0–60 H) for the same concentrations of blood–CSF mixtures. Theoretically, identification of changes in the subarachnoid space would be much easier by MRI than by CT scanning because of the marked relaxation time differences of normal and bloody CSF. However, this may not be true in the routine clinical setting. Separation of normal and dilute CSF hemorrhages (<40%) may be possible by MRI. The greatest incremental changes were observed in the more dilute mixtures. One problem of MRI is that most imaging techniques for patient studies use relatively short TR intervals (<2500 msec), which suppresses the differences in signal for long T1 tissues (since they all have a low signal). Also, the T1 relaxation time of dense acute blood is never shorter than that of brain, and thus it will not stand out as a high-intensity abnormality on most pulse sequence techniques. Recognition of even major changes of the slitlike subarachnoid spaces by MRI may be obscured by partial-volume averaging.

CT scanning has the advantage of immediate identification of acute concentrated hemorrhage (>70% blood) or clot formation since it is seen as a dense region. This allows for visual recognition of the hemorrhage if the patient has a normal hemoglobin. Consistent visualization of bloody spinal fluid (where about 50% or less of the volume is blood) is a serious CT imaging problem since dilute bloody CSF is nearly isodense with both CSF or brain. Subarachnoid hemorrhage may be quite extensive (<40% blood–60% CSF) and still appear essentially isodense with normal CSF or brain. It should be made clear to the referring clinicians that a major acute subarachnoid hemorrhage may not be visible by either MRI or CT imaging. Therefore, in all cases where there is a high clinical suspicion for subarachnoid hemorrhage with negative imaging studies, lumbar puncture is essential to exclude subarachnoid blood.

There are a number of major limitations of this in vitro technique, including the fact that there is no movement (flow dynamics) of the mixtures in comparison with normal patient examinations. Circulation and pulsation of the CSF may have an imaging effect. The volume (1.5×1 cm) of hemorrhage imaged in this study is significantly larger than that expected in many of the slitlike subarachnoid spaces. The effect of partial-volume averaging is not evaluated. There are rapid metabolic changes of blood in the subarachnoid spaces related to hemolysis and white blood cell phagocytosis [15]. The MRI changes related to oxygenation, pH [5–7], breakdown of the hemoglobin pigments [16], and clot lysis cannot be simulated in an in vitro test tube model. Despite these limitations, we still believe that this study is a good model for the definition of the expected MRI appearance of acute sub-

arachnoid that can be used to predict trends in the appearance of hemorrhage in actual patient studies.

REFERENCES

1. Brant-Zawadzki M, Norman D, Newton TH, et al. Magnetic resonance of the brain: the optimal screening technique. *Radiology* **1984**;152:71–77
2. Ham JS, Kaufman B, Alford RJ, et al. Head trauma evaluated by magnetic resonance and computed tomography. A comparison. *Radiology* **1984**;150:71–77
3. Sepponen RE, Sivula A. Chronic subdural hematoma demonstrated by magnetic resonance. *Radiology* **1984**;150:79–85
4. Moon RL, Brant-Zawadzki M, Pitts PH, Mills CM. Nuclear magnetic resonance imaging of CT-isodense subdural hematomas. *AJNR* **1984**;5:319–322
5. Koivula A, Suominen K, Timonen T, Kiviniitty K. The spin-lattice relaxation time in the blood of healthy subjects and patients with malignant blood disease. *Phys Med Biol* **1982**;27:937–947
6. Thulborn KR, Waterton JC, Matthews PM, Radda GK. Oxygenation dependence of the transverse relaxation time of water protons in whole blood at high field. *Biochim Biophys Acta* **1982**;714:265–270
7. Morariu VV, Pop VI, Popescu O, Benga G. Effects of temperature and pH on the water exchange through erythrocyte membranes: nuclear magnetic resonance studies. *J Membr Biol* **1981**;62:1–5
8. Ekstrand KE, Dixon RL, Raben M, Ferree CR. Proton NMR relaxation times in the peripheral blood of cancer patients. *Phys Med Biol* **1977**;22:925–931
9. Farrar TC, Becker ED. *Pulse and Fourier transformation NMR. Introduction to theory and methods*. New York: Academic, 1971
10. Brant-Zawadzki M, Badami JP, Mills CM, Norman D, Newton TH. Primary intracranial tumor imaging: a comparison of magnetic resonance and CT. *Radiology* **1984**;150:435–440
11. Norman D, Price D, Boyd D, Fishman R, Newton T. Quantitative aspects of computed tomography of the blood and cerebrospinal fluid. *Radiology* **1977**;123:335–338
12. Bergstrom M, Erickson K, Levander B, Svendsen P. Computed tomography of cranial subdural and epidural hematomas: variation of attenuation related to time and clinical events such as rebleeding. *J Comput Assist Tomogr* **1977**;1:449–455
13. Zimmerman RA, Bilaniuk LT. Computed tomographic staging of traumatic epidural bleeding. *Radiology* **1982**;144:809–812
14. Peterson OF, Espersen JO. How to distinguish between bleeding and coagulated extradural hematomas on the plain CT scanning. *Neuroradiology* **1984**;26:285–292
15. Fishman RA. *Cerebrospinal fluid in diseases of the nervous system*. Philadelphia: Saunders, **1980**:19–23, 168–251
16. Bradley WG, Schmidt PG. Effects of methemoglobin on MR appearance of subarachnoid hemorrhage. *Radiology* **1984**;153:166