

# MRI of Normal Brain Maturation

Betsy A. Holland<sup>1</sup>  
 David K. Haas  
 David Norman  
 Michael Brant-Zawadzki  
 T. Hans Newton

The unprecedented gray/white differentiation obtained with magnetic resonance imaging (MRI) has created a unique opportunity to trace the normal process of myelination. Fifty-nine children referred for evaluation of a nonneurologic problem or a nonspecific neurologic complaint were studied with MRI using spin-echo technique. Children ranged in age from term (40 weeks intrauterine) to 16 years. Scans were reviewed for quantitative and qualitative changes with age.

T1 and T2 relaxation times were measured for 13 regions of interest in 37 children. With increasing age a sharp decrease in both T1 and T2 values, most pronounced during the first year of life, was seen. The prolonged relaxation times in the newborn infant correspond to the known high water content of the neonatal brain; the subsequent decline corresponds to the decrease in water content and increase in myelination observed in autopsy studies of infants.

Qualitative changes in the MRI appearance of the brain with age using a spin-echo sequence (2 sec repetition time) demonstrated that the process of myelination was most rapid during the first 2–3 years of life. Myelination appeared to occur earliest in the posterior fossa, with the middle cerebellar peduncle identifiable at only 3 months. By the age of 1 year, all major white matter tracts including the corpus callosum, subcortical white matter, and the internal capsule were well defined. However, due to subtle changes in appearance, the refined configuration of the adult brain was not attained until early adolescence.

Development of the human brain is incomplete at birth [1–6]. This is reflected in the limited capabilities of the neonate, particularly when compared with the newborn infants of other species. In the perinatal period, myelination proceeds rapidly, following the order of phylogenetic development, occurring first in the peripheral nervous system, then the spinal cord, and lastly in the brain. Myelination in the brain occurs in different regions at different times. Although this process has been well studied in animals [7–9], the normal development of the human brain during the first decade of life has remained somewhat ambiguous. Inaccessible to study *in vivo*, the sequential changes in the appearance of the postnatal brain have been incompletely characterized on the basis of autopsy studies [3, 5]. The unique sensitivity of magnetic resonance imaging (MRI) to alterations in myelin content and in distinguishing between gray and white matter now provides the opportunity to trace the stages of brain maturation in children [9].

## Materials and Methods

Fifty-nine children (28 male, 31 female) aged from term (40 weeks intrauterine) to 16 years and 10 adults (five men, five women) aged 25–35 years were studied. Fifty-two children and all 10 adults were referred for a nonneurologic problem or a nonspecific neurologic complaint, such as headache or a single seizure; the other seven children had focal neurologic symptoms.

MR images were obtained with a 0.5-T superconducting magnet operating at 0.35-T (Diasonics MT/S) with a resonant frequency of 15 MHz and an imaging matrix of 128 × 256.

Received June 27, 1985; accepted after revision September 30, 1985.

<sup>1</sup> All authors: Department of Radiology, University of California, San Francisco, CA 94143. Address reprint requests to B. A. Holland, Department of Radiology, 1X55D, San Francisco General Hospital, 1001 Potrero Ave., San Francisco, CA 94110.

**AJNR 7:201–208, March/April 1986**  
 0195–6108/86/0702–0201  
 © American Society of Neuroradiology

TABLE 1: Relaxation Values of Gray and White Matter According to Age

Age (in years)	White Matter			Gray Matter		
	Mean Relaxation Time in msec (SD)		No. of ROIs*	Mean Relaxation Time in msec (SD)		No. of ROIs*
	T1	T2		T1	T2	
Birth	1615 (120)	91 (6)	22	1590 (60)	88 (8)	15
1/2	1150 (60)	64 (6)	24	1300 (70)	67 (7)	17
1	580 (50)	57 (5)	22	890 (75)	68 (3)	14
1 1/2	570 (40)	59 (5)	20	840 (90)	68 (6)	15
2	505 (55)	56 (4)	24	820 (25)	69 (4)	18
3	495 (55)	53 (5)	35	900 (90)	62 (7)	25
6-7	515 (48)	48 (3)	39	906 (95)	57 (5)	26
8-10	491 (50)	48 (4)	55	807 (61)	53 (6)	32
11-14	487 (39)	49 (4)	61	805 (82)	59 (4)	40

Note.—ROIs = regions of interest.  
\* Number of individual measurements performed.

A 25-cm head coil was used in all cases. A multislice spin-echo (SE) technique was employed with two SE samplings (28 and 56 msec) of each slice. Four signal acquisitions were averaged for each pulse sequence. Image slice thickness was 7 mm with a slice interval of 3 mm. Fifty-one children and 10 adults were imaged with repetition time (TR) of 2000 msec and eight children with a TR of 1500 msec. Forty-eight children and all adults were imaged with a second sequence with a TR of 500 msec. Fifty-three children and all adults were imaged in the axial plane and six children in the coronal plane.

Of the 48 children imaged with two sequences of different TR settings, T1 and T2 relaxation times were measured for 13 anatomic regions in 37 children. Eleven studies were excluded from measurement because of motion artifacts or registration errors between the imaging sequences. Five regions of gray matter were evaluated including frontal, occipital, and cerebellar gray matter and the head of the caudate and lentiform nuclei. Eight regions of white matter studied included subcortical frontal and occipital white matter, the centrum semiovale, anterior and posterior limbs of the internal capsule, the genu and splenium of the corpus callosum, and the middle cerebellar peduncle. The regions of interest (ROIs) were carefully chosen to minimize the effects of partial volume averaging. The number of pixels within each ROI was recorded, with a minimum of five pixels for each ROI.

For each region, the T1 and T2 relaxation times were calculated using the SE equation,  $I = k(N[H]) (1 - e^{-TR/T1}) e^{-TE/T2}$ , measured on the four images at that level (based on two TR sequences each with two echo times [TEs]). The relaxation time measurements of each of the five regions of gray matter and eight regions of white matter were pooled for each age group. The means and standard deviation were then calculated (table 1).

The scans of 56 children and 10 adults were evaluated for qualitative changes in the appearance of the maturing brain using SE 2000/28 and 2000/56. Particular attention was given to six anatomic regions including the corpus callosum, cortical gray and subcortical white matter, internal and external capsules, and cerebellar white matter at the level of the middle cerebellar peduncle.

**Results**

*Quantitative Changes*

At birth, the T1 and T2 relaxation times of both gray and white matter were markedly prolonged in comparison with those of the adult. In the first weeks of life, the T1 relaxation

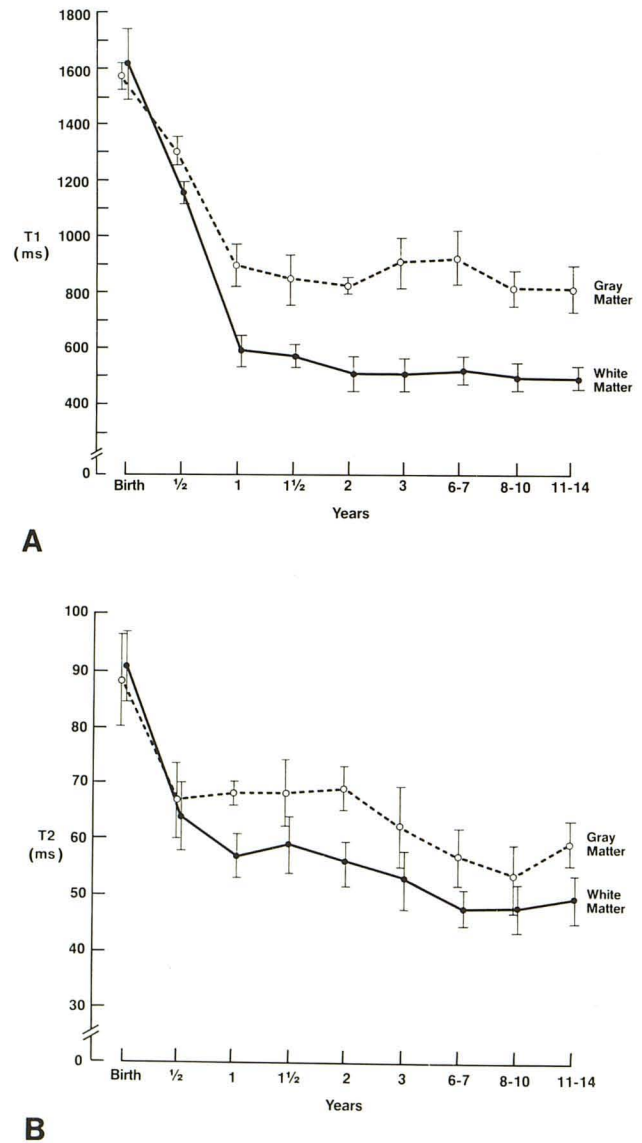


Fig. 1.—T1 (A) and T2 (B) relaxation values of gray and white matter by age.

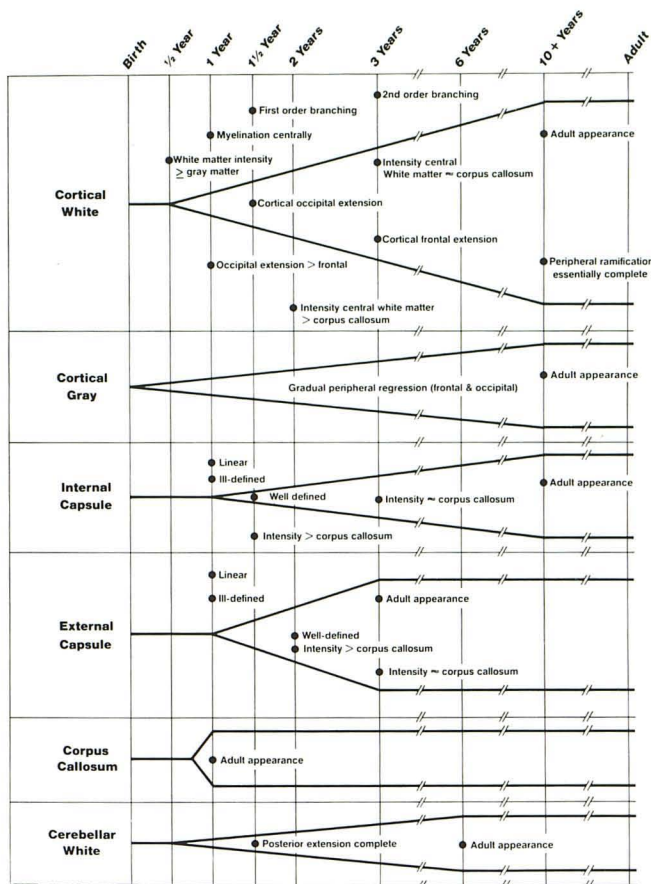


Fig. 2.—Cycles of myelination. For each anatomic region, gradual increase in width of graph indicates progressive maturation in appearance and signal intensity characteristics. For each age, dot along vertical line marks major development in appearance of maturing white matter.

times for gray and white matter were  $1580 \pm 43$  and  $1615 \pm 120$  msec, respectively; T2 relaxation values were  $88 \pm 8$  and  $91 \pm 6$  msec for gray and white matter (table 1). A rapid decrease in the calculated T1 and T2 values was seen during infancy (fig. 1). Nearly adult relaxation values for T1 were seen in gray matter at about 1.5 years ( $840 \pm 90$ ) and white matter at 2 years ( $505 \pm 55$ ). Adult T2 values occurred at 3 years in both gray ( $62 \pm 7$ ) and white ( $53 \pm 35$ ) matter. A small but not statistically significant decrease in the T2 values of both gray and white matter was seen from the age of 3 years through early adolescence.

Of the five regions of gray matter studied individually, the frontal and occipital cortical gray matter attained adult relaxation characteristics at 1.5–2 years, followed by the head of the caudate, the lentiform nucleus, and the cerebellar cortex at about 3 years. Among the white matter regions evaluated, the middle cerebellar peduncle assumed adult intensity values at 1 year; the genu and splenium of the corpus callosum and posterior limb of the internal capsule at 2 years; and the centrum semiovale, the anterior limb of the internal capsule, and the subcortical occipital white matter at 3 years. The relaxation times of the subcortical frontal white matter were similar to those of the adult at 5 years.

### Qualitative Changes

At birth, using a 2000 msec TR, a lack of gray/white differentiation rendered the brain almost featureless. However, during the first year of life, differentiation proceeded rapidly (figs. 2 and 3). White and gray matter could first be differentiated in the posterior fossa shortly after birth. By the age of 1 year, all major white matter tracts including the internal capsule, subcortical white matter, and corpus callosum were well defined. Although most structures were established by the end of the first year of life, the refined configuration and subtle intensity differences of the adult brain were not present until early adolescence.

On T2-weighted SE sequences, gray/white differentiation occurred early in the posterior fossa (fig. 2). The middle cerebellar peduncle, first identified at only 3 months, was well defined at 6 months (fig. 4B). It subsequently appeared to expand, extending farther posteriorly and laterally. The middle cerebellar peduncle assumed a fully adult appearance at 6 years (fig. 4D). The corpus callosum was first defined late in the first year; the genu and splenium appeared simultaneously (fig. 2). By 1 year, the infant corpus callosum had the adult configuration (fig. 3C).

On SE sequences, the subcortical white matter could be distinguished from adjacent cortical gray matter at about 4–6 months (fig. 3B). Initially, its intensity appeared slightly greater than that of gray matter, the inverse of the relative intensities seen in the adult. By 9 months to 1 year of age, their relative intensities reversed, with periventricular white matter now less intense than adjacent gray (fig 3C). Signal intensity of the subcortical white matter was, however, more intense than the corpus callosum. Between 1 and 3 years of age, the periventricular subcortical white matter tracts extended progressively farther toward the cortex and arborized into successively finer branches peripherally. The extension of the periventricular white matter toward the occipital pole was almost complete at age 1.5 years (fig. 3D), and toward the frontal pole, at age 3 (fig. 3E). Rudimentary branches of myelinated white matter ("first-order branching") were first observed extending from periventricular white matter tracts at 1.5–2 years (fig. 3D). By the age of 3 years, these branches had sprouted secondary branches more peripherally ("second-order branching") (fig. 3E). This branching became progressively finer in later years. The intensity of the subcortical white matter appeared similar to that of the corpus callosum, as in the adult, by the age of 3 years (fig. 3E). Because of further minor refinements, the cortical white matter did not assume a fully adult appearance until early adolescence (fig. 3F).

At 6 months of age, the cortical gray matter could first be differentiated from the adjacent white matter (fig. 3B). Although as discussed above the gray matter initially appeared to be of slightly lower signal intensity than white matter, by the age of 9 months gray matter was of slightly higher signal intensity than was white (fig. 3C). At the age of 1 year, the cortical gray matter formed a thick peripheral mantle, particularly at the level of the centrum semiovale (fig. 5B). However, because of the apparent gradual peripheral extension of the subcortical white matter, the cortical gray matter gave the

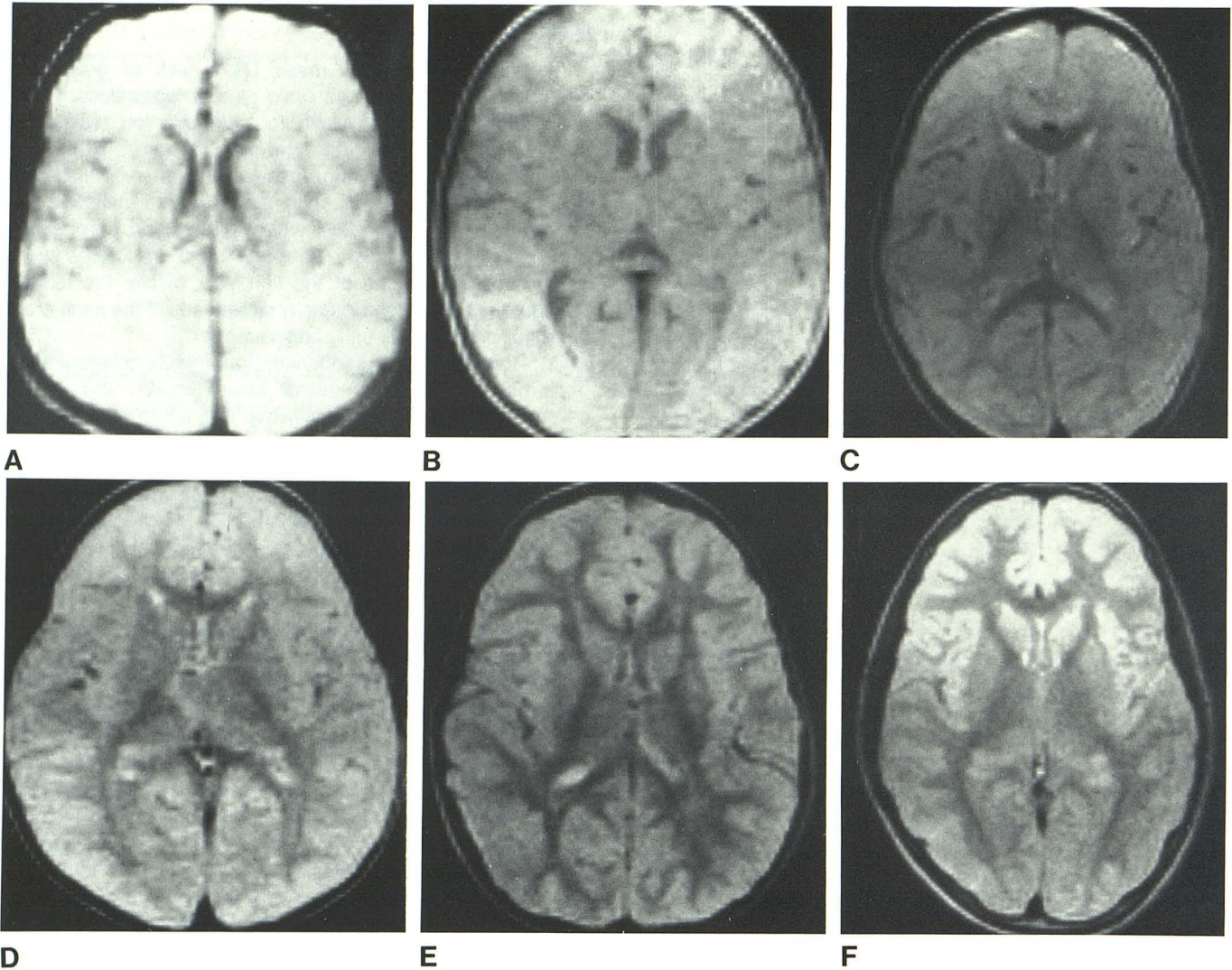


Fig. 3.—Normal SE images (2000 msec TR) with increasing age at ventricular level: 2 weeks (A), 6 months (B), 1 year (C), 2 years (D), 3 years (E), and 14 years (F).

impression of receding (fig. 5C). By early adolescence, when the white matter extension was complete, the cortical gray assumed an adult appearance, forming a much thinner mantle than in infancy (fig. 5D).

The internal capsule could be identified in its entirety by the age of 1 year (fig. 3C) and was well defined by 1.5 years on T2-weighted sequences. The posterior limb, however, appeared slightly earlier than did the anterior limb, at about 6–8 months. Subsequently, both limbs decreased in signal intensity and increased in relative size. The signal intensity diminished to that of the corpus callosum, as in the adult, at about 3 years (fig. 3E). Just as it was defined earlier than the anterior limb, the posterior limb sometimes assumed nearly adult signal characteristics slightly earlier, at 2 years (fig. 3D). The internal capsule gradually increased in relative size, assuming an adult configuration in early adolescence (fig. 3F).

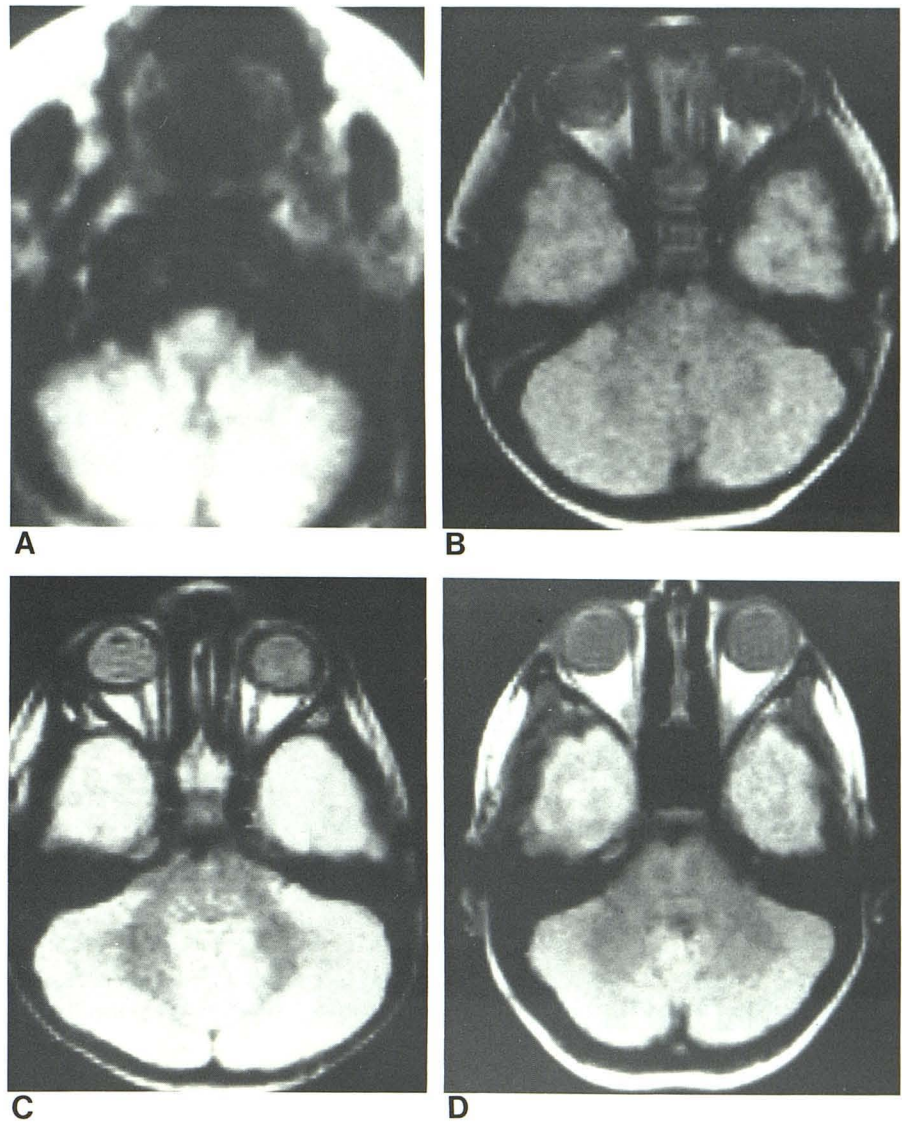
The external capsule could be differentiated from adjacent

gray matter at 1 year on SE (fig. 3C). Initially of higher signal intensity than the corpus callosum, it was linear and poorly defined. By the age of 2, the external capsule was well defined but of immature or high signal characteristics (fig. 3D). It assumed an adult appearance, with a signal intensity similar to that of the corpus callosum, 1 year later at the age of 3 years (fig. 3E).

#### Discussion

The chemical composition of the infant brain undergoes a rapid sequence of major changes, especially during the first year of life. One of the most pronounced alterations is a decrease in water content from 88% at birth to 82% at 6 months, resulting in a nearly 50% increase in dry weight of the brain (fig. 6) [1, 10]. During subsequent years, water content continues to decrease at a much slower rate. Lipid

Fig. 4.—Normal SE images (2000 msec TR) at level of middle cerebellar peduncle: 2 weeks (A), 6 months (B), 1½ years (C), and 6 years (D). (A is probably closest to middle cerebellar peduncles.)



and protein content increase because of progressive myelination [1, 11]. Myelin is about 30% protein and 40% water, and is relatively hydrophobic [6]. Eventually it constitutes one-half of the dry weight of white matter. The degree of myelination has been established experimentally by measuring the quantity of whole brain cholesterol [1]. Cholesterol levels rise rapidly initially, doubling within the first 6 months of life (fig. 7). A more gradual but steady rise continues through the age of 4–5 years.

On computed tomography (CT), gray/white differentiation stems from a difference in photoelectric absorption. In the adult, the higher water and lower lipid content of gray matter result in a greater x-ray attenuation and higher CT number than white matter [12]. At birth, this difference is accentuated because of the very high water and low protein content of neonatal white matter [11]. With advancing gestational age, the gray/white matter density difference decreases. Gray

matter shows no significant variation in x-ray attenuation with age, but white matter increases in attenuation during the first few months of life. This increase is attributed to the gradual decrease in water and increase in protein content associated with myelination. Correlative studies performed in the baboon have corroborated these findings; the increase in the white matter attenuation on CT directly parallels the increase in myelination on histologic examination [13].

On MRI, gray/white differentiation stems from a difference in mobile hydrogen density and associated T1 and T2 relaxation characteristics [14–16]. In the adult, the higher water, and less importantly, lower lipid, content of gray matter cause its relaxation times to be longer than those of white. The higher water content of gray matter results in its higher spin density. The higher spin density, in turn, results in its increased signal. Lipid content is of much less significance than water in determining gray/white differentiation on MR. In fact,

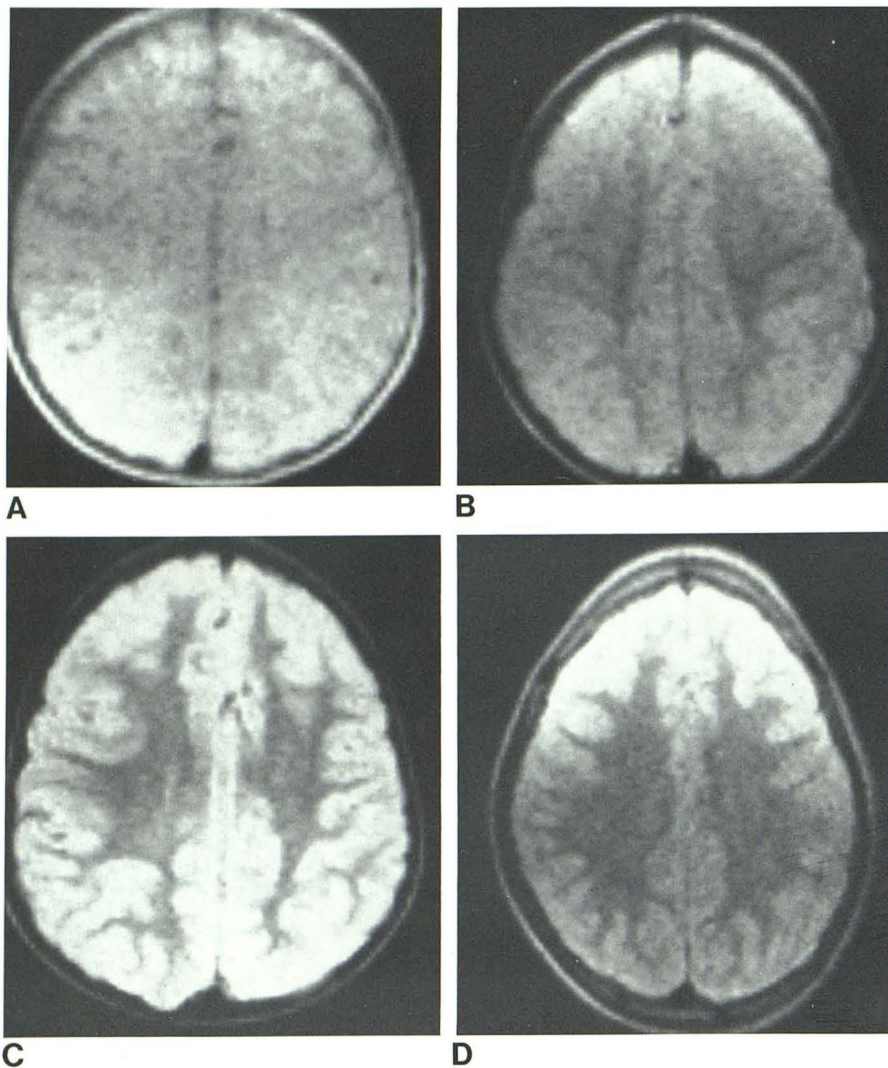


Fig. 5.—Normal SE images (2000 msec TR) at level of centrum semiovale: 2 weeks (A), 6 months (B), 3 years (C), and 14 years (D).

high-resolution spectra obtained from studies of proton spin relaxation and proton density in animals have demonstrated no lipid signal from brain [14–16]. The protons of myelin, tightly bound in fatty acid chains, do not contribute directly to gray/white discrimination. However, lipid concentration may indirectly affect contrast by changing the relaxation times of adjacent water protons.

At birth, no gray/white differentiation is seen on T2-weighted sequences because the relaxation times of both gray and white matter are markedly prolonged (table 1, fig. 3A), and in the absence of myelin, spin proton density is relatively equal. These prolonged values are presumably related to the high water content. In fact, almost like the intensity of cerebrospinal fluid, the mean T1 relaxation values of neonatal gray and white matter are somewhat long compared with our long TR of 1500–2000 msec; the mean T2 values are somewhat long compared with our TE times of 28 and 56 msec. As a result, the calculated intensity measurements

obtained from normal imaging sequences are probably inaccurate in the newborn infant [17].

During the first year of life, a rapid decline in these relaxation times is seen, followed by a more gradual decrease over the next few years (fig. 1). This decline in relaxation times with maturation parallels the decrease in water content observed in autopsy studies (fig. 6). Of interest is that during the initial phase of this rapid decline in brain relaxation values at about 4–6 months, supratentorial white matter transiently appears slightly more intense than gray on T2-weighted sequences (fig. 3B). This is the inverse of the relative intensities seen in the adult. The higher water content in the unmyelinated white matter compared with gray at this age may explain this reversal. By 1 year, periventricular white matter appears less intense than gray, as in the adult (fig. 3C). Presumably, the water content of the now partially myelinated supratentorial white matter is finally less than that of gray.

Anatomic studies corroborate many of the MR findings of

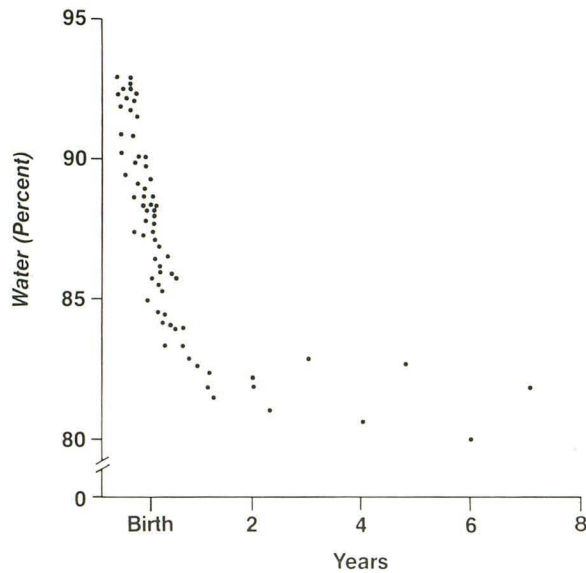


Fig. 6.—Percentage of water in whole brain according to age. (Adapted from [1].)

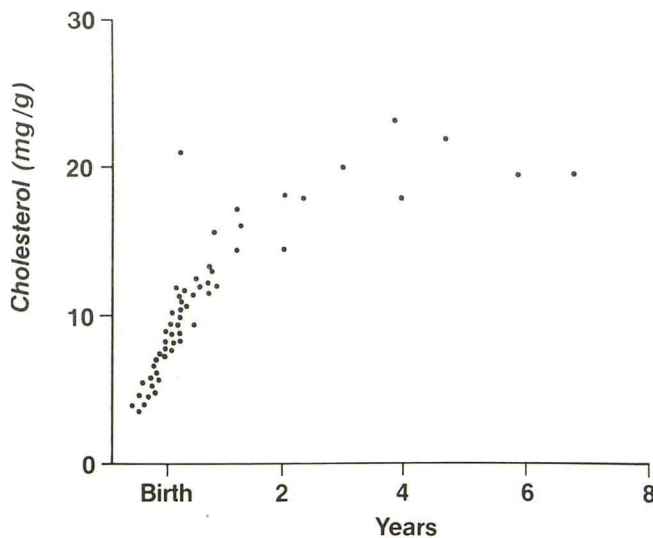


Fig. 7.—Concentration of cholesterol per unit weight in whole brain according to age. (Adapted from [1].)

brain maturation. Autopsy series have demonstrated that in the human the process of myelination is most rapid in the first 2 years of life, but remains incomplete well into the second decade, similar to our MR observations [1–6]. The degree of myelination has been estimated from the density and intensity of staining fibers. Unfortunately, these studies have been hampered by a paucity of pediatric brains. Overall, myelination occurs earliest in the posterior fossa. In the cerebellum, the inferior peduncle is fully myelinated first, at 3 months; the middle peduncle last, at 4 years. Similarly, by MR, myelination

appears to occur earliest in the cerebellum (fig. 4). The middle cerebellar peduncle is poorly defined but can be identified at only 3 months. The corpus callosum contains myelinated fibers shortly after birth. Histologically, myelination is first identified in the splenium in the fourth postnatal month, and shortly thereafter includes the genu and rostrum. However, myelination of commissural fibers in the corpus callosum continues even after the first decade. By MRI, the corpus callosum appears late in the first year and attains an adult appearance almost immediately (fig. 3C). This apparent early maturation of the corpus callosum by MRI is at variance with the more prolonged development indicated by these histologic studies. Presumably the later histologic refinements are beyond our limits of resolution.

Anatomic studies have demonstrated that myelination of the subcortical white matter proceeds from the corona radiata, extending first posteriorly toward the calcarine cortex during infancy and last toward the association areas of the frontal, parietal, and temporal convexity in the second decade. By MRI, myelination begins in the subcortical white matter somewhat later, at about 9 months (fig. 3C), but extends peripherally in a similar pattern and over a similar time course to the pathologic studies. Histologically, the first myelinated fibers in the internal capsule can be identified in the ninth fetal month. From the ninth fetal month to the fourth postnatal month, myelination proceeds primarily posteriorly; it occurs more slowly anteriorly. Again, by SE imaging, the internal capsule seems to myelinate several months later, being first identifiable in its entirety at about 9 months of age (fig. 3C). But in accordance with the anatomic literature, the posterior limb of the internal capsule is defined earlier than is the anterior limb.

In conclusion, using an SE sequence, MRI demonstrates sequential, reproducible changes in the maturing brain. These findings both confirm and elaborate on earlier anatomic studies. Awareness of the normal age-related appearance of the brain is a prerequisite to the evaluation of children with suspected abnormal or delayed myelination.

#### REFERENCES

1. Dobbing J, Sands J. Quantitative growth and development of human brain. *Arch Dis Child* 1973;48:757–767
2. Dobbing J. The later development of the brain and its vulnerability. In: Davis JA, Dobbing J, eds. *Scientific foundations of pediatrics*. London: William Heinemann, 1981:744–759
3. Yakolev PI, Lecours AR. The myelogenetic cycles of regional maturation in the brain. In: Minkowski A, ed. *Regional development of the brain in early life*. Oxford: Blackwell, 1967:3–69
4. Davison AN, Peters A. *Myelination*. Springfield, IL: Thomas, 1970:162–182
5. Lucas Keene MR, Hewer EE. Some observations on myelination in the human nervous system. *J Anat* 1931;6:1–13
6. Norton WT. Formation, structure and biochemistry of myelin. In: Siegel GJ, Albers R, Agranoff BW, Katzman R, eds. *Basic neurochemistry*. Boston: Little, Brown, 1981:63–93
7. Smorajaski T, Rosten C. Age and regional differences in the chemical composition of brains of mice, monkeys and humans. *Prog Brain Res* 1973;40:253–265
8. Benjamins JA, McKhann GM. Development, regeneration and

- aging of the brain. In: Siegel GJ, Albers RW, Agranoff BW, Katzman R, eds. *Basic neurochemistry*. Boston: Little, Brown, **1981**:445-469
9. Johnson MA, Pennock JM, Bydder GM, et al. Clinical NMR of the brain in children: normal and neurologic disease. *AJR* **1983**;141:1005-1018
  10. Penn RD, Trenko B, Baldwin L. Brain maturation followed by computed tomography. *J Comput Assist Tomogr* **1980**;4:614-616
  11. Brant-Zawadzki M, Enzmann DR. Using computed tomography of the brain to correlate low white-matter attenuation with early gestational age in neonates. *Radiology* **1981**;139:105-108
  12. Brooks RA, DiChiro G, Keller MR. Explanation of cerebral white-gray contrast in computed tomography. *J Comput Assist Tomogr* **1980**;4:489-491
  13. Quencer RM. Maturation of normal primate white matter: computed tomographic correlation. *AJNR* **1982**;3:365-372
  14. Bottomley PA, Hart HR Jr, Edelstein WA, et al. Anatomy and metabolism of the normal human brain studied by magnetic resonance at 1.5 tesla. *Radiology* **1984**;150:441-446
  15. Kamman RL, Go KG, Muskiet FAJ, Stomp GP, Van Dijk P, Berendsen HJC. Proton spin relaxation studies of fatty tissue and cerebral white matter. *Magnetic Resonance Imaging* **1984**;2:211-220
  16. Pykett IL, Rosen BR. Nuclear magnetic resonance: in vivo proton chemical shift imaging. *Radiology* **1983**;149:197-201
  17. Kjos BO, Ehman RL, Brant-Zawadzki M, Kelly WM, Norman D, Newton TH. Reproducibility of relaxation times and spin density calculated from routine MR imaging sequences: clinical study of the CNS. *AJNR* **1985**;6:271-276