

Ferromagnetism of Intraocular Foreign Body Causes Unilateral Blindness after MR Study

William M. Kelly,¹ Patrick G. Paglen,² Jack A. Pearson,³ Armando G. San Diego,⁴ and Murray A. Soloman⁵

The rapid ascent of magnetic resonance (MR) imaging as an important tool in neurodiagnosis has been fueled primarily by its unparalleled sensitivity for lesion detection, even when compared with its predecessor, computed tomography (CT). The absence of ionizing radiation is another attractive feature of MR that has provided additional momentum for its rapid development. However, only recently, and on the eve of widespread distribution of this new technology, has significant attention been focused on the potential biologic hazards of MR. Among the risks to which MR patients may be exposed are included ferromagnetic forces that may be exerted on certain internal metal objects. Most patients harboring various types of surgically implanted aneurysm and hemostatic clips as well as other types of metallic hardware can be readily identified by history. Exclusion of individuals with a history of cerebral aneurysm treated by aneurysm clips from consideration for MR eliminates the fearsome risk of a hemorrhagic event or other injury as a result of ferromagnetically induced motion of the metal clip. However, accurate recognition of the presence of small metallic foreign bodies such as an iron filing or shrapnel fragment, prior to consideration for MR, can be more problematic, even with preliminary CT, as we discovered. A former sheet metal worker with a clinically occult intraocular metal fragment experienced a vitreous hemorrhage with resulting blindness during an MR examination. According to the Food and Drug Administration, this case represents the first *reported* instance of a serious complication related to induced ferromagnetism. Attention to the occupational history and a high index of suspicion may help avert this type of calamity in other patients similar to ours. The demonstrated ability of MR to cause serious injury as a result of ferromagnetism has important implications for a much larger group of potential MR candidates with surgically implanted metallic devices.

Case Report

A 63-year-old man with recently diagnosed adenocarcinoma outside the central nervous system developed headaches and worsening

lethargy during the course of an inpatient evaluation. A contrast-enhanced CT scan of the brain revealed hyperdense lesions in the right temporal lobe and anterior left parietal lobe. Mild dilatation of the lateral and third ventricles was noted. In addition, a probable tectal lesion was seen adjacent to the aqueduct of Sylvius (fig. 1A). A small, rounded density adjacent to the posterior scleral margin of the left globe was initially thought to represent a postinflammatory calcification. (While serving in the Armed Forces during World War II, the patient had been taken prisoner by the Japanese Army at Bataan. He had survived the Bataan death march. While prisoner, he had been exposed to parasites. Examination by an ophthalmologist in 1972 revealed abnormalities of the left retina, including a glial band extending supratemporally from the disk margin and ending at an elevated pigmented mass. This was believed to be secondary to an old parasitic [*Toxocara*] granuloma. A cataract extraction with implantation of a polymethylmethacrylate lens implant was performed on the left eye in 1982.)

After consultation with oncology and radiation therapy departments and before initiation of whole-brain radiation, it was decided to perform a head MR study to confirm the suspected midbrain lesion (and thereby corroborate the diagnosis of obstructive hydrocephalus) and more accurately establish the extent of metastatic involvement. The patient denied knowledge of any metal implants.

The patient underwent an MR examination in a Diasonics 0.35 T system. Three multislice spin-echo pulse sequences were performed. Transaxial images were obtained using 500 and 2000 msec repetition times (TRs) and 28 and 56 msec echo times (TEs); sagittal images were obtained using 500 msec TRs and 28 and 56 msec TEs. At the completion of all data acquisition and at the moment the patient table was being pulled out of the magnet bore, the patient described a sudden tugging sensation at the left eye, a flash of light, then a dramatic decrease in vision. Examination revealed a gross vitreous hemorrhage on the left. MR showed extensive ferromagnetic artifact obscuring the left orbit (fig. 1B). A repeat CT study with thin orbital sections (1.5 mm) displayed at bone window settings showed a 2–3 mm metallic density adjacent to the left disk margin (fig. 1C).

Subsequent review of the patient's work history disclosed employment as a sheet metal worker and lathe operator after military service. He admitted to working habitually without protective eyewear and on several occasions felt iron filings strike his face, but denied any specific recollection of an eye injury or consultation with a physician for such. It was concluded that in the remote past the patient had

Received March 28, 1985; accepted after revision October 8, 1985.

¹Department of Radiology, David Grant USAF Medical Center, Travis AFB, CA 94535. Address reprint requests to W. M. Kelly.

²Department of Ophthalmology, David Grant USAF Medical Center, Travis AFB, CA 94535.

³Department of Internal Medicine, David Grant USAF Medical Center, Travis AFB, CA 94535.

⁴Department of Pathology, David Grant USAF Medical Center, Travis AFB, CA 94535.

⁵San Jose Magnetic Resonance Imaging Center, San Jose, CA xxxxx.

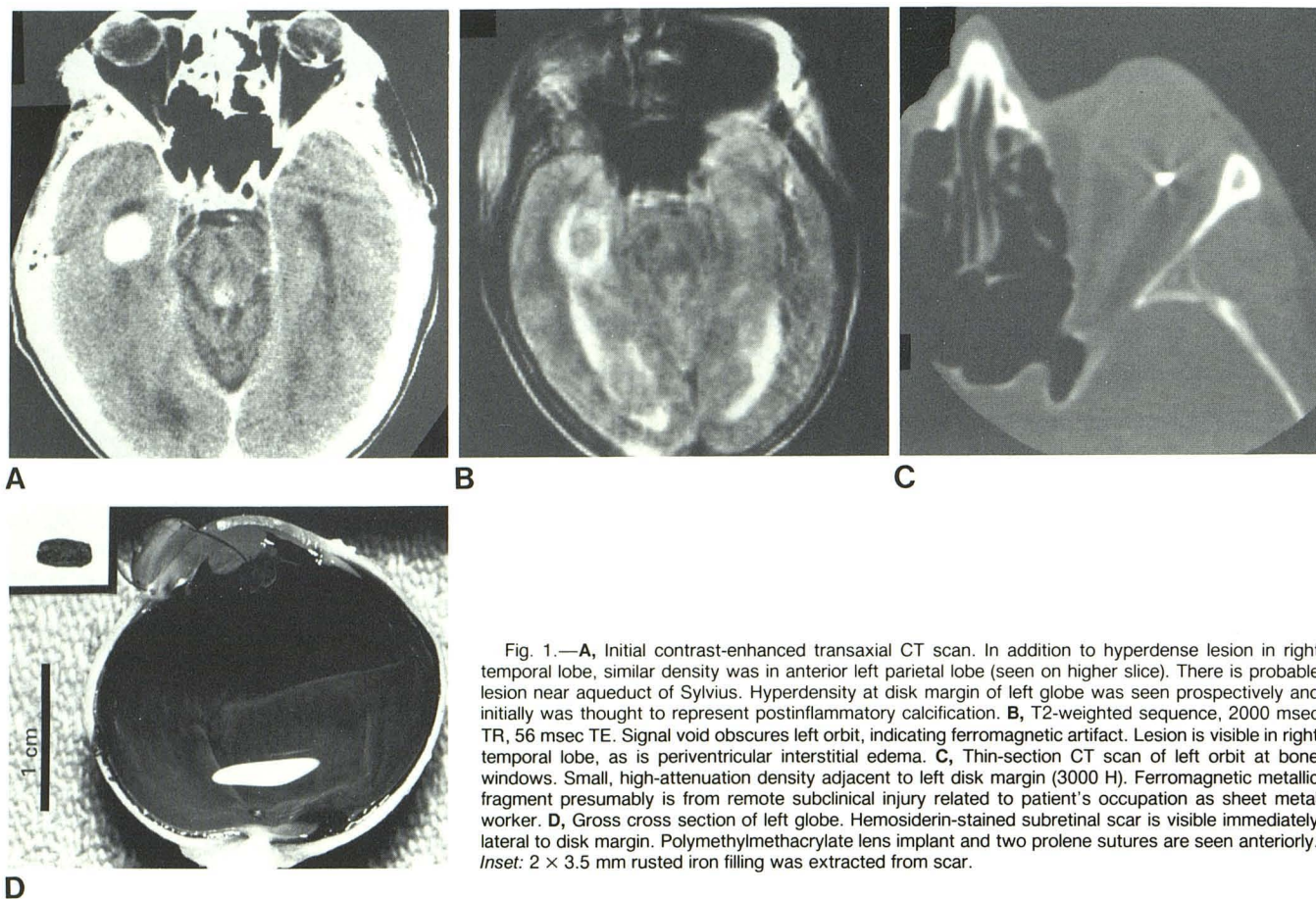


Fig. 1.—**A**, Initial contrast-enhanced transaxial CT scan. In addition to hyperdense lesion in right temporal lobe, similar density was in anterior left parietal lobe (seen on higher slice). There is probable lesion near aqueduct of Sylvius. Hyperdensity at disk margin of left globe was seen prospectively and initially was thought to represent postinflammatory calcification. **B**, T2-weighted sequence, 2000 msec TR, 56 msec TE. Signal void obscures left orbit, indicating ferromagnetic artifact. Lesion is visible in right temporal lobe, as is periventricular interstitial edema. **C**, Thin-section CT scan of left orbit at bone windows. Small, high-attenuation density adjacent to left disk margin (3000 H). Ferromagnetic metallic fragment presumably is from remote subclinical injury related to patient's occupation as sheet metal worker. **D**, Gross cross section of left globe. Hemosiderin-stained subretinal scar is visible immediately lateral to disk margin. Polymethylmethacrylate lens implant and two prolene sutures are seen anteriorly. *Inset*: 2 × 3.5 mm rusted iron filling was extracted from scar.

experienced a subclinical penetrating injury to his left globe from a flying fragment.

The patient died 4 weeks later from complications related to his metastatic disease. At autopsy, the enucleated left eyeball was transected across its equator. Evidence of a subacute hemorrhage was present within the vitreous. A hemosiderin-stained scar was also noted adjacent to the disk margin. The 2 × 3.5 mm rusted iron fragment shown in figure 1D was extracted from the subretinal tissue.

Discussion

Included among the potentially adverse biologic effects of MR imaging are interactions of tissues with the three types of magnetic fields required for proton alignment, localization, and perturbation: (1) the static main magnetic field; (2) rapidly changing gradient fields; and (3) radiofrequency (RF) pulses. Budinger [1] has summarized the potential harmful influence of these magnetic fields on biochemical processes, cellular function, and organism behavior, concluding that no reproducible adverse effects on humans are demonstrable at static fields of less than 2 T [1]. He further stated that for time-varying magnetic fields (gradient and RF fields), power depositions of 1.5 W/kg for long-duration studies and 4 W/kg for short-duration studies (less than 10 min) are acceptable thresholds.

A separate category of hazard arises from the potential for interaction between the magnetic fields and various forms of metal that may be contained within the patient. These include prostheses, clips, and foreign bodies. Larger metallic implants such as hip prostheses may cause a surrounding temperature elevation due to local heating effects. This phenomenon can be due either to the induction of electromotive forces in a conductive metal exposed to time-varying magnetic fields (Faraday law) or to possible arcing effects if the metal is positioned close to another conductor and sufficient voltage is generated [2]. Appropriate concern has also been raised regarding the potential for malfunction of cardiac pacemakers [3]. Pavlicek and Meaney [4] have also recommended that persons with artificial heart valves be excluded from both MR imaging as well as the magnetic area as a routine safety precaution. However, Soulen et al. [5] recently reported experimental data suggesting that individuals with present-day prosthetic heart valves can be imaged safely at field strengths currently in use.

Perhaps of greatest significance and central to the topic of this report is the potential for magnetically induced motion of metallic implants or particles subjected to the magnetic fields currently in use. Torquing or deflection movements of any metallic particle or implant is clearly an unwelcome event, as complications potentially more catastrophic than blindness

(such as subarachnoid hemorrhage) might theoretically occur.

The deleterious effects that may result from induced ferromagnetism of surgical implants are perhaps of greatest concern with respect to aneurysm clips. New and coworkers [6] have examined the ferromagnetic properties of 26 aneurysm and hemostatic clips constructed of various metal alloys. Longitudinal forces proportional to magnetic field gradients and torque forces proportional to main magnetic field strengths were measurable in 19. Eight of the aneurysm clips were judged to demonstrate sufficient longitudinal or torque forces to produce a risk of hemorrhage from clip dislodgment or cerebral injury from clip displacement without dislodgment. Clips that did not exhibit ferromagnetism included those constructed of silver, titanium, tantalum, or stainless steel alloys containing 10%–14% nickel. Thus, if it were possible to identify positively the type of clip used, the mere history of aneurysm surgery might not necessarily preclude the use of MR. However, additional uncertainty stems from the observation that some clips acquire ferromagnetism only after being tooled or deformed (as may occur during surgical positioning) [6]. Furthermore, given the confusing variety of clips in common usage now and previously, subjecting any such patient to MR might be regarded as unduly risk-laden. In the future, the more uniform production of nonferromagnetic aneurysm clips by manufacturers may alleviate this problem.

Compared with aneurysm clips, other types of metallic surgical implants (such as shunt tube connectors, dental appliances, and metal plates) are of less concern with respect to torquing effects and associated hazards. These devices are seldom close to vital neurovascular structures and are usually indirectly tethered to rigid (bony) surfaces exterior to the brain surface. However, even minute metal fragments, if markedly ferromagnetic, such as the metal filing shown in our patient, may generate large zones of artifact due to distortion of the local magnetic field. Production of this type of artifact has also been observed in relation to metal devices without measurable ferromagnetism [6]. In either case, the resulting artifact can cause an annoying obscuration of normal anatomy or pathology. Depending on the location of the metal, orientation of the slices, and number of images obtained, the potential exists for misinterpretation of ferromagnetic artifact as a false-positive finding.

At most centers, including ours, it is routine practice to screen carefully patients scheduled for MR before they enter

the magnet area. Strict contraindications, such as the presence of an aneurysm clip or cardiac pacemaker, can be identified in most cases merely by questioning the patient. When in doubt, the presence of a craniotomy site and/or appropriate history should arouse sufficient suspicion to cancel or at least postpone the examination until more information can be obtained. We believe that our experience with this patient warrants routine careful review of the occupational histories of individuals referred for MR. Specific attention should be given to prior employment as a lathe operator, sheet metal worker, or similar occupation. In selected cases, a single lateral radiograph of the skull may be justified as a direct and relatively inexpensive means of identifying patients who are not suitable candidates for MR, owing to the presence of an otherwise occult metal fragment in a potentially hazardous location. Alternatively, if a preliminary CT scan is obtained, we emphasize the importance of reviewing such images at bone windows, supplemented with region-of-interest measurements, if needed, to help differentiate a dense focal calcification from a small piece of metal. The presence of even minute rays of streak artifact on CT, sometimes difficult to recognize on images displayed at soft-tissue windows, may also be a helpful clue in the search for an occult metal fragment.

REFERENCES

1. Budinger TF. Nuclear magnetic resonance (NMR) *in vivo* studies: known thresholds for health effects. *J Comput Assist Tomogr* **1981**;5:800–811
2. David PL, Crooks L, Arakaw M, McRee R, Kaufman L, Margulis AR. Potential hazards in NMR imaging: heating effects of changing magnetic fields and RF fields on small metallic implants. *AJR* **1981**;137:857–860
3. Pavlicek MS, Geisinger M, Castle L, et al. The effects of nuclear magnetic resonance on patients with cardiac pacemakers. *Radiology* **1983**;147:149–153
4. Pavlicek W, Meaney TF. The special environmental needs of magnetic resonance. *Appl Radiol* **1984**;March/April:23–33
5. Soulen RL, Budinger TF, Higgins CB. Magnetic resonance imaging of prosthetic heart valves. *Radiology* **1985**;154:705–707
6. New PFJ, Rosen BR, Brady TJ, et al. Potential hazards and artifacts of ferromagnetic and nonferromagnetic surgical and dental materials and devices in nuclear magnetic resonance imaging. *Radiology* **1983**;147:139–148