
Subacute Combined Degeneration of the Spinal Cord: MR Findings

Steve R. Timms,¹ Joel K. Curé,² and Jerome E. Kurent¹

Summary: The authors present the initial and follow-up MR findings in a patient with subacute combined degeneration of the spinal cord, a complication of vitamin B12 deficiency, and a rare cause of demyelination of the dorsal and lateral columns of the spinal cord. Initial study showed high intensity in the dorsal columns of the cervical and thoracic spinal cord on T2-weighted image. Five months after treatment, the abnormal signal intensity was noted to have decreased.

Index terms: Degenerative spinal cord disease; Spinal cord, magnetic resonance

Subacute combined degeneration (SCD) of the spinal cord is a neurologic complication of vitamin B12 deficiency. There is degeneration of myelin and axonal loss in the posterior and lateral columns of the spinal cord, typically beginning in the thoracic region and subsequently ascending or descending. Afflicted patients' presentation is dominated by dorsal column dysfunction, typically manifested as sensory ataxia.

The purpose of this report is to present the spinal magnetic resonance (MR) findings in a patient with SCD of the spinal cord. Improvement of MR-documented signal abnormalities in the posterior columns correlated with improvement in clinical status during vitamin B12 therapy.

Case Report

A 69-year-old man underwent prostatectomy for adenocarcinoma. Nitrous oxide was administered during general anesthesia. A metastatic evaluation was negative. Two weeks after the operation, he experienced the gradual onset of

unsteady gait, burning dysesthesias of his hands and feet, and subjective weakness.

The initial laboratory investigation demonstrated mild anemia. A computed tomographic (CT) scan of the brain with and without contrast was normal. A cervical spine MR examination demonstrated a diffuse C5-C6 disk bulge without cord compression but was otherwise negative. The patient's limb and gait ataxia progressed so that he was no longer able to walk or feed himself. He was admitted to our institution approximately 3 months after the onset of his symptoms.

A neurologic examination demonstrated profound sensory deficits in his extremities. There was total loss of vibratory sense and severely impaired proprioception, in the lower extremities to the level of the iliac crests and in the upper extremities to the shoulder level. There was mildly decreased strength in the upper and lower extremities. Upper extremity deep tendon reflexes were 1+ and symmetric (normal), patellar reflexes were 3+ and symmetric (increased), and ankle jerks were 1+ and symmetric (normal). There were bilateral extensor plantar responses. Laboratory studies demonstrated a decreased hemoglobin level and hematocrit (12.4 g/dL and 37.4%, respectively), hypersegmented neutrophils, elevated mean corpuscular volume (99 fL), elevated serum folate (18 ng/mL), and low serum B12 (<100 pg/mL). The rapid plasma reagent was negative. A cerebrospinal fluid analysis, including an assay for oligoclonal bands, was normal. An electromyogram demonstrated generalized peripheral axonal neuropathy. A Schilling test was consistent with pernicious anemia.

An MR examination of the brain revealed non-specific high-signal foci within the cerebral hem-

Received June 4, 1992; revision requested July 27, received September 16, and accepted September 30.

Departments of ¹Neurology and ²Radiology, Neuroradiology Section, Medical University of South Carolina, 171 Ashley Avenue, Charleston, SC 29425. Address correspondence to J. K. Curé.

AJNR 14:1224-1227, Sep/Oct 1993 0195-6108/93/1405-1224 © American Society of Neuroradiology

ispheric white matter on T2-weighted images but was otherwise unremarkable. An MR examination of the cervical and thoracic spinal cord demon-

strated increased signal intensity within the dorsal columns on T2-weighted images. The lateral columns were not involved (Fig. 1a and d). SCD of

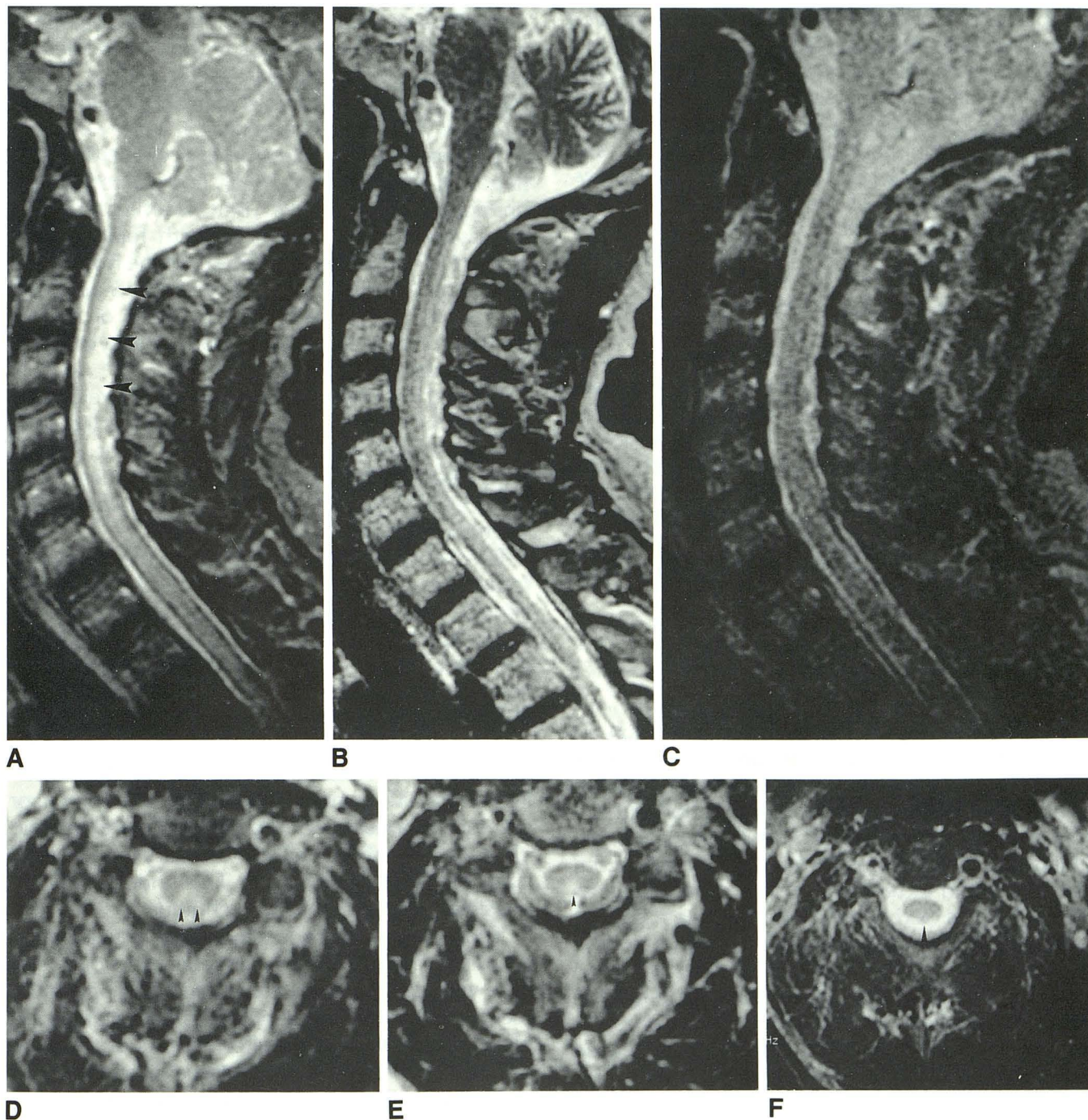


Fig. 1. *A* and *D*, Midline sagittal (1875/90/1 [TR/TE/excitations]) and axial (2000/90) T2-weighted spin-echo images of the cervical spinal cord demonstrate abnormal increased signal intensity in the posterior columns (*arrowheads*).

B and *E*, Follow-up midline sagittal (2432/102, echo train length = 8) and axial (3400/108) T2-weighted fast spin-echo images of the cervical spinal cord demonstrate less pronounced abnormal signal intensity in the posterior columns after 5 months of vitamin B12 therapy (*E*, *arrowhead*).

C and *F*, At 10 months' follow-up, there is a further decrease in the conspicuity of the signal abnormalities in the dorsal columns on conventional T2-weighted sagittal (2000/90) and axial (2812/90) images (*F*, *arrowhead*).

the spinal cord was diagnosed clinically and supported by the findings of the MR study.

The patient was started on intramuscular vitamin B12 therapy. Three months after hospital discharge, he demonstrated mildly improved though persistently unsteady gait. He was now able to feed himself, although with difficulty. The burning dyesthesias persisted, though decreased in severity. A follow-up neurologic examination showed ongoing profound sensory deficit and persistent extensor plantar responses. A follow-up MR examination of the cervical and thoracic spinal cord, performed 5 months after the patient's discharge on vitamin B12 therapy, demonstrated a reduction in the severity of T2 signal abnormality in the dorsal columns of the spinal cord (Fig. 1b and e).

At 10 months' follow-up, the patient demonstrated continued clinical improvement. He manifested less gait ataxia and spasticity than was previously noted. However, he retained severe impairment of vibratory sense and proprioception of the lower extremities. An MR examination of the cervical spine at that time revealed further improvement in the signal abnormalities involving the dorsal columns of the cervical spinal cord (Fig. 1c and f).

Discussion

SCD of the spinal cord, a complication of vitamin B12 deficiency, is an uncommon cause of myelopathy today. Neuropathologic findings include degeneration of myelin sheaths and axonal loss in the posterior and lateral columns, which typically commences in the thoracic cord but which can extend to involve other levels as well. Patients experience paresthesias of the hands and feet, loss of posterior column function, and sensory ataxia. There may be spasticity and weakness of the lower extremities. Although the upper extremities may also be involved, the legs are typically more severely affected. Increased deep tendon reflexes and extensor plantar responses reflect involvement of the corticospinal tracts. However, reflexes may be depressed when polyradiculopathy occurs (1).

Vitamin B12 deficiency may result from insufficient ingestion or from impaired intestinal absorption of vitamin B12 (2). Pernicious anemia, the most frequent cause of vitamin B12 deficiency in the United States, is caused by vitamin B12 malabsorption resulting from the inactivation

of intrinsic factor. Antibodies to parietal cells are seen in 80% to 90% of patients with pernicious anemia, and serum intrinsic factor-blocking antibodies are present in 70% (3). The diagnosis of pernicious anemia can be confirmed with a Schilling test and with an assay for antibodies to parietal cells and intrinsic factor. Other serum markers include elevated levels of methylmalonic acid and homocysteine (4).

The specific mechanisms that cause demyelination of the spinal cord in SCD are incompletely understood. It is known that vitamin B12 is a coenzyme, which, in concert with folate, is important in the formation of methionine from homocysteine. Methionine is converted to S-adenosyl methionine, which serves as a donor of methyl groups for reactions that include methylation of myelin basic proteins (5, 6).

Clinical improvement in a patient's myelopathy may occur if vitamin B12 therapy is started early in the course of the disease (7). Our patient demonstrated mild improvement in clinical function, which correlated with MR findings after vitamin B12 therapy.

It is interesting to note that the patient's symptoms began after nitrous oxide had been administered during surgery. Nitrous oxide enhances the oxidation of vitamin B12, thereby rendering it ineffective. In a patient with borderline B12 levels in serum, such therapy can precipitate the complications of B12 deficiency (5).

It is also important to note that, despite the presence of corticospinal tract dysfunction manifested by diffuse hyperreflexia, bilateral extensor plantar responses, and spasticity, there was no clearly identifiable signal abnormality in the lateral columns on the MR images. This underscores the possible limitations of the technique.

There are numerous causes of myelopathy. Acquired causes include degenerative disk disease with cord compression, infectious or postinfectious myelitis (including tabes dorsalis), multiple sclerosis, vascular malformations of the dura and spinal cord, connective tissue diseases (rheumatoid arthritis, systemic lupus erythematosus, and Sjogren syndrome), sarcoidosis, paraneoplastic syndromes, exposure to a variety of toxins, radiation or electrical injury, or barotrauma (2). Although the MR findings in these diseases are nonspecific, the finding of increased signal intensity within the dorsal columns in a patient with pernicious anemia should suggest SCD. This case demonstrates that MR can be used in conjunction

with neurologic findings to assess the response of patients to vitamin B12 therapy.

References

1. Mancall EL. Subacute combined degeneration of the spinal cord. In: Rowland LP, ed. *Merritt's textbook of neurology*. 8th ed. Philadelphia: Lea and Febiger, 1989:691-694
2. Berger JR, Levy RM, Snodgrass S. Medical myelopathies. In: Rothman RH, Simeone FA, eds. *The spine*. 3rd ed. Philadelphia: WB Saunders, 1992:1553-1569
3. Clementz GL, Schade SG. The spectrum of vitamin B12 deficiency. *Am Fam Physician* 1990;41:150-162
4. Babior BM, Bunn HF. Megaloblastic anemia. In: Braunwald E, Isselbacher KJ, Petersdorf RG, Wilson JD, Martin JB, Favci AS eds. *Harrison's principles of internal medicine*. 11th ed. New York: McGraw Hill, 1987:1498-1504
5. Holloway KL, Alberico AM. Postoperative myeloneuropathy: a preventable complication in patients with B12 deficiency. *J Neurosurg* 1990;72:732-736
6. Chanarin I, Deacon R, Lumb M, Muir M, Perry J. Cobalamin-folate interactions: a critical review. *Blood* 1985;66:479-489
7. Healton EB, Savage DG, Brust JCM, Garrett TJ, Lindenbaum J. Neurologic aspects of cobalamin deficiency. *Medicine* 1991;70:229-244