

Contents of Lumbar Costotransverse Foramina

In their article in the September/October 1984 issue of *AJNR*, Beers et al. [1] posed the question of whether the lumbar costotransverse foramina contained vascular structures or neural tissue. We have studied similar lumbar costotransverse foramina in cadavers using computed tomography (CT) and cryomicrotomy. The CT appearance of these vascular structures depends on the level and thickness of the cut. Anatomic sections obtained with a cryomicrotome revealed the foramina as channels 2–3 mm in diameter, with distinct but not always corticated margins running in an erratic course through the neural arch. They contained veins but no neural tissue (fig. 1).

Our correlative studies suggest that the costotransverse foramina,

at least those under 3 mm in diameter, contain only vascular structures. These foramina are frequent and often bilateral, although usually more prominent on one side.

Victor M. Haughton
Peter Pech

*Froedtert Memorial Lutheran Hospital
Medical College of Wisconsin
Milwaukee, WI 53226*

REFERENCE

1. Beers GJ, Carter AP, McNary WF. Vertical foramina in the lumbosacral region: CT appearance. *AJNR* 1984;5:617–619, *AJR* 1984;143:1027–1029

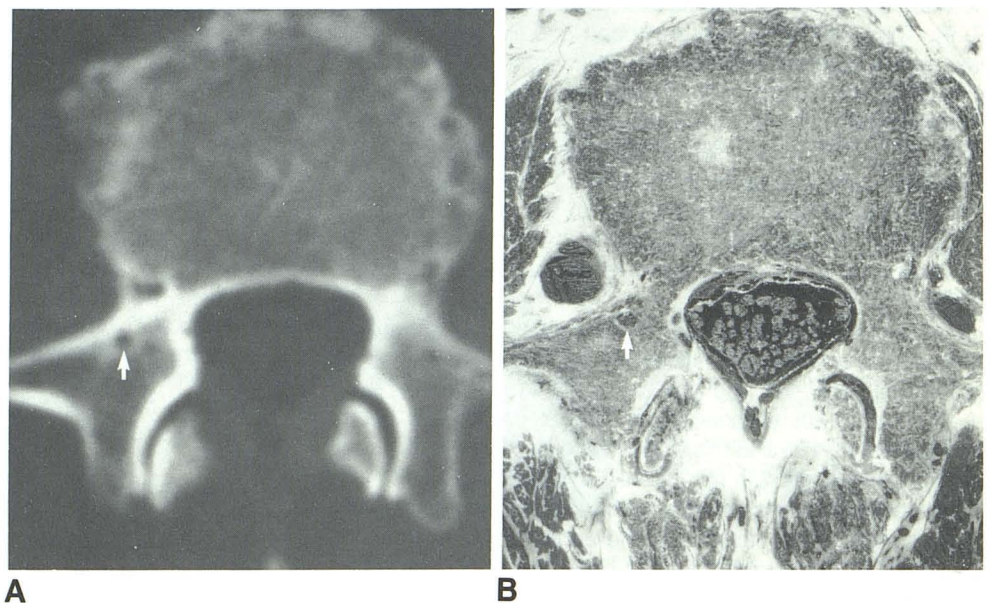


Fig. 1.—CT scan (A) and precisely corresponding anatomic section (B) through a costotransverse foramen in L3 vertebra. Corticated margins of foramen are seen on CT (A, arrow); foramen contained a vein (B, arrow) that communicated with the epidural plexus.