

Superselective Embolization for Severe Traumatic Epistaxis Caused by Fracture of the Skull Base

Akira Kurata,¹ Takao Kitahara,² Yoshio Miyasaka,¹ Takashi Ohwada,² Kenzoh Yada,¹ and Shinichi Kan³

Summary: Intractable epistaxis developed in a 13-year-old girl after she fell down a flight of stairs sustaining facial fractures and fracture of the skull base. Epistaxis was found to emanate from a right ascending pharyngeal artery, which the authors promptly and successfully embolized using polyvinyl alcohol particles and microfibrillar collagen.

Index terms: Skull, fractures; Epistaxis; Skull, trauma; Embolism, therapeutic blockade

We describe a patient with intractable epistaxis due to skull base fracture who was treated with superselective embolization. The bleeding vessel—the ascending pharyngeal artery—was successfully embolized near the bleeding point. The purpose of this paper is to describe the importance of superselective embolization in patients whose blood pressure continues to fall because of intractable posterior epistaxis despite the administration of continuous blood transfusion.

With the advent of digital subtraction angiography (DSA) and the road mapping function, and of highly flexible microcatheters (1, 2), it is possible to perform superselective angiography and embolization quickly and safely. With these tools, percutaneous embolization may be performed more frequently to save the lives of patients with intractable epistaxis caused by skull base fracture as well as other causes.

Case Report

A 13-year-old girl was brought to Kitasato University Hospital 30 minutes after falling down a flight of steps and sustaining bilateral contusions of the forehead and orbits. On admission, physical examination revealed massive bilateral nasal bleeding. Computed tomography demonstrated a fracture of the posterior wall of the left maxillary sinus (Fig. 1), a fracture of the greater wing of the left sphenoid bone, and blood in the left ethmoid, sphenoid,

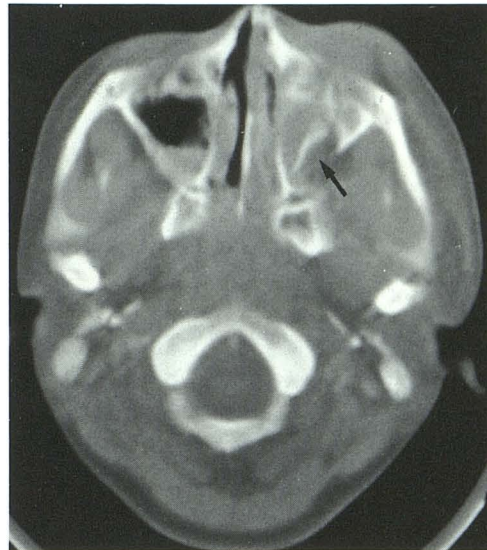

Fig. 1. X-ray computed tomography scan. Fracture of the posterior wall of the left maxillary sinus (arrow) is clearly demonstrated.

and maxillary sinuses. No brain contusion or other abnormal intracranial findings were recognized. Anterior and posterior nasal packing was applied but failed to stem the nasal bleeding.

Thirteen hours after injury the epistaxis worsened, and the decision was made to perform angiography and embolization. Blood pressure and hematocrit, which on admission had been 140/80 and 43%, respectively, had fallen to 100/50 and 29% by the time of catheterization despite continuous blood transfusions.

The first angiographic films were of the left internal and external carotid arteries because the clinical and radiologic findings strongly suggested that the bleeding was from the left side. However, no extravasation of contrast medium was observed. DSA of the right external carotid artery was then performed without delay; it clearly demonstrated extravasation of contrast medium into the posterior nasal cavity, but failed to define the bleeding vessel (Figs. 2A

Received November 14, 1991; revision requested February 10, 1992; revision received March 3 and accepted July 3.

¹ Department of Neurosurgery, Kitasato University School of Medicine, 1-15-1 Kitasato, Sagamihara, Kanagawa, Japan. Address reprint requests to A. Kurata.

² Department of Critical Care Medicine, Kitasato University School of Medicine, Sagamihara Kanagawa, Japan.

³ Department of Radiology, Kitasato University School of Medicine, Sagamihara Kanagawa, Japan.

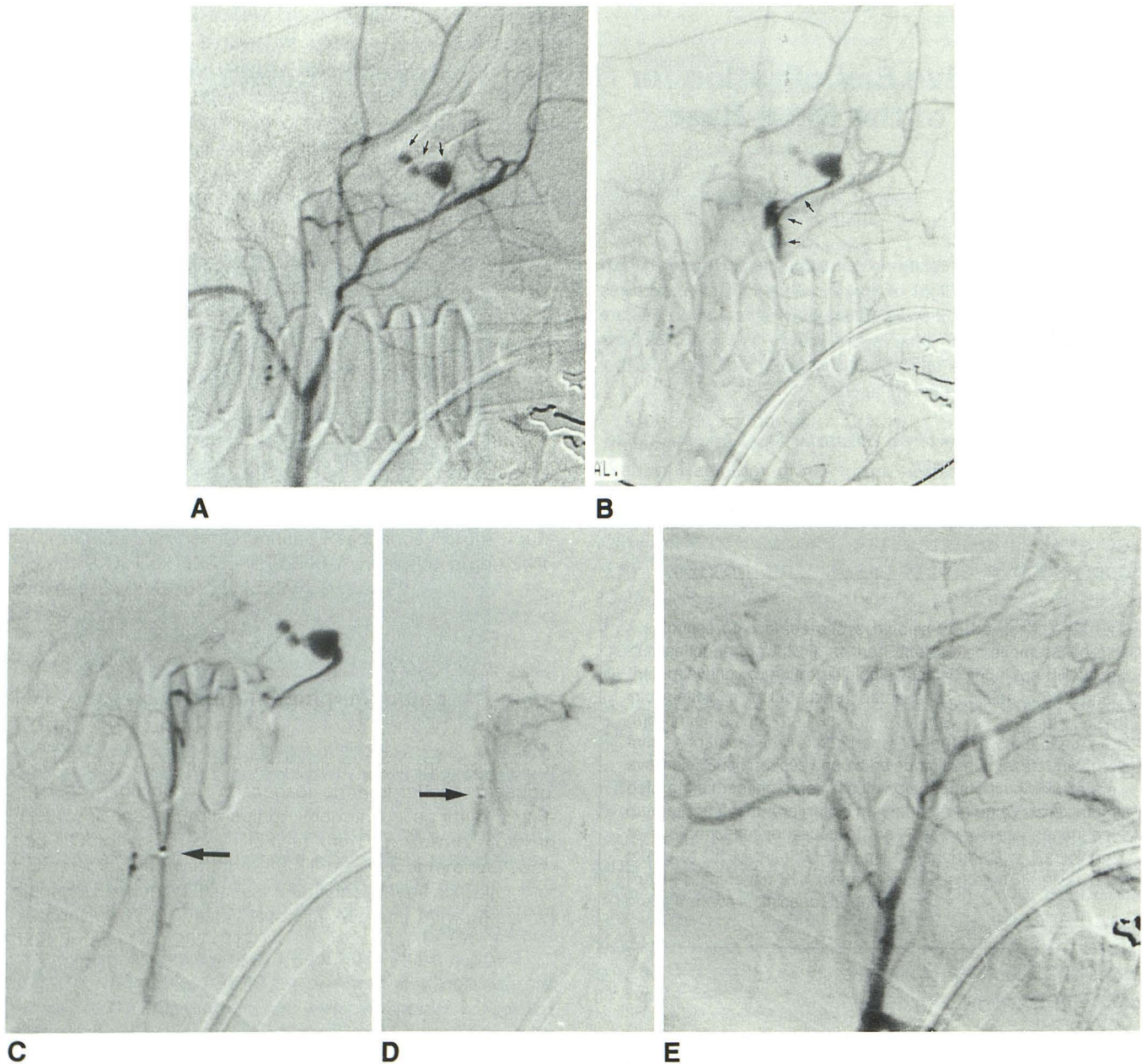


Fig. 2. *A* and *B*, Selective right external carotid arteriograms in early (*A*) and late (*B*) phases. Extravasation of contrast medium is demonstrated (*arrows*).

C, Superselective right ascending pharyngeal arteriogram. Catheter tip is visualized (*arrow*) as is contrast extravasation.

D, Superselective superior pharyngeal branch arteriogram during embolization. Catheter tip is advanced more selectively (*arrow*) into vessel.

E, Selective right external carotid angiogram after embolization. No extravasation is seen.

and 2B). This procedure was followed by superselective angiography using the road mapping function. Internal maxillary arteriography did not reveal the site of extravasation; however, a catheter was immediately introduced into the ascending pharyngeal artery, allowing the source of the bleeding to be identified as the superior pharyngeal branch of the right ascending pharyngeal artery (Fig. 2C). A microcatheter was advanced distally in this vessel and placed near the bleeding point. Embolization using polyvinyl alcohol foam (300–600 microns) and aviten (microfi-

brillar collagen) was performed, resulting in immediate cessation of contrast extravasation and epistaxis (Fig. 2D). The result was complete occlusion of the proximal portion of the superior pharyngeal branch of the right ascending pharyngeal artery (Fig. 2E). Immediately prior to this procedure, the blood pressure fell from 100/50 to 72/40. Following embolization, the blood pressure rapidly recovered to 140/60. Following this procedure, the patient experienced no further epistaxis. Two months after admission, the patient was discharged, with a left seventh nerve

palsy and bilateral eighth nerve palsies due to skull base fracture.

Discussion

Epistaxis associated with a skull base fracture can occasionally become intractable. When nasal bleeding continues despite anterior and posterior nasal packing, angiography to detect the bleeding point and embolization should be performed as soon as possible. Duggan (3) reports one case of intractable epistaxis due to skull base fracture. He states that serial angiography with subtraction techniques is effective for demonstrating active bleeding because extravasation of contrast medium is difficult to visualize on routine angiographic films. In the present case, clinical and radiographic evidence appeared to favor hemorrhage from the left side. However, selective DSA of the right external carotid artery demonstrated extravasation of contrast medium but failed to indicate specifically the bleeding artery. However, superselective DSA with a microcatheter and the road mapping technique demonstrated precisely the source of the bleeding. DSA of both internal and external carotid arteries is necessary to determine on which side the bleeding is occurring. To identify precisely the bleeding artery, superselective DSA is indispensable.

Many authors (3–7) report that epistaxis often occurs from the ethmoid branches of the ophthalmic artery or the pharyngeal branches of the maxillary artery. Other important contributing vessels in addition to these are the vidian artery and the capsular branch of the internal carotid artery according to Lasjaunias (5). Branches of the facial artery are likely to contribute if the internal maxillary artery is occluded proximally. However, no previous reports have implicated the ascending pharyngeal artery as the source of epistaxis.

The three pharyngeal branches (inferior, middle, and superior) of the ascending pharyngeal artery supply the medial and paramedial mucosa of the nasopharynx and oropharynx; they anastomose across the midline with their contralateral counterparts and ipsilaterally with their companion branches of the facial and maxillary arteries. The superior pharyngeal branch also supplies the bone and mucosa of the sphenoid sinus (Fig. 3). The ascending pharyngeal artery may be an important cause of epistaxis, especially when the latter is due to a skull base fracture.

In the present case, the bleeding was only from the right ascending pharyngeal artery. To identify

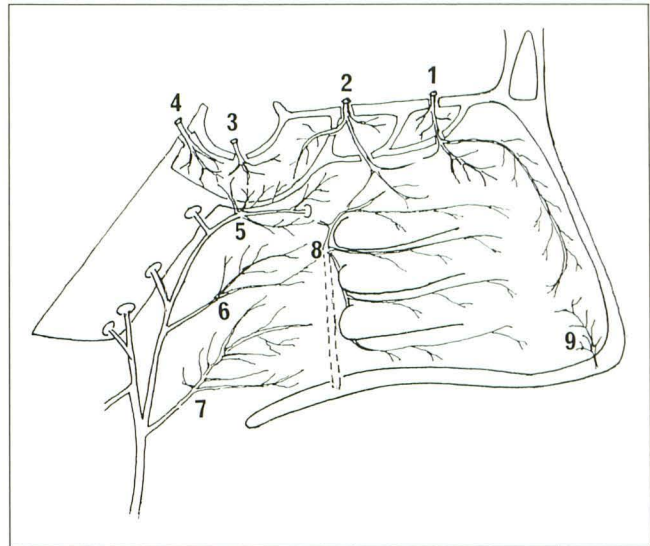


Fig. 3. Drawing of arterial supply to the nasopharyngeal wall, ethmoid sinus, and sphenoid sinus. Key.—The internal carotid system: 1, anterior ethmoid artery; 2, posterior ethmoid artery; 3, capsular artery; 4, vidian artery. The ascending pharyngeal artery: 5, superior pharyngeal branch; 6, middle pharyngeal branch; 7, inferior pharyngeal branch. The internal maxillary system: 8, sphenopalatine artery. The facial artery: 9, superior labial artery.

the bleeding artery in cases of skull base fracture, superselective DSA of the ascending pharyngeal artery should be performed following that of the internal maxillary artery. Embolization should be performed as close to the bleeding point as possible to avoid complications such as cranial nerve palsies. Also, superselective distal embolization may possibly serve to stop the bleeding more rapidly than proximal embolization which leaves the risk of recurrent bleeding from anastomotic channels distal to the embolization site.

References

1. Dion J, Dukwiler GR, Lylyk P, Vinuera F, Bentson J. Progressive suppleness Purcil catheter: a new tool for superselective angiography and embolization. *AJNR* 1989;10:1068–1070
2. Kikuchi Y, Strother CM, Boyer M. New catheter for endovascular interventional procedures. *Radiology* 1987;165:870–871
3. Duggan CA, Brylsky JR. Angiographic demonstration of bleeding in intractable traumatic epistaxis. *Radiology* 1970;97:605–606
4. Hicks JN, Vitek G. Transarterial embolization to control posterior epistaxis. *Laryngoscope* 1989;99:1027–1029
5. Parnes J, Heeneman H, Vinuela F. Percutaneous embolization for control of nasal blood circulation. *Laryngoscope* 1987;97:1312–1315
6. Robertson GH, Reardon EJ. Angiography and embolization of the internal maxillary artery for posterior epistaxis. *Arch Otolaryngol* 1979;105:333–337
7. Sokoloff J, Wickbom I, McDonald D, Brahme F, Goergen TG, Goldberg LE. Therapeutic percutaneous embolization in intractable epistaxis. *Radiology* 1974;111:285–287
8. Lasjaunias PBO, Marsot-Dupuch R, Doyon D. The radio-anatomical basis of arterial embolization for epistaxis. *J Neuroradiol* 1979;6:45–53