

# Computed Tomography of the Sacrum: 2. Pathology

Margaret Anne Whelan<sup>1, 2</sup>  
 Sadak K. Hilal<sup>1</sup>  
 Richard Palmer Gold<sup>1</sup>  
 Martin G. Luken<sup>3</sup>  
 W. Jost Michelson<sup>3</sup>

Fifteen cases of primary sacral pathology were analyzed. High-resolution computed tomography was found to be the most accurate means of studying these cases. Certain anatomic changes involving the central canal and sacral foramina were found to be helpful in determining the type of pathology. Although conventional plain films, radio-nuclide bone scans, and myelography were useful in certain cases, computed tomography was found to be the procedure of choice in the workup of sacral problems

## Materials and Methods

The computed tomographic (CT) scans of 15 patients with sacral abnormalities were analyzed. All scans were obtained in the supine position with no angulation of the table or gantry. Thirteen of the 15 patients were examined using the Pfizer model 450 scanner with a 512 × 512 matrix, a scan time of 5 or 10 sec, and a slice thickness of 2–10 mm. Of the 15 patients studied, nine had congenital lesions (three adults, six children) and six had neoplastic disease (four adults, two children).

## Results

### *Congenital Sacral Lesions*

Congenital lesions were diagnosed as meningocele (case 1), lipoma (cases 2–4), dermoid (cases 5 and 9), lipomeningocele (case 6), low conus, tethered cord (case 7), and lipoma, tethered cord (case 8). All but one of the six children in this group was strongly suspected of having a congenital lesion either because of a superficial dermal marker (hair tuft, hemangioma) or associated anomalies such as anal atresia. Of the adults, two of the three had histories strongly suggestive of a congenital abnormality (cases 2 and 3), while one patient (case 1) was thought to have a neoplasm when first examined. All the patients with congenital lesions had varying degrees of spinal dysraphism on plain films. In two cases, the defect was minimal and not appreciated on the initial films, while in one case of adult meningocele the sacral deformity was believed to represent neoplasm. Bone scanning was not performed in any of the patients with congenital lesions. Myelography was performed in six patients, two with metrizamide and four with Pantopaque. A low conus with tethered cord was demonstrated in five patients; an associated lipoma was present in four and a dermoid in one. However, the most informative study of the sacrum in all these patients was the high-resolution CT scan.

All the congenital lesions demonstrated dorsal dysraphism with widening of the central sacral canal and sparing of the sacral foramina. The four lipomas clearly displayed fat density (fig. 1) while the dermoids showed calcium, fat, and soft-tissue density. In the patient with meningocele (case 1), CT demonstrated the widening of the central canal as well as extrusion of the meningocele into the buttock via a dorsal defect in the sacrum (fig. 2A). In addition, CT was able to

This article appears in the September/October 1982 issue of *AJNR* and the December 1982 issue of *AJR*.

Received October 14, 1980; accepted after revision April 20, 1982.

Presented at the annual meeting of the American Society of Neuroradiology, Los Angeles, March 1980.

<sup>1</sup>Department of Radiology, Columbia-Presbyterian Medical Center, New York, NY 10032.

<sup>2</sup>Present address: Department of Radiology, New York University Medical Center, 560 First Ave., New York, NY 10016. Address reprint requests to M. A. Whelan.

<sup>3</sup>Department of Neurosurgery, Columbia-Presbyterian Medical Center, New York, NY 10032.

*AJNR* 3:555–559, September/October 1982  
 0195–6108/82/0305-0555 \$00.00  
 © American Roentgen Ray Society

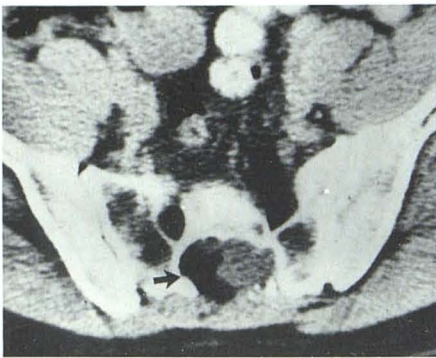


Fig. 1.—Sacral lipoma. Widened sacral canal contains large fat density (arrow).

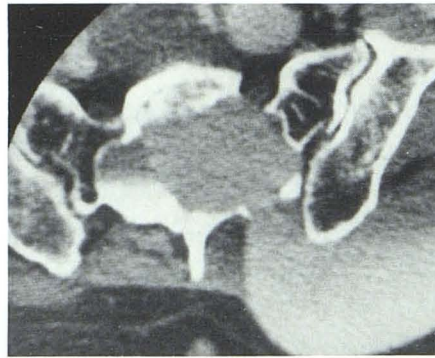
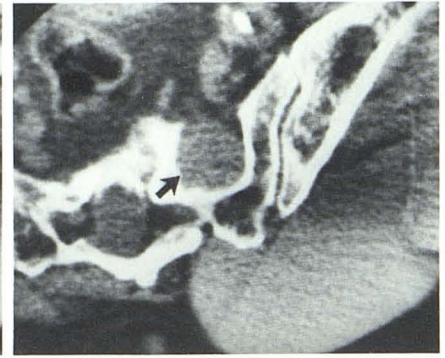
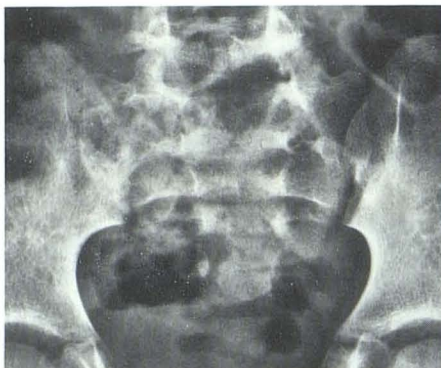

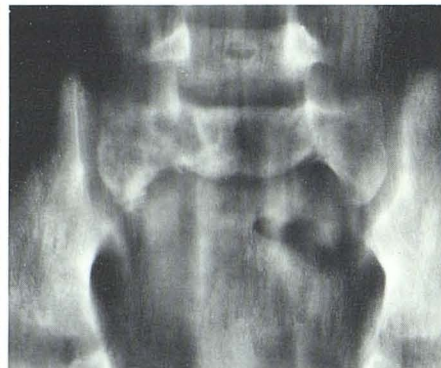Fig. 2.—Sacral meningocele. **A**, Metrizamide-filled meningocele is seen widening central canal and protruding into buttock through dorsal bony



**B**, Lower section. Smaller ventral extrusion (arrow).

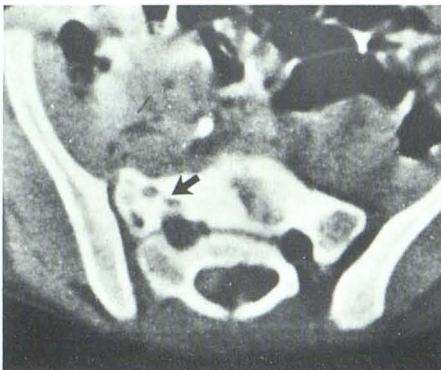


**A**

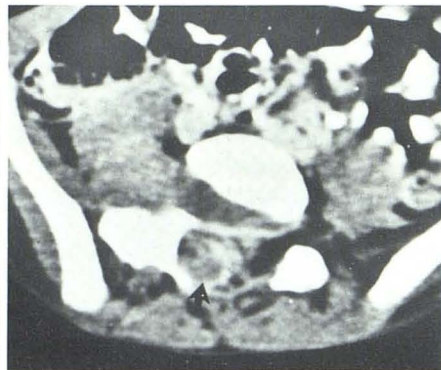

**B**

Fig. 3.—Ewing sarcoma. **A**, Bowel gas and feces obscure right sacral lesion on plain films. **B**, Tomogram clearly demonstrates bone lesion in right upper sacrum. **C**, CT of upper sacrum confirms bony lesion (arrow). **D**, Slightly higher section reveals soft-tissue component both within spinal canal (arrow) and in parasagittal area.



**C**



**D**

identify a smaller ventral extrusion (fig. 2B). Only one patient received intravenous contrast material, because it was not believed to be helpful in delineating congenital lesions of the sacrum. The one patient who had an intravenous contrast study (case 9) had meningitis and demonstrated minimal dural enhancement.

#### Neoplastic Sacral Lesions

Neoplastic lesions were diagnosed as neurofibroma (cases 10 and 11), chordoma (cases 12 and 13), Ewing

sarcoma (case 14), and histiocytic lymphoma (case 15). Although all patients with tumors had abnormal plain films, the lesions were not initially appreciated in three patients (one child and two adults). The diagnosis was clarified in the child because of a strong clinical suspicion leading to a tomogram, which clearly visualized the lesion in the right sacral ala (case 14) (fig. 3). Both the adults (cases 10 and 13) were thought to have disk disease. In fact, one patient (case 13) was operated on for a herniated disk, at which time his primary problem, chordoma, was discovered.

Five of these six patients had Pantopaque myelograms,

Fig. 4.—Sacral neurofibroma. A, AP view of sacrum clearly demonstrates well circumscribed left sacral lesion. B, CT shows uniform widening of first sacral foramina on left with sparing of sacral canal.

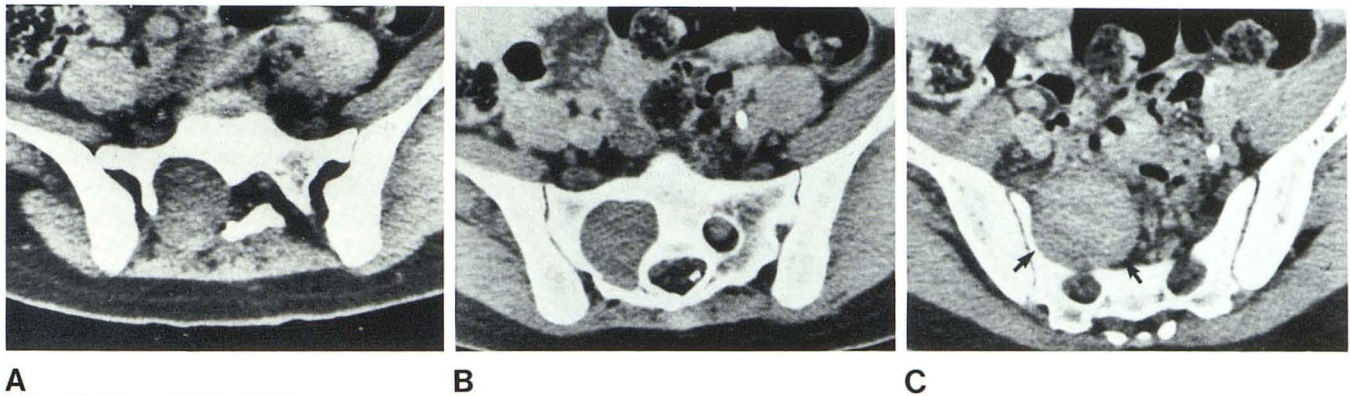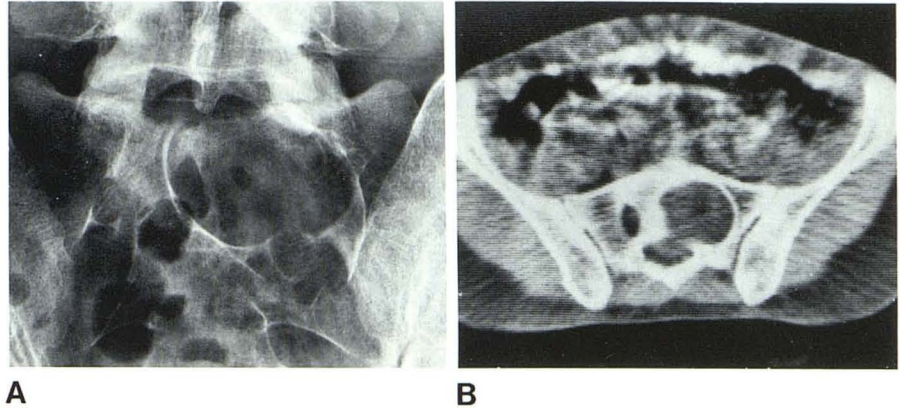


Fig. 5.—Neurofibromatosis involving sacrum. CT demonstrates widening of first (A) and second (B) sacral foramina on right with extension of neurofibroma into pelvis (C) (arrows). Myelogram (D) shows extradural defect on right secondary to large neurofibroma as well as a number of smaller neurofibromas in lower lumbar region.

and all were abnormal. Four patients had bone scans (cases 10, 12, 14, and 16). The chordoma (case 12) and the sarcomas (cases 14 and 16) showed abnormal uptake, while the neurofibroma (case 10) showed a focal photon-deficient area. High-resolution CT proved the most diagnostic study in all three cases.

Both neurofibromas showed selective uniform expansion

of the sacral foramina with sparing of the sacral canal (figs. 4 and 5). In one patient, the extrasacral component of the large neurofibroma was outlined in the pelvis (fig. 5C). The two chordomas showed extensive destruction of the bony sacrum with obliteration of the bony landmarks, namely foramina and sacral canal (fig. 6). Again, CT was able to demonstrate both the ventral and dorsal soft-tissue com-

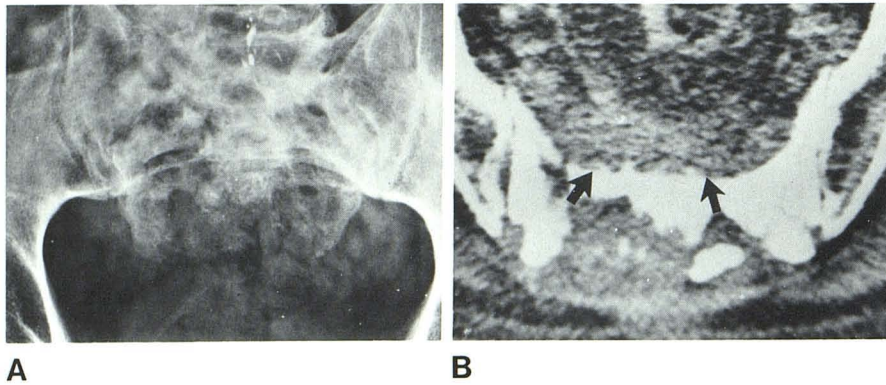


Fig. 6.—Chordoma. **A**, Plain film demonstrates extensive destruction of sacrum. **B**, CT confirms diffuse destructive pattern of bony sacrum as well as revealing ventral and dorsal soft-tissue component (arrows).

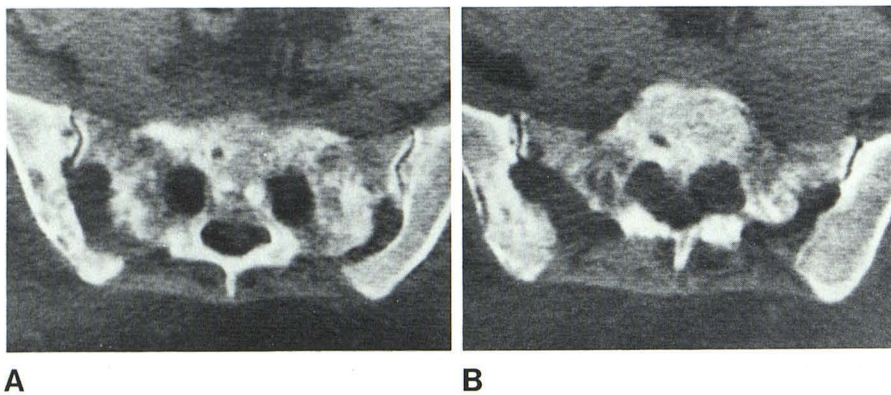


Fig. 7.—Lymphosarcoma. CT of sacrum shows destruction of sacrum and iliac bone (**A**) with large ventral soft-tissue components bilaterally (**B**).

ponent of these lesions. The Ewing sarcoma revealed a discrete abnormality of the bony matrix as well as a soft-tissue component of the lesion that was not appreciated on tomography (fig. 3D). The lymphosarcoma showed bony destruction of the lumbosacral as well as iliac regions bilaterally. CT also demonstrated a large ventral soft-tissue component (fig. 7). By demonstrating both bony and soft-tissue components, CT was the best means of delineating the true extent of these neoplasms.

### Discussion

It is difficult to evaluate the sacrum using conventional radiography because of its dorsal curvature and normal overlying bowel gas and fecal material. To compensate for this dorsal curvature, it has been recommended that patients with suspected sacral problems have an anteroposterior (AP) sacral view with the x-ray tube angled  $15^{\circ}$ – $20^{\circ}$  cephalad. This view will avoid foreshortening of the sacrum (fig. 4). To overcome the problem of gas and feces, especially in children, an AP tomogram is necessary when the abnormality cannot be definitely established by the plain film (fig. 3). To further complicate the plain film evaluation of the sacrum, a variant on the lateral projection has been described that appears as a sharply demarcated bony defect overlying the first or second sacral vertebra [1]. This variant represents the fossa cribrosa, the site of penetration of blood vessels into the bone, and can be confused with

neoplasms or intrasacral meningoceles. Lateral tomograms should be helpful in this instance [1].

Myelography and bone scanning may further delineate a problematic area in the sacrum, although not all sacral lesions will cause a myelographic defect or pick up radio-nuclide agents. The advent of high-resolution CT, however, has resolved these problems by providing a noninvasive means of accurately evaluating the sacrum [2–5]. Therefore, once a sacral lesion has been established or strongly suggested by either clinical, plain film, or tomographic criteria, a high-resolution CT scan is the next procedure of choice.

Sacral lesions include congenital, neoplastic, metabolic, inflammatory, and traumatic processes. In evaluating the CT scan of the sacrum, it can be divided into four areas, sacral canal, sacral foramina, bony matrix, and perisacral soft tissues. Analysis of the alteration of these various features enabled us to separate the congenital from neoplastic lesions in our series.

The congenital lesions showed varying degrees of spinal dysraphism with primary widening of the midline sacral canal. Determination of the CT numbers allowed distinction of fat, calcium, and cerebrospinal fluid densities. In delineating the position of the conus, however, CT alone was not sufficient. Here, myelography with either metrizamide or Pantopaque was necessary. In the congenital lesions, metrizamide was preferred because myelography can be combined with CT, and removal of the contrast fluid, more difficult and dangerous in low conus situations, is not nec-

essary. Although complications have been reported with metrizamide, the more serious complications, namely, transient visual disturbance and paresis, are unusual. Furthermore, children and young adults seem less affected by metrizamide [6-8].

It must be mentioned that a study has been reported in the literature [9] stating that water-soluble contrast agents such as metrizamide decrease the ability to recognize various intracanalicular tissues such as fat, fibrocartilage, and bone, and therefore, air myelography should be coupled with CT in evaluating lumbosacral problems. Using the fourth-generation Pfizer 0450 scanner, it has not been difficult to distinguish fat or bone from metrizamide. Furthermore, it is often difficult to manipulate subarachnoid air into the exact area of interest.

With regard to neoplastic lesions of the sacrum, the efficacy of CT has previously been reported [10-12]. Depending on the results of the sacral scan, a decision as to the necessity of myelography can be made. Certain CT characteristics were believed to add specificity to the diagnosis. Both neurofibromas demonstrated primary expansion of the sacral foramina sparing the sacral canal. Since the sacral nerve roots exit through the foramina, this CT finding was considered diagnostic of a neoplastic nerve lesion such as neurofibroma, ganglioneuroma, or schwannoma (figs. 4 and 5). Both chordomas revealed diffuse bone destruction with obliteration of the sacral canal and foramina (fig. 6). In addition, both revealed large soft-tissue components both ventrally and dorsally on CT. The CT scan helped in the surgical approach as both cases were operated on in two stages, one using a ventral and one a dorsal approach, thus allowing maximal removal of the tumor. In the child with Ewing sarcoma, CT showed a bony abnormality in the superior part of the right sacrum with a small ventral soft-tissue component, as well as an intracanalicular extension at L5-S1 on the right (fig. 3). If there remains a question as to the extent of tumor involvement in the lower lumbar region, myelography can be performed. All the neoplasms in this series demonstrated extradural defects in the lower lumbar region while one patient with neurofibromatosis showed on myelography small neurofibromas in the lumbar and cervical region (fig. 5D).

After the extent of the neoplasm has been documented with CT and myelography, follow-up CT provided a non-invasive method of evaluating residual tumor after surgery or the response of malignant lesions to radiation and/or chemotherapy.

From this experience we believe high-resolution tomography is not only the most accurate evaluation of the sacrum,

but analysis of the alteration of the various sacral components, canal, foramina, bony matrix, and soft tissues adds specificity to the diagnosis. All congenital lesions expand the central sacral canal, while neoplasms involving an individual nerve root will expand the sacral foramina. Malignant neoplasms such as chordoma and sarcoma alter the bony matrix to varying degrees and frequently demonstrate associated soft-tissue masses.

Plain films of the sacrum, even with tomography, can be difficult to evaluate and may not fully clarify the etiology of the clinical problem. We believe that high-resolution CT should be performed in all patients with suspected sacral lesions where more conventional plain film examinations do not provide the anatomic information necessary for definitive patient management.

#### REFERENCES

1. Kreyenbuhl W, Hessler C. A variation of the sacrum on the lateral view. *Radiology* **1973**;109:49-52
2. Baleriaux-Waha, Osteux M, Terwinghu G, deMeeus A, Jeanart L. The management of anterior sacral meningocele with computed tomography. *Neuroradiology* **1977**;14:45-46
3. Crellin RQ, Jones ER. Sacral extradural cysts—a rare cause of low backache and sciatica. *J Bone Joint Surg [Br]* **1973**;55:20-31
4. Gilula LA, Murphy WA, Tailor CC, Patel RB. Computed tomography of the osseous pelvis. *Radiology* **1979**;132:107-114
5. Janecki CJ, Nelson CL, Dohn DF. Intracanalicular cyst—report of a case and review of the literature. *J Bone Joint Surg [Am]* **1972**;54:423-428
6. Barry JF, Harwood-Nash DC, Fitz CR, Byrd SE, Boldt DW. Metrizamide in pediatric myelography. *Radiology* **1977**;124:409-418
7. Drayer BP, Rosenbaum AE, Reigel DB, Bank WO, Deeb ZL. Metrizamide computed tomography cisternography: pediatric application. *Radiology* **1977**;124:349-357
8. Hugosson C, Hindmarsh T, Bergstrom K. Myelography with metrizamide in infants and children. *Acta Radiol [Suppl]* (Stockh) **1977**;355:193-199
9. Scatliff JH, Bidgood WD, Killebrew K, Staab EV. Computed tomography and spinal dysraphism: clinical and phantom studies. *Neuroradiology* **1979**;17:71-75
10. Berger PE, Kuhn JP. Computed tomography of tumors of the musculoskeletal system in children. *Radiology* **1978**;127:171-175
11. deSantos LA, Bernardino ME, Murray JA. Computed tomography in the evaluation of osteosarcoma. Experience with 25 cases. *AJR* **1979**;132:535-540
12. Smith J, Wixon D, Waston RC. Giant cell tumor of the sacrum. *J Can Assoc Radiol* **1979**;30:34-39