

Developmental Morphology of the Subarachnoid Space, Brain Vasculature, and Contiguous Structures, and the Cause of the Chiari II Malformation

David G. McLone¹ and Thomas P. Naidich

From the Children's Memorial Hospital, Chicago, IL (DGM), and the Baptist Hospital of Miami, Miami, FL (TPN)

Preliminary studies have shown that the mouse, the monkey, and humans have strikingly similar ultrastructure and distribution of the mature subarachnoid space (1). For that reason, we have chosen normal hy-3 mice to study the development of normal mammalian meninges. To maintain structural comparability, we have confined our study to the meninges overlying the developing cerebral hemispheres. The cellular elements in this particular region are thought to be derivatives of a single embryonic cell layer (2), so this approach avoids the question of whether other cell lines contribute to the meningeal structure in other regions of the pia-arachnoid.

Development of the Meninges

Development of the meninges proceeds through 3 stages:

Stage 1

The first stage in the development of the cranio-cerebral meninges begins with closure of the cephalic end of the neural tube—the site of the future telencephalon—at about the ninth fetal day (in mice). The mesenchyme surrounding this part of the neural tube is characterized by a large extracellular space filled with ground substance.

The mesenchymal cells elaborate fine processes that course through the ground substance to form a reticulum that is situated between the developing neuroepithelium and the single squamous cell layer of ectoderm at the surface (Fig. 1) (3). The mesenchymal cells have oval, eccentrically located nuclei with scant cytoplasm on one side and a large Golgi complex on the other. At the 10th fetal day, vascular elements begin to develop in the otherwise nonvascular mesenchymal layer. These vascular elements form close to the surface of the neuroepithelium and, therefore, lie “deep” to the major portion of the mesenchyme. Over the telencephalon, the vascular elements develop into a “vascular tunic” (4) that contains immature hematogenous elements (Fig. 2). The developing endothelium appears similar to the mesenchyme, but can be distinguished by the presence of complex “tight” junctions between the cells, by the presence of a basal lamina, by pinocytotic vesicles, and by the microvilli that extend into the vascular lumina.

As development progresses, vessels penetrate the surface of the telencephalon (Fig. 3). In spite of active proliferation of vessels, mitotic figures are uncommon in the perineural mesenchyme, suggesting that the vessels may form from the mesenchymal cells already present. At this stage, only vascular elements can be seen in the mesenchyme. No other meningeal elements can be identified. By the 12th fetal day (in mice), the entire telencephalon is covered by a continuous vascular tunic. Sinusoids situated within this continuous vascular tunic then begin to condense into tubular vessels.

¹ Address reprint requests to Dr McLone, Children's Memorial Hospital, 2300 Children's Plaza #28, Chicago, IL 60614.

Index terms: Subarachnoid space; Chiari malformations; Pediatric neuroradiology

AJNR 13:463-482 Mar/Apr 1992 0195-6108/92/1302-0463
© American Society of Neuroradiology

Stage 2

Superficial to the developing vascular tunic, the preexisting reticulum of mesenchymal cells and their processes now becomes organized into distinct layers (Fig. 4). This marks the beginning of the second stage. At some distance superficial to the vascular tunic, elongated cells with large oval nuclei form a compact cellular lamina, three to four cells thick. The residual mesenchyme situated between the vessels and this compact, cellular lamina remains as a more loosely cellular layer. Thus, from superficial to deep, there are now sequential layers of squamous surface epithelium, a compact cell layer, a loosely cellular layer of residual mesenchyme, the vascular tunic that is differentiating into tubular vessels, and the neuroepithelium. The compact layer of cells proceeds to become more compact by a marked

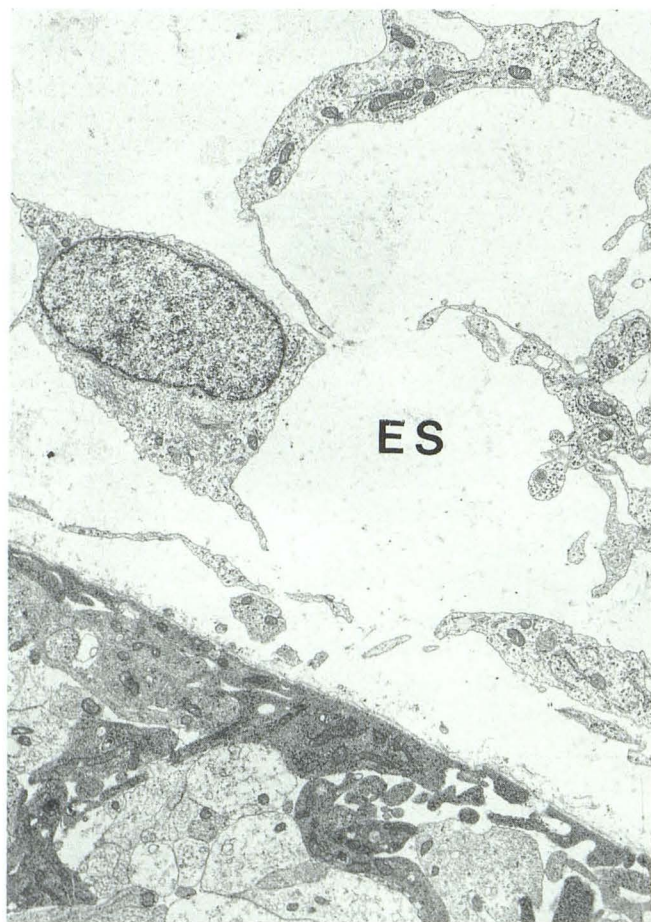

Fig. 1. The developing subarachnoid space over the mammalian telencephalic hemisphere is composed of a loose mesenchyme with a large extracellular space (ES) filled with a gel-like ground substance. This preexisting space will become the pathway for CSF.

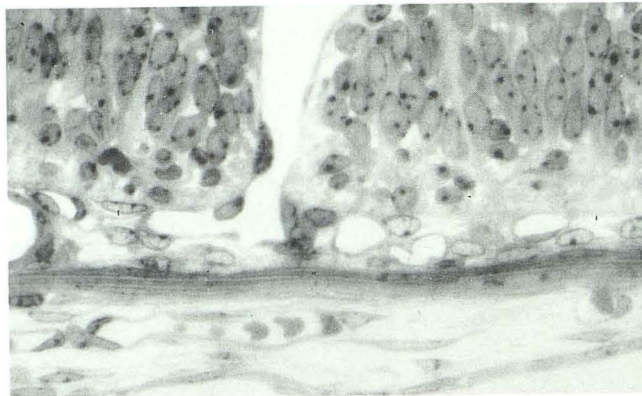


Fig. 2. As the mammalian subarachnoid space develops, the cells begin to align parallel to the cerebral surface. Note the large vascular channels.

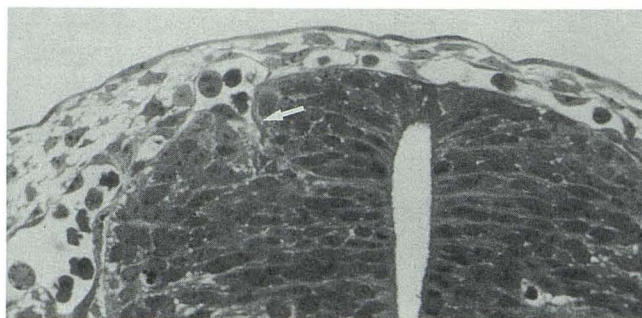


Fig. 3. The developing subarachnoid space near the midline is smaller. Note the penetration of the vascular tunic into the nervous system (arrow). This also shows the first bifurcation of the vessels as they advance into deeper layers.

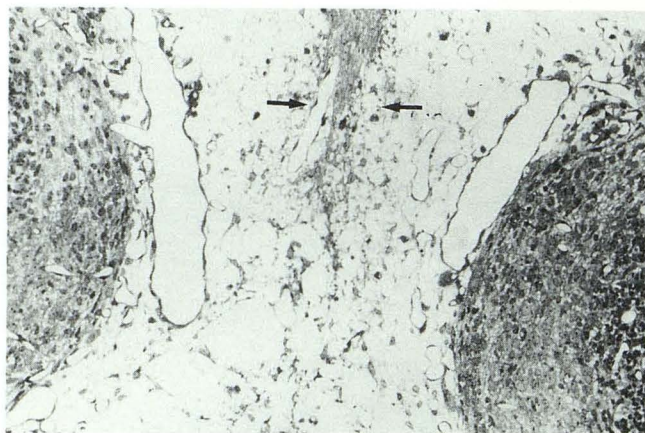


Fig. 4. Early delineation of the outer layer of the subarachnoid space can be identified (arrows) between the developing cerebral hemispheres.

reduction in the extracellular space. This compact layer delineates the outer limit of the primitive subarachnoid space. It is destined to form the *outer* arachnoid membrane, the *dura mater*, and

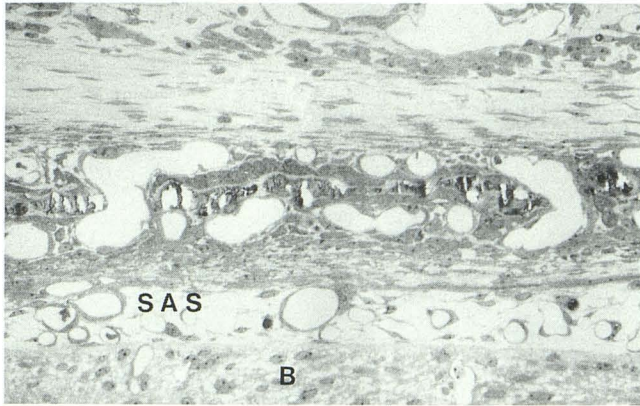


Fig. 5. Delineation is complete and now the dense layer of collagen over the cerebral hemispheres has become calcifiable with early membranous bone formation underway. *B* = Brain; SAS = subarachnoid space. The center layer superficial to the SAS is composed of (from inner to outer layer) primitive dura mater, early membranous bone, and outer periosteum.

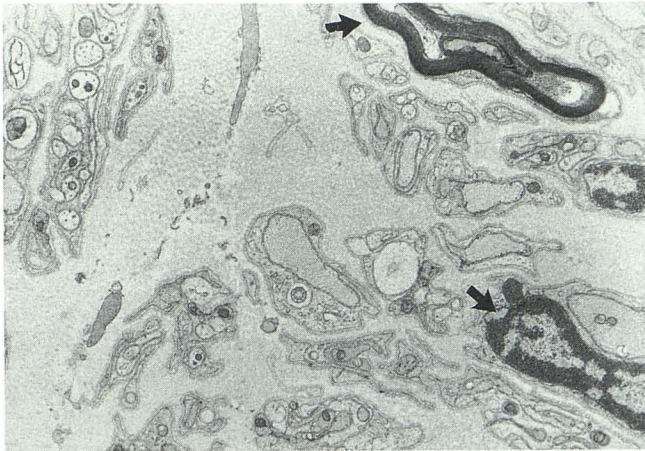


Fig. 6. As the dura mater matures, axons migrate into it. The exact function of all of these nerves is not known. Many are pain fibers (arrows), but the two large myelinated fibers serve some other function.

the skull. The loosely cellular layer of mesenchyme situated deep to the compact layer is filled with mesenchymal ground substance. It will evolve into the subarachnoid space.

Cells forming the primitive pia-arachnoid can now be differentiated from the vascular elements, because the vascular endothelial cells now appear denser and contain abundant ribosomes. The endothelial cells are attenuated and extend over a much larger area, but plump primitive endothelial cells are still numerous. The remaining mesenchymal cells tend to align parallel to the telencephalic surface; their cytoplasm is now less dense. Their ribosomes are gathered into rosettes or polysomes. There is a reduction in the number of mitochondria and in the amounts of rough

endoplasmic reticulum. Intercellular junctions appear numerous.

The amount of extracellular space becomes greatly reduced in the compact layer, but remains large in the deeper loosely-cellular portion of mesenchyme that will form the fetal subarachnoid space. Collagen fibrils and extracellular microfibrils are scattered through the extracellular space between the inner layer of pia-arachnoid cells and the cerebral surface. By the end of stage 2, the subarachnoid space and the fetal meninges are identifiable.

Stage 3

During the final stage, growth of the meninges and an increased amount of tissue between blood vessels, leads to an *apparent* decrease in the number of vessels in the superficial meninges. The subarachnoid space is now well established. Slender processes of arachnoidal trabeculae traverse the subarachnoid space and make contact with the vascular endothelial cells. Other long slender cellular processes extend over the surface of the brain and around the vessels of the subarachnoid space. These processes act to ensheath the brain and vessels, so that they become separated from the developing subarachnoid space and the space itself becomes lined by an epithelium.

Cells containing large dense bodies, probably macrophages, are found in the subarachnoid space from the second period of pia-arachnoid development onward. These increase in number during adult stages.

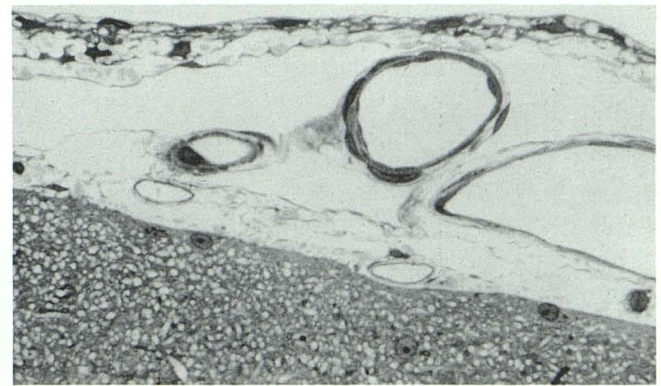


Fig. 7. The mature mammalian subarachnoid space is now present. The outer, hydrated cell layer of pia-arachnoid remains intact, as the dura mater has previously been peeled away. Vessels show their ensheathment with pia-arachnoid cells. The surface of the hemisphere is coated with pia-arachnoid cell processes and connective tissue elements.

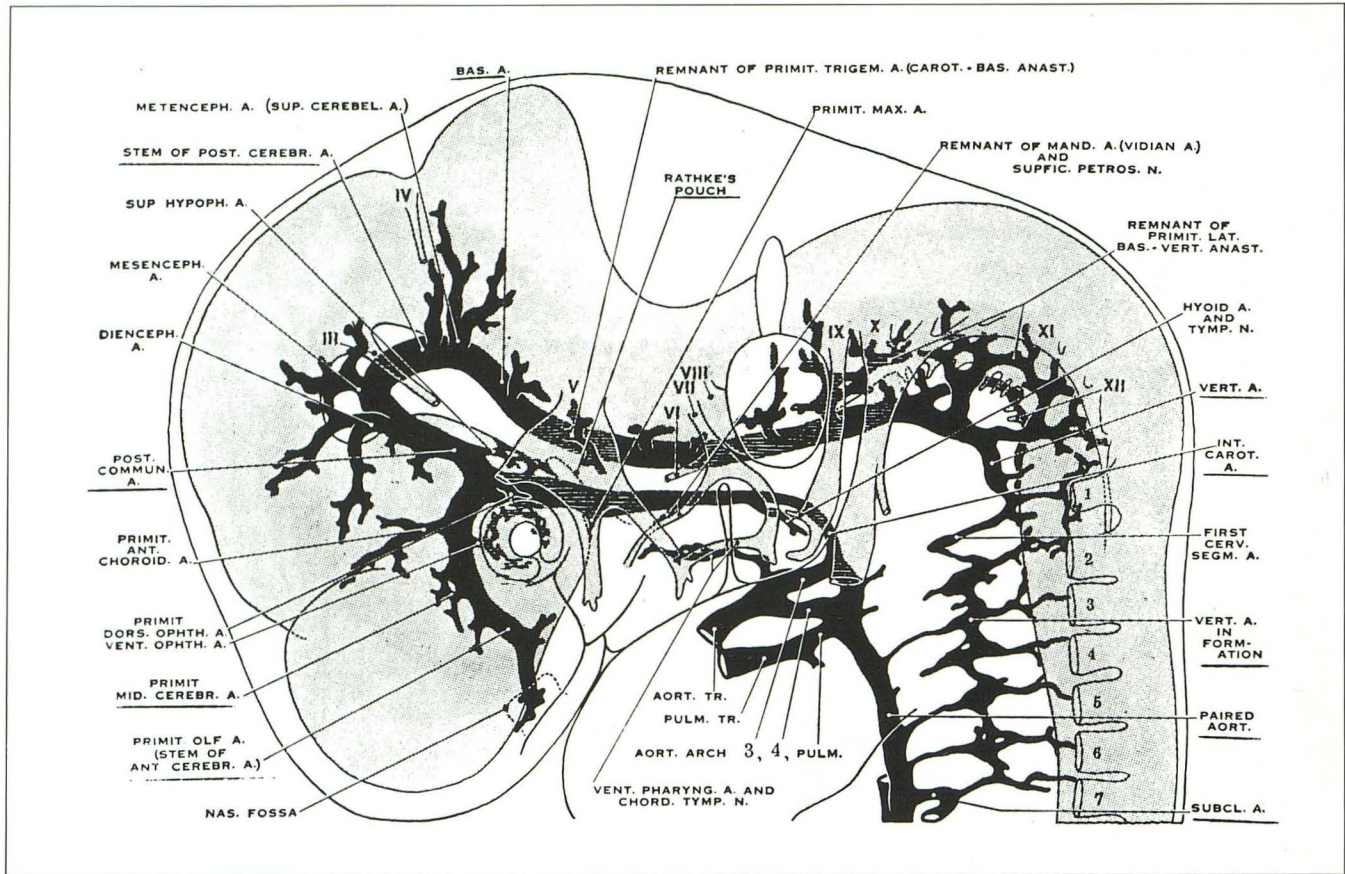


Fig. 8. Cranial arteries of the left side in a 9-mm embryo (lateral view). Note formation of the vertebral artery from elements of the upper cervical segments, the caudal swing of the cranial nerve VII and its associated hyoid artery, the ventral pharyngeal artery lying against the mandibular end of the chorda tympani, and the two primitive arteries supplying the eye. The primitive olfactory artery, cranial division of the internal carotid artery, terminates at the nasal cavity. (Reprinted from *Contributions to Embryology* (20).)

The compact cell layer now differentiates further into the deeper layer that will form the outer layer of the arachnoid and the more superficial layer that will form dura. The deep portion of the compact layer, now consists of five to six parallel cellular processes and appears more electron-lucent. This establishes the *outer* arachnoid or "hydrated cell" layer (5). There is a marked decrease in intracellular organelles, so that by maturity only scattered mitochondria, small amounts of rough endoplasmic reticulum and polysomes remain. Postnatally, continued maturation of the outer arachnoid converts this previously simple laminar layer into a layer with complex interdigitations between cells.

In most areas, it is difficult to identify a distinct boundary between the arachnoid mater and the developing dura mater. Only a gradual change in cellular morphology from the inner arachnoid through the dura can be seen. With each successive layer from arachnoid through dura, the cells become progressively more dense and contain

increasing amounts of rough endoplasmic reticulum. There is also a gradual increase in the number of collagen fibrils between cells. No true subdural space or transitional layer between dura and arachnoid can be identified.

Following development of the compact layer about the 14th fetal day, there is a concomitant increase in the deposition of *extra*-cellular collagen fibrils between cells. Vessels grow into a layer of cells midway in the compact layer. These cells then increase in size, become polyhedral, and surround a layer of collagen fibrils that appears randomly woven. These cells are the early osteoblasts (Fig. 5). They contain abundant rough endoplasmic reticulum and a large Golgi complex (6, 7). Microvilli extend into the surrounding collagenous matrix. On this matrix calcium is deposited to form the intramembranous bone of the skull. This process proceeds from multiple points in the parietal bone. These points eventually coalesce into linear ossification centers that radiate outward from the center of the parietal bone

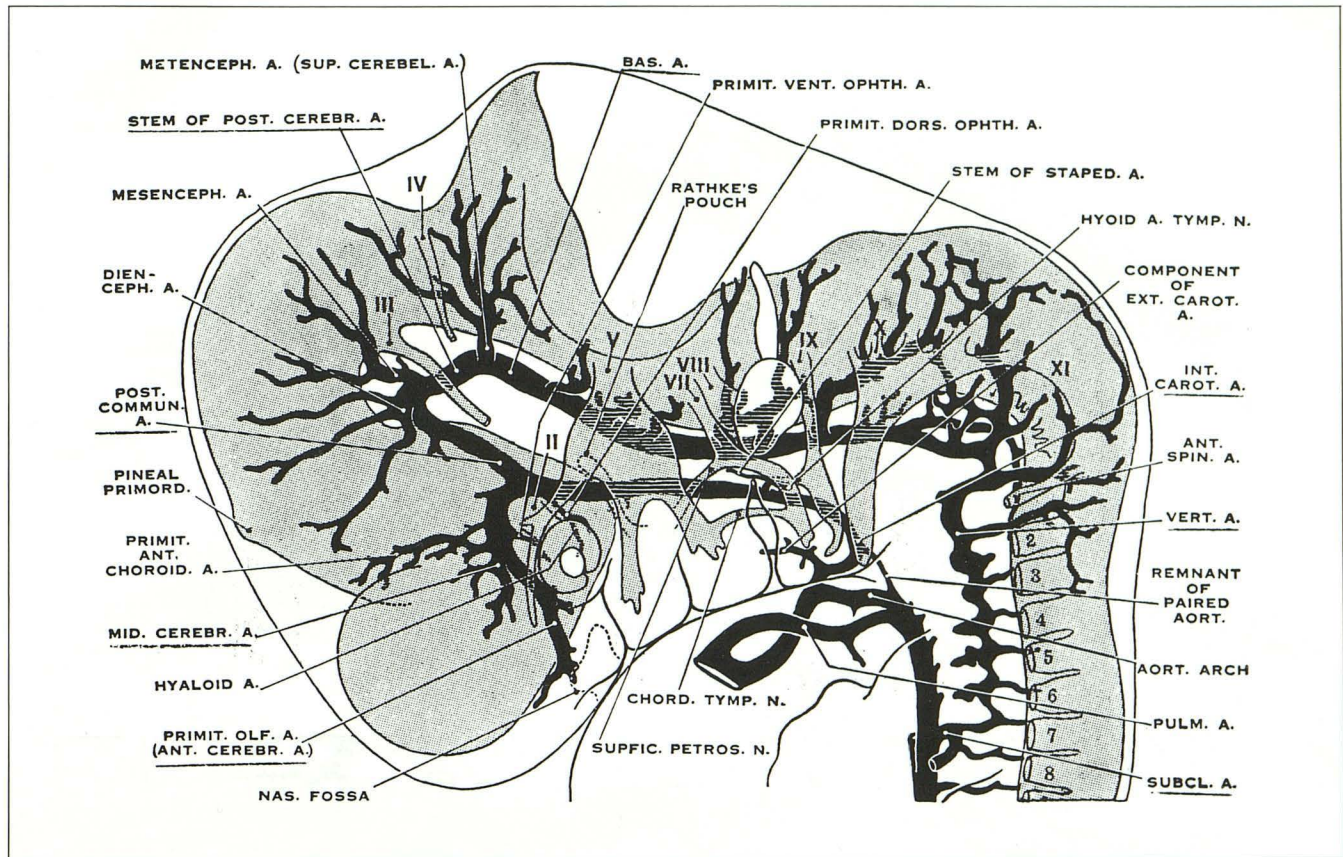


Fig. 9. Cranial arteries in a 12.5-mm embryo. Developments to note are the new stapelial branches of the hyoid artery, the stem of which has been shifted cranially; the more advanced conformation of the vertebral artery; the emergence of several well-defined cerebral arteries; and elongation and differentiation of the two primitive ophthalmic branches of the internal carotid artery. (Reprinted from *Contributions to Embryology* (20).)

like a starburst. The osteoblasts on the inner surface of the cranium become the periosteal dura. Osteoclasts do not appear until early postnatal life.

At birth, the fibrous dura mater over the parietal convexity consists of large fibroblasts and their processes. The processes are arranged in lamellae, with bundles of collagen fibrils within the wide intercellular spaces. The collagen fibrils appear randomly distributed, so the collagenous laminae are not complete at this stage. Organization into lamellae begins at the arachnoid side of the dura and progresses toward the periosteal dura. By the fourth postnatal day, the lamellae are well established with well-ordered collagen bundles that tend to be oriented in a single plane within each lamella.

Nerves grow into the fibrous dura at various levels (8, 9) in much the same way described for other developing peripheral nerves (10). At birth, nerves appear over the cerebral convexity in bundles, with the ensheathing Schwann cells en-

circling the bundles. Within a short time Schwann cell processes interdigitate between the axons, isolating them from each other. This is followed by the appearance of myelin (Fig. 6).

In the early postnatal period, the pia-arachnoid is characterized by a wider distribution of collagen fibers and the appearance of smooth muscle around the larger vessels. Two types of cells encircle the subarachnoid vessels: 1) the ensheathing pia-arachnoidal cells, and 2) smooth muscle cells and pericytes. The smooth muscle cells and pericytes appear identical during the stage of ensheathment (Fig. 7). It remains difficult to differentiate between the smooth muscle cells and the pericytes until the presence of cytoplasmic densities associated with the plasma membrane of smooth muscle cells eventually allows smooth muscle cells to be identified.

As others have pointed out (11, 12), the pial mantle never completely invests the cerebral surface; in many areas, the basal lamina of glia limitans abuts directly on the subarachnoid space.

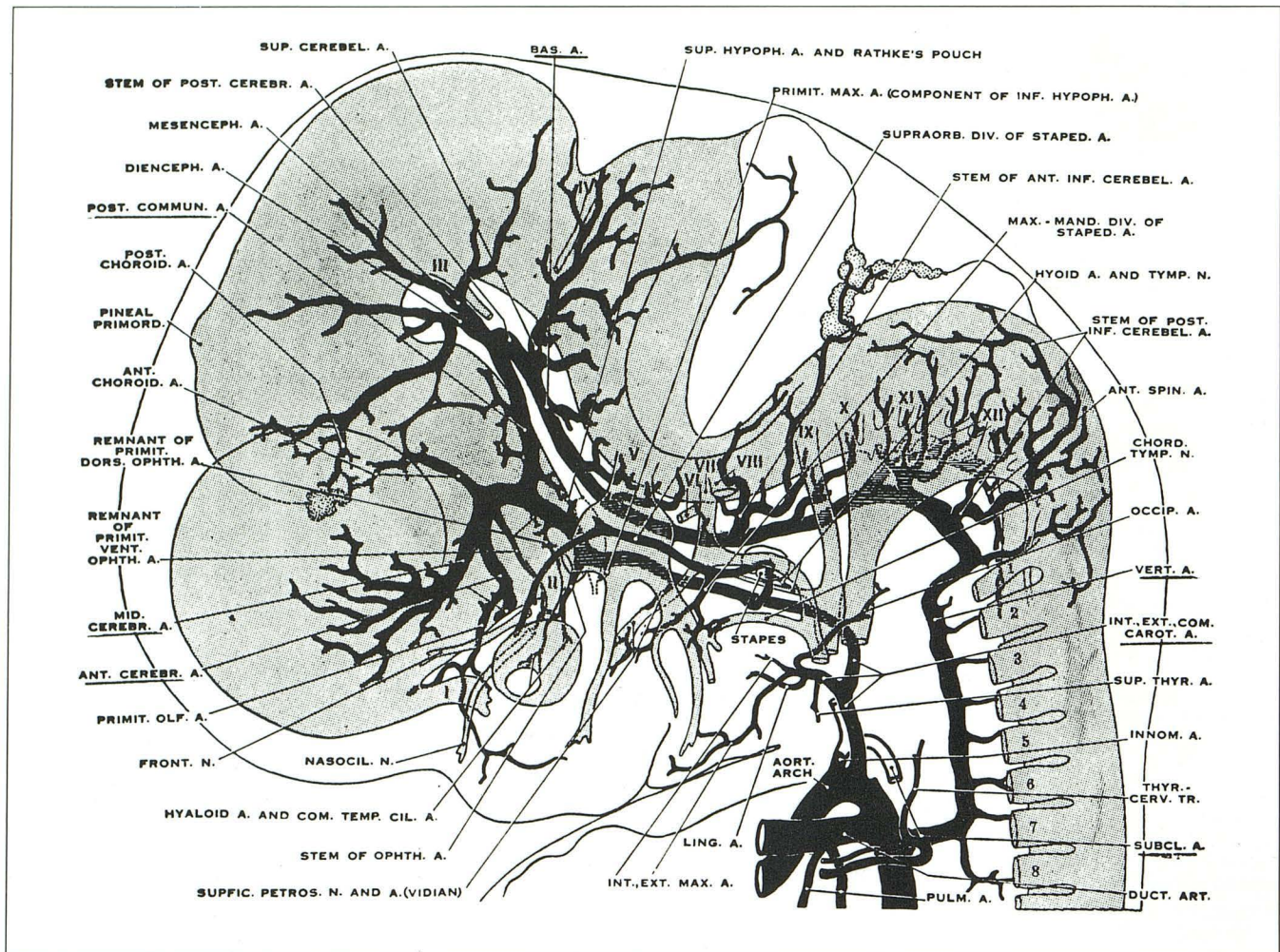


Fig. 10. Cranial arteries in an 18-mm embryo at the period when most of the adult arteries in the head region become recognizable. Note particularly the new adult stem of the ophthalmic artery, which annexes the ocular branches of the primitive ophthalmic arteries. $\times 16.7$. (Reprinted from *Contributions to Embryology* (20).)

The distinction between pial and arachnoid cells is unclear even in mature meninges. Indeed, these cells might better be designated pia-arachnoid cells. This is especially true in some areas where a single cell contributes distinctly different processes to both the pial surface and the inner portion of the arachnoid. Those pia-arachnoid cells associated with collagen or extracellular microfibrils (13) have more polysomes and rough endoplasmic reticulum, whereas those pia-arachnoid cells associated with blood vessels have more pinocytotic and coated vesicles.

Embryology of the Brain Vascular System

Historical Review

In 1944, Dandy (14) summarized earlier descriptions of the head arteries by Tandler (15), Mall (16), and Evans (17). Streeter (1918) (18)

had described the formation of the cranial vasculature, the adjustment of vessels to cerebral growth and the dural venous sinuses. Congdon (1922) (19) had described the evolution of the aortic arch and of the carotid, vertebral, and basilar arteries. However, our present understanding of vascular embryology depends heavily on the work of Padgett who described the development of the arterial supply (1948) (20) and the venous drainage (1956, 1957) (21, 22) of the human brain. Stoeter and Drews (1983) (23) added to our understanding of the embryonic venous system. Others further described the nature of the vascular system (24–26).

The Cranial Arteries

The precise order in which cranial capillaries appear in the embryo varies from individual to

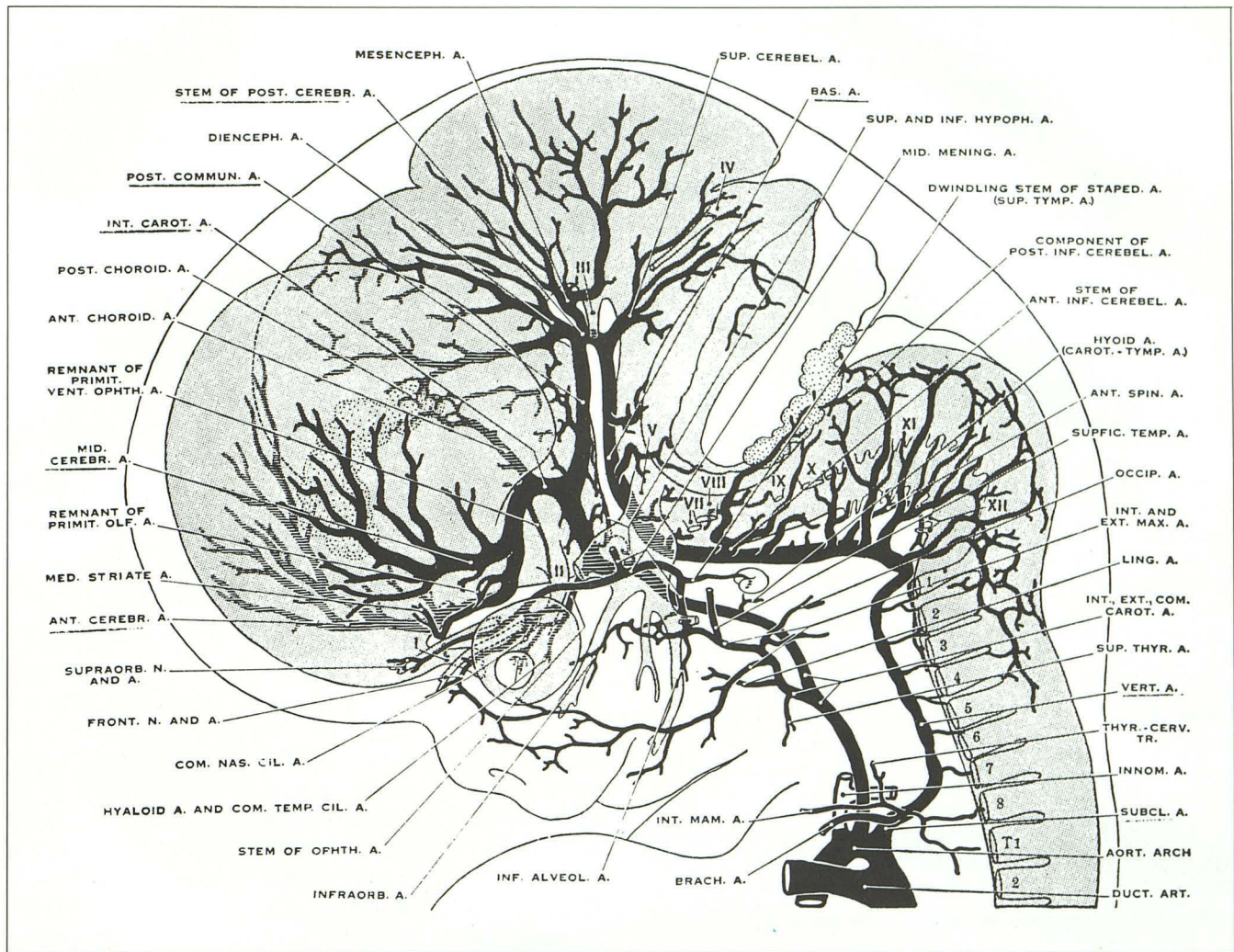


Fig. 11. Cranial arteries in a 24-mm embryo. Note the dwindling stem of the stapelial artery and the two secondary anastomoses by which its major divisions are annexed, respectively, by the ophthalmic artery to form its orbital branches, and the internal maxillary artery to form the stem of the middle meningeal artery. Derivatives of the primitive olfactory artery now penetrate the anterior perforated substance as striate branches of the anterior cerebral artery. $\times 13.3$ (Reprinted from *Contributions to Embryology* (20).)

individual. In general, however, development passes through successive stages (20).

Stage 13–16

In this stage the first and second aortic arches are involuting. The portions of the paired aortas that extend cephalically from the third arch constitute the primitive internal carotid artery on each side. This artery appears to emerge from a vascular plexus and to bifurcate distally into two branches. One branch is the primitive trigeminal artery. The other branch is the cerebral artery that continues toward Rathke's pouch around which it anastomoses with the opposite cerebral artery. Each carotid artery forms two divisions. A cranial division curves in front of the optic vesicle to terminate in the olfactory area. A caudal

division of the carotid artery ends in a plexus at the mesencephalon (27). A primitive ophthalmic artery is also seen at this stage.

Stage 17

The most striking development in stage 17 is the initial formation of the vertebral artery (Fig. 8). The primary cranial division of the internal carotid artery gives rise to the primitive anterior choroidal artery. Mesial twigs form in the path of the future anterior cerebral artery. Vascular twigs also appear at the distal end of the middle cerebral arterial stem.

At the caudal end of the posterior communicating artery the posterior choroidal artery is now visible. Superior cerebellar arteries are forming at the distal end of the basilar artery.

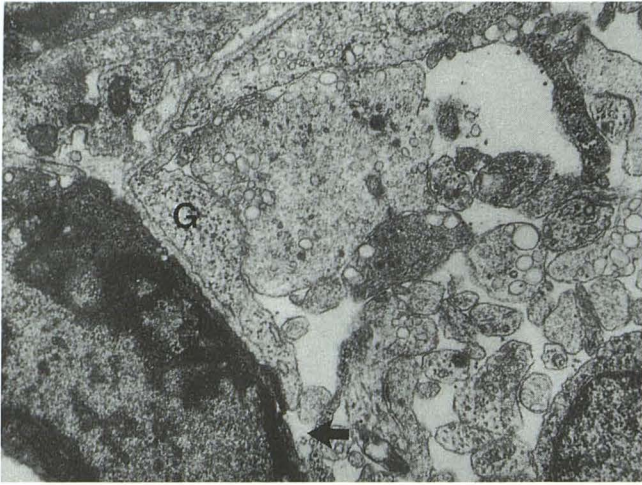


Fig. 12. An electron micrograph shows the zone of penetration of the developing hemisphere by vascular elements. Note the glial processes (*G*) already beginning to isolate the vessel from direct contact with neuronal elements. At this point the isolation is incomplete (*arrow*).

Stage 18–20

In stage 18, descent of the heart into the thorax elongates the common carotid artery. The definitive adult ophthalmic artery arises from two widely separated portions of the internal carotid artery.

The middle cerebral artery now gives rise to several branches that spread over the cerebral hemispheres (Fig. 9). Both the anterior and the posterior choroidal arteries terminate in the choroidal infolding at the diencephalic roof. The first segment of the posterior cerebral artery is now evident at the distal end of the posterior communicating artery. Later, this artery will enlarge rapidly as the hemisphere grows posteriorly to envelop the midbrain.

The three principle branches of the basilar system are now identifiable.

Stage 20–23

In stage 20, the head now has recognizable human features and begins to lift away from the chest. Expansion of the cerebral hemispheres leads to completion of the circle of Willis.

The most important arterial advances in this stage involve the anterior cerebral and the anterior communicating arteries. Prior to the development of the corpus callosum from the commissural plate, a branch of the anterior cerebral artery supplies the choroid plexus in the region of the foramen of Monro (28). In chimpanzees, this artery may persist, passing around the splen-

ium into the velum interpositum to terminate at the foramen of Monro. The anterior cerebral artery shows variable development, and may appear as a barely identifiable vessel, a plexus or a single midline vessel. In some animals and as a rare variation in man, the anterior cerebral artery may persist as a single vessel designated the azygous anterior cerebral artery; paired anterior cerebral vessels may not develop (Fig. 10).

By 8 weeks' gestation, all the major intracranial arteries are readily identifiable and have assumed nearly their adult form. During this stage, those variations that are recognized in the adult may already be seen, eg, the variable origin of the posterior communicating artery, variations in the circle of Willis, and the reciprocal changes in the form of the anterior inferior and posterior inferior cerebellar arteries (Fig. 11).

The Penetrating Vessels and Capillaries

As described earlier, the cranial vessels reach the neural tissue. A plexus of vessels or *vascular tunic* spreads over the neural epithelium through the developing subarachnoid space. Initially, the metabolic demands of the evolving brain are adequately met by diffusion of metabolites from surrounding tissue. As the neural mass grows larger, however, diffusion no longer can supply the metabolic requirements of the brain. Vessels then begin to penetrate the neural parenchyma, possibly in response to a vasogenic factor elaborated by the brain.

Duckett (29) divided the development of vessels to the human brain into two successive phases. This section considers the internal phase.

Embryo

Through the seventh week, the telencephalic pallium is essentially avascular. By the end of the seventh week vessels have started to penetrate brain. Four stages of this vascularization are recognized (29): 1) During the seventh week, stem vessels from the surface vascular plexus invade across the cortical anlage (the stratum cribrosum of His) to reach the zona incerta beneath. 2) During the eighth and ninth weeks of fetal life, the stem vessels in the zona incerta dichotomize, sending out capillary-size branches parallel to the cortical and ventricular surfaces. 3) During the ninth and 10th weeks, a second group of stem vessels arises from the pial vasculature and either (a) anastomoses with the parallel vessels or (b)

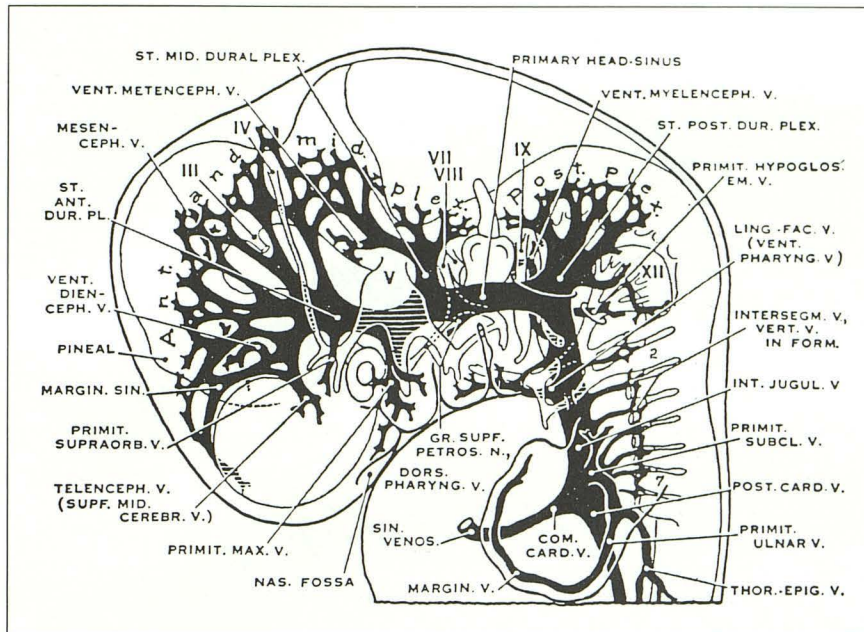


Fig. 13. Expansion of the future hemispheres of the brain clearly separates the dural and pial layers of venous channels. Consequently, the numerous anastomoses traversing the primitive pia-arachnoid begin to decrease and can thus be identified; often at least one such transverse vein for each division of the brain is seen in older embryos of this stage. (Reprinted from *Contributions to Embryology* (22).)

invades the mantle layer directly with ramifying vessels from the parallel vessels. 4) During the 11th and 12th weeks, vessels of the mantle layer give rise to branches that enter the germinal layer to form a rete. With thickening of the telencephalic pallium the phase of internal vascularization is established.

Fetus

The vascularization of the fetal brain has been described by Sterzi (30), Hoskins (31), Tilney and Casamajor (32), Luna (33), Williams (34), Wislocki (35), Feeney and Watterson (36), Niemineva (37), Sensenig (38), Strong (39), and Duckett (29).

At the ultrastructural level, the primitive vessels that cross the outer brain surface are initially exposed directly to the extracellular space (Fig. 12). They lack a glial covering. In the adult brain, the entire vascular stem is separated from the extracellular space by limiting glial processes. The vessels are not exposed directly to the brain. The role that primitive glial cells play in directing the vascularization of brain remains unclear.

At the light microscopic level, vessels seem to appear suddenly throughout the brain. Strong (39) interpreted this observation to mean that preexisting interconnecting strands of endothelial cells suddenly develop lumina to form a hollow vascular network. Electron microscopy has confirmed this interpretation in developing rat brains (40). It may be that the lumen initially develops from the coalescence of vacuoles in endothelial

cells. This is supported by the fact that some fetal capillaries appear seamless.

The final vascular pathway develops by a process of anastomosis, followed by selection of preferred architecture, and then regression of other pathways. This phase appears to be the most vulnerable. Alterations in this period may lead to the development of vascular variations and of defective vascular structures such as malformations.

Vascular penetration of the spinal cord and hindbrain occurs early, shortly after closure of the neural tube (41, 42). Our studies of dysraphic states in mammals indicates that vascularization occurs independent of neural tube closure.

In the diencephalon and hindbrain, vessels penetrate to the ependymal layer where they form a rich vascular plexus. Some of these vessels may even penetrate into the lumen. The functional significance of this plexus is not certain, but it seems reasonable to assume this plexus is the origin of cerebrospinal fluid (CSF) prior to the development of the choroid plexus.

The vascular penetration of the cerebral hemisphere described above is a late event in brain vascularization, because the human pallium matures much later than the other parts of the central nervous system (CNS).

Development of the Cranial Venous System

We owe our knowledge of the development of venous drainage in the embryo to Padgett (21,

Fig. 14. The first definitive sinus, the sigmoid, is formed dorsal to the otocyst by an anastomosis between the middle and posterior dural plexuses. The head-sinus, thus replaced, has begun to dwindle. The voluminous maxillary vein draining the orbital and nasal regions, soon anastomoses with the linguofacial (ventral pharyngeal) vein to form the anterior facial vein. Note: The elongated stems of the pia-arachnoid veins, the primary drainage of the lateral choroid plexus into the ventral diencephalic tributary of the primitive subclavian vein, arching over the clavicle, becomes the stem of the future external jugular system. (Reprinted from *Contributions to Embryology* (22).)

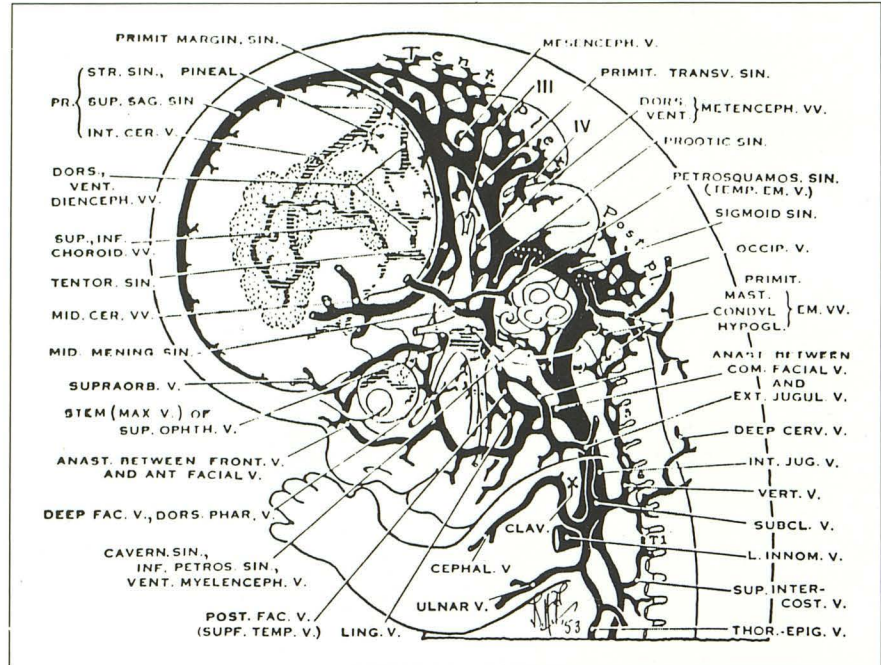
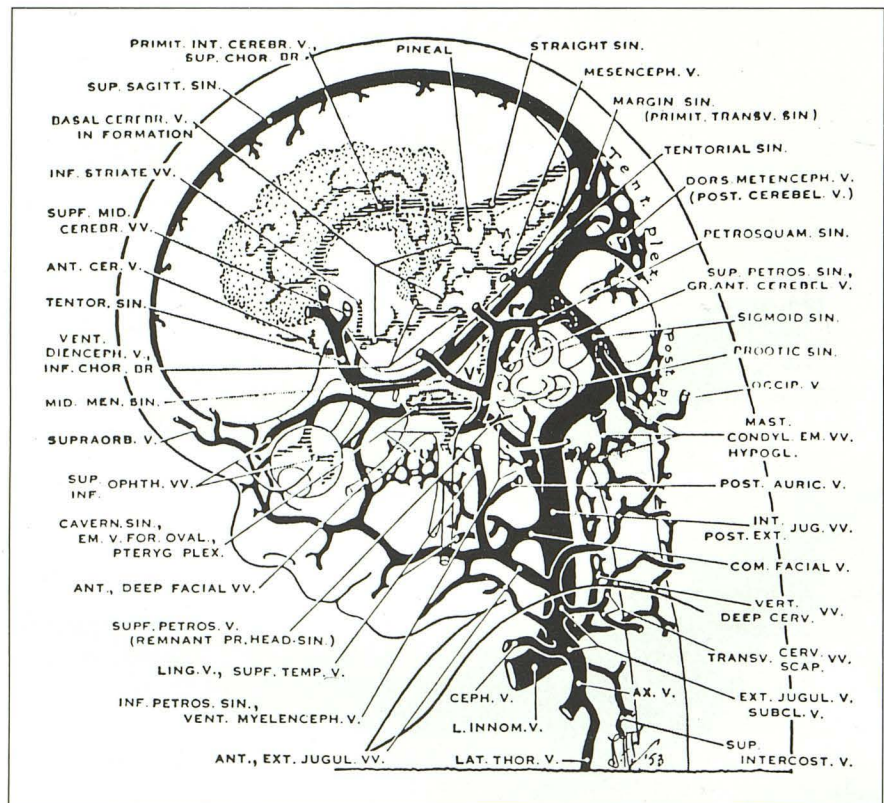


Fig. 15. Cranial venous stem when adult patterns become recognizable. The elongated tentorial sinus, draining the superficial cerebral veins, begins to migrate to the junction of the sigmoid sinus with the transverse sinus, which has been swung into definitive position. The superior petrosal sinus becomes definitive as the dural end of the metencephalic vein, which it represents, surmounts the expanding optic capsule. Note the spurious jugular foramen and its vein. The basal cerebral vein is formed by pial anastomoses between the primary transverse veins of the pia arachnoid. (Reprinted from *Contributions to Embryology* (22).)



22). Following her description of the development of the cranial arterial system, she identified eight corresponding stages of development of the venous system, including the infant and adult. Padgett (21) also detailed the comparative anat-

omy of the human venous system with that of other vertebrates. The venous system develops over a wide range of embryonic life than does the arterial system. It develops later and, therefore, is more evident in older embryos. In fact, some

TABLE 1: Anatomical features of the Chiari II malformation

Anterior/middle fossa
Luckenschadel of the skull
Polygyria
Cortical heterotopia
Dysgenesis of the corpus callosum
Large massa intermedia
Interhemispherical quadrigeminal cysts
Tectal "beak" of midbrain
Posterior fossa
Small posterior fossa
Low-lying tentorium with large incisura
Scalloping of the petrous bone
Shortening of the clivus along the basisphenoid
Loss of the pontine flexure
Aqueductal stenosis or forking
Caudal displacement of pons, medulla, and basilar artery
Descent and elongation of cerebellar vermis through the foramen magnum
Descent and kinking of the brain stem
Dorsal kink of cervicomedullary junction
Upward herniation of the superior cerebellum through the incisura
Spinal cord/canal
Enlargement of foramen magnum
Spina bifida aperta
Stretching of lower cranial nerves
Caudal displacement of upper cervical cord with horizontal or upward course of exiting nerve roots
Hydromyelia/syringohydromyelia

of the venous patterns are not fully established until after birth.

We begin at 30 days' gestation, because venous development is only rudimentary in arterial stage 13–14. The anterior cardinal vein is the venous drainage of the head on each side. This vein is the future internal jugular vein. Caudal to the 10th and 12th nerve roots, a venous channel lies directly on the neural tube and is continuous with the anterior cardinal vein. This vessel antedates true circulation and is transitory. As this vessel disappears, another vessel develops more laterally, one on each side. These paired lateral vessels are the first true venous drainage, the primary head-sinuses.

Major tributaries develop from the plexus of capillaries over the neural tube. On each side, these tributaries drain laterally into three superficial plexi or stems called the anterior, middle, and posterior dural stems. These stems drain in turn into the ipsilateral primary head sinus.

At 35 days' gestation, the telencephalon separates from the diencephalon by lateral evagination, and the pontine flexure begins to form.

The plexus of the anterior dural stem now contains the primitive marginal sinus on the dorsum of the emerging cerebral hemispheres. This sinus includes elements of the future superior and

transverse sinuses. The anterior stem also receives the telencephalic vein that drains the striate area. This vein will become a tentorial sinus. The plexus of the middle dural stem drains the large metencephalon. A notable change in the posterior dural plexus establishes the relationship of the 11th nerve to the jugular vein. The caudal end of the sigmoid sinus is established at this stage. Following these changes, the anterior cardinal vein can be called the primitive internal jugular vein.

The "postbranchial phase" occurs at 42 days' gestation (Fig. 13). The most notable feature is the delineation of the subarachnoid space and the establishment of the meningeal layers. The mesenchyme initially forms arteries. As the arteries mature, they move above the surface. Small tributary veins then develop from the remaining plexuses *deep* to the arteries. The small tributary pial veins that lie deep to the arteries must then gather into larger veins that lift off the brain surface and pass superficially across the large primitive subarachnoid space to reach the dural sinuses. The large veins of the adult brain lie on the surface superficial to the arteries; only the smaller tributaries lie beneath the arteries. Since the surface veins tend to drain superiorly or inferiorly to the dural sinuses, the veins lift pro-

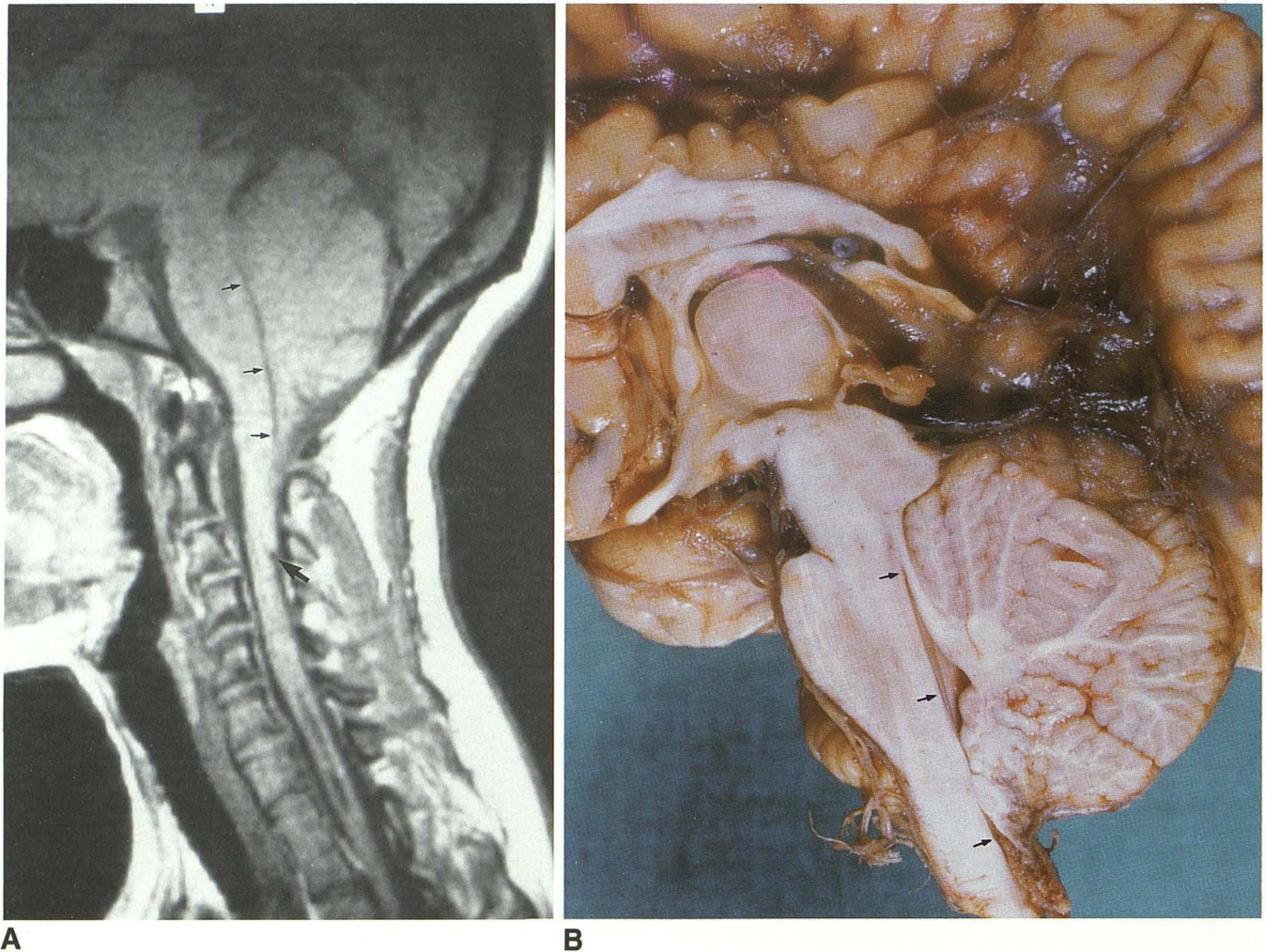


Fig. 16. Chiari II malformation of the hindbrain.

A, Midsagittal T1 MR.

B, Midsagittal pathologic section of the upper spinal cord, the brain stem, the cerebellum, the diencephalon, and the corpus callosum. There are elongation of the fourth ventricle (*small arrows*), upward herniation of the dorsal cerebellum, tectal beak of the midbrain, and downward herniation of the cerebellar vermis. A also displays the kink and spur at the cervicomedullary junction (*large arrow*) and hydromyelia. B also displays the large massa intermedia and dysplasia of the posterior corpus callosum.

gressively further away from the brain surface as they pass superiorly or inferiorly to enter the dual venous sinuses.

Padget (21) discussed the embryologic background of the arteriovenous anomalies. Vascular development suggests that both the deep and superficial arteriovenous malformations have the same embryonic basis; abnormal arterial influx into a large vein on the neural tube. As a general rule the developing veins and arteries cross each other at approximately right angles. This right angle crossing of arteries and veins keeps the contact between the two systems at a minimum. Areas where the arteries and the veins course parallel with each other, such as in the choroid plexi, have a higher probability of developing arteriovenous malformations.

By 48 days, when the human face becomes apparent, the venous system has become prominent, although it is far less developed than is the arterial system. A new longitudinal channel forms parallel and dorsal to the primary head-sinus and connects the anterior, middle, and posterior dural stems. The primary head sinus then dwindles (Fig. 14). The channel between the middle and posterior dural plexuses will constitute the definitive sigmoid sinus. The portion of the dorsal sinus between the anterior and middle dural plexi is the primitive transverse sinus.

At 50 days, the head lifts away from the chest and fingers become identifiable. Blood flow becomes reversed in the middle plexus and flows toward the new sigmoid sinus. The head-sinus disappears. The stem now constitutes the pro-

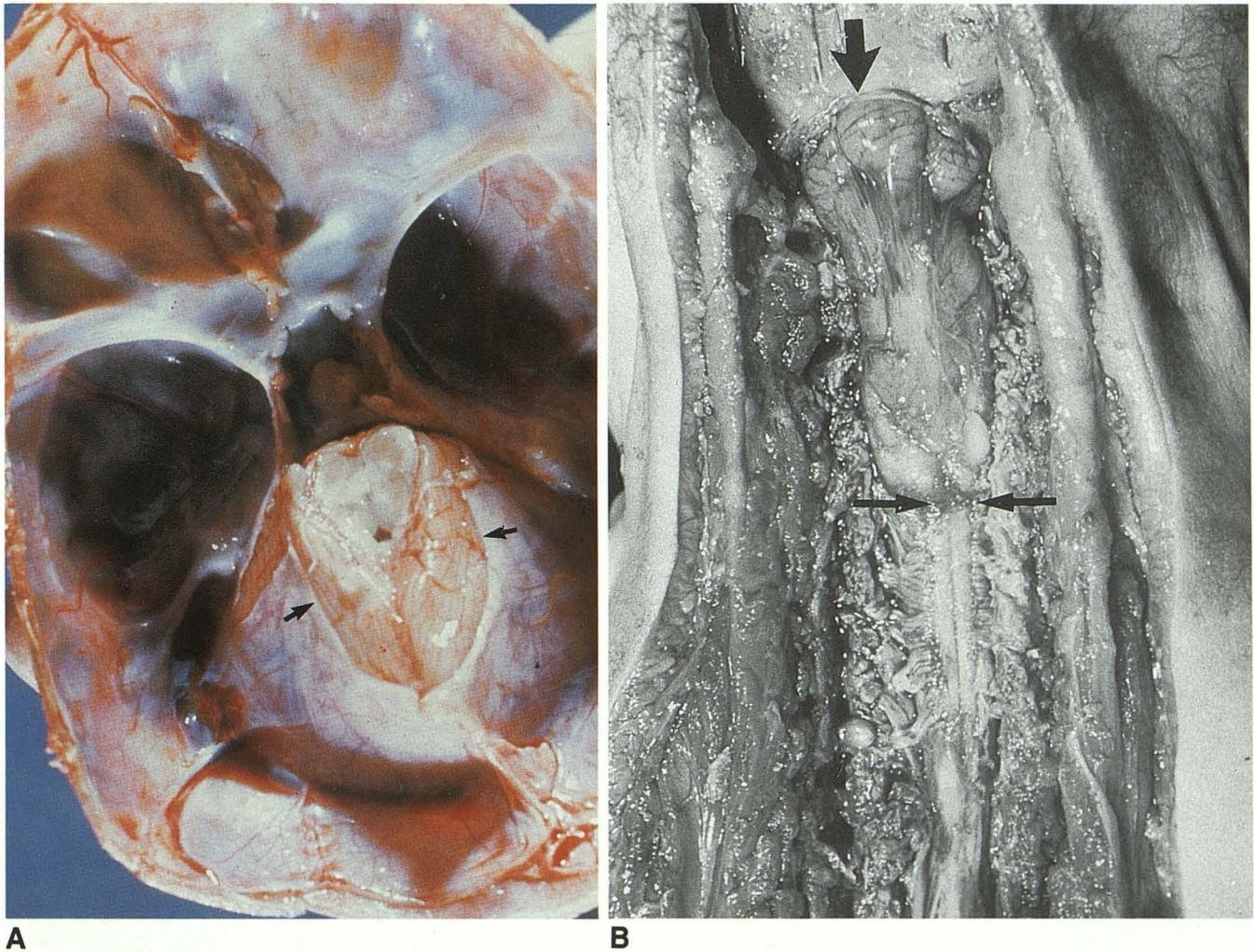


Fig. 17. A, Postmortem dissection. Resection of the cerebrum by section through the midbrain reveals the superior aspect of the dysplastic tentorium with a large incisure (arrows), and upward herniation of the cerebellum.

B, Operative exposure of the upper cervical spinal canal containing the downwardly herniated cerebellar vermis (large arrow) and medullary elements (paired arrows) of a Chiari II malformation. Note the glistening appearance of the arachnoid membrane over the dorsal aspect of the cerebellum.

otic sinus and is the last remnant of the head-sinus. Coincident with the development of the pro-otic sinus, the tentorial sinus becomes prominent. The tentorial sinus drains deep and superficial veins of the caudoventral posterior portion of the cerebral hemispheres. The sagittal plexus, tentorial plexus, and primitive transverse sinus are all prominent at this stage. The embryo is now about 10 weeks old and is passing into the fetal age.

Previously, only the sigmoid sinuses had assumed their definitive form. Other sinuses now also take nearly their final form. The medial portions of the primitive transverse sinuses (the marginal sinuses) move posteriorly. This process initiates formation of the superior sagittal sinus. The superior sagittal sinus arises with the coales-

cence of these vessels in the midline as the cerebral hemispheres meet and progress caudally. The dural sheath of the superior sagittal sinus is still immature, so the sinus remains plexiform. The Galenic system also begins to form. The primitive straight sinus and the great cerebral veins form primarily to the right as a plexus in the roof of the diencephalon near to the pineal primordium.

A prominent superior choroidal vein develops into the primitive internal cerebral vein that joins the great cerebral vein of Galen. Initially, the choroid plexi of the lateral and third ventricles drain anteriorly into the inferior choroid vein.

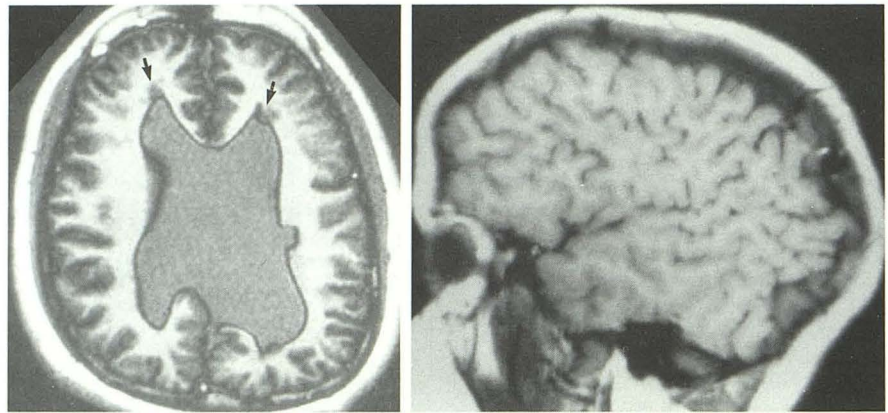
A new plexiform channel medial to the trigeminal ganglion is derived from the pro-otic sinus. This plexus surrounds the carotid artery at the

Fig. 18. Cerebral disorganization in association with Chiari II malformation.

A, Axial inversion recovery MR shows periventricular gray matter heterotopias (arrows).

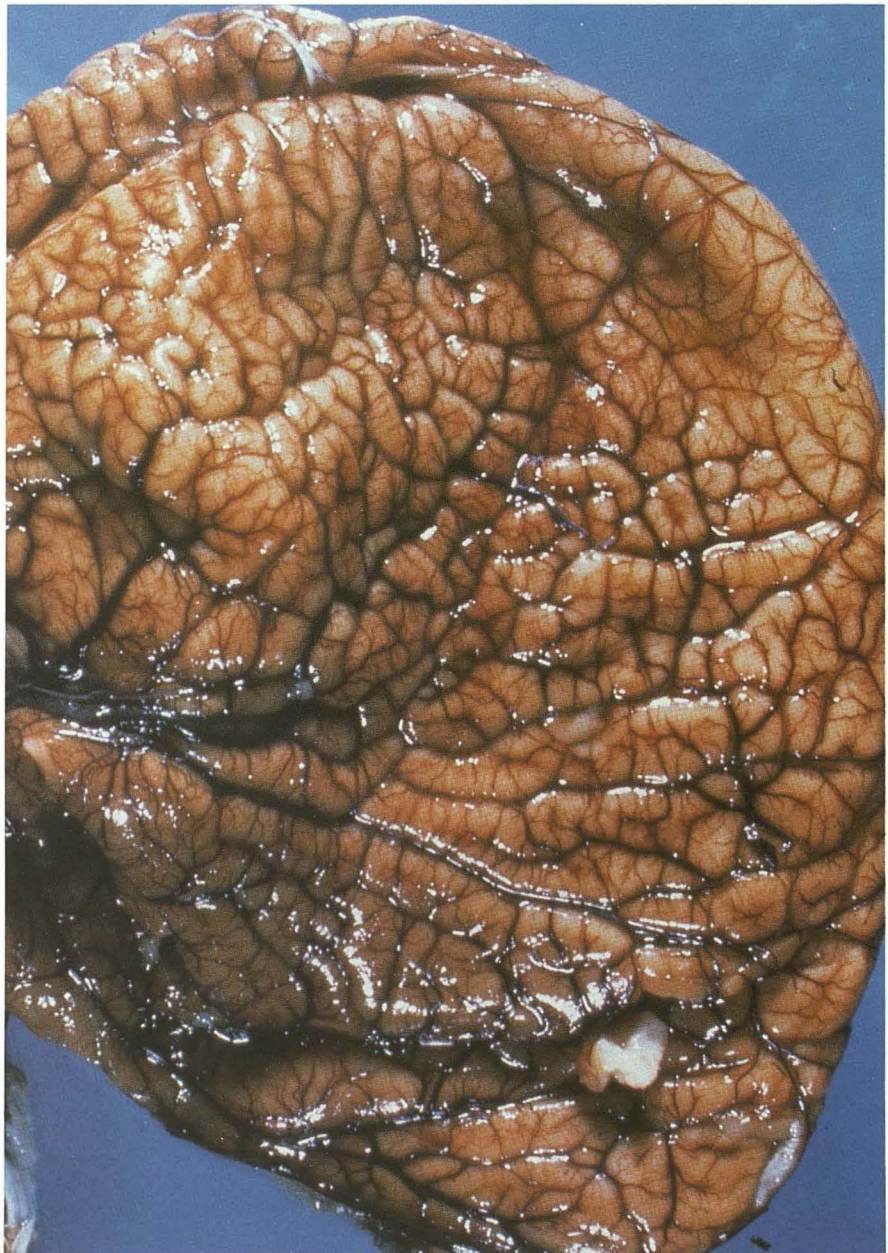
B, Sagittal T1 MR of a Chiari II brain, oriented like B, shows polygyria.

C, Lateral surface of a Chiari II brain shows marked polygyria.



A

B



C

level of the hypophysis, forming the primitive cavernous sinus.

At 80-mm crown rump length, the fetus has an adult pattern. Expansion of the cerebral hemispheres and otic capsule causes the superior petrosal sinus to appear. This is the last definitive sinus to appear.

The basal cerebral vein forms from the transverse telencephalic, diencephalic, and mesencephalic veins (Fig. 15). This is the most important vein at the base of the brain.

Venous changes occurring subsequently depend on the expansion of the cerebral hemispheres and late ossification of the skull. The pattern of drainage will continue to shift even into adulthood.

The Chiari II Malformation of the Hindbrain and the Associated Pan-CNS Anomalies

The Chiari II malformation of the hindbrain is almost invariably associated with a myelomeningocele (43–46); this complex hindbrain malformation is the principal cause of death in children with myelomeningocele, despite surgical intervention and aggressive medical management (47, 48). The precise cause of the clinical manifestations of the Chiari II malformation may relate to the dysplasia of the brain stem and intrinsic “wiring” defects in the human newborn, and to progressive hydrocephalus and/or hindbrain compression in the infant or older child.

Previous theories of the Chiari II malformation have described the cause of the malformation in structural and mechanical terms. In the Chiari II hindbrain malformation, the cerebellar vermis is displaced downward below the foramen magnum into the cervical canal; the brain stem is elongated, kinked, and displaced into the cervical canal; the fourth ventricle is elongated and displaced below the foramen magnum; and the superior cerebellum lies above the opening in the dysplastic low-lying tentorium. Approximately 20% of children with myelomeningocele develop symptoms of hindbrain, cranial nerve, and spinal cord compression. The majority of clinical manifestations of Chiari II malformation occur in infancy, usually before the age of 3 months (49). In addition to the typical hindbrain abnormalities, multiple cerebral anomalies also occur (Table 1).

We have studied the initial development defects of the Chiari II malformation in embryos of mutant mice with a genetically abnormal neurulation: the delayed *Spotch* (*Spd/Spd*) mouse em-

bryo with a sacral neural tube defect. At selected time points in the progression of Chiari II malformation, cellular events were studied by light microscopy, scanning electron microscopy, and fluorescein isothiocyanate (FITC)-lectin cytochemistry using low-intensity video microscopy. On the basis of these studies, we suggest that 1) a series of interrelated time-dependent defects occurs in the development of the primitive ventricular system and that 2) defects in or mistiming of these events result in the Chiari II malformation and the associated pan-CNS anomalies. We offer a unified theory of the cause of Chiari II malformation of the hindbrain and of the associated pan-CNS anomalies (50). The theory examines the cell biology and the developmental neurobiology of the brain and emphasizes the developmental sequence and consequences of six key events. 1) The neural folds fail to neurulate completely, leaving a dorsal myeloschisis. This abnormal neurulation is a prerequisite for later development of the Chiari II malformation. 2) Failure of correct timing of apposition of the walls of the spinal cord with consequent failure to occlude the spinal neurocele transiently (or excessive drainage of “ventricular” CSF through the neural tube defect after the neurocele reopens) leads to 3) failure to maintain distention of the primitive ventricular system because fluid escapes out through the neural tube defect. 4) Lack of distention of the rhombencephalic vesicle alters the inductive effect of pressure and volume on the surrounding mesenchyme and on the endochondral bone formation, thereby resulting in a small posterior fossa. Consequently, the development of the cerebellum and the brain stem within a small posterior fossa leads to (a) upward herniation, resulting in an enlarged incisural opening and a dysplastic tentorium, and to (b) downward herniation, resulting in a large foramen magnum and caudal displacement of the cerebellar vermis and brain stem into the cervical segments. 5) Failure to maintain distention of the primitive ventricular system supratentorially leads to (a) close approximation of the thalami with consequently large massa intermedia, (b) inadequate support for the normal outward migration of neuroblasts with consequent migration defects, and (c) failure to maintain the normal radial pattern of collagen formation and ossification in the developing calvarium, leading to *luckenschadel*. 6) Hydrocephalus is *secondary* to maldevelopment of the CSF pathway in the posterior fossa. More specifically:

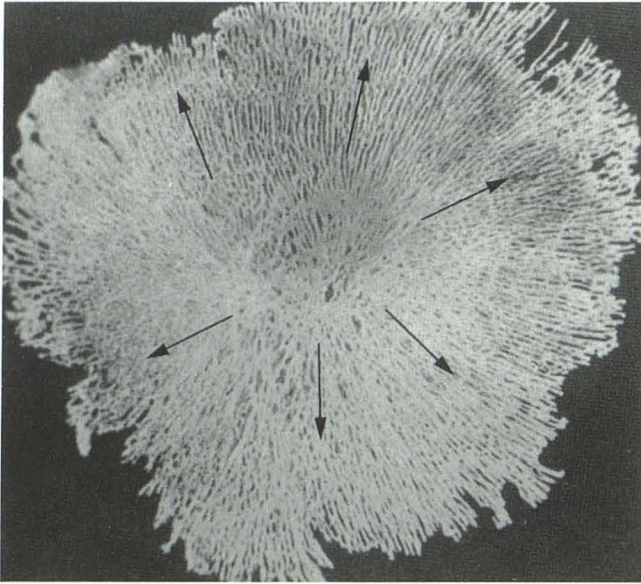


Fig. 19. Specimen of a normal fetal parietal plate shows the radial distribution (arrows) of the collagen bundles that radiate from the growth center.

1. *Neurulation defect*: A defect in neurulation is an a priori feature of the Chiari II malformation. In our experimental model, the homozygous delayed Splotch mouse, the most common neural tube defect is sacral. Frequently, the rhombencephalic roof is collapsed, which indicates that the primitive ventricular system was not distended.

2. *Failure to occlude the spinal neurocele transiently*: The neurocele is the name given to the central cavity of the developing CNS. Normally, there is transient occlusion of the spinal neurocele as a result of a transient apposition of the medial walls of the spinal cord during cord and brain development in humans (51–53), mice (54), and chicks (55–59). Scanning electron micrographs of the midthoracic region of normal embryos at gestation day-11 show partial apposition of the medial walls and apparent closure of the ventral portion of the spinal neurocele. This normal, transient occlusion appears to be necessary to retain CSF within the developing brain and to expand the primitive ventricular system.

The transient occlusion of the neurocele is similar in basic cell biology to the process of neural tube closure in that both require cell recognition and adhesion. In animals with abnormal neurulation, the process of occlusion appears to be similarly defective, and may be delayed or inadequate. Nondistension or collapse of the primitive ventricular system could also result from incomplete occlusion of the spinal neurocele, too short a period of occlusion of the spinal

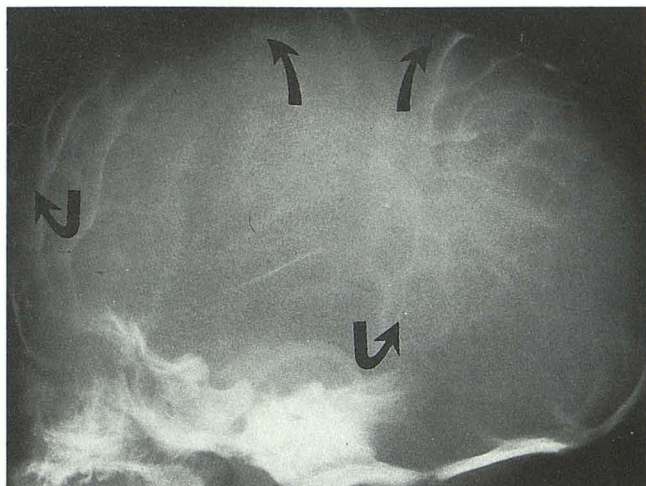
neurocele or excessive drainage of CSF out of the neural tube defect after reopening of the occluded spinal neurocele. A spectrum of such abnormalities should be anticipated.

3. *Failure to maintain distension of the primitive ventricular system*: Because the neural tube does not close properly and because the occlusion of the spinal neurocele is abnormal, CSF escapes down the central canal of the neural tube into the amniotic cavity. Therefore, the primitive ventricular system decompresses and collapses. In the homozygous Splotch embryo with a neural tube defect, lack of occlusion results in *partial distension* of the mesencephalic and rhombencephalic vesicles and reduced size of the lateral and third ventricles.

The expansion of the primitive ventricular system appears to be required to provide the mechanical support for outward migration of neuroblasts and for expansion of the surrounding mesenchyme, permitting it to condense into cartilage or into bone of a size appropriate to future growth. The distension of the rhombencephalic vesicle appears to be required to *anticipate* the future growth of the cerebellum and to provide sufficient room for it to develop. In human embryos at 35 days gestation, for example, the posterior fossa has formed in cartilage and has a fixed volume, even though the cerebellar hemispheres are just beginning to develop from the rhombic lips. Failure of the primitive cranial ventricular system to distend results in a posterior fossa that is too small to accommodate the future growth of the cerebellum.

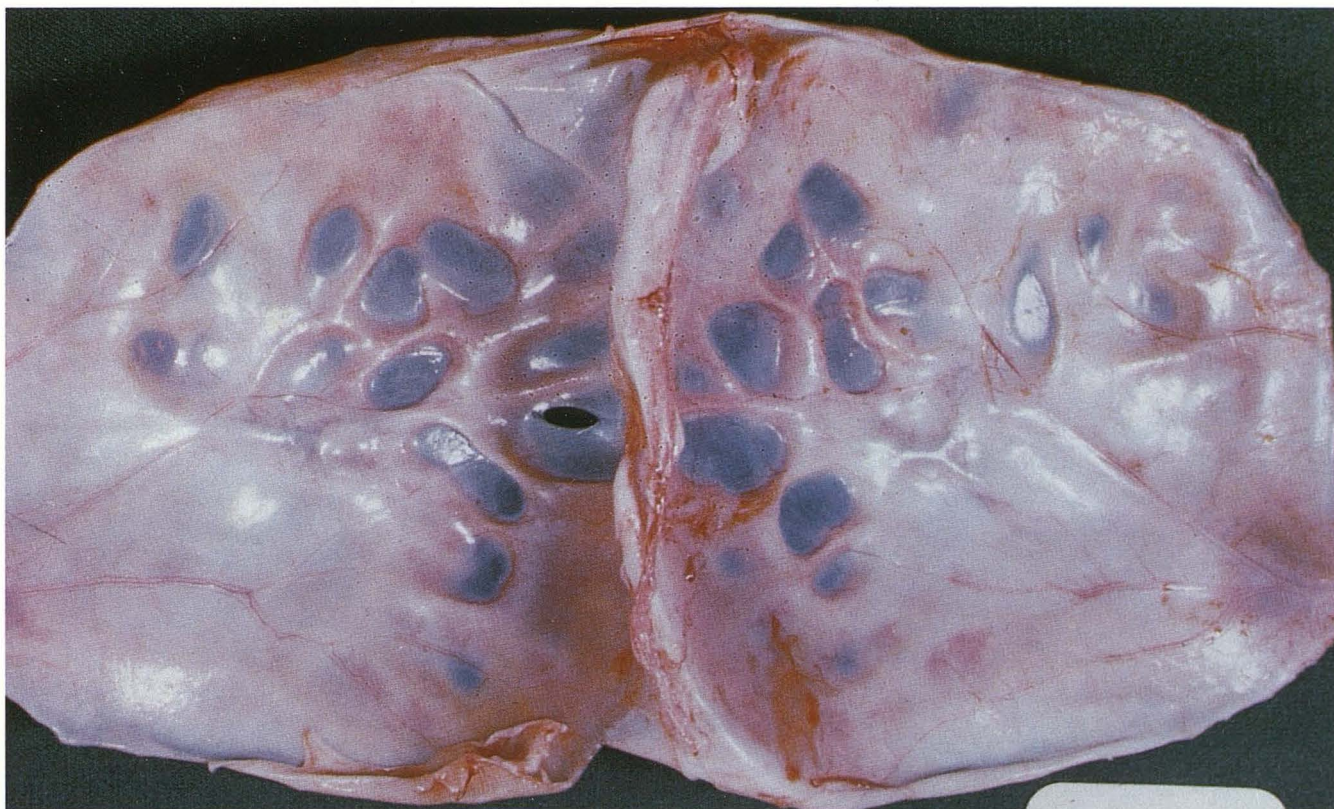
4. *Chiari II malformation*: Initially, at 11 days gestation, the effect of this lack of distension on the developing hindbrain appears minimal. The failure of distention of the rhombencephalic ventricle leaves the basal cranial mesoderm without the inductive force necessary for the normal development of the posterior fossa and its contents, especially the future growth of the cerebellum (60, 61). At the time that occlusion of the spinal neurocele should normally occur, the mesenchyme surrounding the rhombencephalon contains no collagen. It is made up of widely dispersed cells with large extracellular spaces. Therefore, the mesenchyme is pliable and responds easily to distention by the underlying neural mass.

In the Chiari II patients, the volume of the posterior fossa is determined by a nondistended rhombencephalon. Within days, the mesenchyme surrounding the partially collapsed rhombencephalic vesicle condenses. Collagen and cartilage



A

Fig. 20. Chiari II malformation shows the typical radiologic (A) and pathologic (B) findings of "luckenschadel" (curved arrows) in which the radial growth of bone is altered.



B

form, and endochondral bone formation begins. The clivus develops abnormally (62), and the foramen magnum is large. The volume of the posterior fossa is then fixed and inadequate (63). The tentorium is left low and deficient; consequently, the pontine flexure cannot form. Growth of the brain displaces the junction of the brain stem and spinal cord below the foramen magnum (Figs. 16 and 17). The angle of the brain stem is altered. It is also likely that the lack of expansion of the rhombencephalic ventricle influences brain

stem development, producing disorganization of the cranial nerve nuclei and of their afferent and efferent connections.

The short gestational period of the delayed Splotch mouse and the trypan blue-injected rat limits the magnitude of the deformity (64, 65). However, the direction of deformation is identical to that seen in the human Chiari II malformation.

5. *Mechanical effects of failure to distend the third and lateral ventricles:* Mechanical forces are known to exert intrinsic effects on cellular syn-

thesis; eg, compression and tension are factors in the induction of calcification and bone formation (66). As a result of failure of the development of the primitive ventricular system, a transcranial disorganization occurs, leading to diverse malformations. The third ventricle fails to distend, so the thalami remain approximated and in contact to form a large massa intermedia (Fig. 16). The lateral ventricles fail to distend and thereby fail to support the developing telencephalon. The lack of support for the developing telencephalic hemispheres results in gray matter heterotopia, disorganization of future cerebral gyri, and dysgenesis of the corpus callosum (Figs. 16 and 18). In experimental animals (54, 60) if the fluid is vented from the telencephalic ventricles, the developing cerebral cortex becomes disorganized. Mechanical support by the primitive ventricle appears to be essential to normal organization of the cerebral cortex.

Normal development of the membranous skull requires distention of the underlying neural mass (ie, the developing brain and ventricular system). The skull develops from centers in each cranial plate. As the brain expands, collagen bundles are drawn out from those centers in an orderly radial fashion, much like the uniform expansion of the surface of an inflating balloon. As the radial expansion proceeds, the collagen bundles ossify (Fig. 19). In children born with a myelomeningocele, the collagen bundles form whorls and coils instead of radial lines. The fibrous tissue between these whorls has varying thickness. Ossification of the disorganized collagen mat produces the luckenschadel skull (Fig. 20), which is almost invariably seen with myelomeningocele. Late in gestation or postnatally, developing hydrocephalus and/or normal growth and expansion of the neural mass remodels the skull plates, so the luckenschadel disappears.

6. *Hydrocephalus*: There is increasing evidence that the extracellular matrix and the cellular activity of the cerebrospinal outflow pathway are influenced by time-dependent inductive factors (67, 68). A series of morphogenetic and biochemical events yields a functional outflow pathway. The cause of hydrocephalus in the Chiari II malformation may be variable (69). An obstruction of the outlets of the fourth ventricle (70), a block at the cerebral aqueduct (71), obliteration of the subarachnoid space at the level of the foramen magnum by the herniated hindbrain with caudal displacement of the outlets of the fourth ventricle (46), and/or obstruction at the

level of the dysplastic tentorium may block outflow of CSF and, consequently, may contribute to the hydrocephalus.

Study of the first 100 children born with a myelomeningocele and treated by us showed that 25% had head circumferences less than the fifth percentile *at birth* (72). Only after closure of the back did the head circumference increase rapidly. As crowding progresses in the posterior fossa, CSF outflow from the fourth ventricle is occluded. This is especially true at the level of the large incisural opening at the deficient tentorium, where a block is most often seen in the newborn (69). Consequently, hydrocephalus is likely to be secondary to mistimed developmental steps in the development of the ventricular system. The hydrocephalus is the *result* of the Chiari II hind-brain malformation and the associated pan-CNS anomaly. It is *not* the cause of the malformation.

Our unified theory incorporates the observation of Padgett (73) and Padgett and Lindenberg (74) that leakage of CSF is one factor in the cause of a small posterior fossa and emphasizes the role of distention of the embryonic and fetal ventricular system in normal cerebral development (51–53). The theory identifies the neural tube defect and the defective occlusion of the spinal neurocele as the developmental factors that cause the Chiari II malformation and the interrelated cerebral and skull anomalies. The Chiari II malformation and luckenschadel are the result of altered inductive pressure on the surrounding mesenchyme, whereas the cerebral anomalies, eg, dysgenesis of the corpus callosum, large massa intermedia, cortical heterotopia, and polygyria, are the result of lack of distention of the developing telencephalic vesicles. Thus, Chiari II malformation is a result of a series of interrelated time-dependent defects in the development of the ventricular system, which leads to multiple anomalies of brain development.

References

1. Bondarref W, McLone DG, Decker SJ. Ultrastructure of gliopathia in the brains of mice and men. *Anat Rec* 1973;175:487
2. Johnston MC. The neural crest in vertebrate cephalogenesis. Ph.D. Thesis. University of Rochester, Rochester, NY 1965
3. Hay ED. Organization and fine structure of epithelium and mesenchyme in the developing chick embryo. In: Gleitschmajer R, Billingham RE, eds. *Epithelial-mesenchymal interactions: 8th Hahnemann Symposium*. Baltimore: Williams & Wilkins, 1968:1–30
4. Weed LH. The development of the cerebro-spinal spaces in pig and in man. *Contrib Embryol Carnegie Inst* 1917;5:3–116
5. McCabe JS, Low FN. The subarachnoid angle: an area of transition in peripheral nerve. *Anat Rec* 1969;164:15–34
6. Dudley HR, Spiro D. The fine structure of bone cells. *J Biophys*

- Biochem Cytol* 1961;11:627-650
7. Engstrom A. Structure of bone from the anatomical to the molecular level. In: *Bone structure and metabolism*. London: Churchill, 1956: 3-13
 8. Cooper ERA. Nerves of the meninges and choroid plexus. *Ciba Found Symp* 1958;80-96
 9. Penfield W, McNaughton F. Dural headache and innervation of the dura mater. *Arch Neurol Psychiatry* 1940;44:43-75
 10. Peters A, Palay SL, Webster HF. The fine structure of the nervous system. New York: Hoeber, 1970:105-119
 11. Pease DC, Schultz RL. Electron microscopy of rat cranial meninges. *Am J Anat* 1958;102:301-321
 12. Ramsey HJ. Fine structure of the surface of the cerebral cortex of human brain. *J Cell Biol* 1965;16:323-333
 13. Low FN. Microfibrils: fine filamentous components of the tissue space. *Anat Rec* 1962;142:131-137
 14. Dandy WE. Intracranial arterial aneurysms. *Am J Anal* 1944;2: 137-150
 15. Tandler J. Zur Entwicklungsgeschichte der kopfartern bei den mammalia. *Morphol Jahrb* 1902;30:275-373
 16. Mall FP. On the development of blood-vessels of the brain in the human embryo. *Am J Anat* 1905;4:1-18
 17. Keibel F, Mall FP. Manual of human embryology. Vol 2. Philadelphia: 1912
 18. Streeter GL. The developmental alterations in the vascular system of the brain of the human embryo. *Contrib Embryol* 1918;8:5-38
 19. Congdon ED. Transformation of the aortic-arch system during the development of the human embryo. *Contrib Enzymol* 1922;14: 47-110
 20. Padget DH. The development of the cranial arteries in the human embryo. *Contrib Embryol* 1948;32:205-261
 21. Padget DH. The cranial venous system in man in reference to development, adult configuration, and relation to the arteries. *Am J Anat* 1956;98:307-356
 22. Padget DH. The development of the cranial nervous system in man, from the viewpoint of comparative anatomy. *Contrib Embryol* 1957; 36:79-140
 23. Stoeter P, Drews U. Vorgeburtliche entwicklung der firnvenene und sinus mit varianten und dysplasien. *Radiologe* 1983;23:273-283
 24. Hassler O. Deep cerebral venous system in man. *Neurology* 1966; 16:504-511
 25. Kaplan HA. Arteries of the brain: an anatomic study. *Acta Radiol* 1956;23:364-370
 26. Kaplan HA, Ford DH. The brain vascular system. Amsterdam: Elsevier, 1966
 27. DeVriese B. Sur la signification morphologique des artères cérébrales. *Arch Biol* 1905;21:257-457
 28. Bremer JL. Congenital aneurysms of the cerebral arteries: an embryologic study. *Arch Pathol* 1943;35:819-831
 29. Duckett S. The establishment of internal vascularisation in the human telecephalon. *Arch Anat* 1971;80:107-113
 30. Sterzi G. Die Blutgefasse des ruckenmarks: Untersuchungen uber ihre vergleichende anatomie und entwicklungsgeschichte. *Anat Hefte* 1904;24:1-364
 31. Hoskins ER. On the vascularization of the spinal cord of the pig. *Anat Rec* 1914;8:371-391
 32. Tilney F, Casamajor L. The development of the hemal channels in the central nervous system of the albino rat. *Anat Rec* 1917;11: 326-328
 33. Luna E. Studi sulla morfologia delle arterie dell'encefalo. II. Morfologia e morfogenesi delle arterie profonde del bulbo e del ponte. *Ric Morfol* 1920;1:37-95
 34. Williams RG. The development of vascularity in the hind-brain of the chick. *J Comp Neurol* 1937;66:77-102
 35. Wislocki GB. The unusual mode of development of the blood vessels of the opossum's brain. *Anat Rec* 1939;74:409-428
 36. Feeney LF, Watterson RL. The development of the vascular pattern within the walls of the central nervous system of the chick embryo. *J Morphol* 1946;78:231-303
 37. Niemineva K. On the capillary net of the human cerebral hemispheres during the early fetal period. *Ann Med Exp Biol Fenn* 1950;28:262
 38. Sensenig EC. The early development of the meninges of the spinal cord in human embryos. *Contrib Enzymol* 1950;34:145-158
 39. Strong LH. The early embryonic pattern of internal vascularization of the mammalian cerebral cortex. *J Comp Neurol* 1964;123:131-138
 40. Caley DW, Maxwell DS. Development of blood vessels and extracellular spaces during postnatal maturation of rat cerebral cortex. *J Comp Neurol* 1970;138:31-48
 41. Gillilan LA. Anatomy and embryology of the arterial system of the brain stem and cerebellum. In: Vinken PJ, Bryun GW, eds. *Handbook of clinical neurology*. Vol 11. Amsterdam: North-Holland, 1972: 24-44
 42. Gillilan LA. The arterial blood supply of the human spinal cord. *J Comp Neurol* 1958;110:75-103
 43. Chiari H. Über Veränderungen des Kleinhirns infolge von Hydrocephalie des Grosshirns. *Dtsch Med Wochenschr* 1891;17:1172-1175
 44. Chiari H. Über Veränderungen des Kleinhirns, der Pons und der Medulla oblongata infolge von congenitaler Hydrocephalie des Grosshirns. *Denkschr Akad Wiss Wien* 1895;63:71-115
 45. Cleland J. Contribution to the study of spina bifida, encephalocele, and anencephalus. *J Anat Physiol* 1883;17:257-292
 46. Ingraham FD, Scott HW Jr. Spina bifida and cranium bifidum. V. The Arnold-Chiari malformation: a study of 20 cases. *N Engl J Med* 1943; 229:108-114
 47. Hoffman HJ, Neill J, Crone JR, Hendrick EB, Humphreys RP. Hydro-syringomyelia and its management in childhood. *Neurosurgery* 1987; 21:347-351
 48. McLone DG, Naidich TP. Myelomeningocele: outcome and late complications. In: McLaurin RL et al, eds. *Pediatric neurosurgery*. 2nd ed. Philadelphia: Saunders, 1989:53-70
 49. Bell WO, Charney EB, Bruce DA, Sutton LN, Schut L. Symptomatic Arnold-Chiari malformation: review of experience with 22 cases. *J Neurosurg* 1987;66:812-816
 50. McLone DG, Knepper PA. The cause of Chiari II malformation: a unified theory. *Pediatr Neurosci* 1989;15:1-12
 51. Desmond ME. Description of the occlusion of the spinal cord lumen in the early human embryos. *Anat Rec* 1982;204:89-93
 52. Muller F, O'Rahilly R. The development of the human brain from a closed neural tube at stage 13. *Anat Embryol* 1988;177:203-224
 53. O'Rahilly R, Gardner E. The initial development of the human brain. *Acta Anat* 1979;104:123-133
 54. Kaufman MH. Occlusion of the neural lumen in early mouse embryos analyzed by light and electron microscopy. *J Embryol Exp Morphol* 1983;78:211-228
 55. Desmond ME, Jacobsen AG. Embryonic brain enlargement requires cerebrospinal fluid pressure. *Dev Biol* 1977;57:188-198
 56. Facheco MA, Marks RW, Schoenwolf GG, Desmond ME. Quantification of the initial phases of rapid brain enlargement in the chick embryo. *Am J Anat* 1986;175:403-411
 57. Schoenwolf GC, Desmond ME. Descriptive studies of occlusion and reopening of the spinal canal of the early chick embryo. *Anat Rec* 1984;209:251-263
 58. Schoenwolf GC, Desmond ME. Neural tube occlusion precedes rapid brain enlargement. *J Exp Zool* 1984;30:405-407
 59. Schoenwolf GC, Desmond ME. Timing and positioning of reopening of the occluded spinal neurocele in the chick embryo. *J Comp Neurol* 1986;246:459-466
 60. Coulombre AJ, Coulombre JL. The role of mechanical factors in brain morphogenesis. (abstr). *Anat Rec* 1958;130:289-290
 61. Jelinek R, Pexieder T. Pressure of the CSF and the morphogenesis

- of the CNS. *Folia Morphol (Praha)* 1970;18:102-110
62. Yu HC, Deck MDF. The clivus deformity of the Arnold-Chiari malformation. *Radiology* 1971;101:613-615
 63. McLone DG. The subarachnoid space: a review. *Child's Brain* 1980;6:113-130
 64. Gunberg DL. Spina bifida and the Arnold-Chiari malformation in the progeny of trypan blue injected rats. *Anat Rec* 1956;126:343-367
 65. Van den Akker S. Arnold-Chiari malformation in animals. *Acta Neuropathol* 1962;1(suppl):39-44
 66. Moss ML. Functional anatomy of cranial synostosis. *Child's Brain* 1975;1:22-33
 67. Knepper PA, McLone DG. Glycosaminoglycans and outflow pathways of the eye and brain. *Pediatr Neurosci* 1985;12:240-251
 68. Vanden Hoek TL, Goossens W, Knepper PA. Fluorescence labeled lectins, glycoconjugates, and the development of the mouse AOP. *Invest Ophthalmol Vis Sci* 1987;28:451-458
 69. French BN. Midline fusion defects of formation. In: Youmans JR, ed. *Neurological surgery*. 2nd ed. Vol 3. Philadelphia: Saunders, 1982: 1236-1380
 70. Russell DS, Donald C. The mechanism of internal hydrocephalus in spina bifida. *Brain* 1935;58:203-215
 71. Lichtenstein BW. Distant neuroanatomic complications of spina bifida (spinal dysraphism): hydrocephalus, Arnold-Chiari deformity, stenosis of the aqueduct of Sylvius, etc., pathogenesis and pathology. *Arch Neurol Psychiatry* 1942;47:195-214
 72. McLone DG, Raimondi AJ, Sommers MW. The results of early treatment of 100 consecutive newborns with myelomeningocele. Proceedings of the VII Congress of European Society for Paediatric Neurosurgery. *Z Kinderchir* 1981;2:115-117
 73. Padgett DH. Development of so-called dysraphism: with embryologic evidence of clinical Arnold-Chiari and Dandy-Walker malformations. *Johns Hopkins Med J* 1972;130:127-165
 74. Padgett DH, Linderberg R. Inverse cerebellum morphogenetically related to Dandy-Walker and Arnold-Chiari syndromes: bizarre malformed brain with occipital encephalocele. *Johns Hopkins Med J* 1972;131:228-246