

MR Findings in Two Presumed Cases of Mild Central Pontine Myelinolysis

Yukunori Korogi,¹ Mutsumasa Takahashi,¹ Jintetsu Shinzato,¹ Yuji Sakamoto,¹ Katsuhiko Mitsuzaki,¹ Toshinori Hirai,¹ and Kazuhiro Yoshizumi¹

Summary: The authors describe two patients with presumed central pontine myelinolysis whose clinical symptoms were mild despite extensive intrapontine lesions evident on MR imaging. Enhancement of the lesions with Gd-DTPA was not observed in either case. It is suggested that the severity of findings on MR imaging does not necessarily reflect the severity of clinical symptoms of the disease.

Index terms: Demyelinating disease; Degenerative brain disease; Brain stem, magnetic resonance

Central pontine myelinolysis (CPM) was described by Adams et al in 1959 (1). This disorder was originally thought to be uniformly fatal, but there have been recent reports of survival (2–8). Occasionally, there are mild cases with atypical clinical courses such as lack of disturbed consciousness and complete recovery from neurologic deficit (4, 9).

In this report, we present two mild cases of presumed CPM and discuss the magnetic resonance (MR) findings including follow-up examinations and Gd-DTPA enhancement studies.

Case Reports

Case 1

A 38-year-old man, with a history of diabetes mellitus and chronic renal failure with hemodialysis for the previous 13 months, presented with dizziness, weakness of the right hand, and difficulty with speech immediately after hemodialysis. A day before the onset of symptoms, electrolytes revealed only mild hyponatremia (serum sodium of 131 mEq/L). Two days later, serum sodium was 134 mEq/L. Other laboratory tests were normal, except for decreased renal function (blood urea nitrogen of 76.2 mg/dL and creatinine of 10.3 mg/dL). His symptoms gradually improved; when he was referred to a neurologist 14 days after the onset of symptoms he was neurologically intact. MR imaging performed 19 days following the onset revealed lesions compatible with CPM (Figs. 1A–1C). There

was no enhancement of the lesion with Gd-DTPA. Extrapontine involvement was not observed on MR images.

Eight months after onset, the patient was neurologically normal and the pontine abnormality persisted on the T2-weighted scan (Fig. 1D), although the size and intensity of the lesion was diminished, and no enhancement of the lesion was observed on T1-weighted MR images. A diagnosis of CPM was established by the combination of an acute brain stem dysfunction and neuroradiologic features, including follow-up studies.

Case 2

A 52-year-old man with a history of alcohol abuse and diabetes mellitus developed mild dysarthria and dysphagia without disturbed consciousness. Initial MR imaging 3 days following the onset demonstrated intrapontine hyperintensity on T2-weighted images (Figs. 2A–2C). Serum electrolytes before the onset were not measured, but 3 days after the onset there was mild hyponatremia (serum sodium of 130 mEq/L). Other laboratory tests were normal except for blood sugar.

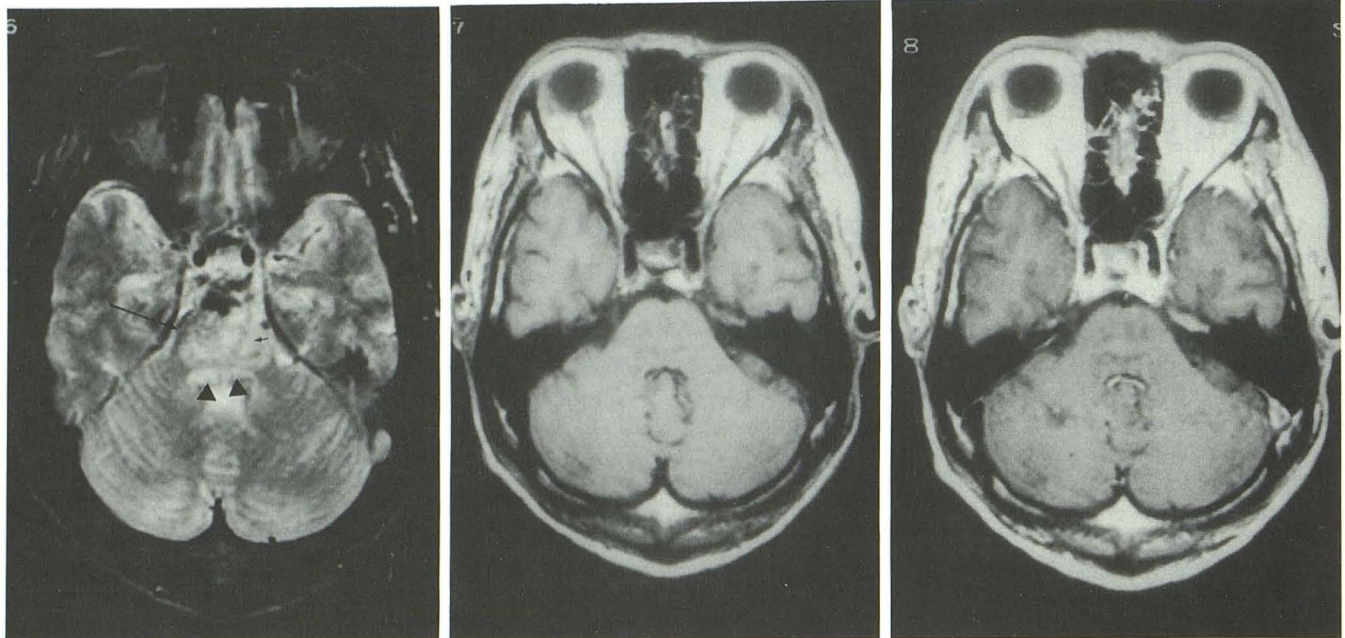
When he was admitted to the hospital 2 weeks following the onset of symptoms neurologic examination revealed mild dysarthria, mild limb ataxia, and hypoactivity of deep tendon reflexes. A second MR study on admission showed findings similar to those on the initial MR study. His condition gradually improved, and 2 months later, neurologic examination revealed only mild ataxia with generalized muscular hypotonia. Follow-up MR imaging at that time demonstrated no significant changes compared with the initial MR examination (Fig. 2D). All three MR examinations demonstrated lack of enhancement of the lesion on post-contrast study. Extrapontine involvement was not observed on any MR image. A diagnosis of CPM was established on the basis of acute brain stem dysfunction with typical neuroradiologic features.

Discussion

CPM is a disorder of demyelination that has a predilection for the basis pontis (1). This process

Received February 11, 1992; revision requested March 26; final revision received June 30 and accepted July 6.

¹ Department of Radiology, Kumamoto University School of Medicine, 1-1-1 Honjo, Kumamoto 860, Japan. Address reprint requests to Y. Korogi.



A

B

C

D

Fig. 1. Case 1.

A, Axial T2-weighted MR image, 3000/80/1 (TR/TE/excitations), demonstrates a hyperintense area in the basis pontis (*short arrow*) accompanied with mild swelling of the pons. Lateral regions (*long arrow*) are spared, while the pontine tegmentum is hyperintense (*arrowheads*).

B, Axial T1-weighted MR image (550/13/1) demonstrates no abnormal intensity within the pons.

C, Axial T1-weighted gadolinium-enhanced MR image (550/13) shows no enhancement in the pons.

D, Axial T2-weighted MR image (3000/80), obtained 8 months following the onset, demonstrates a persistent hyperintensity (*arrow*), although the size and intensity of the lesion are diminished.

is most often found in patients with a history of alcoholism (1, 10), but also has been found in patients with electrolyte abnormalities (especially rapidly corrected hyponatremia) (10, 11). The clinical manifestations include spastic quadriplegia, pseudobulbar palsy, and rapid development of the so-called locked-in state (1, 6, 10, 11).

The typical histopathologic features include symmetric demyelination of the basis pontis, spreading centrifugally from the median raphe. There is sparing of the ventrolateral longitudinal fibers, neurons, axis cylinders, and blood vessels.

In severe cases, there may be necrosis and cavitation, as well as extension of the lesion into the pontine tegmentum and midbrain (6, 10, 12).

There is no proven explanation for the pathogenesis of CPM, but Norenberg (13) and Koci et al (14) have noted lesions in areas of rich gray-white matter apposition. They propose that osmotically induced endothelial changes result in myelinotoxic factors and/or edema derived from gray matter.

This disorder was originally thought to be uniformly fatal. However, there have been recent

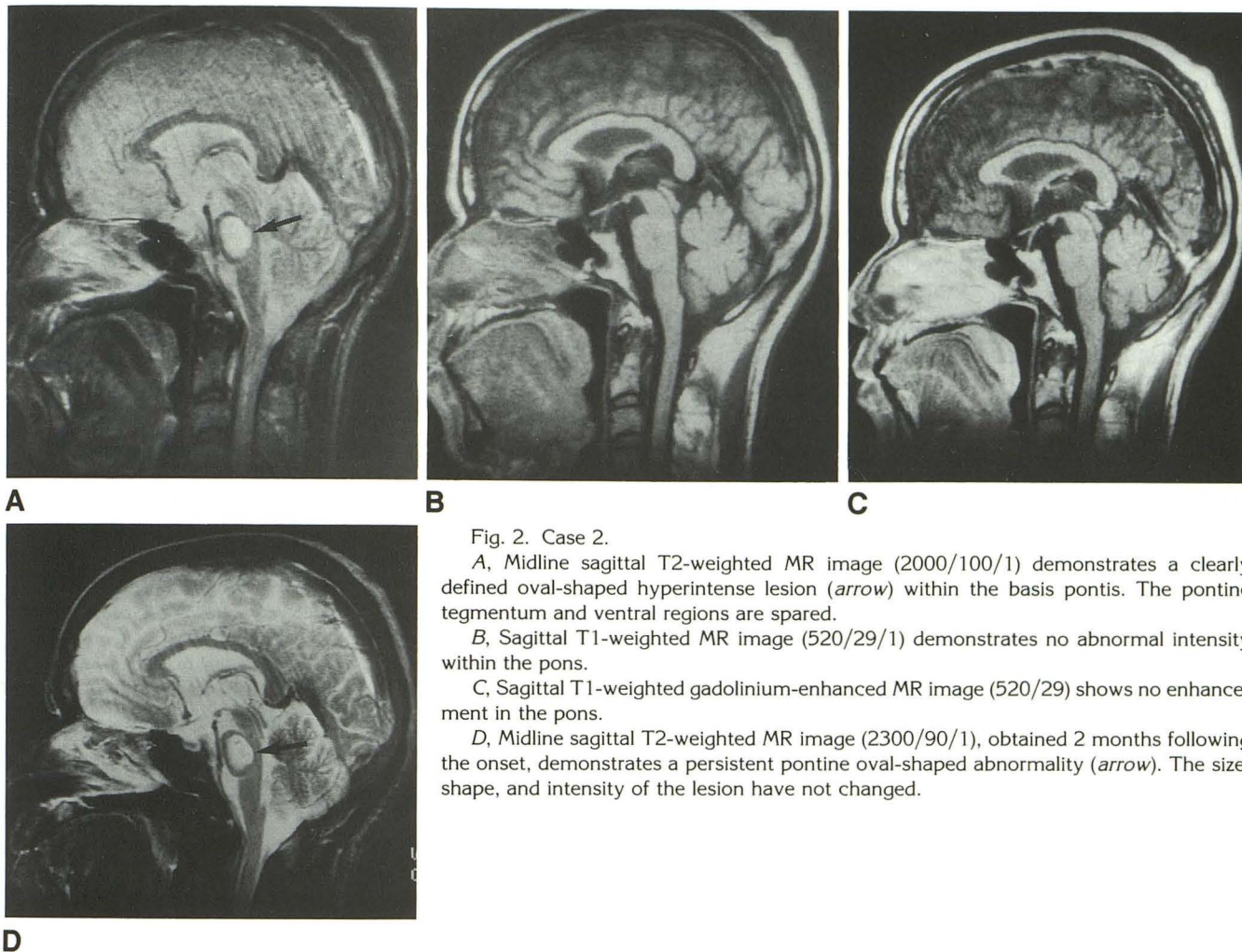


Fig. 2. Case 2.

A, Midline sagittal T2-weighted MR image (2000/100/1) demonstrates a clearly defined oval-shaped hyperintense lesion (*arrow*) within the basis pontis. The pontine tegmentum and ventral regions are spared.

B, Sagittal T1-weighted MR image (520/29/1) demonstrates no abnormal intensity within the pons.

C, Sagittal T1-weighted gadolinium-enhanced MR image (520/29) shows no enhancement in the pons.

D, Midline sagittal T2-weighted MR image (2300/90/1), obtained 2 months following the onset, demonstrates a persistent pontine oval-shaped abnormality (*arrow*). The size, shape, and intensity of the lesion have not changed.

reports of longer survivals or atypical mild cases (2–8). Our cases showed mild clinical courses despite extensive intrapontine hyperintense areas on T2-weighted MR images. There have been few reports of cases without locked-in state or tetraplegia (4).

The clinical manifestations of CPM were thought to vary from minimal to complete locked-in syndrome or coma according to the extent of the lesions (15). However, Pfister et al proposed that there was dissociation between the severity of neurologic dysfunction and the extension of the computed tomography or MR lesion (4). Our observation supports the hypothesis that there is a lack of correlation between the severity of the MR findings and the clinical manifestations. Our cases lacked the episodes of hyponatremia and intravenous infusion therapy, which are also atypical. A case similar to ours, in which CPM developed after hemodialysis, has been reported (9).

Since our cases were atypical by being clinically mild, they bring into question the criteria on which to establish the diagnosis of CPM. There are many diseases that may present with MR features of CPM such as age-related hyperintense foci, normal pressure hydrocephalus, infarction, glioma, metastases, encephalitis or encephalopathy, postradiation therapy, postchemotherapy, multiple sclerosis, acute disseminated encephalomyelitis, adrenoleukodystrophy, and dementia (6). Our patients did not show any clinical findings compatible with encephalitis, and did not receive radiation therapy or chemotherapy. The acute onset of symptoms in both cases was argument against the possibility of brain tumors. Pontine glioma or metastases were also excluded by the fact that the lesion diminished despite no treatment in case 1. Pontine infarction or demyelinating disease like multiple sclerosis would cause more severe neurologic deficit with an extensive pontine lesion such as in our cases. Follow-up

MR studies were also atypical for infarction, tumor, or multiple sclerosis.

There have been several reports of the MR appearance of CPM that describe a symmetric round- or oval-shaped area of prolonged T1 and T2 relaxation within the base of the pons on sagittal images, with sparing of the pontine tegmentum and ventrolateral pons (5–8). Extrapontine lesions may be observed in the basal ganglia, thalami, and subcortical white matter (14).

The enhancement of CPM lesions with Gd-DTPA has been described in two cases. One report describes ring-like enhancement (16); the other showed no enhancement (14). In our cases, no enhancement was observed, although MR imaging was obtained in the acute, subacute, and chronic phases. The gadolinium enhancement might be related to the clinical severity of CPM, because clinical findings in our cases were mild. The cardinal pathologic changes of CPM, loss of myelin with preservation of axons and blood vessels, in the absence of a significant inflammatory reaction (10, 12), might explain the lack of enhancement.

The persisting abnormal signals in CPM have been observed in almost all cases by follow-up examinations (5–8). However, the lesion may resolve completely, especially when it is very small, possibly accounting for the normal MR findings reported in two patients at 6 and 7 weeks of follow-up (4, 6). Persistence of CPM lesions on MR imaging with clinical recovery is likely due to fibrillary gliosis, and may be an important finding for the differential diagnosis in follow-up studies (8).

In conclusion, MR and clinical findings in our two CPM cases are characterized by: 1) lack of an episode of rapid correction of hyponatremia, 2) extremely mild neurologic deficit without tetraplegia or locked-in state despite extensive pontine lesions on MR imaging, 3) lack of Gd-DTPA enhancement, and 4) persisting abnormal MR findings despite complete or near complete clinical recovery.

References

1. Adams RD, Victor M, Mancall EL. Central pontine myelinolysis: a hitherto undescribed disease occurring in alcoholic and malnourished patients. *Arch Neurol Psychiatry* 1959;81:154–172
2. Stam J, van Oers MHJ, Verbeeten B Jr. Recovery after central pontine myelinolysis. *J Neurol* 1984;231:52–53
3. Schroth G. Clinical and CT confirmed recovery from central pontine myelinolysis. *Neuroradiology* 1984;26:149–151
4. Pfister HW, Einhaupl KM, Brandt T. Mild central pontine myelinolysis: a frequently undetected syndrome. *Eur Arch Psychiatry Neurol Sci* 1985;235:134–139
5. Rippe DJ, Edwards MK, D'Amour PG, Holden RW, Roos KL. MR imaging of central pontine myelinolysis. *J Comput Assist Tomogr* 1987;11:724–726
6. Miller GM, Baker HL Jr, Okazaki H, Whisnant JP. Central pontine myelinolysis and its imitators: MR findings. *Radiology* 1988;168:795–802
7. Ragland RL, Duffis AW, Gendelman S, Som PM, Rabinowitz JG. Central pontine myelinolysis with clinical recovery: MR documentation. *J Comput Assist Tomogr* 1989;13:316–318
8. Thompson PD, Miller D, Gledhill RF, Rossor MN. Magnetic resonance imaging in central pontine myelinolysis. *J Neurol Neurosurg Psychiatry* 1989;52:675–677
9. Udaka F, Tsuji T, Shigematsu K, Kawamata T, Kameyama M. Spontaneous complete recovery in a case of central pontine myelinolysis which developed following hemodialysis (in Japanese). *Shinkei Naika* 1988;29:268–272
10. Messert B, Orrison WM, Hawkins MJ, Quagliari CE. Central pontine myelinolysis: considerations on etiology, diagnosis, and treatment. *Neurology* 1979;29:147–160
11. Sterns RH, Riggs JE, Schochet SS Jr. Osmotic demyelination syndrome following correction of hyponatremia. *N Engl J Med* 1986;314:1535–1542
12. Kalnins RM, Berkovic SF, Bladin PF. Central pontine myelinolysis with wide spread extrapontine lesions: a report of two cases. *Clin Exp Neurol* 1984;20:189–202
13. Norenberg MD. A hypothesis of osmotic endothelial injury: a pathogenetic mechanism in central pontine myelinolysis. *Arch Neurol* 1983;40:66–69
14. Koci TM, Chiang F, Chow P, et al. Thalamic extrapontine lesions in central pontine myelinolysis. *Am J Neuroradiol: AJNR* 1990;11:1229–1233
15. Valk J, van der Knaap MS. Central pontine and extrapontine myelinolysis. In: Valk J, van der Knaap MS, eds. *Magnetic resonance of myelin, myelination, and myelin disorders*. Berlin: Springer-Verlag, 1989:253–262
16. Koch KJ, Smith RR. Gd-DTPA enhancement in MR imaging of central pontine myelinolysis. *Am J Neuroradiol: AJNR* 1989;10:S58