

## Phase III Multicenter Trial of High-Dose Gadoteridol in MR Evaluation of Brain Metastases

William T. C. Yuh, David J. Fisher, Val M. Runge, Scott W. Atlas, Steven E. Harms, Kenneth R. Maravilla, Nina A. Mayr, Joan E. Mollman, and Ann C. Price

**PURPOSE:** To assess the efficacy and safety profile of high-dose (0.3 mmol/kg cumulative dose) gadoteridol in patients with suspected central nervous system metastatic disease. **METHODS:** We studied 67 patients using an incremental-dose technique. Patient monitoring included a medical history, physical examination, vital signs, and extensive laboratory tests within 24 hours before and after the MR examination. Precontrast T1- and T2-weighted spin-echo studies were performed, followed by intravenous injection of 0.1 mmol/kg of gadoteridol. T1-weighted images were acquired immediately after and at 10 and 20 minutes after injection. At 30 minutes an additional 0.2 mmol/kg of gadoteridol was administered (0.3-mmol/kg cumulative dose), and T1-weighted images were acquired. Cases demonstrating abnormal MR findings were assessed for efficacy by unblinded and blinded reviewers and were analyzed quantitatively. **RESULTS:** Three adverse effects in two patients were considered to be related to gadoteridol administration. No adverse effects were serious; all self-resolved. Forty-nine cases showed abnormal MR findings and were included in the efficacy analysis. A significantly greater number of lesions was seen on the high-dose as opposed to the standard-dose images. Blinded and unblinded readers identified 5 and 8 patients, respectively, with solitary lesions on standard-dose examination and multiple lesions on high-dose examination. Two patients who had normal standard-dose findings had lesions identified on high-dose studies. Quantitative analysis of 133 lesions in 45 patients demonstrated significant increases in lesion signal intensity on high-dose studies when compared with standard-dose studies. **CONCLUSION:** Gadoteridol can be safely administered up to a cumulative dose of 0.3 mmol/kg. High-dose contrast studies provide improved lesion detectability and additional diagnostic information over studies performed in the same patients with a 0.1-mmol/kg dose and aid in patient diagnosis and treatment. High-dose gadoteridol study may facilitate the care of patients with suspected central nervous system metastasis.

**Index terms:** Brain neoplasms, magnetic resonance; Brain neoplasms, metastatic; Contrast media, nonionic; Efficacy studies; Magnetic resonance, contrast enhancement, Magnetic resonance, in treatment planning

*AJNR Am J Neuroradiol* 15:1037-1051, Jun 1994

---

Received December 22, 1992; accepted pending revision February 16, 1993; revision received July 14.

This work was supported in part by grants to each participating institution from Squibb Diagnostics.

From Department of Radiology, The University of Iowa College of Medicine, Iowa City (W.T.C.Y., D.J.F. N.A.M.); Department of Radiology, The University of Kentucky Medical Center, Lexington (V.M.R.); Department of Radiology, University of Pennsylvania, Philadelphia (S.W.A., J.E.M.); Department of Radiology, Baylor University Medical Center, Dallas, Tex (S.E.H.); Department of Radiology, The University of Washington, Seattle (K.R.M.); and Department of Radiology, Albany Medical Center (A.C.P.).

Address reprint requests to William T. C. Yuh, MD, MSEE, Department of Radiology, The University of Iowa, Hospitals and Clinics, Iowa City, IA 52242.

*AJNR* 15:1037-1051, Jun 1994 0195-6108/94/1506-1037

© American Society of Neuroradiology

Since the introduction of magnetic resonance (MR) contrast agents, primarily gadopentetate dimeglumine (Magnevist, Berlex Laboratories, Wayne, NJ), the evaluation of central nervous system pathologic processes has been greatly facilitated (1-19) (Haustein J, Bauer W, Hilbertz T, et al, Dosing of Gd-DTPA in MR Imaging of Intracranial Tumors: a Randomized Double-Blind Multicenter Study in 90 Cases, presented at the 9th Annual Meeting of the Society of Magnetic Resonance in Medicine, New York, 1990). Significant improvement in intracranial lesion detectability and conspicuity (lesion contrast, lesion size, and border definition) has been reported with the

use of gadopentetate dimeglumine at a dose of 0.1 mmol/kg.

Recently, the MR contrast agent gadoteridol (gadolinium 1,4,7-*tris*-(carboxymethyl)-10-(2'-hydroxypropyl)-1,4,7,10-tetraazacyclododecane; ProHance; Squibb Diagnostics, Princeton, NJ) has been studied in phase II and III clinical trials. Gadoteridol is nonionic (neutral) and has lower osmolality and greater in vitro chelate stability than gadopentetate dimeglumine (20–22). Phase II trials and preliminary results from phase III trials have shown that gadoteridol can be administered safely at doses up to 0.3 mmol/kg and that increased lesion contrast, delineation, and detection can be obtained at higher doses without increased adverse effects (20, 22–26). In this paper we report the cumulative results of the multicenter phase III trials of gadoteridol in the MR evaluation of brain metastases.

The purpose of this study was to evaluate the safety profile and clinical efficacy of high-dose gadoteridol. The specific study goals were to: (a) expand the safety profile and patient tolerance profile of gadoteridol at the 0.3-mmol/kg dose; (b) determine whether high-dose gadoteridol (0.3-mmol/kg cumulative dose) can improve lesion detectability, provide additional diagnostic information, and aid in patient diagnosis and treatment; and (c) evaluate quantitatively differences between precontrast, standard-dose, standard-dose delayed, and high-dose studies.

## Materials and Methods

This study was a phase III, open-label pilot study conducted at five investigational sites (Baylor University, University of Washington, Albany Medical Center, University of Kentucky, and The University of Iowa). Patients with radiologic evidence (angiography, computed tomography [CT], and MR studies) and/or clinical suspicion of brain metastases were recruited into this study. Patients excluded from the study included patients younger than 18 or older than 76 years of age, pregnant or lactating women, patients who had undergone contrast-enhanced MR procedures within the previous 48 hours, patients with histories of sensitivity to MR contrast media, and patients normally excluded from MR studies because of pacemaker implants, aneurysm clips, any other condition that would preclude proximity to a strong magnetic field, or severe claustrophobia. All patients involved in this study gave informed consent and were studied in compliance with a protocol approved by the institutional review board at each participating site.

Imaging was performed with either medium-field (0.5-T) or high-field (1.5-T) units. Precontrast examinations included at least one spin-echo axial T1-weighted and one

spin-echo axial T2-weighted study. T1-weighted images were acquired at 10–22/350–600/1–2 (repetition time/echo time/excitations). T2-weighted images were 90–100/2000–4000/0.5–2. All imaging was performed using a 22- to 24-cm field of view and a 256 × 192 to 256 × 256 matrix size. A section thickness of 5 mm (1.5 T) or 10 mm (0.5 T) was used.

After the precontrast examinations, each patient received an initial bolus injection of 0.1 mmol/kg (standard dose) of gadoteridol. T1-weighted images were obtained immediately and at 10 and 20 minutes after the initial injection. At 30 minutes, an additional bolus injection of 0.2 mmol/kg of gadoteridol was administered (cumulative dose of 0.3 mmol/kg), and high-dose T1-weighted images were obtained immediately after injection. All postcontrast MR examinations were performed using scanning protocols identical with those of the T1-weighted precontrast studies, including the same section plane, spacing, and thickness.

## Safety Monitoring

Patient monitoring included history, physical examination, vital signs, and extensive laboratory tests within 24 hours before the MR examinations. Blood analysis consisted of a complete blood count (hemoglobin level, hematocrit, mean corpuscular volume, and total leukocyte count, including differential and platelet count), blood chemistry (glucose, creatinine, urea nitrogen, calcium, phosphorus, uric acid, total cholesterol, total protein, albumin, total bilirubin, alkaline phosphatase, serum glutamic oxaloacetic transaminase, lactic dehydrogenase, serum glutamic pyruvic transaminase, and  $\gamma$ -glutamyl transpeptidase), electrolytes (sodium, potassium, and chloride), a clotting function panel (prothrombin time and partial thromboplastin time), and an iron metabolism panel (serum iron and iron binding capacity). Urinalysis included evaluation of pH, specific gravity, protein, glucose, blood, and ketones and microscopic examination of sediment. The patients' vital signs were checked immediately before the precontrast MR studies, immediately after the completion of all MR examinations, and 2 hours after the administration of gadoteridol. Twenty-four hours after the administration of gadoteridol, patient monitoring, including a physical examination, vital signs, and all laboratory tests, was repeated. Vital-sign changes after the dose were considered abnormal if blood pressure changed by more than 10% from baseline, respiration changed more than 20%, or temperature changed more than 1°C. Laboratory results from each postinjection sample were compared directly with preinjection results to identify any abnormal change.

## Visual Assessment

The study of high-dose gadoteridol efficacy included visual assessment of lesion detection as well as assessment of any additional information provided by high-dose gadoteridol studies and the influence of that information on patient diagnosis and management. Images were assessed visually using both an unblinded and blinded evaluation

method. The unblinded radiologists at each of the five clinical trial sites evaluated precontrast and postcontrast images to determine whether the patient had MR findings consistent with metastatic disease. The unblinded radiologists had full access to patient information and were allowed to evaluate all the examinations at the same time, including the precontrast T1- and T2-weighted studies, standard-dose studies, and high-dose studies. In each of the examinations, diagnostic quality was assessed, and evidence of cerebral metastases was described. The unblinded reviewers counted the number of lesions present in each of these three studies. A lesion was defined as an area with abnormal signal or abnormal parenchymal enhancement that did not appear as a thin linear structure in contiguous sections (blood vessel).

The blinded efficacy assessment was performed by a neuroradiologist (S.W.A.) and a neurooncologist (J.E.M.). Neither physician had any affiliation with the study sites or any other connection with the clinical study. The blinded neuroradiologist was unaware of the patients' identities, doses of gadoteridol, clinical and laboratory results, and the identities of the sites that produced the images. Precontrast T1- and T2-weighted images were evaluated and compared with the standard-dose and high-dose studies in a manner similar to the unblinded evaluation. Image sets, however, were randomized by both clinical site and gadoteridol dose. The neuroradiologist read the film sets in random pairs: precontrast versus standard-dose, precontrast versus high-dose, and standard-dose versus high-dose studies. The neuroradiologist also determined the number of lesions present in each study, but did so for each random pair of imaging studies. The blinded reviewer, therefore, assessed each study twice. These data were evaluated statistically using the same methods applied to the unblinded lesion-count data.

Lesion detectability at different doses of gadoteridol was evaluated statistically using the lesion-count data for each of the precontrast, standard-dose, and high-dose studies. The Wilcoxon Signed-Ranks Test, a paired-data nonparametric statistic, was used to compare studies.  $P < .05$  was considered significant.

Both the unblinded and blinded radiologists compared the degree of lesion enhancement on postcontrast studies and determined whether additional diagnostic information was provided relative to the precontrast images. The following factors were specifically graded: (a) number of lesions (lesion detection), (b) improved visualization, (c) disease classification, (d) determination of recurrent tumor, (e) distinction of edema, and (f) definition of tumor border. Comparisons were made between precontrast and standard-dose studies and between standard-dose and high-dose studies.

Both the unblinded and blinded reviewers also determined whether the additional diagnostic information provided by the contrast-enhanced MR examinations would assist or change the patient's diagnosis or treatment. Specifically, these data were categorized into one of four groups: (a) assist in diagnosis, (b) change of diagnosis, (c) assist in therapy, and (d) change of treatment. Unblinded

evaluation was performed by a radiologist at each of the five clinical sites. Blinded evaluation was performed by a single neurooncologist who reviewed only those study pairs that the blinded neuroradiologist judged to contain additional information on the postcontrast studies. The neurooncologist was aware of the patients' medical histories but was blinded to the doses of gadoteridol administered.

#### *Quantitative Analysis*

Quantitative image analysis was performed on each T1-weighted study obtained at the five different time points (precontrast, standard-dose, 10- and 20-minute delayed, and high-dose studies). Image data from the five clinical sites were analyzed by a core image-processing facility. Lesion borders were defined by using an automatic edge-detection algorithm on lesions detected on high-dose studies. A maximum of nine lesions was analyzed for each patient. In patients with more than nine lesions, the largest lesions were selected for analysis. The automatically detected lesion border defined the perimeter of a region of interest. Regions of interest for the precontrast, standard-dose, and delayed studies were generated by duplicating region-of-interest locations from the corresponding high-dose study. Image statistics were computed for each region of interest.

For each image containing a region of interest to be analyzed, an additional region of interest delineating the normal brain parenchyma was defined manually. Areas containing lesions were not included in the normal brain parenchyma regions of interest. A normalized lesion-contrast estimate was calculated for each lesion using the lesion mean intensity and the normal brain parenchyma region-of-interest statistics. A normal distribution model was used. Lesion contrast was expressed in terms of the number of standard deviations that the mean lesion contrast deviated from the mean brain parenchyma intensity. This analysis allowed linear-scale factors to be canceled and compensated partially for scan-dependent variations beyond experimental control. Additionally, for each lesion studied, lesion-to-background ratios were computed using the mean signal intensities from the lesion and background regions of interest. A paired, two-tailed Student's *t* test was performed between each of the studies.  $P < .05$  was considered significant.

#### **Results**

A total of 68 patients with suspected intracranial metastatic lesions were enrolled in the study. Thirty-eight of these patients had either prior radiologic or pathologic evidence of metastatic disease. In 32 patients, evidence of metastatic disease was present on prior MR or CT studies. Six patients included in the study had prior pathologically proved metastatic disease demonstrated by either biopsy or resection. Of the 68 patients enrolled in the study, 67 patients re-

ceived gadoteridol and were included in the safety analysis (37 men and 30 women). The age range of these 67 patients was 21 to 76 years (mean,  $57 \pm 11$  years). One of these 67 patients was excluded from the efficacy evaluation because of extravasation of the initial dose of gadoteridol; however, this patient was included in the safety analysis. Sixteen of the 66 patients who received cumulative 0.3-mmol/kg doses of gadoteridol showed no evidence of metastatic disease on either standard- or high-dose MR studies. Each of the 50 remaining patients had at least one lesion demonstrated by MR. Forty-six of these 50 patients had neurologic symptoms. Because of a scanner equipment failure, imaging was not completed in 1 patient with metastatic disease; therefore, 49 patients were included in the unblinded efficacy analysis.

All 49 image sets included in the efficacy analysis portion of the study were judged by the unblinded investigators to be of acceptable diagnostic quality. The blinded reviewer, however, judged one image set in the high-dose to standard-dose randomized comparison inadequate for diagnostic evaluation because of motion artifact in the high-dose study. Summary data, therefore, vary between the unblinded and blinded data with respect to the total number of patients studied.

### *Safety Monitoring*

Four of the 67 patients who received gadoteridol experienced a total of six adverse events after gadoteridol administration. Two of the patients reported adverse events that were considered by the investigators to be only remotely related to gadoteridol injection. One of the patients reported dizziness and a loss of arm coordination after gadoteridol administration; both complaints resolved without intervention. This patient had a left parietal lobe cortical lesion that had caused similar symptoms before administration. A second patient experienced a decline in mental status the day after gadoteridol administration. The patient's serum sodium level was abnormally low at 127 mEq/L in the 24 hours before imaging. As part of the patient's ongoing therapy, additional parenteral hydration was given after the imaging was completed, resulting in a further decrease in the serum sodium level to 121 mEq/L. The decline in mental status was considered by the site investigator to be related to this electrolyte imbalance.

Three adverse events in another two patients were considered probably related to gadoteridol administration by the investigators. One patient experienced nausea and hypotension. This patient's blood pressure was 145/90 mm Hg and heart rate was 96 beats per minute immediately before entering the magnet. The patient's blood pressure had decreased to 100/45 mm Hg and heart rate had decreased to 72 beats per minute 2 hours after gadoteridol administration. The patient's nausea and hypotension resolved without treatment, and no sequelae were noted. Another patient reported a metallic taste in the mouth.

In the 67 patients studied, there were no significant differences between the results of the physical examination performed 24 hours after gadoteridol administration and those of the physical examination performed before dosing except in 1 patient who was recovering after surgery at the time of the second examination. Changes in vital signs (heart rate, temperature, blood pressure, and respiration rate) were considered unremarkable except in the 1 patient who had experienced nausea and hypotension. There were no clinically significant changes between predose and postdose blood chemistry, hematology, or urinalysis laboratory results and no postdose changes that were considered to be related to gadoteridol administration.

### *Visual Assessment*

The visual evaluation data for both unblinded and blinded reviewers are summarized in Tables 1 through 4. There was general agreement between the unblinded and blinded reviewers that the high-dose studies provided improved diagnostic confidence (Figs 1 and 2), lesion detection (Figs 2-5), and additional diagnostic information over the standard-dose studies despite an increase in flow-related artifact (Fig 5). Similar results were also found in standard-dose studies compared with precontrast studies.

*Lesion Detection.* Both the unblinded (Table 1) and blinded (Table 2) reviewers noted that the high-dose studies allowed detection of a greater number of lesions than did the standard-dose studies (51% and 32% increases, respectively) (Figs 1-5), and that the standard-dose studies allowed detection of more lesions than did the precontrast studies (81% and 88% increases, respectively) (Figs 3 and 5). When comparing high-dose with precontrast studies, both unblinded and blinded reviewers noted a dramatic

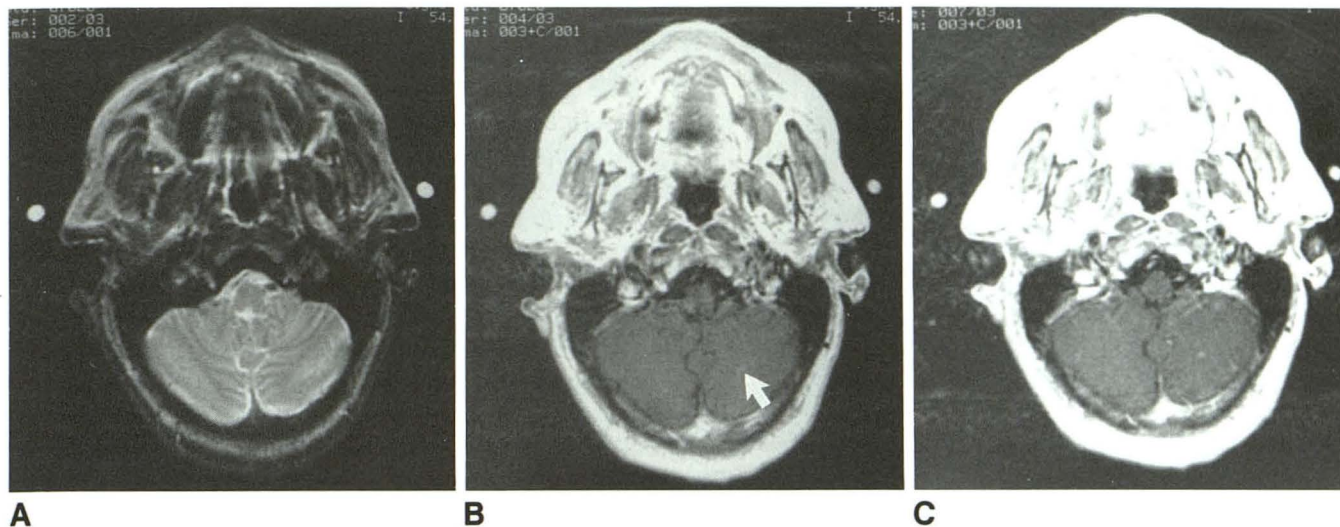


Fig. 1. Improved diagnostic confidence and lesion detection.

A, Axial T2-weighted (2350/90) image shows no significant abnormality.

B, Axial T1-weighted (350/15) initial-dose study demonstrates mild pulsation artifact and a small focal area (*arrow*) with faint enhancement thought to be a possible lesion.

C, The high-dose study shows further enhancement and border delineation of this small lesion (approximately 1.9 mm). There is a possible additional lesion in the right cerebellar hemisphere.

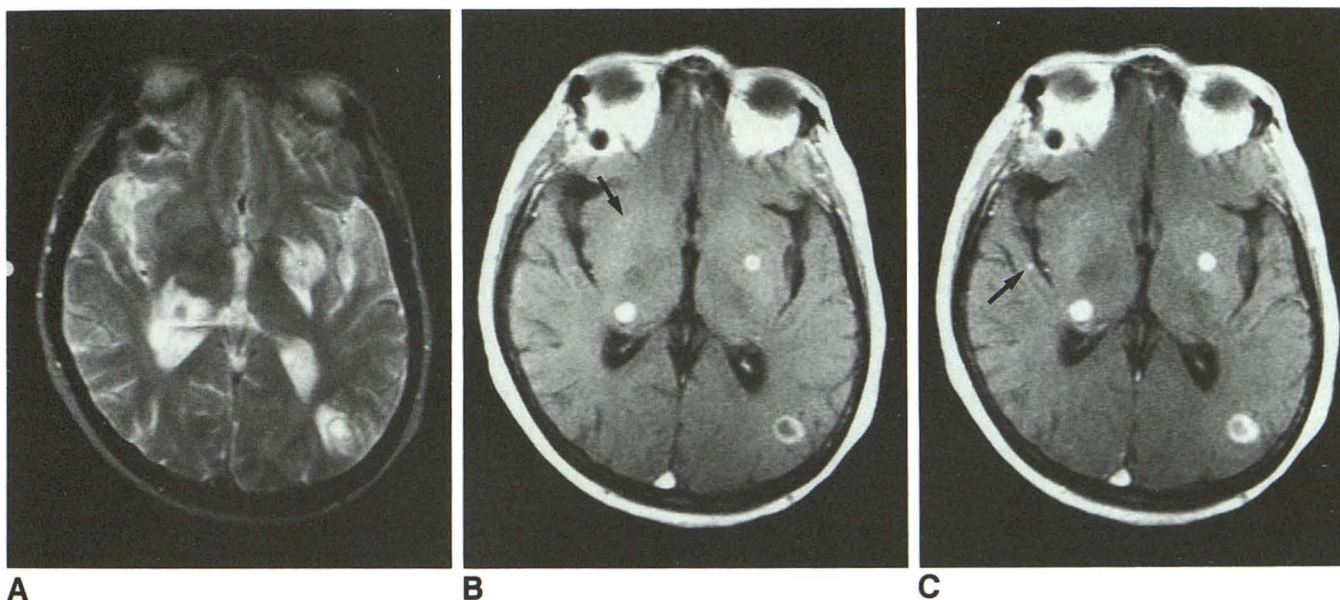


Fig. 2. Increased diagnostic confidence and lesion detection.

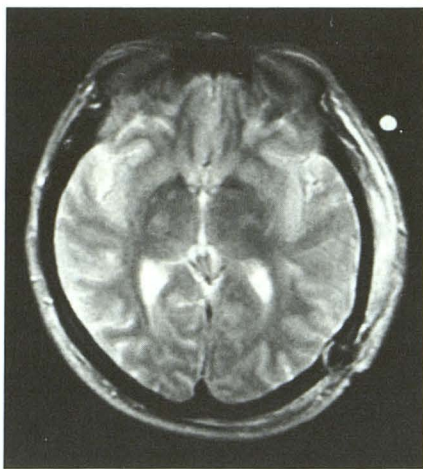
A, Axial T2-weighted (2000/100) image shows multiple areas with abnormal signal.

B, Axial T1-weighted (583/20) initial-dose study shows three enhancing lesions and one possible lesion (*arrow*).

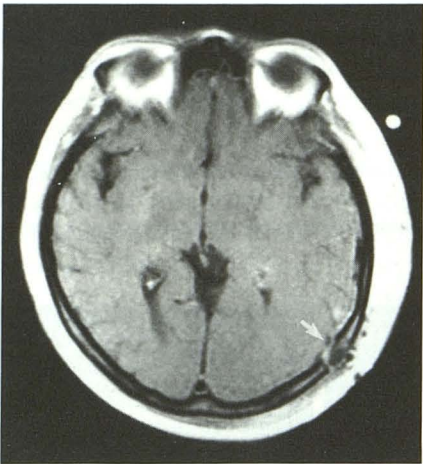
C, High-dose study demonstrates greater enhancement and increased apparent size of these lesions. An additional lesion (*arrow*) in the right temporal lobe was also detected. The questionable lesion noted in the standard-dose study (*B*, *arrow*) did not show further enhancement on the high-dose study. High-dose study yielded improved diagnostic confidence and the exclusion of this lesion.

increase in the number of detectable lesions (173% and 170%, respectively) (Figs 1–5). Because of the large number of metastatic lesions detected in three patients by both unblinded and blinded reviewers, the distribution of the number of lesions in all patients studied with high-dose

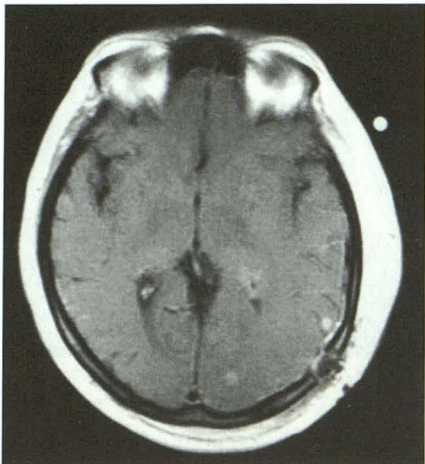
gadoteridol had a large variance and was non-gaussian (Fig 6). Because the paired-difference distributions had similar characteristics, the Wilcoxon Signed-Ranks Test was used in the analysis of the lesion-count data. The differences in the number of lesions detected in the precontrast



A



B



C

Fig. 3. Improved diagnostic confidence and increased lesion conspicuity and detection in a postoperative patient.

A, Axial T2-weighted (spin-echo, 2000/100) image shows postoperative changes in the left parietal region.

B, Axial T1-weighted (spin-echo, 583/20) initial-dose study shows abnormal enhancement in the region of the surgical site (*arrow*). This focal area of faint enhancement suggested a tumor, but postoperative changes could not be completely excluded.

C, High-dose examination demonstrates increased enhancement and border delineation of this left parietal lesion. An additional lesion in the left occipital lobe is also demonstrated.

versus standard-dose, the precontrast versus high-dose, and the standard-dose versus high-dose comparisons were all found to be statistically significant (range,  $P < .0001$  to  $P < .038$ ) in both the unblinded and blinded image evaluations (Tables 1 and 2).

Both interobserver and intraobserver variability is present in the lesion-count data (Tables 1 and 2). These differences are caused primarily by difficulties in counting lesions in the three patients with extensive metastatic disease. One patient was judged by the blinded reviewer to have 111 lesions on the high-dose images when comparing standard-dose with high-dose studies, but the unblinded reviewer counted only 74 lesions. In this same patient's standard-dose images, the blinded reviewer reported 85 lesions when comparing standard-dose with precontrast studies, but only 74 lesions when comparing standard-dose with high-dose studies. Similar difficulties were encountered in two additional patients with extensive cerebral metastases. The statistical analysis remained relatively unaffected by these discrepancies, however, because the Wilcoxon Signed-Ranks Test bases its estimate of significance on relative rank rather than absolute number (Tables 1 and 2).

*Additional Information.* In those patients in whom increases in diagnostic information were noted, the unblinded and blinded reviewers also classified the type of information provided (Table 3). Despite interobserver and intraobserver variability, both unblinded and blinded reviewers found that, when comparing precontrast with standard-dose studies, lesion visualization, border definition, lesion number, disease classification, and distinction of edema improved with the administration of 0.1 mmol/kg of gadoteridol. When comparing the high-dose to standard-dose studies, both unblinded and blinded reviewers noted further improvement in lesion visualization, border definition, and lesion number, although disease classification and distinction of edema were not found to be greatly improved by the high-dose studies. A comparison of the extent (amount) of edema, however, was not made between the studies. The unblinded and blinded reviewers found that neither standard-dose nor high-dose studies allowed determination of recurrent tumor.

There is some variation between the findings of the unblinded and blinded reviewers, predominantly between the precontrast and standard-dose comparisons (Table 3). Many of the stand-

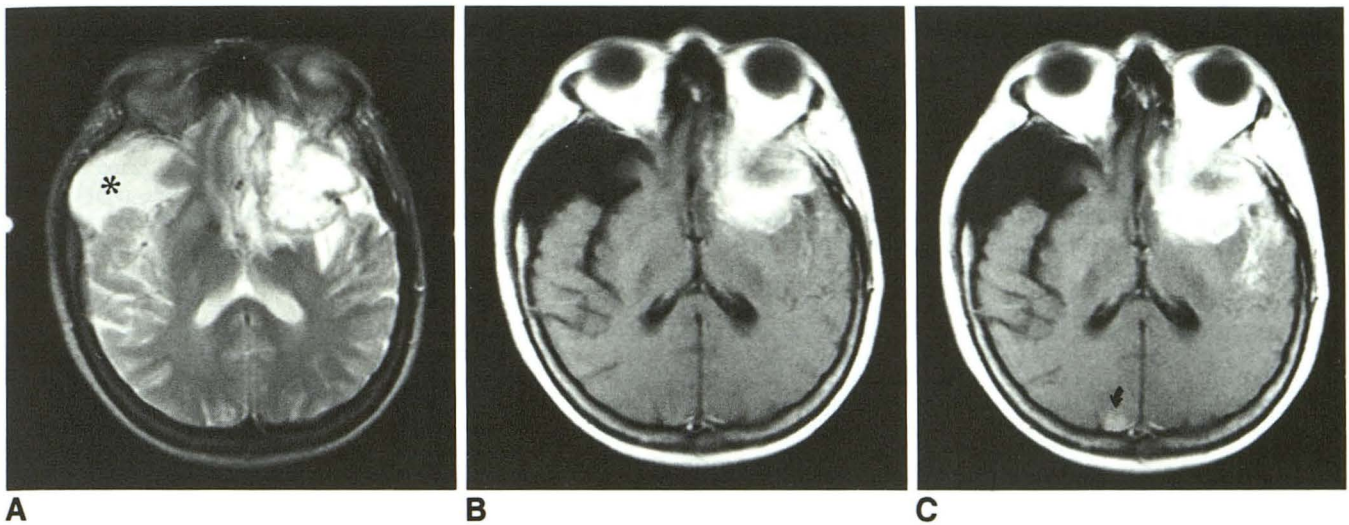


Fig. 4. Increased lesion conspicuity and detection.

A, Axial T2-weighted (2000/100) image shows an area with abnormal signal in the left frontal lobe and a subarachnoid cyst (*asterisk*) near the temporal lobe.

B, Axial T1-weighted (583/20) initial-dose study demonstrates an enhancing left frontal lobe mass and the nonenhancing subarachnoid cyst.

C, High-dose examination shows slightly greater enhancement and improved border definition of the left frontal lobe mass. An additional lesion (*arrow*) was also detected in the right occipital lobe.

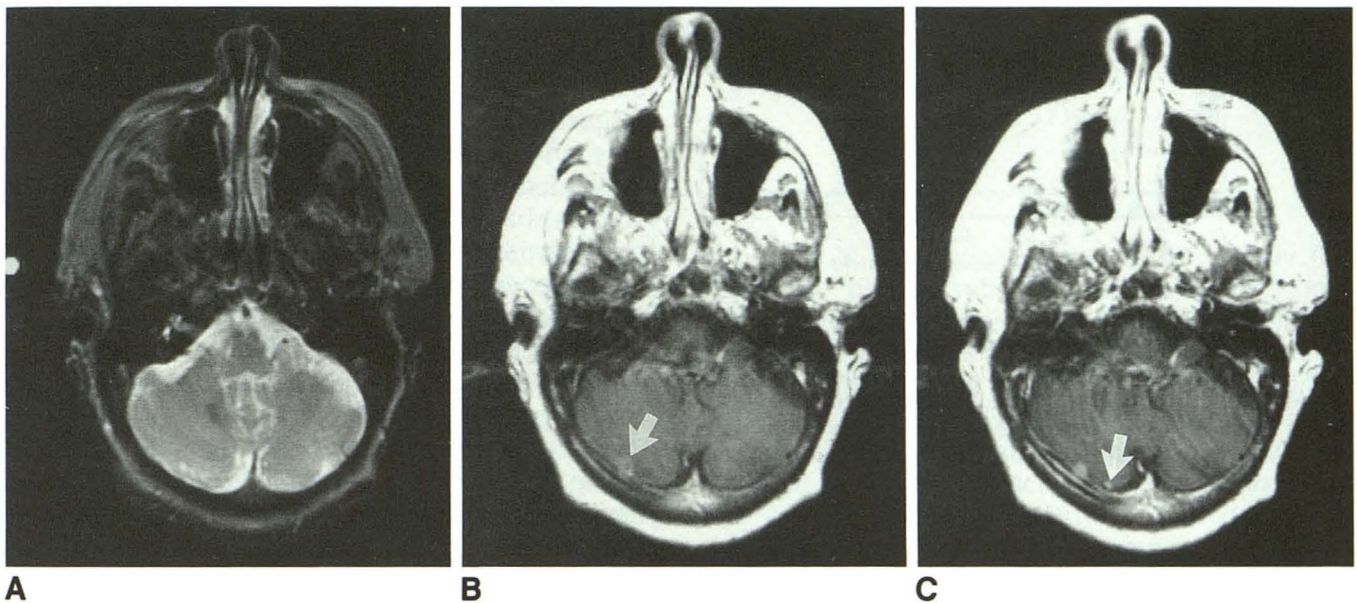


Fig. 5. Improved diagnostic confidence and increased lesion visualization and detection.

A, Axial T2-weighted (2350/90) image shows no significant abnormalities.

B, Axial T1-weighted (350/20) initial-dose study shows pulsation artifact and a possible ring-enhancing lesion in the right cerebellar hemisphere (*arrow*). However, partial-volume effect from the enhancing transverse sinus cannot be completely excluded.

C, High-dose examination clearly defines this area as a metastasis and demonstrates an additional smaller lesion (*arrow*), despite a worsening pulsation artifact.

ard-dose studies, when compared with the pre-contrast studies, were judged by the unblinded reviewers to have increased visualization (78%). The blinded reviewer noted fewer improved studies (41%). This difference between the unblinded

and blinded reviewers' assessments of improved lesion visualization represents 18 of the 49 patients studied (37%) and accounts for the difference in the total percentage of patients judged to have additional information provided (92% versus

TABLE 1: Unblinded reviewers' detection of lesions in 49 patients

|                   | Number of Lesions |             |             | Difference                     |                                |                        |
|-------------------|-------------------|-------------|-------------|--------------------------------|--------------------------------|------------------------|
|                   | Precontrast       | 0.1 mmol/kg | 0.3 mmol/kg | 0.1 mmol/kg versus Precontrast | 0.3 mmol/kg versus Precontrast | 0.3 versus 0.1 mmol/kg |
| Number of lesions | 113               | 204         | 309         | 91                             | 196                            | 105                    |
| P value           |                   |             |             | .0384 <sup>a</sup>             | .0001 <sup>a</sup>             | .0001 <sup>a</sup>     |

<sup>a</sup> Wilcoxon Signed-Ranks Test considered significant at  $P < .05$ .

TABLE 2: Blinded reviewers' detection of lesions

|                   | Number of Lesions                            |  |                                      | Difference                                   |  |                                      |
|-------------------|--|--|--------------------------------------|--|--|--------------------------------------|
|                   | Precontrast versus 0.1 mmol/kg (49 Patients) | Precontrast versus 0.3 mmol/kg (49 Patients) | 0.1 versus 0.3 mmol/kg (48 Patients) | Precontrast versus 0.1 mmol/kg (49 Patients) | Precontrast versus 0.3 mmol/kg (49 Patients) | 0.1 versus 0.3 mmol/kg (48 Patients) |
| Number of lesions | 129 versus 243                               | 116 versus 313                               | 238 versus 315                       | 114  | 197  | 77                                   |
| P value           |  |  |                                      | 0.0009 <sup>a</sup>                          | 0.0001 <sup>a</sup>                          | 0.0001 <sup>a</sup>                  |

<sup>a</sup> Wilcoxon Signed-Rank Test considered significant at  $P < .05$ .

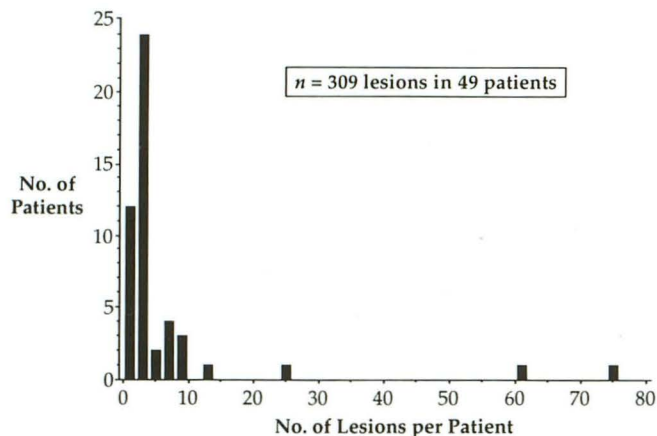


Fig. 6. Distribution of lesion numbers in all patients detected in the high-dose studies by the unblinded reviewers. Many of the lesions included in the lesion detection data came from a small percentage of the total patients studied. For this reason, nonparametric statistics were used to evaluate the lesion-detection data, and a maximum of 10 lesions per patient were included in the quantitative image analysis.

55%). The single blinded reviewer reported a greater increase in distinction of edema over that of the unblinded reviewers when comparing precontrast with standard-dose studies (41% versus 29%, 6 additional patients) but reported 4 fewer patients with increased numbers of lesions than did the unblinded reviewers. When comparing the high-dose with standard-dose studies, however, there was far less variation between the findings of the unblinded and blinded reviewers. Although there was general agreement between the readings, the blinded reviewer noted less improvement in lesion visualization (65% versus 73%)

and greater improvement in disease classification (13% versus 4%).

**Effect on Patient Diagnosis and Treatment.** The impact of the additional information provided by the contrast-enhanced studies on patient diagnosis and treatment was assessed by both unblinded and blinded reviewers (Table 4). Without considering the overall extent of systemic disease present in the patients, but considering only the radiologic findings of the brain, the unblinded reviewers found that standard-dose studies changed or assisted in diagnosis or patient treatment in 84% of the patients when compared with precontrast studies. When comparing high-dose with standard-dose studies, unblinded readers judged that 57% of patients demonstrated lesion enhancement that changed or assisted diagnosis or patient treatment.

The blinded neurooncologist evaluated only the group of studies that the blinded neuroradiologist had indicated as having revealed additional information on the contrast-enhanced images and evaluated studies in random pairs. A total of 27 of 49 precontrast with standard-dose comparisons and 31 of 48 standard-dose with high-dose comparisons were reviewed by the neurooncologist. The blinded neurooncologist was given the patients' histories and was able to consider the overall extent of systemic disease in judging the influence of contrast-enhanced examinations on patient treatment and the additional information provided by the high-dose studies. Therefore, the blinded reviewer generally noted fewer patients who benefited in diagnosis or treatment. In 3 of 31 patients (10%) reviewed by the blinded neu-



TABLE 3: Visual evaluation by blinded and unblinded reviewers

|  | Unblinded Reviewer                                    |   | Blinded Reviewer                                      |   |   |
|--|---|---|---|---|---|
|  | 0.1 mmol/kg versus<br>Precontrast,<br>49 Patients (%) | 0.3 versus<br>0.1 mmol/kg,<br>49 Patients (%) | 0.1 mmol/kg versus<br>Precontrast,<br>49 Patients (%) | 0.3 mmol/kg versus<br>Precontrast,<br>49 Patients (%) | 0.3 versus<br>0.1 mmol/kg,<br>48 Patients (%) |
| Type of additional information                                 |   |   |   |   |   |
| Improved visualization   | 38 (78)   | 36 (73)                                       | 20 (41)   | 24 (49)   | 31 (65)                                       |
| Definition of lesion borders                                   | 40 (82)   | 22 (45)                                       | 25 (51)   | 28 (57)   | 25 (52)                                       |
| Number of lesions  | 21 (43)   | 24 (49)                                       | 17 (35)   | 23 (47)   | 21 (44)                                       |
| Disease classification   | 13 (27)   | 2 (4)   | 13 (27)   | 15 (31)   | 6 (13)  |
| Determination of recurrent tumor                               | 2 (4)   | 1 (2)   | 0 (0)   | 0 (0)   | 0 (0)   |
| Distinction of edema   | 14 (29)   | 0 (0)   | 20 (41)   | 21 (43)   | 1 (2)   |
| Total patients with additional diagnostic information provided | 45 (92)   | 38 (78)                                       | 27 (55)   | 32 (65)   | 31 (65)                                       |

TABLE 4: Aid in patient diagnosis and treatment

|  | Unblinded Reviewer                                    |   | Blinded Reviewer                                      |   |
|--|---|---|---|---|
|  | 0.1 mmol/kg versus<br>Precontrast,<br>49 Patients (%) | 0.3 versus<br>0.1 mmol/kg,<br>49 Patients (%) | 0.1 mmol/kg versus<br>Precontrast,<br>27 Patients (%) | 0.3 versus<br>0.1 mmol/kg,<br>31 Patients (%) |
| Type                                     |   |   |   |   |
| Assist in diagnosis                      | 26 (53)   | 11 (22)                                       | 5 (19)  | 2 (6)   |
| Change in diagnosis                      | 3 (6)   | 3 (6)   | 3 (11)  | 1 (3)   |
| Assist in treatment                      | 33 (67)   | 28 (57)                                       | 5 (19)  | 2 (6)   |
| Change in treatment                      | 6 (12)  | 10 (20)                                       | 5 (19)  | 2 (6)   |
| Total patients with any change or assist | 41 (84)   | 28 (57)                                       | 8 (30)  | 3 (10)  |

neurooncologist, the high-dose images, when compared with the standard-dose images, provided information that assisted or changed patient diagnosis or treatment. The first patient was a 61-year-old woman with a history of breast cancer 30 years previously. She had been recently diagnosed with a right hilar mass and had a 2-month history of headaches. The blinded standard-dose study revealed one cerebral lesion, whereas the blinded high-dose study revealed two lesions. The neurooncologist judged that for a single lesion she would recommend a biopsy to identify primary versus metastatic disease. Finding two lesions on the high-dose study assisted her diagnosis of metastatic disease and changed her recommended treatment. (The blinded reviewer would not recommend a biopsy of the two cerebral lesions.)

The second patient was a 69-year-old woman in whom small-cell carcinoma of the lung was diagnosed 2 years previously. A recent CT scan revealing a suspicious brain mass was markedly different from a previous CT scan done at the

time of her prophylactic brain radiotherapy (30 Gy). The patient recently had developed poor balance, dysarthria, and headaches. The blinded reading of the standard-dose study revealed no cerebral metastases. The high-dose study revealed a single metastatic lesion. The neurooncologist judged that this information would have assisted and changed her diagnosis and assisted her in the patient's treatment. Based on this additional information, she would recommend resection of the isolated lesion.

The third patient was a 56-year-old man who underwent a right nephrectomy for renal-cell carcinoma 1 year previously. At the time of this study, he presented with a 3-day history of right-leg weakness and right-hand clumsiness. The standard-dose study revealed a single cerebral lesion, whereas the high-dose study revealed two lesions. The neurooncologist judged that this information assisted and changed her treatment of the patient. In this case, the presence of two lesions suggested cerebral metastatic disease and precluded recommending surgery for the patient.

In four additional patients, the number of metastatic lesions detected by the blinded reviewer increased from zero to one (one patient) and one to multiple (three patients) when standard- and high-dose studies were compared. Although in these cases the high-dose studies provided essential information that could have resulted in a major change in patient treatment, no alteration of therapy was suggested by the blinded neurooncologist because of widely disseminated metastatic disease outside the brain. In these cases, MR studies of the brain generally would not have been indicated, because the management of these patients would not be changed by MR findings. The unblinded reviewers noted two patients with lesion-number changes from zero to one or more and eight patients with changes from one to multiple. The unblinded reviewers ranked each of these patients as having an assist or change in treatment as a result of information provided by the high-dose examination.

#### Quantitative Analysis

The magnitude of contrast enhancement was evaluated using quantitative image analysis in 45 of the 49 patient-image sets. Three sets of images were excluded from analysis because of patient motion between images. One set was excluded because the archive tape was unreadable. Mean normalized lesion contrast and 95% confidence intervals were plotted for each of the MR study types (precontrast, standard-dose, 10- and 20-minute delayed, and high-dose studies). Quantitative analysis was performed on 133 lesions in 45 patients with metastatic disease (Fig 7). Both the mean normalized lesion contrast and the lesion-to-background ratio increased significantly between each of the five groups, including the delayed imaging studies ( $P < .05$  considered significant). The mean normalized lesion contrast of the high-dose studies increased dramatically from 1.11 to 2.11 SD greater than the mean brain parenchyma intensity when compared with the initial-dose studies ( $P < .0001$ ). The 10- and 20-minute delayed studies demonstrated a slight but statistically significant increase in mean normalized lesion contrast (1.30 and 1.36, respectively) when compared with the immediate initial-dose studies ( $P < .0001$ ) and also were themselves significantly different from one another ( $P < .02$ ). Lesion-to-background ratios followed similar trends.

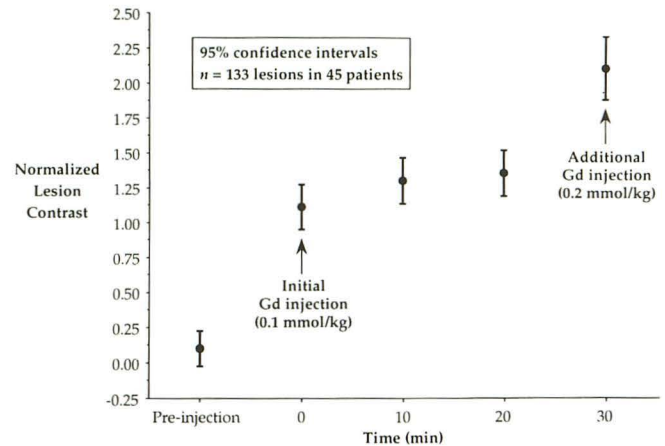


Fig. 7. Quantitative analysis. Mean normalized lesion contrast and 95% confidence intervals are plotted for a total of 133 lesions identified in 45 patients. The normalized lesion contrast increased significantly ( $P < .0001$ ) between precontrast studies and initial-dose studies and also between initial-dose studies and high-dose studies. Both the 10- and 20-minute delayed examinations demonstrated slight but significant increases in mean normalized lesion contrast when compared with the immediate initial-dose studies ( $P < .005$ ).

#### Discussion

Intracranial metastases occur in approximately 25% of patients with cancer and account for up to 40% of all adult brain neoplasms (27, 28). Lung carcinomas, breast carcinomas, and melanomas (in decreasing order) are the most common primary neoplasms that metastasize to the brain (28). Lung carcinomas account for 50% of all primary tumors in patients with intracranial metastatic disease detected by CT (28, 29). The remaining primary tumors include breast carcinomas in 15%, melanomas in 10.5%, pelvic-abdominal carcinomas in 9.5%, other cancers in 4%, and those of unknown origin in 11% (29). Immediately before death, in approximately 72% of patients with melanomas and in 34% of those with lung carcinomas, intracranial metastases developed (27, 30). In a large autopsy series of patients with breast carcinomas, 30% of patients had evidence of intracranial metastases (31). Radiologic examination of the central nervous system during or after diagnosis of primary tumors (especially lung carcinomas, breast carcinomas, and melanomas) is particularly needed for the optimal treatment of the patient.

The period between primary tumor diagnosis and diagnosis of intracranial metastases is usually short. Intracranial metastases are diagnosed before or at the same time as the primary tumors in approximately 20% of patients with cancer (32). Approximately 50% occur within the first

year after diagnosis of the primary tumors, and only 7% occur after 5 years (32). This suggests that many of the lesions may have metastasized to the brain but were too small to be detected by conventional radiologic means at the time of primary-tumor diagnosis. In addition, 50% of all patients with intracerebral metastases will have only single lesions demonstrated on CT or MR (27–29, 33). In these 50%, the detection of additional occult lesions that were not evident on routine radiologic examinations (including CT and standard-dose contrast-enhanced MR) or the reconfirmation of the diagnoses of single metastases by high-dose study may be essential for optimal treatment. Results of this multicenter trial suggest that high-dose MR examination has the potential to provide this information.

Patients with brain metastases, especially in those with small or early lesions, may not present with symptoms. Five percent of patients with carcinomas of the lung who had no neurologic signs or symptoms and who were considered surgical candidates showed evidence of cerebral metastatic disease on CT (34). With improvements in the diagnostic sensitivity in radiology, the true incidence of asymptomatic brain metastasis from lung cancer may be found to be even greater than 5%. The application of high-dose MR studies may increase further the detection of early or small metastases and provide essential information in the subset of patients who show no lesions or only solitary lesions on initial standard-dose MR studies (35, 36). Therefore, a brain-screening technique with improved sensitivity not only may save at least 5% of patients with lung cancer from unnecessary radical operations for primary tumors or presumed solitary brain lesions, but also may be cost-effective (34).

Early studies reported that noncontrast MR detects more lesions than contrast-enhanced CT (37, 38). In cases in which CT was superior to noncontrast MR, the advantage was always related to contrast enhancement on the CT image (37). After the introduction of gadopentetate dimeglumine, contrast-enhanced MR was proved superior to noncontrast MR or contrast CT in detection of cerebral metastases (14, 15, 39) and, therefore, became an essential part of the evaluation of patients with clinically suspected brain metastases.

Although 0.1 mmol/kg of gadopentetate dimeglumine is generally considered the standard dose for contrast-enhanced MR examinations, the optimal dose of gadolinium may vary by proce-

dures (22, 23). Several studies have shown that gadoteridol and gadopentetate dimeglumine demonstrate nearly identical enhancement effects when administered in equal doses (23, 25, 40). Recent clinical studies have compared different doses of gadoteridol (0.05 to 0.3 mmol/kg) with 0.1 mmol/kg of gadopentetate dimeglumine. These studies have demonstrated that higher doses of gadoteridol (0.2 and 0.3 mmol/kg) provide increased lesion enhancement, tissue contrast, border definition, and lesion detection when compared with examinations using 0.1 mmol/kg of gadopentetate dimeglumine (22, 23). Prior study also has shown that 0.1 mmol/kg of gadopentetate dimeglumine had the same advantages over a half-dose (0.05 mmol/kg) of gadoteridol (23). These previous reports support the findings of this study that higher-dose MR study is often more efficacious than lower-dose study.

Safety monitoring during this multicenter phase III trial reinforces earlier findings that gadoteridol has a lower incidence of adverse effects than conventional radiographic contrast agents (22–24, 41). Previous studies investigating the safety and efficacy of gadopentetate dimeglumine have shown that the dose of 0.1 mmol/kg is a well-tolerated, safe, and efficacious dose for imaging intracranial pathologic processes (1, 3–6, 14–16, 19, 42) (Haustein J, Bauer W, Hilbertz T, et al, Dosing of Gd-DTPA in MR Imaging of Intracranial Tumors: a Randomized Double-Blind Multicenter Study in 90 Cases, presented at the Meeting of the Society of Magnetic Resonance in Medicine, 1990). Adverse effects from radiographic contrast media have been reported to occur much less frequently with the application of lower-osmolality and nonionic agents (41, 43–45). Gadoteridol is a low-osmolality agent with nonionic properties and, therefore, adverse effects might not be expected to increase even at a higher dose. This hypothesis is supported by our data and by previous reports (22–24), which showed no increase in adverse effects with gadoteridol at doses up to 0.3 mmol/kg.

The qualitative (Tables 1–3) and quantitative (Fig 7) findings of this multicenter high-dose clinical trial of gadoteridol are consistent with the findings of previous studies (20, 22–26). High-dose gadoteridol causes a proportional increase in the lesion-to-background signal-intensity ratio (Fig 7). Earlier studies raised concern that higher doses of gadolinium may cause a decrease in lesion enhancement because of T2 shortening effects (16–18). Our data and other recent studies

with gadoteridol, however, demonstrate an increase in lesion enhancement with increasing doses up to 0.3 mmol/kg without apparent T2 shortening effects (8, 22–24). Quantitative analysis performed on 133 lesions in 45 patients demonstrated that mean normalized lesion contrast increased by approximately an entire standard deviation between initial-dose and high-dose studies, relative to the signal intensity of the overall brain parenchyma (Fig 7). The increased lesion contrast on high-dose studies is almost certainly responsible for improved diagnostic confidence (Figs 1 and 2) and lesion detection (Figs 2–5) relative to standard-dose studies.

An incremental-dose technique similar to that used by Niendorf et al (1) was applied in this study. This method results in improved data comparability and reliability. The enhancement effect is influenced predominately by the contrast dose and, to a much lesser degree, by the effects of delayed gadolinium uptake (Fig 7). When the incremental-dose technique is applied, differences between the initial-dose and high-dose examinations can be considered primarily attributable to the tissue concentration of gadolinium and not to disease progression, interventional therapy, or variations in the image-acquisition process. Quantitative image analysis revealed that lesions in the 10- and 20-minute delayed studies showed slightly increased contrast than the same lesions in the immediate initial-dose studies (Fig 7). This increased contrast, however, was clinically insignificant compared with the dramatic increase in contrast seen on high-dose studies. Other investigators have demonstrated that the small increases in lesion contrast produced by delayed postcontrast imaging may not always be visually detectable (16, 22, 46).

The relationship between lesion contrast and lesion detectability has been studied previously using phantoms (23, 47, 48). Previous study has shown that lesion detection increases with increasing lesion signal intensity. Smaller lesions are detectable only if the lesion-to-background ratio (lesion contrast) is sufficiently high, yet larger lesions can be detected with relatively low lesion contrast (1). Additionally, increases in lesion contrast not only improve lesion detectability but also improve lesion delineation, resulting in improved diagnostic confidence (Fig 1). Apparent lesion size tends to decrease as the lesion-to-background ratio (lesion contrast) decreases. This results in a loss of signal primarily from the periphery of the lesion, because of a loss of

peripheral pixel signal intensity caused by partial volume effects (from the low-signal background). This effect is most noticeable in smaller lesions, because they have a higher percentage of peripheral pixels (23). These previous observations are supported by our findings of increased lesion detection with increasing contrast dose, particularly detection of small or early metastases.

Both unblinded and blinded visual evaluation revealed that lesion detection increased significantly (Tables 1 and 2) with increasing doses of gadoteridol up to a cumulative dose of 0.3 mmol/kg. Most importantly, we have seen patients with additional lesions demonstrated by high-dose studies who showed no lesions (two patients) or only solitary lesions (five patients by blinded and eight patients by unblinded reviewers) in standard-dose studies. Although pulsatile artifacts increased in several patients, especially in the posterior fossa, when a higher dose of gadolinium was used, the high-dose studies still provided superior lesion conspicuity and detection in the posterior fossa when compared with the standard-dose studies (Fig 5).

Because of the nature of the enrollment criteria, this study was biased toward patients with clinical or radiologic evidence of extensive metastatic disease (24.2% of the patients had normal findings in this series). Clinically asymptomatic patients were not included in these studies. Many patients enrolled in the study already had evidence of multiple metastatic lesions (Fig 2) demonstrated by other imaging modalities; many lesions were large. In these patients, particularly those with large lesions, metastases were readily demonstrated on standard-dose and precontrast MR studies (Figs 2 and 4). Neither the standard-dose nor the high-dose studies tended to impact significantly on diagnosis or management in these patients, because these large lesions were likely to be apparent on precontrast T1- or T2-weighted studies (1) (Yuh WTC, Tali ET, Nguyen H, et al, Application of Delayed Imaging and Dose Increment in the Evaluation of Central Nervous System Metastatic Disease, presented at the 30th Annual Meeting of the American Society of Neuroradiology, St. Louis, Mo 1992). However, many of the lesions demonstrated by the high-dose studies but not by the standard-dose studies were small (Figs 2 and 5), most less than 5 mm. This study, therefore, establishes the fact that high-dose study has the potential to improve lesion detection of small and/or early metastases. Because metastases have an exponential rate of

growth (50), early metastases may remain small and asymptomatic for some time and can be difficult to detect by routine imaging techniques, including standard-dose MR. As demonstrated by both phantom and previous high-dose studies of patients with extensive metastatic disease, smaller lesions are detectable only if they have increased lesion-to-background ratios (lesion contrast) (23, 24). High-dose studies, therefore, may be particularly valuable in the evaluation of patients with new diagnoses of a primary cancer or patients with either no lesions or solitary lesions demonstrated by conventional radiologic examination, because it is in these patients that central nervous system metastases are likely to be early or small lesions and to impact greatly on patient treatment.

Although the unblinded and blinded reviewers generally agreed that the high-dose studies were superior to standard-dose studies in providing better lesion detection (Tables 1 and 2), additional diagnostic information (Table 3), and assistance in patient diagnosis and treatment (Table 4), there were variations between unblinded and blinded readings with regard to the findings of precontrast versus standard-dose, precontrast versus high-dose, and standard-dose versus high-dose studies. These disparities between unblinded and blinded reviewers are possibly the result of differences in the assessment of impact of the contrast-enhanced examinations. The protocols used by the unblinded reviewers to review the images were not exactly the same as those used by the blinded reviewer, as were the number of patients reviewed, the number of reviewers, and treatment approaches of the reviewers.

Several possible factors may have contributed to variations in lesion detection between the unblinded and blinded reviewers (Tables 1 and 2). The blinded reviewer analyzed fewer cases because one image set (standard-dose versus high-dose studies) was judged to be of poor diagnostic quality. Intraobserver variability was particularly prominent in three cases in which extensive metastatic disease made the counting of small lesions prone to error. When these three cases are excluded, intraobserver variability in the blinded reviewer data is minimal. Because only a single blinded reviewer was used in the study, differences between this single reviewer and the multiple unblinded reviewers also may be exaggerated. Despite the presence of many factors that potentially promote variation, statistical analysis of both unblinded and blinded data showed sig-

nificant increases in lesion detection with increasing contrast doses (Tables 1 and 2).

There was also variation between the unblinded and blinded reviewers in the assessment of the nature of the additional information provided by standard-dose and high-dose studies (Table 3). This variation was higher in the precontrast versus standard-dose compared with the standard-dose versus high-dose comparison and was most marked in the "improved visualization" and "lesion border definition" categories. Discrepancies between the findings of the unblinded and blinded reviewers were much less, however, in the standard-dose with high-dose comparisons in the same categories. This suggests that high-dose studies further improved the confidence of both unblinded and blinded reviewers.

In the assessment of additional information (Table 3), discrepancies between the findings of the unblinded and blinded reviewers in determining "distinction of edema" may have resulted from differences in how the image-evaluation protocol was interpreted. In evaluating the images, only the presence or absence of differentiation of tumor from edema was assessed; some reviewers also may have attempted to characterize the degree of improvement. Both unblinded (4%) and blinded (13%) reviewers noted few cases in which disease classification was improved by high-dose studies. The "disease classification" category was primarily influenced by cases in which there was an improved confidence in the diagnosis of metastatic disease. This finding again may be related to the bias of the enrollment criteria. Even with additional lesions demonstrated by the high-dose study, the disease classification of these patients with known multiple metastases was unlikely to be altered by high-dose study. Despite these variations, the findings of both unblinded and blinded reviewers indicate that high-dose MR study provides additional diagnostic information over standard-dose MR study, including improved lesion visualization, improved lesion border delineation, and increased lesion detection. Unblinded and blinded reviewers agreed that neither precontrast, standard-dose, nor high-dose studies allowed the determination of recurrent tumor. This finding is expected, because neither set of reviewers was allowed to view prior studies.

In the assessment of the effect of contrast administration on patient diagnosis and treatment, discrepancies were also noted between the unblinded and blinded reviewers (Table 4). The variation in the categories "assist in diagnosis"

and "assist in treatment" may be related to differences in the interpretation of additional diagnostic information and also to differences in the number of patients evaluated by the reviewers. The single blinded neurooncologist evaluated only those patients identified by the blinded neuroradiologist as having demonstrated additional information on contrast-enhanced studies, whereas unblinded reviewers evaluated all patients with radiologic evidence of disease. The potential benefit of improved confidence was not assessed by the blinded reviewer. The absence of a demonstrable lesion on a high-dose examination can provide reassurance that a questionable area of increased signal intensity on the standard-dose study may be disregarded. By comparison, the unblinded reviewers found that the high-dose studies often reassured them that a lesion was not present (Fig 2); such studies were considered helpful in patient treatment, despite the absence of additional findings.

The difference in determination of change in treatment by the high-dose study (20% unblinded versus 6% blinded) may be related to differences in the review protocol. There was a difference in treatment approach between the unblinded and blinded reviewers. In four of the seven patients in whom the blinded neuroradiologist identified additional lesions on the high-dose studies (changed from zero lesions to one lesion in one patient and changed from one lesion to multiple lesions in three patients), the blinded neurooncologist did not consider the additional information to assist in treatment. In these four patients, the neurooncologist thought that the patients' terminal conditions precluded alteration of treatment, despite the fact that useful information was provided by the high-dose studies. Radiologic brain examination in these patients would have been considered unnecessary by the blinded oncologist. Therefore, the lack of change in the treatment of these patients by the blinded neurooncologist may not reflect the actual benefit of the high-dose study. The unblinded neuroradiologists, however, assumed that the MR studies were a part of patient management and judged the value of the high-dose studies based purely on the central nervous system findings without regard to systemic involvement. Taking into consideration the variations mentioned above in all categories of treatment, the number of patients demonstrating a change or assistance in treatment varied greatly between the five unblinded reviewers and the single blinded reviewer (57% and 10%, respec-

tively). These variations might be minimized in future studies by using a stricter review protocol, increasing the number of blinded reviewers, and selecting a more representative patient population. Nevertheless, both unblinded and blinded reviewers agreed that high-dose studies improved patient diagnosis and treatment, and four patients did have documented changes in treatment plans based on the additional information obtained from the high-dose study.

In summary, lesion signal intensity increased significantly with increasing doses of gadoteridol up to a cumulative 0.3-mmol/kg dose without evidence of T2-shortening effect or increase of adverse effects. High-dose MR study with gadoteridol can result in improved lesion detection and provide additional diagnostic information that can aid in patient treatment. Although many patients studied had radiologic evidence of multiple metastases, additional lesions identified only on high-dose studies tended to be small, suggesting possible advantages to the use of higher doses of gadoteridol in the detection of early or small brain metastases in those patients with newly diagnosed primary cancer and in patients with no lesions or single lesions demonstrated by conventional radiologic examinations.

## References

1. Niendorf HP, Laniado M, Semmler W, Schörner W, Felix R. Dose administration of gadolinium-DTPA in MR imaging of intracranial tumors. *AJNR Am J Neuroradiol* 1987;8:803-815
2. Carr DH, Brown J, Bydder GM, et al. Gadolinium-DTPA as a contrast agent in MRI: initial clinical experience in 20 patients. *AJR Am J Roentgenol* 1984;143:215-224
3. Carr DH, Brown J, Bydder GM, et al. Intravenous chelated gadolinium as a contrast agent in NMR imaging of cerebral tumours. *Lancet* 1984;1:484-486
4. Claussen C, Laniado M, Kazner E, Schörner W, Felix R. Application of contrast agents in CT and MRI (NMR): their potential in imaging of brain tumors. *Neuroradiology* 1985;27:164-171
5. Brant-Zawadzki M, Berry I, Osaki L, Brasch R, Murovic J, Norman D. Gd-DTPA in clinical MR of the brain, 1: Intraaxial lesions. *AJNR Am J Neuroradiol* 1986;7:781-788
6. Berry I, Brant-Zawadzki M, Osaki L, Brasch R, Murovic J, Newton TH. Gd-DTPA in clinical MR of the brain, 2: Extraaxial lesions and normal structures. *AJNR Am J Neuroradiol* 1986;7:789-793
7. Runge VM, Carollo BR, Wolf CR, Nelson KL, Gelblum DY. Gd-DTPA: a review of clinical indications in central nervous system magnetic resonance imaging. *Radiographics* 1989;9:929-955
8. Runge VM, Kirsch JE, Burke VJ, et al. High-dose gadoteridol in MR imaging of intracranial neoplasms. *J Magn Reson Imaging* 1992;2: 9-18
9. Felix R, Schörner W, Laniado M, et al. Brain tumors: MR imaging with gadolinium-DTPA. *Radiology* 1985;156:681-688

10. Bauer WM, Fenzl G, Vogl T, Fink U, Lissner J. Indications for the use of Gd-DTPA in MRI of the central nervous system: experiences in patients with cerebral and spinal diseases. *Invest Radiol* 1988;23 (suppl 1):S286-S288
11. Elster AD, Rieser GD. Gd-DTPA-enhanced cranial MR imaging in children: initial clinical experience and recommendations for its use. *AJNR Am J Neuroradiol* 1989;10:1027-1030
12. Valk J, de Slegte RG, Crezee FC, Hazenberg GJ, Thjaha SI, Nauta JJ. Contrast-enhanced magnetic resonance imaging of the brain using gadolinium-DTPA. *Acta Radiol* 1987;28:659-665
13. Hesselink JR, Healy ME, Press GA, Brahme FJ. Benefits of Gd-DTPA for MR imaging of intracranial abnormalities. *J Comput Assist Tomogr* 1988;12:266-274
14. Sze G, Milano E, Johnson C, Heier L. Detection of brain metastases: comparison of contrast-enhanced MR with unenhanced MR and enhanced CT. *AJNR Am J Neuroradiol* 1990;11:785-791
15. Russell EJ, Geremia GK, Johnson CE, et al. Multiple cerebral metastases: detectability with Gd-DTPA-enhanced MR imaging. *Radiology* 1987;165:609-617
16. Graif M, Bydder GM, Steiner RE, Niendorf HP, Thomas DG, Young IR. Contrast-enhanced MR imaging of malignant brain tumors. *AJNR Am J Neuroradiol* 1985;6:855-862
17. Brasch RC, Weinmann HJ, Wesbey GE. Contrast-enhanced NMR imaging: animal studies using gadolinium-DTPA complex. *AJR Am J Roentgenol* 1984;142:625-630
18. Laniado M, Weinmann HJ, Schörner W, Felix R, Speck U. First use of Gd-DTPA/dimeglumine in man. *Physiol Chem Phys Med NMR* 1984;16:157-165
19. Claussen C, Laniado M, Schörner W, et al. Gadolinium-DTPA in MR imaging of glioblastomas and intracranial metastases. *AJNR Am J Neuroradiol* 1985;6:669-674
20. Tweedle MF, Hagan JJ, Kumar K, Mantha S, Chang CA. Reaction of gadolinium chelates with endogenously available ions. *Magn Reson Imaging* 1991;9:409-415
21. Tweedle MF. Nonionic or neutral? *Radiology* 1991;178:891
22. Runge VM, Gelblum DY, Pacetti ML, Carolan F, Heard G. Gd-HP-DO3A in clinical MR imaging of the brain. *Radiology* 1990;177:393-400
23. Yuh WTC, Fisher DJ, Engelken JD, et al. MR evaluation of CNS tumors: dose comparison study with gadopentetate dimeglumine and gadoteridol. *Radiology* 1991;180:485-491
24. Yuh WTC, Engelken JD, Muhonen MG, Mayr NA, Fisher DJ, Ehrhardt JC. Experience with high-dose gadolinium MR imaging in the evaluation of brain metastases. *AJNR Am J Neuroradiol* 1992;13:335-345
25. Runge VM, Kaufman DM, Wood ML, Adelman LS, Jacobson S. Experimental trials with Gd(HP-DO3A) - a nonionic magnetic resonance contrast agent. *Int J Rad Appl Instrum part B*, 1989;16:561-567
26. Wedeking P, Sotak CH, Telsler J, Kumar K, Chang CA, Tweedle MF. Quantitative dependence of MR signal intensity on tissue concentration of Gd(HP-DO3A) in the nephrectomized rat. *Magn Reson Imaging* 1992;10:97-108
27. Posner JB, Chernik NL. Intracranial metastases from systemic cancer. *Adv Neurol* 1978;19:579-592
28. Russell DJ, Rubenstein LJ. *Secondary tumors of the nervous system*. 5th ed. Baltimore: Williams & Wilkins, 1989:825-841
29. Delattre JY, Krol G, Thaler HT, Posner JB. Distribution of brain metastases. *Arch Neurol* 1988;45:741-744
30. Amer MH, Al-Sarraf M, Baker LH, Vaitkevicius VK. Malignant melanoma and central nervous system metastasis: incidence, diagnosis, treatment and survival. *Cancer* 1978;42:660-668
31. Tsukada Y, Fouad A, Pickren JW, Lane WW. Central nervous system metastasis from breast carcinoma: autopsy study. *Cancer* 1983;52:2349-2354
32. Rubin R, Green J. *Solitary metastases*. Springfield, Ill: Thomas, 1968
33. Weiss L, Gilbert HA, Posner JB. *Brain metastases*. Boston: Hall, 1980:2-29
34. Butler AR, Leo JS, Lin JP, Boyd AD, Kricheff II. The value of routine cranial computed tomography in neurologically intact patients with primary carcinoma of the lung. *Radiology* 1979;131:399-401
35. Galicich JH, Sundaresan N, Thaler HT. Surgical treatment of single brain metastasis. Evaluation of results by computerized tomography scanning. *J Neurosurg* 1980;53:63-67
36. Posner JB. Surgery for metastases to the brain. *N Engl J Med* 1990;322:544-545
37. Sze G, Shin J, Krol G, Johnson C, Liu D, Deck MD. Intraparenchymal brain metastases: MR imaging versus contrast-enhanced CT. *Radiology* 1988;168:187-194
38. Woodruff WW, Djang WT, McLendon RE. Intracerebral malignant melanoma: high field strength MR imaging. *Radiology* 1987;168:209-213
39. Davis PC, Hudgins PA, Peterman SB, Hoffman JC Jr. Diagnosis of cerebral metastases: double-dose delayed CT vs contrast-enhanced MR imaging. *AJNR Am J Neuroradiol* 1991;12:293-300
40. Tweedle MF, Eaton SM, Eckelman WC, et al. Comparative chemical structure and pharmacokinetics of MRI contrast agents. *Invest Radiol* 1988;23(suppl 1):S236-S239
41. Bryan RN, Miller SL, Roehm JO Jr, Weatherall PT. Neuroangiography with iohexol. *AJNR Am J Neuroradiol* 1983;4:344-346
42. Healy ME, Hesselink JR, Press GA, Middleton MS. Increased detection of intracranial metastases with intravenous Gd-DTPA. *Radiology* 1987;165:619-624
43. Bacarini L, de Nicola T, Gasparini D, Orlando P, Vassallo A. Iapamidol (B 15 000), a nonionic water-soluble contrast medium for neuroradiology. Part II: results of a double-blind study of the lumbar epidural venous plexuses. *Neuroradiology* 1982;23:147-152
44. Cohan RH, Dunnick NR. Intravascular contrast media: adverse reactions. *AJR Am J Roentgenol* 1987;149:665-670
45. Katayama H, Yamaguchi K, Takahiro K, Takashima T, Seez P, Matsuura K. Adverse reactions to ionic and nonionic contrast media: a report from the Japanese committee on the safety of contrast media. *Radiology* 1990;175:621-628
46. Schörner W, Laniado M, Niendorf HP, Schubert C, Felix R. Time-dependent changes in image contrast in brain tumors after gadolinium-DTPA. *AJNR Am J Neuroradiol* 1986;7:1013-1020
47. Yuh WTC, Fisher DJ, Mayr-Yuh NA, et al. Review of the use of high-dose gadoteridol in the magnetic resonance evaluation of central nervous system tumors. *Invest Radiol* 1992;27(suppl 1):S39-S44
48. Yuh WTC, Fisher DJ, Nguyen HD, Tali ET, Mayr NA. The application of contrast agents in the evaluation of neoplasms of the central nervous system. *Top Magn Reson Imaging* 1992;4:1-6
49. Tannock IF. Principles of cell proliferation: cell kinetics. In: DeVita VT Jr, Hellman S, Rosenberg SA, eds. *Cancer: principles and practice of oncology*. 3rd ed. Philadelphia: Lippincott, 1989:3-13

Please see the commentary on page 1062 in this issue.