

Primary Lymphoma of the Cauda Equina: Myelographic, CT Myelographic, and MR Appearance

Edmond A. Knopp, K. York Chynn, and James Hughes

Summary: This case demonstrates the myelographic, CT myelographic, and MR appearance of primary lymphoma of the cauda equina. It also illustrates the utility of high-resolution CT myelography in certain lesions of the cauda equina. The authors feel that CT myelography, with its inherent ability to depict individual nerve roots and therefore any pathologic involvement as well, should be considered an adjunct to MR in imaging the cauda equina.

Index terms: Lymphoma; Cauda equina; Spine, computed tomography; Spine, neoplasms; Myelography

Primary lymphoma of the cauda equina is an extremely rare disease. There have been four cases previously reported (1–4); however, one was related to acquired immunodeficiency syndrome (4). We report the myelographic, computed tomography (CT) myelographic, and magnetic resonance (MR) appearance of this lesion. It is presented to illustrate the utility of CT myelography as an adjunct to MR in the evaluation of lesions of the cauda equina.

Case Report

A 69-year-old woman presented with a 3-week history of progressive bilateral lower-extremity numbness and weakness. Before this she was in her usual state of good health. Physical examination revealed decreased motor strength in both lower extremities, grade 2/5, with decreased sensation as well. Deep-tendon reflexes were absent. There was no incontinence or decreased sphincter tone.

The patient underwent an emergency myelogram to evaluate the possibility of spinal cord compression. The cerebrospinal fluid obtained at this time was significant for the following: protein, 5932 mg/dL; cell count, 29 red blood cells, 121 white blood cells, with 98% lymphocytes and 2% large monocytes. A total myelogram was per-

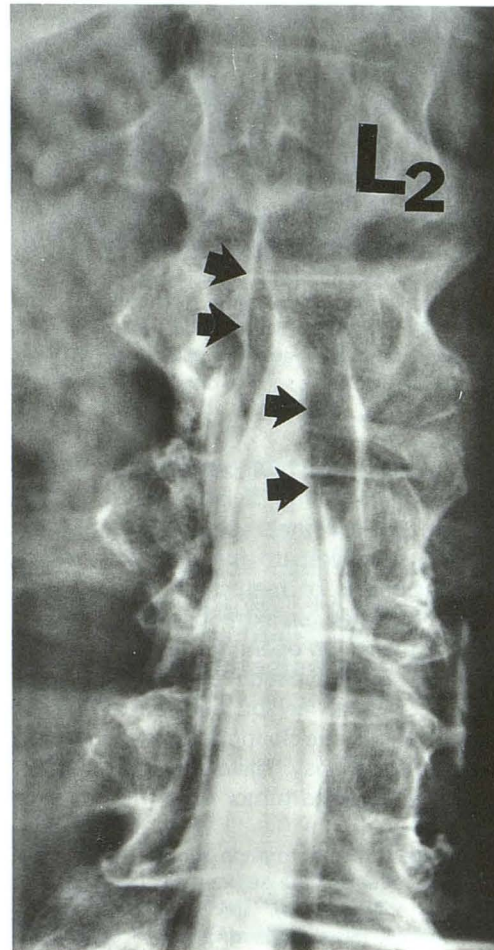


Fig. 1. Anteroposterior myelogram spot film demonstrates a high-grade block at L2–3, which appears extradural. The nerve roots of the cauda look thickened (arrows).

formed and revealed a high-grade block at L2–3 with contrast able to pass this level (Fig 1). A compression fracture of L-2 was also seen; however, this did not seem to have any compressive effect on the thecal sac. A CT

Received December 23, 1991; accepted pending revision February 25, 1992; revision received February 1, 1993.

Presented as an Excerpta Extraordinaire at the 29th Annual Meeting of the American Society of Neuroradiology, Washington, DC, 1991.

From the Departments of Diagnostic Radiology (E.A.K., K.Y.C.) and Neurosurgery (J.H.), St Luke's/Roosevelt Hospital Center, Columbia University College of Physicians and Surgeons, New York.

Address reprint requests to Edmond A. Knopp, MD, Division of Neuroradiology, Department of Radiology, New York University Medical Center, 560 First Ave, New York, NY 10016.

AJNR 15:1187–1189, Jun 1994 0195-6108/94/1506-1187 © American Society of Neuroradiology

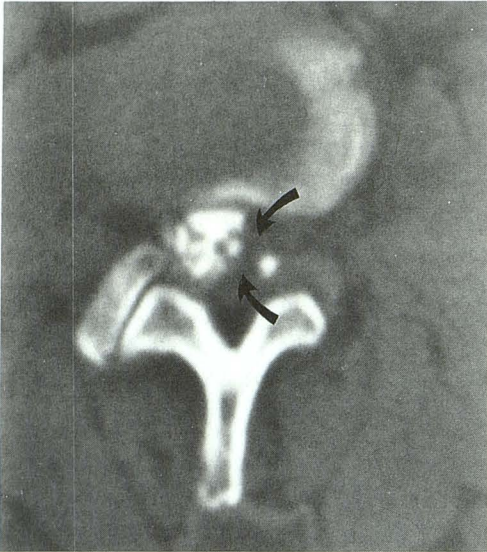
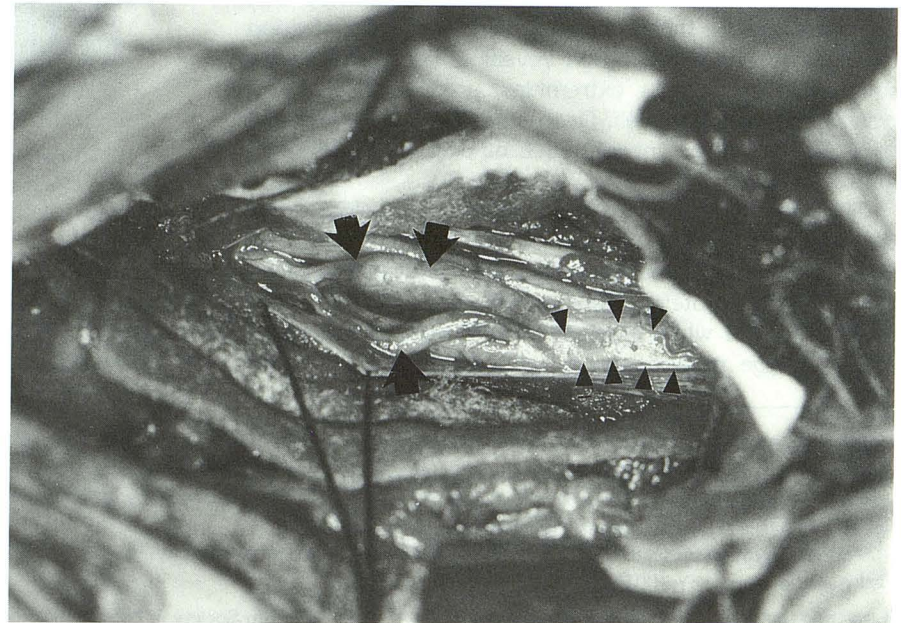


Fig. 2. Four-millimeter axial view from the CT myelogram taken at the L2-3 level shows multiple enlarged nerve roots (*arrows*) involving the left side of the cauda equina. The matted and thickened nerve roots are seen to displace this contrast toward the right.

myelogram demonstrated multiple enlarged nerve roots of the cauda, mostly involving the left side (Fig 2). There was no evidence of an extradural mass lesion.

The patient was taken to the operating room with a presumptive diagnosis of metastatic involvement of the cauda equina. At surgery an extradural exploration revealed no evidence of mass. On opening the dura, we found that the nerve roots of the cauda equina were individually swollen in a segmental fashion and matted together (Fig 3). There were a few free-floating tissue fragments, which were submitted for biopsy. Histologic examination of the biopsy specimen revealed tumor cells with an appearance

Fig. 3. Intraoperative photograph shows the opened dura revealing the segmentally thickened nerve roots (*arrows*), which also appear to be matted together (*arrowheads*) where they have not been dissected. There is no discrete tumor mass.



consistent with malignant lymphoma, confirmed by immunoperoxidase staining.

Two days after decompression the patient underwent a gadolinium-enhanced MR examination for more thorough evaluation of her spine. At the L1-3 level there was a mass seen filling the spinal canal and exhibiting a heterogenous increased signal on T1-weighted images. The mass was seen to enhance after gadolinium administration (Fig 4). The signal characteristics depicted on the MR images were thought to represent the primary lymphomatous disease despite the scan's being postoperative, because no excision of intradural material had been made at surgery, performed within the preceding 48 hours.

The patient underwent extensive evaluation, including bone marrow biopsies, to locate another site of malignancy; all results were negative.

Discussion

Primary lymphoma of the cauda equina is a rare condition. There are four previously reported cases demonstrating nerve-root infiltration (1-4). With the advent and evolution of MR, its utility in imaging spinal lymphoma has been shown (5, 6). It is felt that with the use of gadolinium, MR provides an excellent way of imaging this lesion (6).

Imaging of the cauda equina, however, requires high resolution to discern individual nerve roots. The presence of thickened and swollen roots, if not resolved adequately, could lead one to consider a diagnosis of a primary mass (such as ependymoma or intradural metastasis) or even an extradural process that has completely filled the spinal canal (ie, bony metastasis or infection)

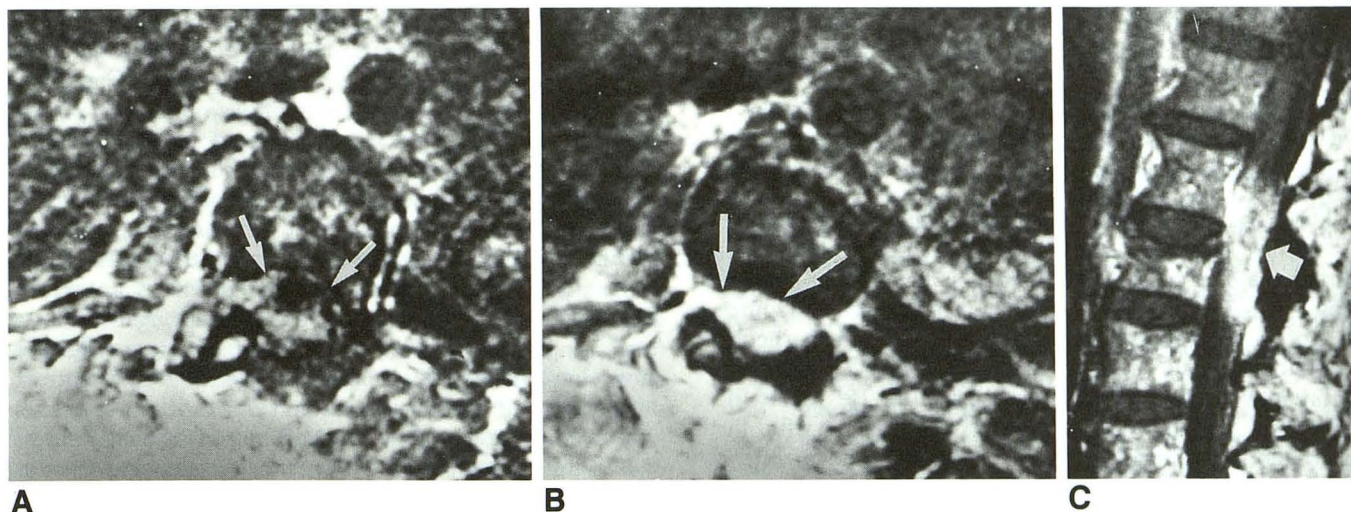


Fig. 4. A, Three-millimeter axial T1-weighted image (800/30/2 [repetition time/echo time/excitations], 256 × 256 matrix, 24-cm field of view) shows a mass filling the canal with inhomogeneous increased signal—thought to represent the lymphomatous nerve roots (arrows).

B, Same level as A, shows intense enhancement with gadolinium (white arrow).

C, Three-millimeter sagittal T1-weighted image with gadolinium (600/20/2, 256 × 256 matrix, 30-cm field of view) shows an enhancing mass that appears to fill the thecal sac (white arrow).

as opposed to a process affecting the individual roots (such as lymphoma, sarcoid, tuberculosis, arachnoiditis, or hypertrophic interstitial polyneuritis) (7).

Lymphoma can affect the spinal canal and neural tissues in variable ways. Invasion of the canal with associated compression can occur with widespread lymphoma with or without adjacent bony involvement (5). Likewise, primary lymphoma also can affect both the cord or its roots (1, 3, 6), as well as the overlying meninges (4).

It has been shown that, using a high-field surface-coil technique, MR is efficient in defining the anatomy of the cauda equina (8). Monajati et al felt that "morphologic alterations due to tumors infiltrating the nerve roots were correctly perceived" (8). Our case, however, shows that there may be instances in which MR may not afford the resolution necessary to discern lesions clearly that infiltrate individual nerve roots in a segmental fashion. As can be seen from Figure 4, the pattern of enhancement does not allow for the depiction of the individual nerve roots or of their precise pathologic involvement. The CT myelogram (Fig 2), on the other hand, does allow for the visualization of individual nerve roots and their pathologic involvement.

The use of CT myelography may allow for a greater resolution in depicting the precise ana-

tomic and pathologic changes that result from primary lymphoma of the cauda equina and should be considered as an adjunct study in cases of disease of the cauda equina, in which the MR examination demonstrates abnormal signal filling the canal with no discernable individual structures or evidence of an extradural process giving rise to the mass.

References

1. Mauney M, Sciotto CG. Primary malignant lymphoma of the cauda equina. *Amer J Surg Pathol* 1983;7:185-190
2. Case records of the Massachusetts General Hospital (case 1:2-1985). *N Engl J Med* 1985;312:774-783
3. Toner GC, Holmes R, Sinclair RA, Tang SK, Schwarz MA. Central nervous system lymphoma: primary lumbar nerve root infiltration. *Acta Haematol* 1989;81:44-47
4. Klein P, Zientek G, VandenBerg SR, Lothman E. Primary CNS lymphoma: lymphomatous meningitis presenting as a cauda equina lesion in an AIDS patient. *Can J Neurol Sci* 1990;17:329-331
5. Holtas SL, Kido DK, Simon JH. MR Imaging of spinal lymphoma. *J Comput Assist Tomogr* 1986;10:111-115
6. Bluemke DA, and Wang H. Primary spinal cord lymphoma: MR appearance. *J Comput Assist Tomogr* 1990;14:812-814
7. Krishna Rao CVG, Fitz CR, Harwood-Nash DC. Dejerine-Sottas syndrome in children (hypertrophic interstitial polyneuritis). *AJR Am J Roentgenol* 1974;122:70-74
8. Monajati A, Wayne WS, Rauschnig W, Ekholm SE. MR of the cauda equina. *AJNR Am J Neuroradiol* 1987;8:893-900