

Nonaneurysmal Perimesencephalic Subarachnoid Hemorrhage: CT and MR Patterns That Differ from Aneurysmal Rupture

Gabriel J. E. Rinkel¹
 Eelco F. M. Wijdicks¹
 Marinus Vermeulen²
 Lino M. P. Ramos³
 Hervé L. J. Tanghe⁴
 Djo Hasan²
 Linda C. Meiners³
 Jan van Gijn¹

We describe a characteristic distribution of cisternal blood in 52 patients with nonaneurysmal subarachnoid hemorrhage proved by a normal angiogram. On CT, the center of the bleeding was located immediately anterior to the brainstem in all patients, which was confirmed in four patients who were studied with MR imaging. Extension to the ambient cisterns or to the basal parts of the sylvian fissures was common, but the lateral sylvian or anterior interhemispheric fissures were never completely filled with blood. Rupture into the ventricular system did not occur. MR demonstrated downward extension of the blood anterior to the brainstem as far as the medulla, but failed to detect the source of hemorrhage. Our aim was to determine whether this so-called nonaneurysmal perimesencephalic hemorrhage could be distinguished from aneurysmal subarachnoid hemorrhage on early CT scans. Two neuroradiologists were shown a consecutive series of 221 CT scans of patients with subarachnoid hemorrhage who subsequently underwent angiography. Only one patient with a basilar artery aneurysm on angiography was incorrectly labeled by both observers as having a nonaneurysmal perimesencephalic pattern of hemorrhage.

The high predictive value of the perimesencephalic pattern of hemorrhage for a normal angiogram (0.95 and 0.94, respectively, for the two observers) and the excellent interobserver agreement (κ 0.87) demonstrate that nonaneurysmal perimesencephalic hemorrhage can be distinguished on CT in the majority of patients. Recognition of this pattern of hemorrhage is important as patients with this subset of subarachnoid hemorrhage have an excellent prognosis.

AJNR 12:829-834, September/October 1991; *AJR* 157: December 1991

The distribution of extravasated blood on CT scans in patients with subarachnoid hemorrhage may predict the site of the ruptured aneurysm [1]. Half the patients with subarachnoid hemorrhage and a normal angiogram showed a predominance of blood in the cisterns around the midbrain [2, 3]. This contrasts with aneurysmal subarachnoid hemorrhage, in which hemorrhages resulting from posterior circulation aneurysms were found in only approximately 10% of the patients [1, 4].

The clinical picture of patients with perimesencephalic hemorrhage and a normal angiogram is characterized by an uncomplicated clinical course, without delayed cerebral ischemia or rehemorrhage [2], and with an excellent prognosis 18 months to 7 years after the hemorrhage [5]. These clinical features differ from the aneurysmal type of subarachnoid hemorrhage and strongly argue against an undetected aneurysm as the source of this type of hemorrhage.

We studied the radiologic characteristics in a large series of consecutive patients with this so-called nonaneurysmal perimesencephalic hemorrhage to gather radiologic criteria for its recognition. Using these criteria, we addressed the question of whether this pattern could be completely distinguished from that of aneurysmal subarachnoid hemorrhage on CT. Therefore, we conducted an interobserver study to determine the predictive value of identifying a perimesencephalic pattern of hemorrhage on CT for a normal angiogram.

Received October 19, 1990; revision requested January 14, 1991; revision received March 11, 1991; accepted March 22, 1991.

¹ University Department of Neurology, Heidelberglaan 100, 3584 CX Utrecht, The Netherlands. Address reprint requests to G. J. E. Rinkel.

² University Department of Neurology, Rotterdam, The Netherlands.

³ University Department of Radiology, Utrecht, The Netherlands.

⁴ University Department of Radiology, Rotterdam, The Netherlands.

0195-6108/91/1205-0829

© American Society of Neuroradiology

Subjects and Methods

We studied 52 consecutive patients with (1) signs and symptoms of subarachnoid hemorrhage, (2) a normal four-vessel angiogram, and (3) a CT study performed within 72 hr of the first clinical symptoms that showed a subarachnoid hemorrhage located predominantly in the posterior portion of the basal cisterns. Patients with a normal angiogram in which the center of the hemorrhage was located in the anterior portion of the basal cisterns, suggesting an anterior communicating–internal carotid or middle cerebral artery aneurysm, were excluded and will be the subject of a separate paper.

CT scanning was performed within 24 hr of the ictus in 45 patients and between 24 and 72 hr in seven patients. In 12 patients CT scanning was repeated 1 week after the hemorrhage. CT scans were performed on a Philips tomoscan 350 or 500 third-generation scanner. Contiguous slices of 3 mm were used in the region of the basal cisterns. In the supratentorial part of the brain noncontiguous slices of 5 mm were made. In none of the patients was contrast material used.

In four patients MR scans with detailed views of the brainstem were obtained within 5 days of the hemorrhage and again after 6 weeks to investigate the possibility of a small angioma being the source of bleeding in perimesencephalic hemorrhage. MR images were made on a Philips Gyroscan S15 (1.5-T) scanner. Slices of 4 mm thickness with a 0.8-mm gap were made in the area of the brainstem in both the transverse and sagittal planes. Both T1-weighted spin echo (SE) 500/30/2 (TR/TE/excitations) and T2-weighted SE 2000/50/2 and 2000/100/2 sequences were used. Additional T2-weighted SE 2000/50/1 and 2000/100/1 transverse slices of 8 mm thickness with a 1.6-mm gap were made of the entire brain. The MR examination was not performed with contrast agent.

All patients had selective bilateral internal carotid and bilateral vertebral angiography with frontal, lateral, and oblique projections. Subtraction films were obtained in most patients. Angiograms were usually made within 3 days of the hemorrhage. Angiography was repeated in 12 patients, in two because of narrowing of the basilar artery on the first angiogram and in one because of poor visualization of the posterior inferior cerebellar artery. In the remaining nine patients angiography was repeated 3 months after the hemorrhage. All repeated angiograms were completely normal.

After having detailed the blood distribution in these 52 patients, we outlined radiologic criteria for the pattern of perimesencephalic hemorrhage as follows: (1) center of the hemorrhage located immediately anterior to the midbrain, with or without extension of blood to the anterior part of the ambient cistern or to the basal part of the sylvian fissure; (2) no complete filling of the anterior interhemispheric fissure and no extension to the lateral sylvian fissure, except for minute amounts of blood; (3) absence of frank intraventricular hemorrhage. To test the validity of these criteria, we conducted an interobserver study with two neuroradiologists. From a consecutive series of patients with spontaneous subarachnoid hemorrhage admitted between 1983 and 1989 to the departments of neurology of the university hospitals in Utrecht and Rotterdam we selected patients who had blood visible on CT scans obtained within 72 hr of the ictus and who underwent selective four-vessel angiography. The CT scans of the 221 patients fulfilling these criteria form the basis of the present study. All CT scans were made on a Philips tomoscan 350 or 500 third-generation scanner. The results of angiography in the 221 patients were as follows. Thirty-one patients had a normal four-vessel angiogram. In the remaining 190 patients angiograms revealed aneurysms of the anterior cerebral artery in 72, the internal carotid artery in 55, the middle cerebral artery in 41, the pericallosal artery in seven, and the posterior circulation in 15, with 12 located at the basilar artery. Twenty-two of the 31 patients with a normal angiogram had

extravasated blood predominantly in the posterior portion of the basal cisterns, in the remaining nine patients the center of the bleeding was located in the anterior half of the basal cisterns.

The entire set of CT scans was shown separately to two experienced neuroradiologists. They were asked to distinguish between a nonaneurysmal perimesencephalic and an aneurysmal pattern of subarachnoid hemorrhage. The observers were unaware of the results of angiography at the time of the review. The degree of agreement between the two observers was measured by kappa statistics [6]. $\kappa = (P_o - P_e)/(1 - P_e)$, where P_o is the observed percentage of agreement and P_e is the percentage of agreement that is expected by chance. (κ is 0.0 when there is just chance agreement and 1.0 when there is perfect agreement.)

Results

The mean age of the patients was 53 years (range, 22–70 years). Thirty-two patients were men, 20 were women. All patients had a sudden onset of headache. Only two patients lost consciousness for a few minutes at the time of the ictus. All patients were found to have a normal level of consciousness on admission, and, except for neck stiffness, a normal neurologic examination corresponding with WFNS grade 1 [7].

Amount of Blood on CT Scan

There was a marked variation of the amount of cisternal blood within this series. In two patients only one of the basal cisterns was filled with blood, and then only partly. At the other extreme were four patients in whom all perimesencephalic cisterns were filled with blood, with extension to both basal parts of the sylvian fissures. In most other patients two or more cisterns were partly or completely filled with blood.

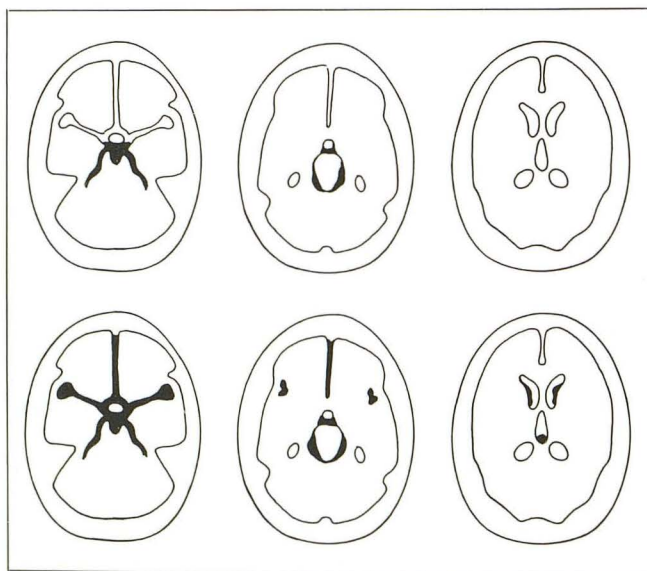
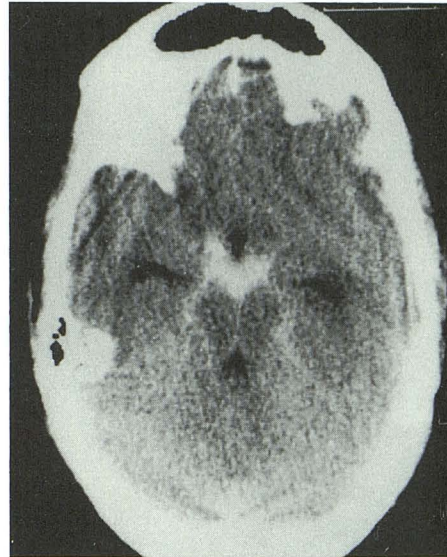

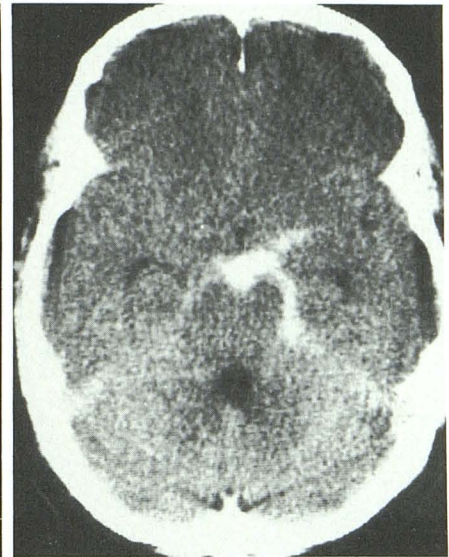
Fig. 1.—Line drawing shows axial views of characteristic pattern of blood distribution in nonaneurysmal perimesencephalic hemorrhage (upper row) compared with characteristic pattern of blood distribution in subarachnoid hemorrhage from a ruptured basilar artery aneurysm (lower row).

Fig. 2.—CT scan shows center of bleeding in interpeduncular fossa, with extension of blood into both ambient cisterns.



2

Fig. 3.—CT scan shows center of bleeding extending from interpeduncular fossa to left ambient cistern.



3

Sedimentation of blood in the posterior parts of the lateral ventricles occurred in 11 patients (21%), but frank intraventricular hemorrhage was not found.

Distribution of Blood on CT Scan

The characteristic pattern of blood distribution in nonaneurysmal perimesencephalic subarachnoid hemorrhage is illustrated in Figure 1.

In 45 (87%) of the 52 patients the center of the bleeding was located immediately anterior to the midbrain and pons (Fig. 2). In the remaining seven patients (13%) the center of

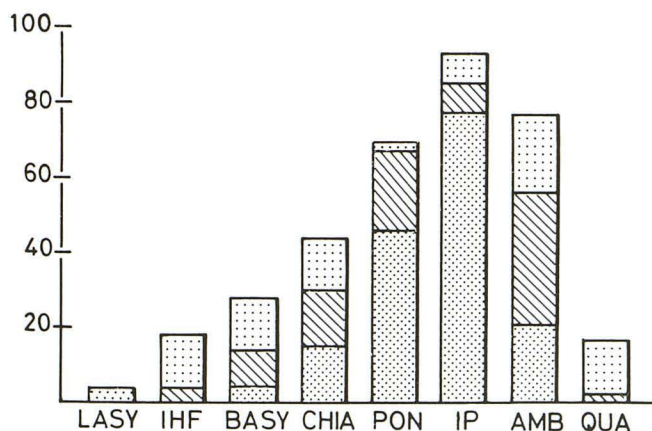


Fig. 4.—Graph shows distribution of cisternal blood in 52 patients with perimesencephalic hemorrhage. Bars represent percentage of patients in whom the cistern in question contained blood. *Densely dotted areas* = completely filled (grade 3); *hatched areas* = partly filled (grade 2); *sparsely dotted areas* = blood barely visible (grade 1). LASY = lateral part of sylvian fissures; IHF = anterior interhemispheric fissure; BASY = basal part of sylvian fissures; CHIA = chiasmatic cisterns; PON = prepontine cistern; IP = interpeduncular cistern; AMB = ambient cisterns; QUA = quadrigeminal cistern.

the bleeding extended from the interpeduncular cistern to the anterior part of one of the ambient cisterns (Fig. 3).

The distribution of cisternal blood is summarized in Figure 4. The prepontine cistern could be adequately visualized in 38 patients, in all of which it contained blood, most often contiguous with blood in the interpeduncular and suprasellar cisterns, either as a long, thin layer (Fig. 5) or as a more local clot. In some patients the blood extended to the lower pons. In two patients a prepontine clot was the only site of hemorrhage (Fig. 6). The interpeduncular cistern was filled with blood in 50 patients (96%), completely in 37 patients, and partly in 13. Blood extended to one or both chiasmatic cisterns in 24 patients (46%), but in only three patients were both chiasmatic cisterns completely filled with blood. In 46 patients (88%) blood was visible in one or both ambient cisterns, with extension into the quadrigeminal cistern in only 10 of these (19%). Blood in the quadrigeminal cistern not accompanied by blood in an ambient cistern did not occur in this study.

In 19 patients (37%) evidence of blood was present in the basal part of the sylvian fissure, invariably contiguous with blood in the chiasmatic cistern. In nine of these 19 patients both basal sylvian fissures contained blood, and in one of these patients the basal part of both fissures was completely filled with blood. In two patients a small amount of blood (grade 1) was found in the lateral sylvian fissure.

In nine patients (17%) the hemorrhage extended to the posterior part of the anterior interhemispheric fissure (Fig. 7). This fissure was never completely filled.

Repeated CT Scanning

In 12 patients CT scanning was repeated 1 week after the hemorrhage. In one patient a small amount of blood was still visible in the prepontine cistern, in all other patients the cisternal blood had completely disappeared.

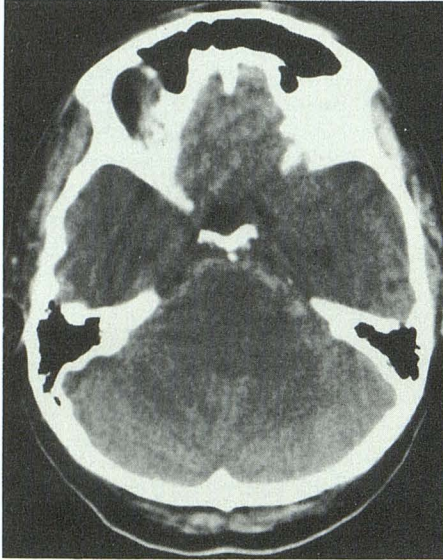


Fig. 5.—CT scan shows long, thin layer of blood in prepontine cistern.

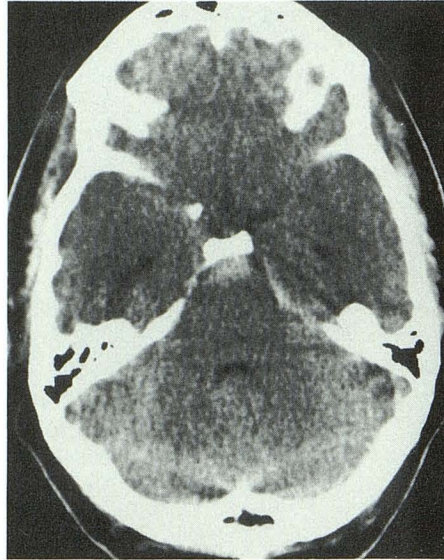


Fig. 6.—CT scan shows isolated clot in prepontine cistern.

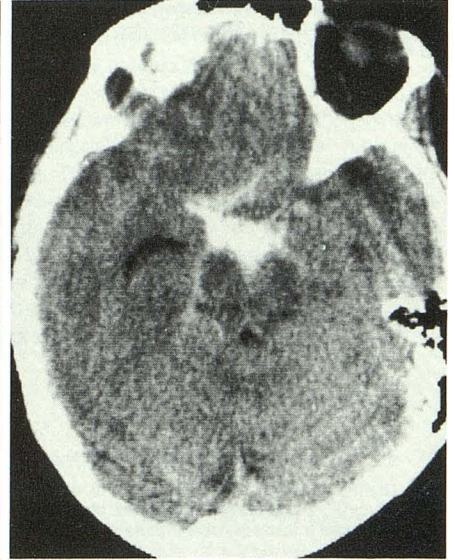
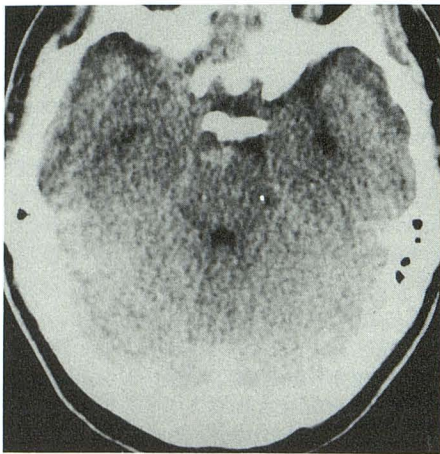
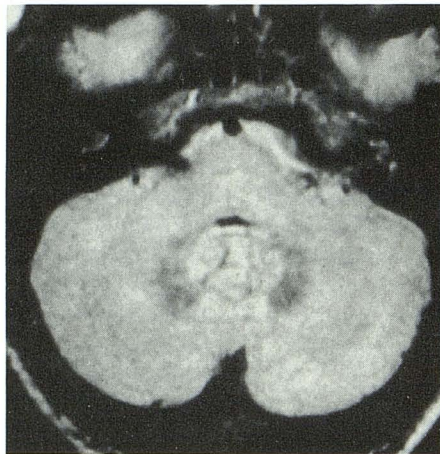


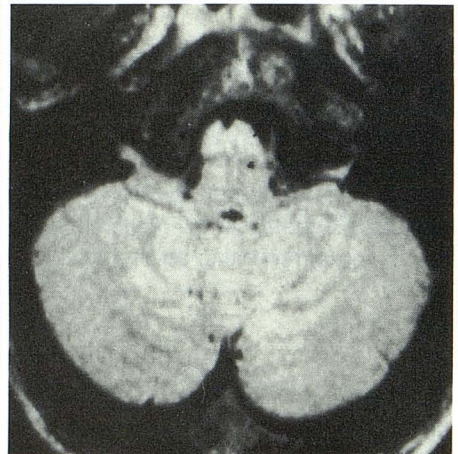
Fig. 7.—CT scan shows blood in interpeduncular fossa with extension to both ambient cisterns, chiasmal cistern, and basal part of sylvian fissure on the right, and to posterior part of anterior interhemispheric fissure.



A

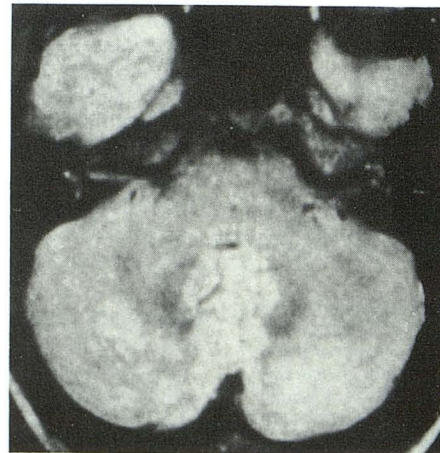


B

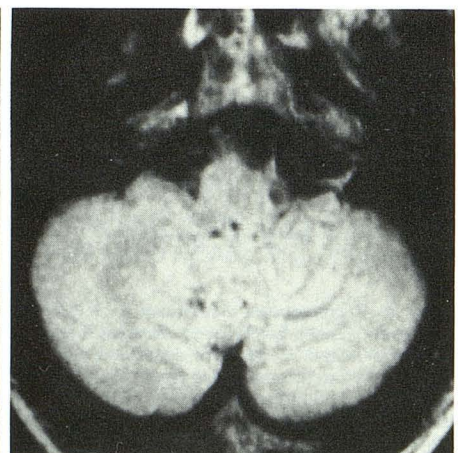


C

Fig. 8.—A-E, Blood in interpeduncular cistern on CT scan (A) and blood in front of pons (B) and medulla oblongata (C) on MR images (SE 2000/50) in same patient. MR images obtained 6 weeks later show that blood had disappeared (D and E).



D



E

		result of angiography		
		aneurysm	no aneurysm	total
prediction of observers	A			
	aneurysm	14	7	21
	no aneurysm	1	15	16
total		15	22	37

Fig. 9.—Schematic shows observers' predictions of aneurysmal origin of subarachnoid hemorrhage in posterior circulation on the basis of CT scans (observer A = upper right half, observer B = lower left half) compared with the results of angiography.

MR Scanning

Within 5 days after the hemorrhage, subarachnoid blood was best visualized on the first echo of the T2-weighted sequence (2000/50). On this sequence the blood showed increased signal relative to the adjacent brainstem. The appearance of blood was hyperintense on the second echo of the T2-weighted sequence. The signal of the blood on the T1-weighted sequence was intermediate between the signal of the brainstem and the signal of CSF. In all patients examined, blood was demonstrated immediately anterior to the lower brainstem. In one case the hemorrhage extended from the pons to the medulla (Figs. 8A–8C). After 6 weeks blood could no longer be demonstrated in any of the patients (Figs. 8D and 8E). A vascular abnormality could not be visualized, either in the acute phase or after the blood had disappeared.

Interobserver Study

The strongest agreement between the two observers was found in patients who had a CT scan in which the center of

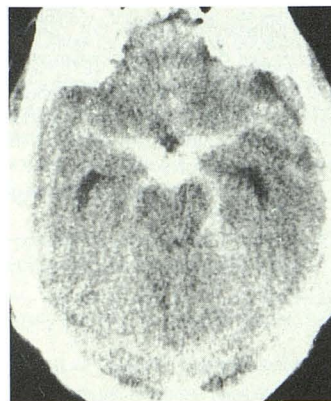


Fig. 10.—CT scan of a patient with nonaneurysmal perimesencephalic hemorrhage, mistaken for a ruptured basilar artery aneurysm.

the bleeding was not predominantly in the posterior portion of the basal cisterns. All these patients were considered to have the aneurysmal pattern of hemorrhage by both observers. A compilation of the observers' predictions of the origin of hemorrhage in the 37 patients with a predominance of blood in the posterior portion of the basal cisterns (15 patients with a proved posterior circulation aneurysm and 22 patients with a normal angiogram) appears in Figure 9. A fair proportion of patients with a posterior hemorrhage were thought to have an aneurysm when in fact they did not: three of 17 by observer A (false-positive rate 18%; 95% confidence interval [CI] 0.04–0.43) and seven of 21 by observer B (false-positive rate 33%; 95% CI 0.15–0.57). In all these CT scans the relative amount of cisternal blood in front of the brainstem was comparatively great (Fig. 10).

The predictive value of a perimesencephalic pattern of hemorrhage for a normal angiogram (true-negative rate) was 0.95 (95% CI 0.75–0.99) for observer A and 0.94 (95% CI 0.70–0.99) for observer B. Both observers mislabeled one (the same) patient with a proved basilar artery aneurysm as a perimesencephalic pattern of hemorrhage (false-negative rate for observer A 0.05 (95% CI 0.01–0.25) and for observer B 0.06 (95% CI 0.01–0.30)). All 15 CT scans correctly labeled as nonaneurysmal perimesencephalic by observer B were also labeled as nonaneurysmal perimesencephalic by observer A. The CT scans of the remaining three patients with a posterior hemorrhage and a normal angiogram were not identified as nonaneurysmal perimesencephalic by either observer. Thus, the observers disagreed on four patients with a normal angiogram. The κ value for interobserver agreement was 0.87 (95% CI 0.75–0.99).

Discussion

In approximately 15% of patients with subarachnoid hemorrhage no aneurysm is found despite high-quality four-vessel angiography [8]. In patients with a normal angiogram, a high rate of hemorrhages originating in the posterior portion of the basal cisterns has been noted by several authors [2, 3, 9–11]. In the present series of patients with nonaneurysmal perimesencephalic hemorrhage we found that the CT pattern of subarachnoid bleeding suggested a site of origin immediately anterior to the brainstem, usually in the interpeduncular and prepontine cisterns. In a few cases the suggested site of origin extended to the anterior part of one of the ambient cisterns. Prepontine blood was always present when this region was properly visualized. In only a few patients, subarachnoid blood extended farther backward to the quadrigeminal cistern or anteriorly to the basal part of the sylvian fissure or the posterior part of the anterior interhemispheric fissure. MR studies in these patients showed blood immediately anterior to the lower part of the brainstem. We never found complete filling of the anterior interhemispheric fissure, and extension to the lateral sylvian fissure was extremely uncommon and then only minimal. Frank intraventricular hemorrhage did not occur.

We found that this pattern of cisternal hemorrhage could be differentiated from patterns of subarachnoid hemorrhage

caused by a ruptured aneurysm in most patients. The predictive value of a perimesencephalic pattern of hemorrhage for a normal angiogram was very high, but a serious source of error is that the occasional patient with a ruptured aneurysm of the basilar artery may show a pattern of hemorrhage on CT resembling that of nonaneurysmal perimesencephalic hemorrhage. In our series, 11 of the 12 basilar artery aneurysms could easily be distinguished from nonaneurysmal perimesencephalic hemorrhage by either extension of blood into the anterior interhemispheric or lateral sylvian fissures or by the presence of intraventricular hemorrhage. In the 12th case of basilar artery aneurysm, however, both features were absent and the pattern of extravasation could not be distinguished from a perimesencephalic pattern of hemorrhage by either observer. A careful reconsideration of this misjudged CT scan of the patient with a proved basilar artery aneurysm revealed one possible distinguishing feature. The slice through the suprasellar cisterns in this particular patient showed a homogeneous filling by blood of all suprasellar cisterns (interpeduncular as well as chiasmatic) and both ambient cisterns, rather than a clot remaining confined immediately anterior to the midbrain and pons, which is characteristic of a perimesencephalic pattern hemorrhage. Studies with even larger series of patients are needed to validate this potential discriminating feature.

Given that the rare patient with a ruptured aneurysm of the basilar artery but a nonaneurysmal pattern of hemorrhage will still occur in one of every 20 (observer A) or 16 (observer B) cases in which a negative angiogram is predicted, the risk of missing a basilar artery aneurysm by omitting angiography in patients with this type of hemorrhage is about 5–6% (95% CI 0–31%). The chance of a fatal rehemorrhage in patients with a ruptured basilar artery aneurysm after the second week has been found to be 48% [12]. This risk of fatal rehemorrhage after omitting angiography clearly outweighs complications of angiography in patients with a normal angiogram (0.7%) [13] even if combined with the mortality of operations on a ruptured basilar artery aneurysm (6%) [14]. Therefore, we still advocate angiography in all patients with a perimesencephalic pattern of hemorrhage, despite the many negative results.

The cause of perimesencephalic hemorrhage remains elusive. Angiograms with particular attention to the venous phase [2] and MR scans with detailed views of the brainstem and surrounding cisterns have, to date, failed to detect a cause for nonaneurysmal perimesencephalic hemorrhage. Nevertheless, not only the negative findings on angiography but also certain features that are common to all patients with nonaneurysmal perimesencephalic hemorrhage, strongly argue against an undetected basilar artery aneurysm. These are (1) the localized nature of the clot, quite different from the extension in aneurysmal patterns; (2) the uncomplicated clinical course without rehemorrhage or ischemia [2]; and (3) the excellent prognosis after a mean follow-up period of 4 years (range, 18–83 months) without deterioration or rehemorrhage

in a large series of patients with perimesencephalic hemorrhage [5], whereas basilar artery aneurysms usually carry a fatal rehemorrhage risk of almost 50% in the first 4 years after the initial hemorrhage [12]. These features favor a venous or capillary rupture. Rupture of one of the anterior longitudinal pontine veins in the prepontine cistern or of the interpeduncular and posterior communicating veins in the interpeduncular cistern [15, 16] may explain both the clinical picture and the peculiar CT scan pattern. Widespread awareness of this CT pattern of hemorrhage may eventually be useful in determining the cause of this separate entity of nonaneurysmal hemorrhage.

REFERENCES

1. van Gijn J, van Dongen KJ. Computed tomography in the diagnosis of subarachnoid haemorrhage and ruptured aneurysm. *Clin Neurol Neurosurg* **1980**;82:11–24
2. van Gijn J, van Dongen KJ, Vermeulen M, Hijdra A. Perimesencephalic hemorrhage: a nonaneurysmal and benign form of subarachnoid hemorrhage. *Neurology* **1985**;35:493–497
3. Alexander MSM, Dias PS, Uttley D. Spontaneous subarachnoid hemorrhage and negative cerebral panangiography. *J Neurosurg* **1986**;64:537–542
4. Maurice-Williams RS. *Subarachnoid hemorrhage: aneurysms and vascular malformations of the central nervous system*. Bristol: Wright, **1987**: 101–105
5. Rinkel GJE, Wijndicks EFM, Vermeulen M, Hageman LM, Tans JTJ, van Gijn J. Outcome in perimesencephalic (nonaneurysmal) subarachnoid hemorrhage. *Neurology* **1990**;40:1130–1132
6. World Federation of Neurological Surgeons. Report of World Federation of Neurological Surgeons committee on a universal subarachnoid hemorrhage grading scale. *J Neurosurg* **1988**;68:985–986
7. Cohen J. A coefficient of agreement for nominal scales. *Educ Psychol Meas* **1960**;20:37–46
8. Kassell NF, Torner JC, Jane JA, Haley EC, Adams HP. The international cooperative study on the timing of aneurysm surgery. Part 2: Surgical results. *J Neurosurg* **1990**;73:37–47
9. Iwanaga H, Wakai S, Ochai, C, Narita J, Inoh S, Nagai M. Ruptured cerebral aneurysms missed by initial angiographic study. *Neurosurgery* **1990**;27:45–51
10. Cioffi F, Pasqualin A, Cavazzani P, Da Pian R. Subarachnoid hemorrhage of unknown origin: clinical and tomographical aspects. *Acta Neurochir* **1989**;97:31–39
11. Stober T, Emde H, Anstätt T, Freier G, Metzger U. Blood distribution in computer cranial tomograms after subarachnoid hemorrhage with and without an aneurysm on angiography. *Eur Neurol* **1985**;24:319–323
12. Troupp H. The natural history of aneurysms of the basilar bifurcation. *Acta Neurol Scand* **1971**;47:350–356
13. Mani RL, Eisenberg RL. Complications of cerebral arteriography: analysis of 5000 procedures. II. Relation of complication rates to clinical arteriographic diagnosis. *AJR* **1978**;131:867–869
14. Peerless SJ, Drake GG. Vertebro-basilar aneurysms. In: Wilson CB, Hoff JT, eds. *Current surgical management of neurological disease*. London: Churchill Livingstone, **1980**:144–168
15. Yasargil GM, Kasdaglis K, Jain KK, Weber HP. Anatomical observations of the subarachnoid cisterns of the brain during surgery. *J Neurosurg* **1976**;44:298–302
16. Braun JP, Tournade A, Ammerich H. Transverse anastomoses of the veins at the base of the brain. *Neuroradiology* **1976**;12:165–169