

# B-Mode Gray Scale Ultrasound of the Head in the Newborn and Young Infant

Diane S. Babcock<sup>1</sup>  
Bokyung K. Han<sup>1</sup>  
Garry W. LeQuesne<sup>1, 2</sup>

A technique using commercially available B-mode gray scale ultrasonography for imaging the head in the newborn and young infant is described. Serial scans were performed at several angles from the canthomeatal line. Images of technical quality previously unobtainable are shown. Normal anatomic structures such as ventricles, cerebral peduncles, pons, cerebellum, sulci, gyri, choroid plexus, falx cerebri, and tentorium cerebelli can be demonstrated. From April 1978 through December 1978, 165 gray scale ultrasonograms of the head on 111 children younger than 2 years were performed; 63 normal and 48 abnormal patients were studied, with hydrocephalus of various etiologies the most common abnormality. Porencephalic cysts, developmental anomalies, intraventricular and intracerebral hemorrhages, cephalohematoma, subdural hematomas, and arteriovenous malformations were demonstrated. Because of its safety and relatively low cost, ultrasonography proved to be an excellent method for following ventricular size and shunt function.

A-mode or one-dimensional ultrasonography has been used since 1955 to detect shifts of the midline intracranial structures. B-mode or two-dimensional ultrasonography of the brain was first reported by Vleiger et al. [1] in 1963. In 1974 and 1975, Kossoff, Garrett, et al. [2, 3] reported visualization of the normal anatomy and dilated ventricles in infants, and Shkolnik [4] reported demonstration of a brain tumor by gray scale ultrasonography. The significant technical improvement achieved in the current generation of gray scale B-mode equipment of increased resolution and improved image quality has increased our ability to study the head of newborn and young infants. Several recent reports have shown that various abnormal conditions can be demonstrated using B-mode gray scale ultrasonography [5-8]. We describe our technique for imaging heads with examples of normal anatomy and document our experience with ultrasonography for imaging a variety of abnormal conditions in the head of an infant.

## Method

At our institution, the examination is performed in the radiology department. The ultrasound room is equipped with air, suction, and oxygen outlets so that critical life support measures can be maintained. The infant's temperature is maintained with an overhead servo-control radiant heater. The head is turned to the side with the patient in a lateral position on a foam sponge so that the head is up off the table, thus improving access for the sector scans through the fontanelles and sagittal suture. Our radiology department nurse holds the head in this position and monitors the baby while the scan is performed (fig. 1). Sedation is not usually necessary, although chloral hydrate in a dose of 50 mg/kg may be used in older infants. Aqueous gel placed on the baby's head is used as the coupling agent.

While some information is obtained through the calvarium, we found that most of the useful information is obtained while scanning through the open sutures and fontanelles, and special attention is paid to these areas. Sector scans are made through these areas

Received April 10, 1979; accepted after revision October 30, 1979.

Presented at the annual meeting of the American Roentgen Ray Society, Toronto, March 1979.

This article appears in March *AJR* and March/April *AJNR*.

<sup>1</sup> Division of Roentgenology, Children's Hospital Medical Center, Cincinnati, OH 45229. Address reprint requests to D. S. Babcock.

<sup>2</sup> Present address: Department of Radiology, Adelaide Children's Hospital, North Adelaide, South Australia 5006, Australia.

*AJNR* 1:181-192, March/April 1980  
0195-6108/80/0102-0181 \$00.00  
© American Roentgen Ray Society



Fig. 1.—Sonographers performing ultrasound scan of head of premature infant.

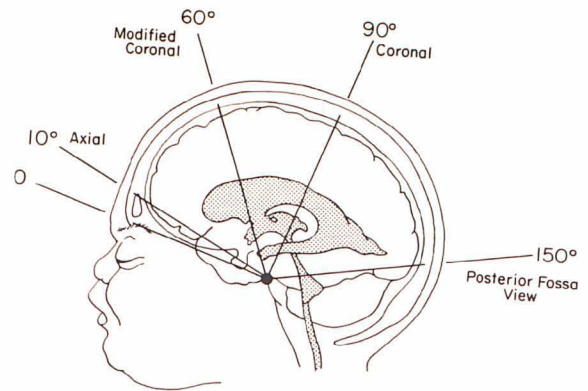
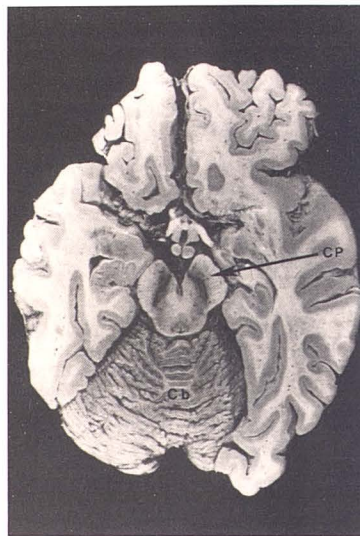
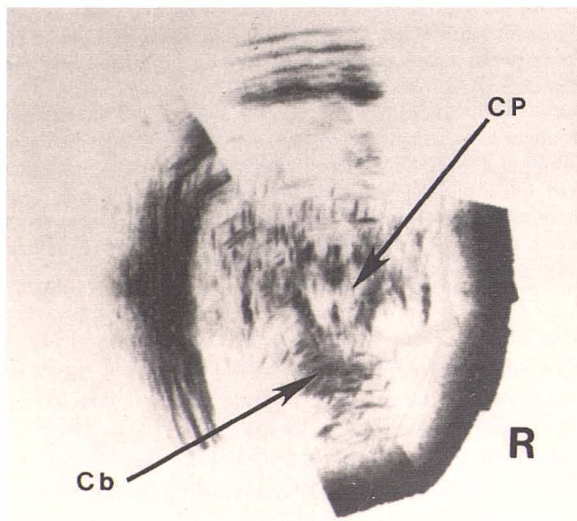
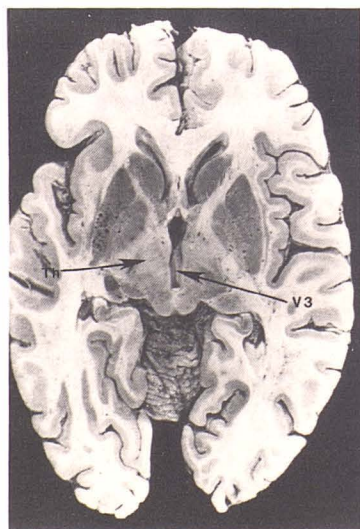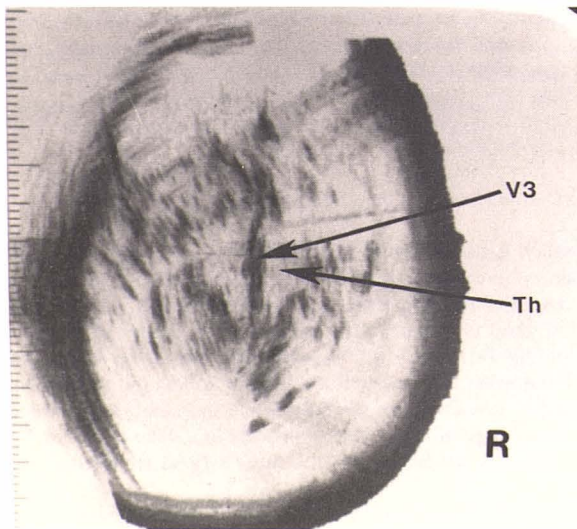


Fig. 2.—Scan angles: axial, coronal, modified coronal, and posterior fossa.



A



B

Fig. 3.—Axial scans with corresponding anatomic sections. A, Low scan. Bilobed midline structure, cerebral peduncles (CP). Echogenic vermis of cerebellum (Cb). B, Through level of third ventricle (V3) and thalamus (Th).

and if necessary the outline of the head is then filled in. Technically adequate examinations are obtained only in children under the age of about 2 years, or in older infants who have open sutures. We also found that long or thick hair interferes with the scanning contact and can cause an inadequate examination.

Using commercially available (Picker) 80L Ultrasonoscopes (analog and digital) and either 5 or 3.5 MHz focused transducers, serial scans of the entire head are performed at 5 mm intervals. We routinely do at least three, and sometimes four, projections (fig. 2). An axial series is performed parallel to a line  $10^\circ$  from the canthomeatal line that is comparable to the usual CT brain scan images. Scans are performed at 5 mm intervals starting at the level 1 cm above the external auditory meatus and working toward the top of head. Coronal and modified coronal series at angles  $90^\circ$  and  $60^\circ$  respectively, from the canthomeatal line often produce our best images. Scans are performed at 5 mm intervals starting as far anterior as we can make contact, and working posteriorly. A posterior fossa ( $150^\circ$ ) series is performed in selected cases in which posterior fossa abnormalities or a dilated fourth ventricle are suspected.

## Results

From April 1978 through December 1978, we performed 165 gray scale ultrasonograms of the head on 111 children younger than 2 years. All patients had clinical symptoms and/or signs suggesting intracranial disease. The examinations were considered normal in 63 and abnormal in 48 patients.

## Normal Anatomy

**Axial Sections.** A series of axial scans is performed at 5 mm intervals, starting at 1 cm above the level of the external auditory meatus. These correspond to the routine CT images. Representative axial sections are shown in figure 3. Shown alongside for reference are corresponding sections of adult human brain [9]. We chose a patient with minimally enlarged ventricles so that the anatomy is easier to see.

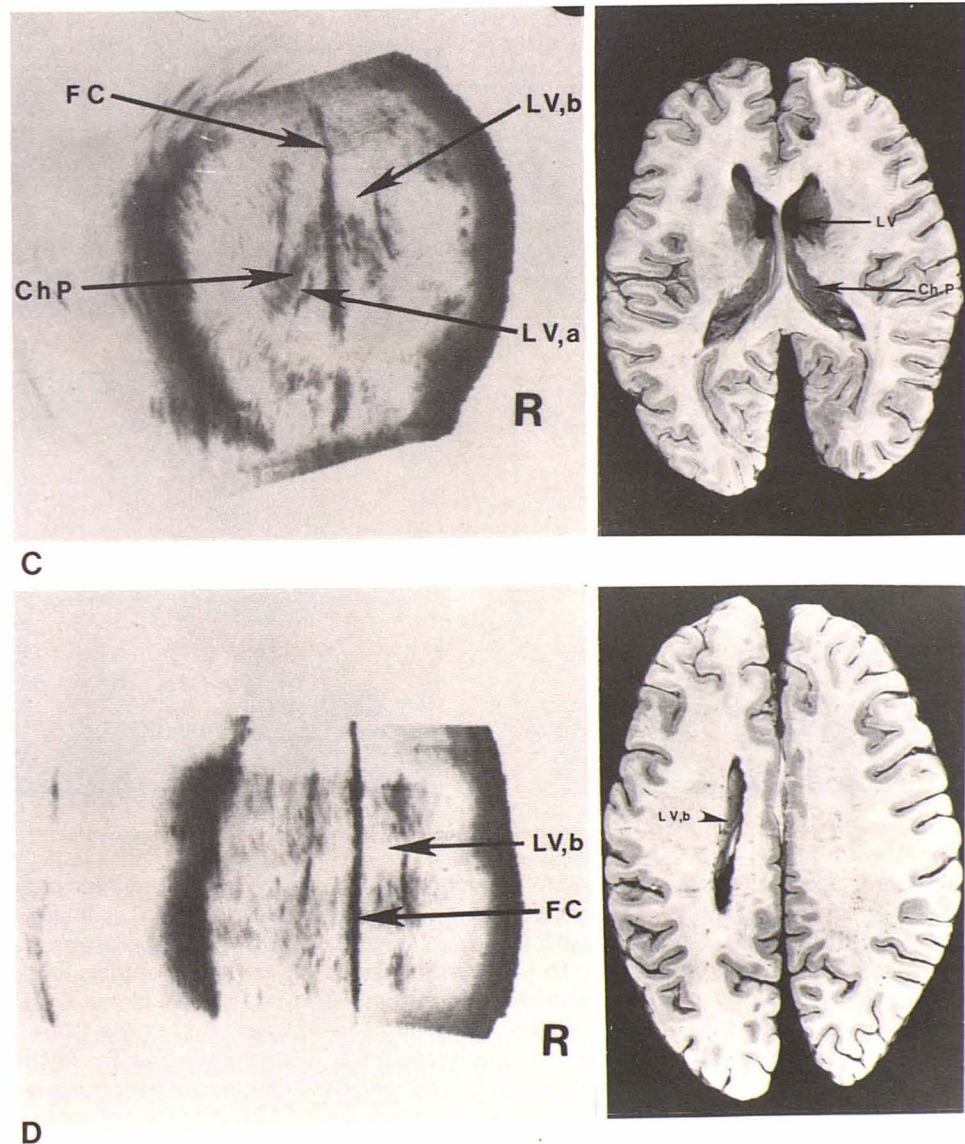


Fig. 3.—C, At level of bodies (LV,b) and atria (LV,a) of lateral ventricles. Midline falx cerebri (FC). Choroid plexuses (Ch P) are echogenic structures in floor of lateral ventricles. D, Through top of lateral ventricles. Midline falx cerebri (FC) with bodies of lateral ventricles (LV,b) on either side. (All anatomic sections reprinted from [9].)

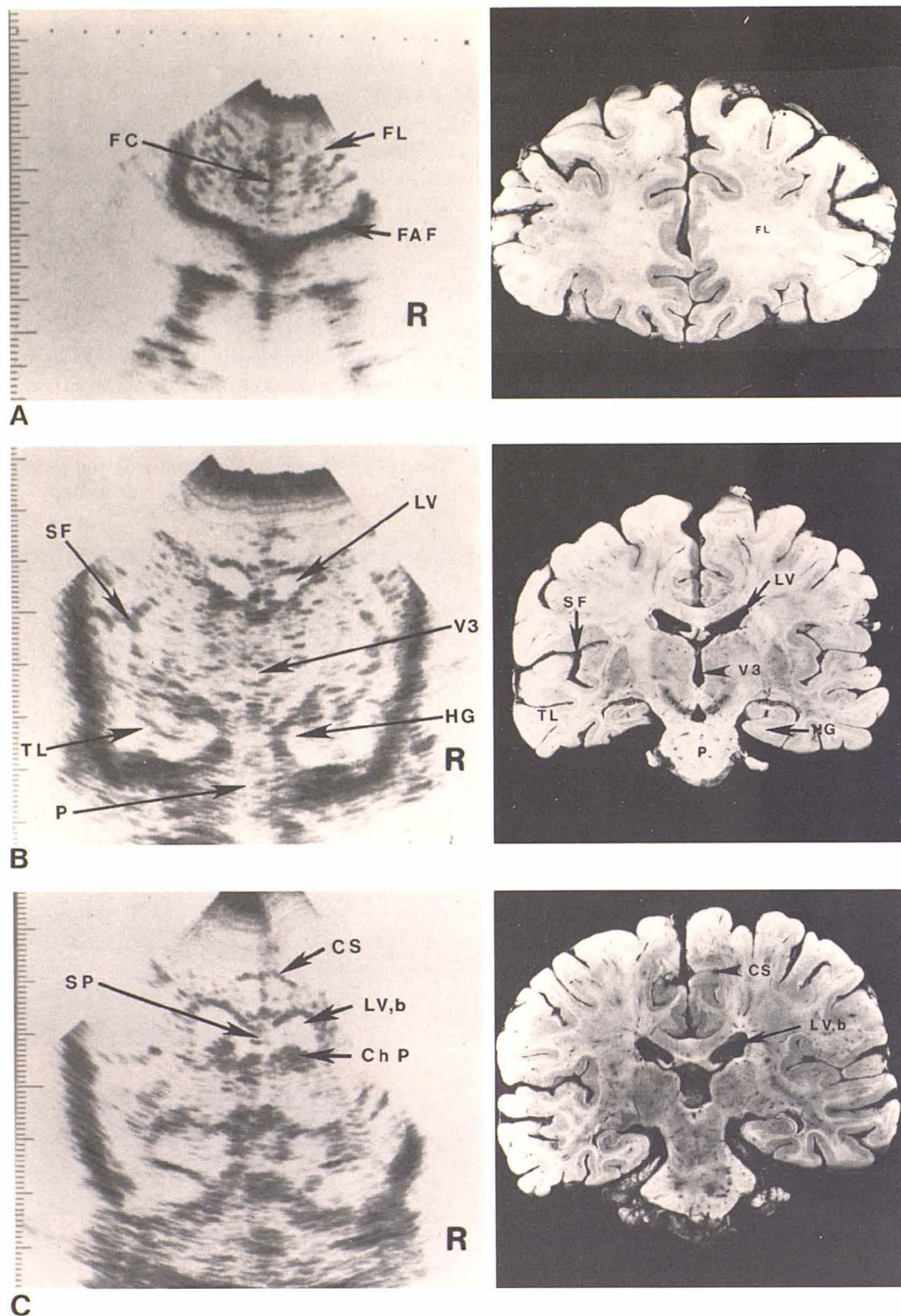


Fig. 4.—Coronal scans with corresponding anatomic sections. **A**, Anterior scan through frontal lobes (FL). Echogenic bony floor of anterior fossa (FAF) inferior. Midline linear echoes of falx cerebri (FC). **B**, Through lateral ventricles (LV) and third ventricle (V3). Temporal lobe (TL) with most medial gyrus, hippocampal gyrus (HG). Pons and mid-brain (P) inferior. Sylvian fissure (SF) produces Y-shaped echoes. **C**, Through bodies of lateral ventricles (LV,b) with choroid plexuses (Ch P) in floor. Septum pellucidum (SP) separates lateral ventricles. Cingulate sulci (CS).

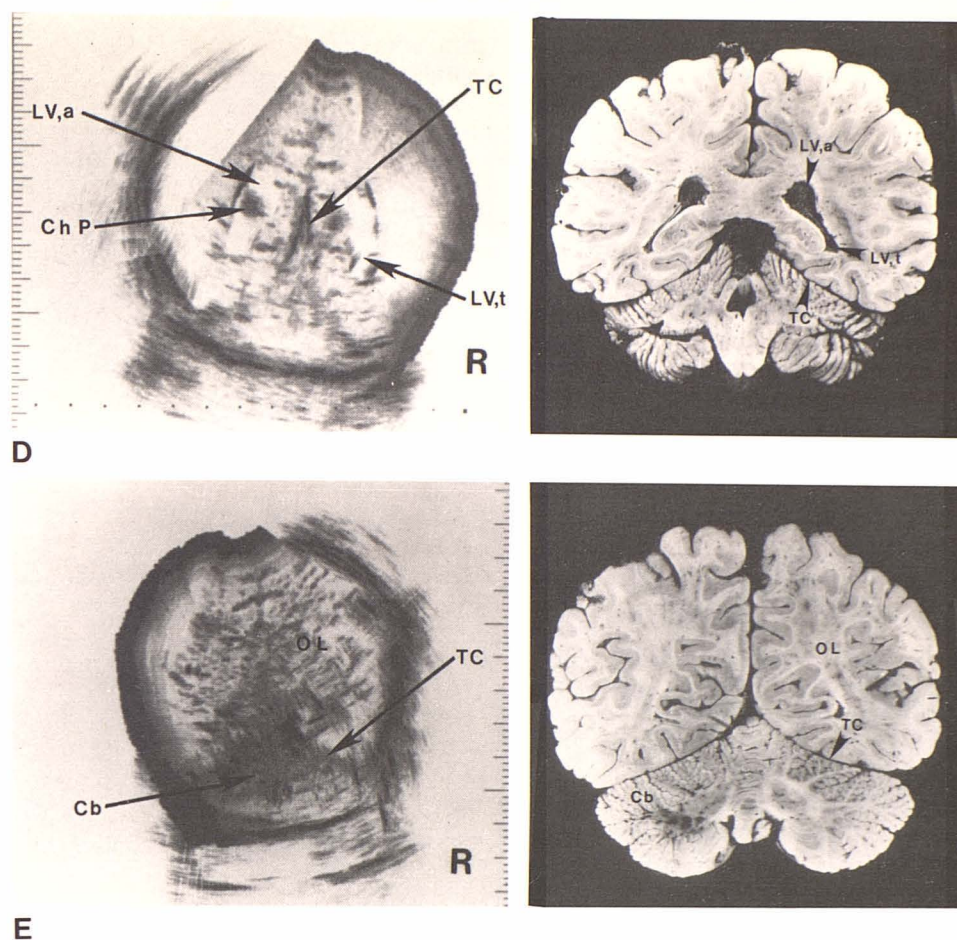
On the most caudad scan (fig. 3A) a bilobed midline structure corresponds to the cerebral peduncles and brain stem. This structure is mildly echogenic relative to the more echogenic surrounding structures. The area of increased echogenicity just posterior to the brain stem represents the vermis of the cerebellum. The cerebellum is highly echogenic compared with the cerebrum and other brain tissue.

A scan 1 cm superior to the previous level (fig. 3B) shows two relatively homogeneous, faintly echogenic structures

lying on either side of the midline that represent the area of the thalami. The lateral walls of the third ventricle are identified as parallel linear echoes in the midline at this level. The third ventricle is slitlike in the normal patient.

The next higher scan (fig. 3C) is at the level of the bodies and atria of the lateral ventricles. The strong linear echo complex from the falx cerebri is identified. The lateral ventricles are anechoic areas on either side of the falx and their lateral walls are seen as linear collections of echoes. The

Fig. 4.—**D**, Through atria of lateral ventricles (LV,a) joined by temporal horns (LV,t). Choroid plexuses (Ch P) and tentorium cerebelli (TC). **E**, Most posterior scan. Tentorium cerebelli (TC) with occipital lobes (OL) above echogenic cerebellum (Cb) inferior. (All anatomic sections reprinted from [9].)



choroid plexuses of the lateral ventricles are identified as echogenic structures in their floor.

The highest axial scan (fig. 3D) is through the top of the lateral ventricles. The midline strong linear echo collection represents the falx cerebri and extends the whole length of the head visualized. In the normal infant, the ratio of the distance between the midline and the lateral wall of the ventricle, and the distance between the midline and the inner table of the skull, lies in the range of 0.25–0.35 at the level of the body [2]. The fine echogenicity of the cerebral tissue is seen between the lateral ventricle and the inner table of the skull.

**Coronal Sections.** Figure 4 shows coronal sections (90°) at intervals from front to back with corresponding sections of the adult brain [9]. The first coronal section (fig. 4A) is through the frontal lobes. The fine low-level echoes represent cerebral tissue while the diffuse medium-level echoes represent sulci and vascular structures. The densely echogenic bony floor of the anterior fossa is seen inferior to the frontal lobes. The falx cerebri is identified as a linear echogenic structure in the midline between the frontal lobes.

The next more posterior scan is through the level of the lateral ventricles (fig. 4B) which are the fluid-filled structures on either side of midline. The temporal lobes can be identified separated from the midbrain and the pons. The hippo-

TABLE 1: Abnormal Ultrasound Findings

Abnormality	No. Patients (n = 111)
<b>Associated with hydrocephalus:</b>	
Meningomyelocele	15
Intraventricular hemorrhage	4
Intraparenchymal hemorrhage	1
Meningitis	3
Arteriovenous malformation	1
Encephalocele	1
Porencephalic cyst	1
Dandy-Walker cyst	1
Craniopharyngioma (retrospect)	1
Other	17
Subtotal	45
<b>Not associated with hydrocephalus:</b>	
Cephalohematoma	2
Cavum septum pellucidum	1
Subtotal	3
Total	48

campal gyri are their most medial gyri. The Sylvian fissures are seen as Y-shaped echogenic structures above the temporal lobes. The third ventricle is not well seen, presumably due to the ultrasound beam projecting parallel to its walls rather than perpendicular.

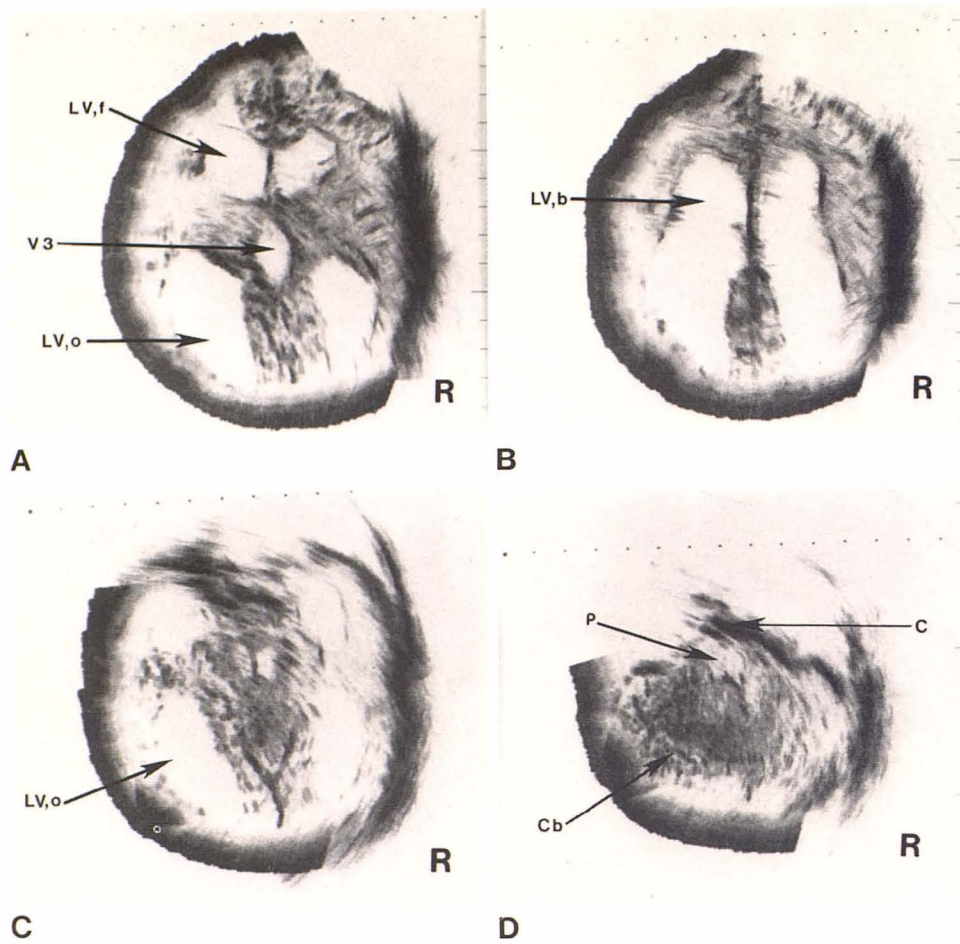


Fig. 5.—Case 1. Hydrocephalus in 7-day-old infant with lumbosacral meningocele and large head. A and B, Axial scans. Moderate dilatation of frontal horns (LV,f), bodies (LV,b), and occipital horns (LV,o) of lateral ventricles and third ventricle (V3). Thickness of moderately echogenic cerebral cortex can be measured. C and D, Posterior fossa views. Dilated occipital horns (LV,o) and atria of lateral ventricles. Cerebellum (Cb) is highly echogenic structure on lower scan (D). Fourth ventricle not identified because of usually low position and normal size with Arnold-Chiari II malformation. Bilobed, mildly echogenic pons (P) between clivus (C) and cerebellum.

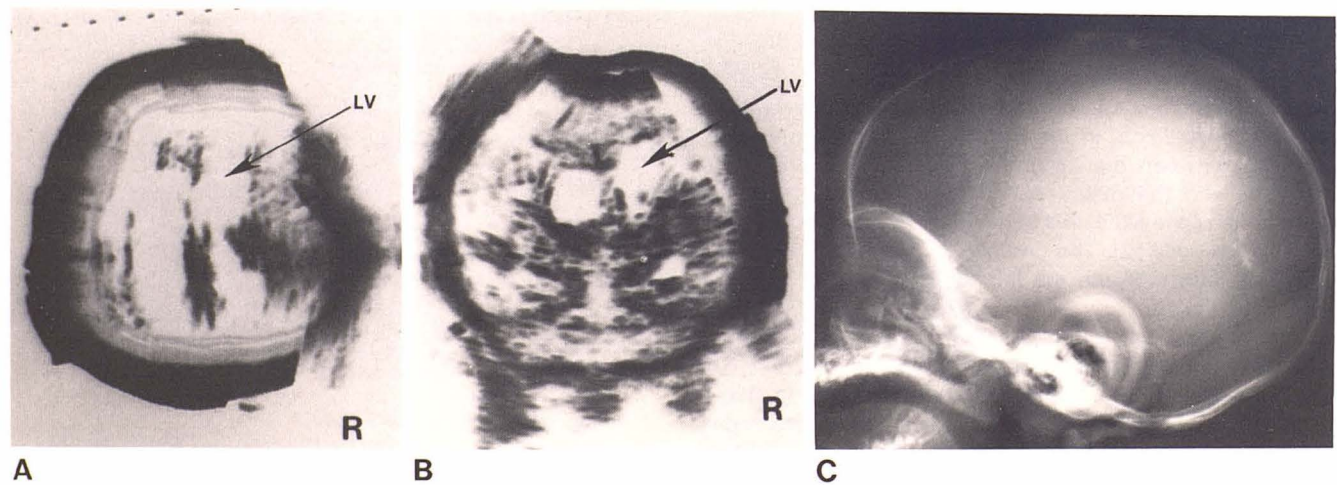


Fig. 6.—Case 2. Hydrocephalus in 6-week-old infant with streptococcal meningitis diagnosed at age 2 weeks. Axial (A) and coronal (B) scans. Moderate enlargement of lateral ventricles (LV). C, At age 4½ months. Intracranial calcifications result from infection.

On the next scan (fig. 4C), through the bodies of the lateral ventricles, the echogenic structures in the floor of the lateral ventricles are the choroid plexuses. The septum pellucidum is an echogenic linear structure separating the

lateral ventricles in the midline. The body of the corpus callosum lies above, and forms the roof of, the lateral ventricles. Two linear structures on either side of the midline represent the cingulate sulci.

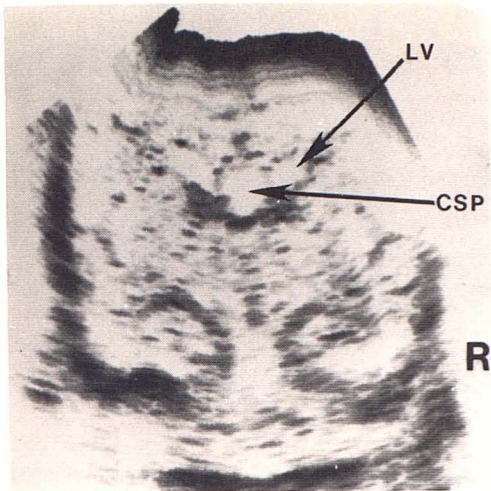


Fig. 7.—Case 3. Cavum septi pellucidi in 3-week-old twin from whom bloody fluid was aspirated at spinal tap. Coronal scan through level of bodies of lateral ventricles (LV). Mild dilatation of lateral ventricles. Fluid-filled structure between bodies of lateral ventricles represents cavum septi pellucidi (CSP). Hippocampal gyrus and Sylvian fissure also seen.

Fig. 8.—Case 4. Dandy-Walker cyst in 2-week-old infant with marked hydrocephalus and skeletal malformations. Axial ultrasound scan (A) and comparable CT scan (B). Dilated lateral ventricles (LV) displaced laterally by large midline fluid collection (Cy). Large fluid collection thought to likely represent large Dandy-Walker cyst, although patient is still living and this is unproven. Thin rim of brain tissue over frontal and parietal regions.

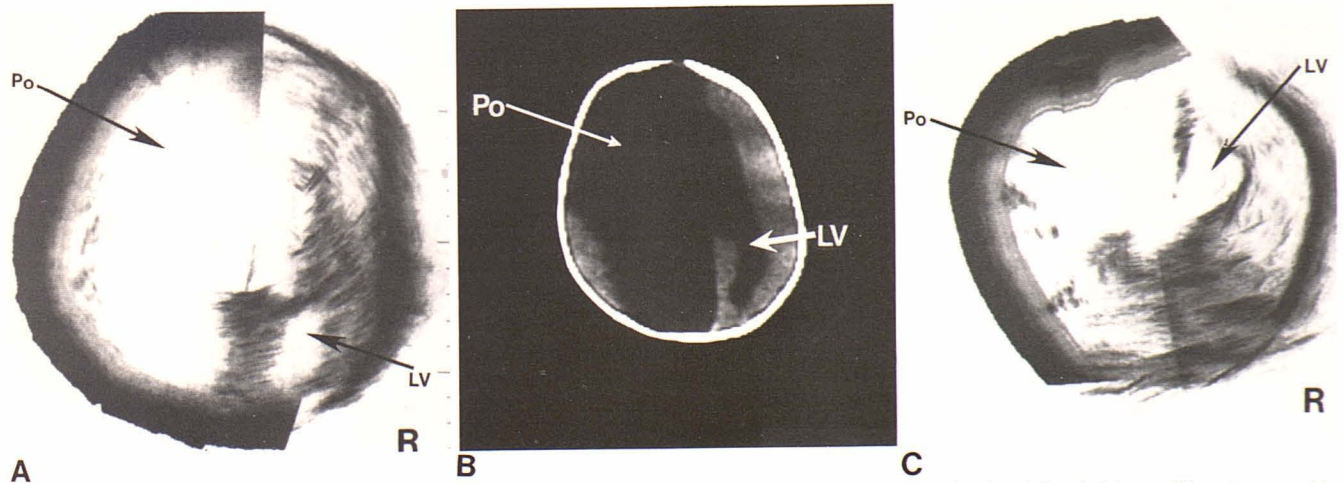
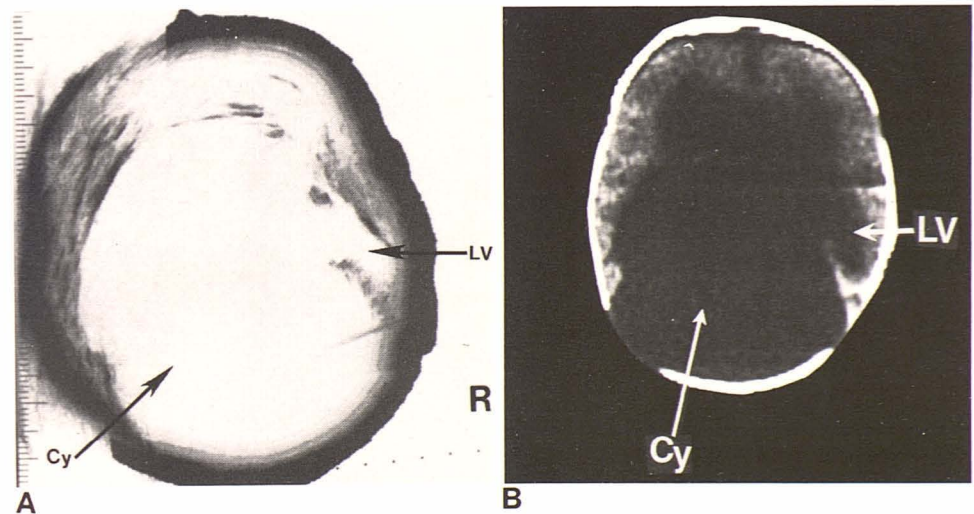


Fig. 9.—Case 5. Porencephalic dilatation of lateral ventricle in 7-month-old macrocephalic infant with increasing head size. Axial scan (A) and comparable CT scan (B). Large fluid-containing structure (Po) replaces most of left hemisphere and extends from anterior to posterior fossa. Right lateral ventricle (LV) appears moderately dilated and midline falx cerebri displaced from left to right. C, Coronal view. Again, Large cystic structure (Po) in left hemisphere represents porencephalic dilatation of left lateral ventricle. Moderately dilated right lateral ventricle (LV) with shift of falx cerebri from left to right.

On the next, more posterior scan (fig. 4D) the atria of the lateral ventricles are identified with the temporal horns leading into them. The echogenic choroid plexuses are seen within the ventricles. The falx cerebri midline linear echo is seen to separate into a V-shaped echogenic structure representing the tentorium cerebelli. The cerebellum is just inferior to the tentorium.

On the most posterior scan (fig. 4E) the tentorium cerebelli is identified with moderately echogenic cerebrum of the occipital lobe above it and the densely echogenic cerebellum inferior to it.

*Abnormal Anatomy*

Of the 48 examinations considered abnormal, hydrocephalus of various etiologies was the most common abnormality (table 1). Representative case reports are given in figures 5-16.

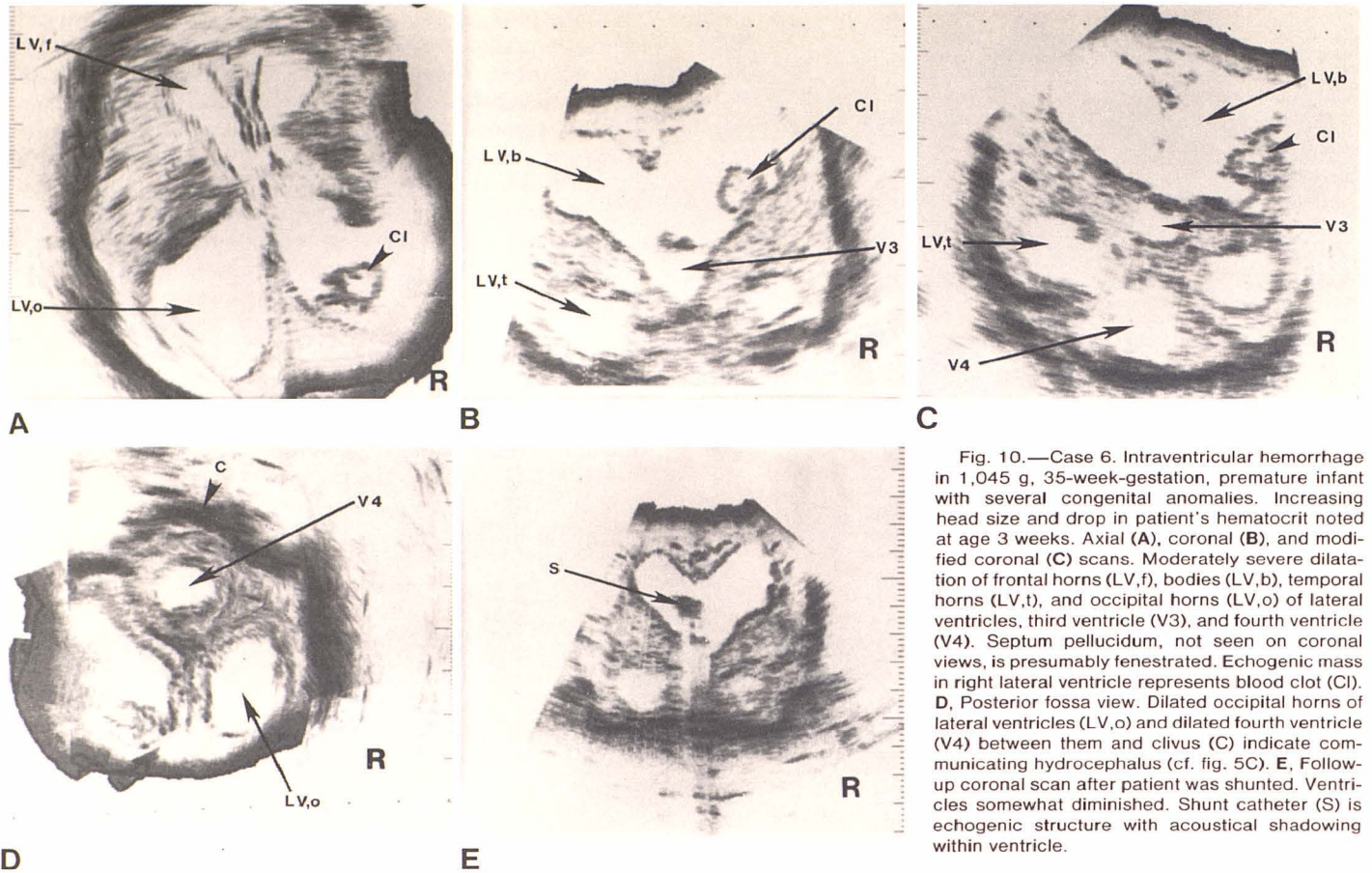


Fig. 10.—Case 6. Intraventricular hemorrhage in 1,045 g, 35-week-gestation, premature infant with several congenital anomalies. Increasing head size and drop in patient's hematocrit noted at age 3 weeks. Axial (A), coronal (B), and modified coronal (C) scans. Moderately severe dilatation of frontal horns (LV,f), bodies (LV,b), temporal horns (LV,t), and occipital horns (LV,o) of lateral ventricles, third ventricle (V3), and fourth ventricle (V4). Septum pellucidum, not seen on coronal views, is presumably fenestrated. Echogenic mass in right lateral ventricle represents blood clot (CI). D, Posterior fossa view. Dilated occipital horns of lateral ventricles (LV,o) and dilated fourth ventricle (V4) between them and clivus (C) indicate communicating hydrocephalus (cf. fig. 5C). E, Follow-up coronal scan after patient was shunted. Ventricles somewhat diminished. Shunt catheter (S) is echogenic structure with acoustical shadowing within ventricle.

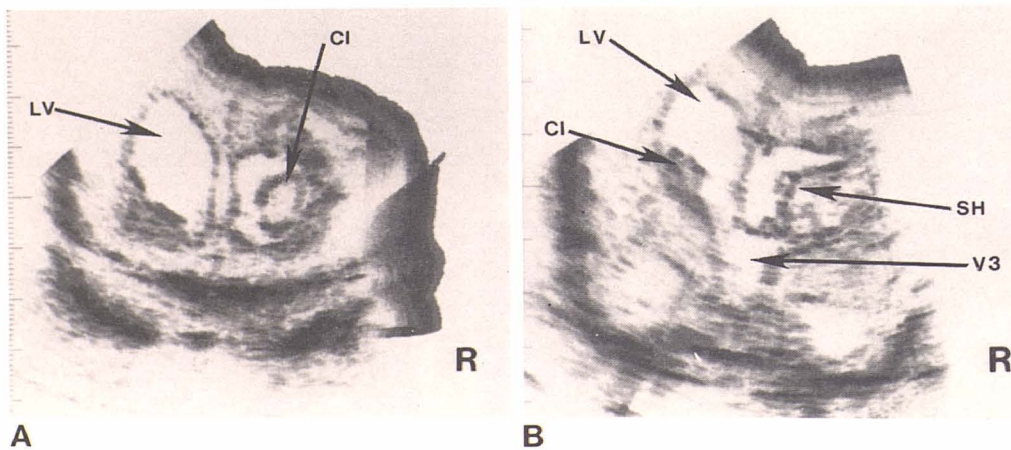


Fig. 11.—Case 7. Intraventricular hemorrhage in 1,080 g, 28-week-gestation infant with respiratory distress syndrome, patent ductus arteriosus, sepsis, and seizure disorder. At age 3 weeks, increasing head size was noted. A, More anterior coronal scan. Round echogenic mass of clot (CI) within right lateral ventricle. B, Coronal scan through bodies of lateral ventricles. Mass bulges into lateral aspect of right lateral ventricle, likely representing area of subependymal hemorrhage (SH).

**Discussion**

Our study demonstrates that, with the latest gray scale ultrasound equipment, a considerable amount of information about the intracranial anatomy can be obtained in the normal infant brain as well as in a variety of abnormal conditions, as shown in the representative cases. Although the ultrasonic beam is partially attenuated by bone, the thinner infant skull contains less organic material and enough of the sound

beam is transmitted to image the intracranial structures. Also, in the infant, the sound beam can be transmitted through the open sutures where there is little attenuation, allowing the transmission and display of low-energy-level echoes that arise from the brain tissue. These low-level echoes can then be displayed in shades of gray, thus enabling differentiation between different brain tissues such as cerebrum and cerebellum. Fissures, the falx cerebri, the tentorium cerebelli, and the septum pellucidum are strongly



Fig. 12.—Case 8. Intracerebral hemorrhage in full-term infant who had right-side seizure at age 2 days. Axial (A) and coronal (C) scans. Large, highly echogenic mass in left frontal lobe thought to represent intracerebral hemorrhage (H). Right lateral ventricle (LV) mildly dilated and mild shift of midline structures from left to right. B, Corresponding axial CT scan without contrast. Large frontal lobe mass with area of increased density compatible with intracerebral hematoma (H). Patient did well clinically. D, Follow-up coronal scan 6 weeks later. Large left frontal lobe mass has partially liquified and anechoic. Blood clot retracting.

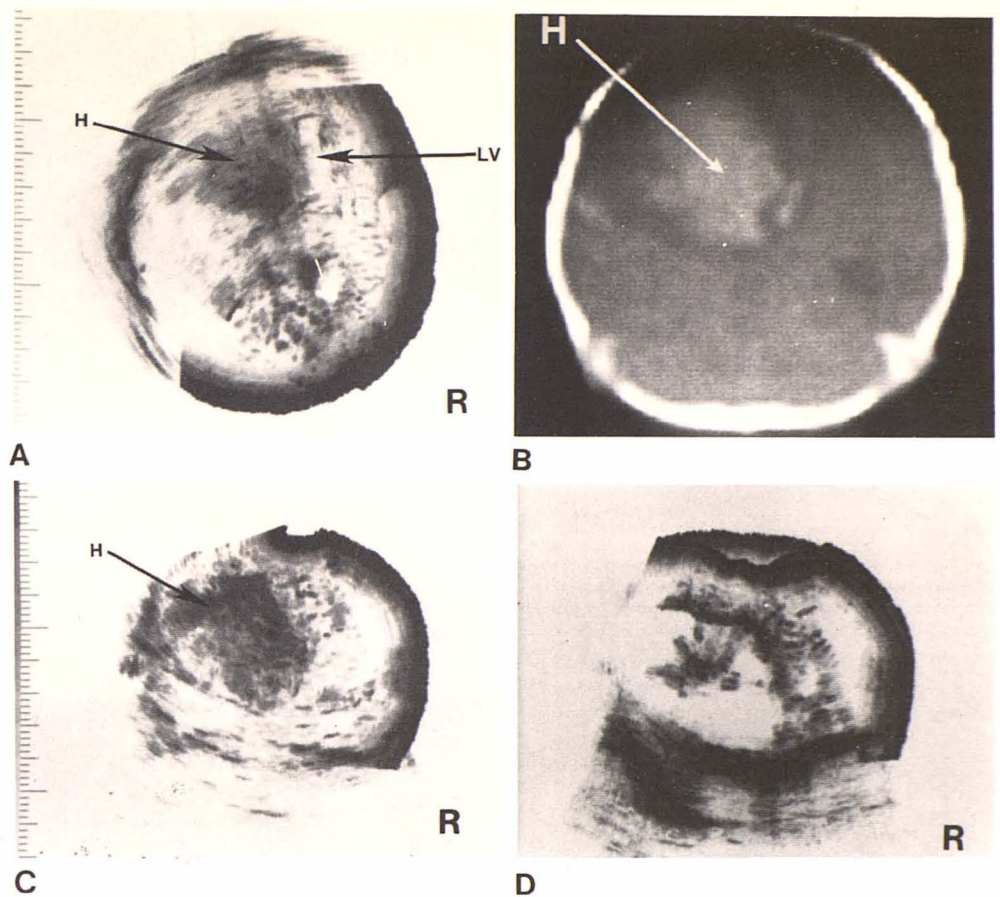
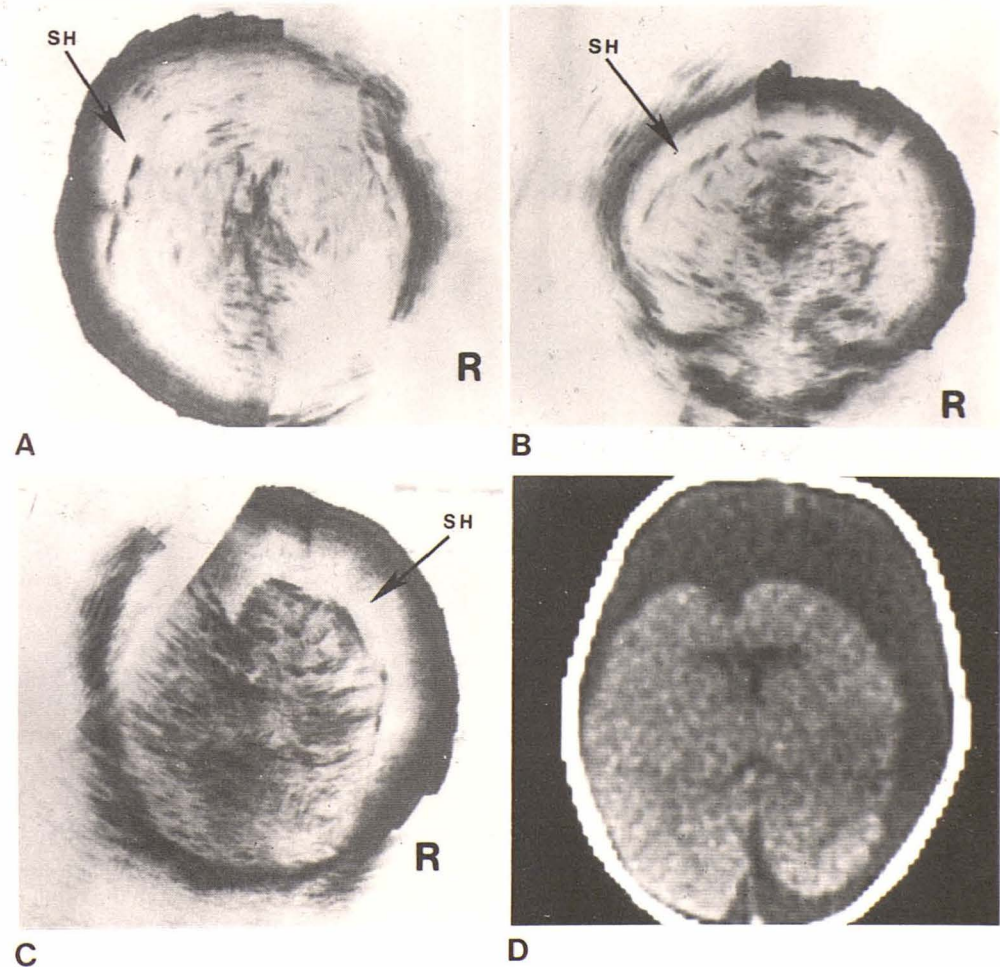


Fig. 13.—Case 9. Subdural hematoma in 3-week-old infant with birth history of difficult, traumatic forceps delivery and right parietal cephalohematoma. She did well at home until seizures developed at age 3 weeks. Axial (A) and coronal (B) scans. Large bilateral subdural fluid collections (SH) and subdural taps yielded bloody fluid. Subdural hematomas repeatedly tapped but reaccumulated and enlarged on axial ultrasound scan (C) and CT scan (D). (Case 9 seen after original 111 patients.)



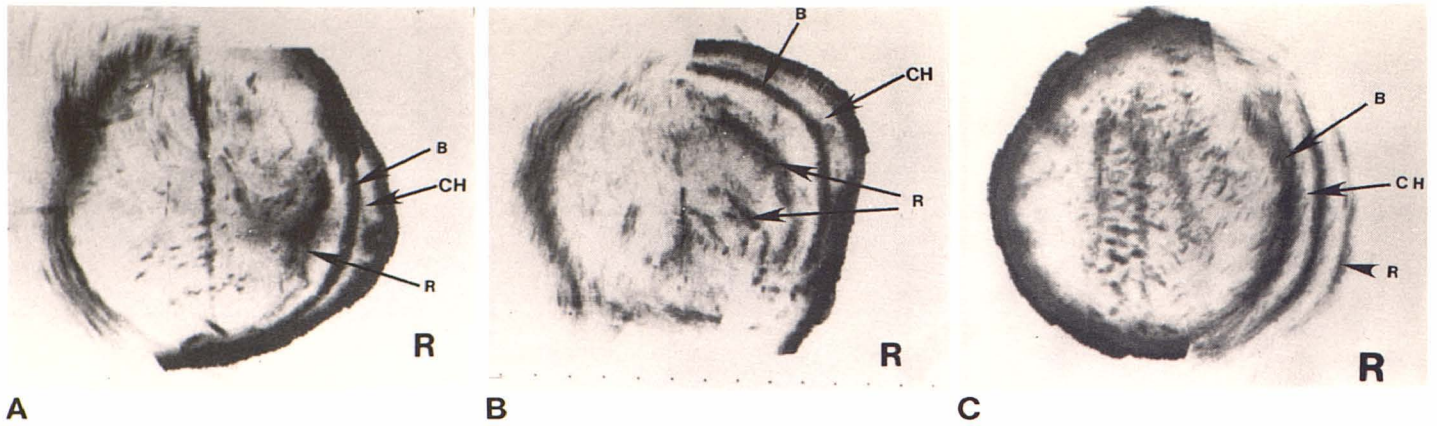


Fig. 14.—Case 10. Cephalohematoma in 3-day-old infant with swelling over right parietal region noted at birth. Axial (A) and coronal (B) scans. Cephalohematoma (CH) in right posterior parietal region with separation of scalp from bony skull (B) by hematoma. Reverberation lines (R) paralleling skull, apparently within calvarium, are thought to be artifactual, but are suspicious for subdural hematoma although there is no shift of midline echoes and they are seen outside head when patient is scanned from opposite side (C).

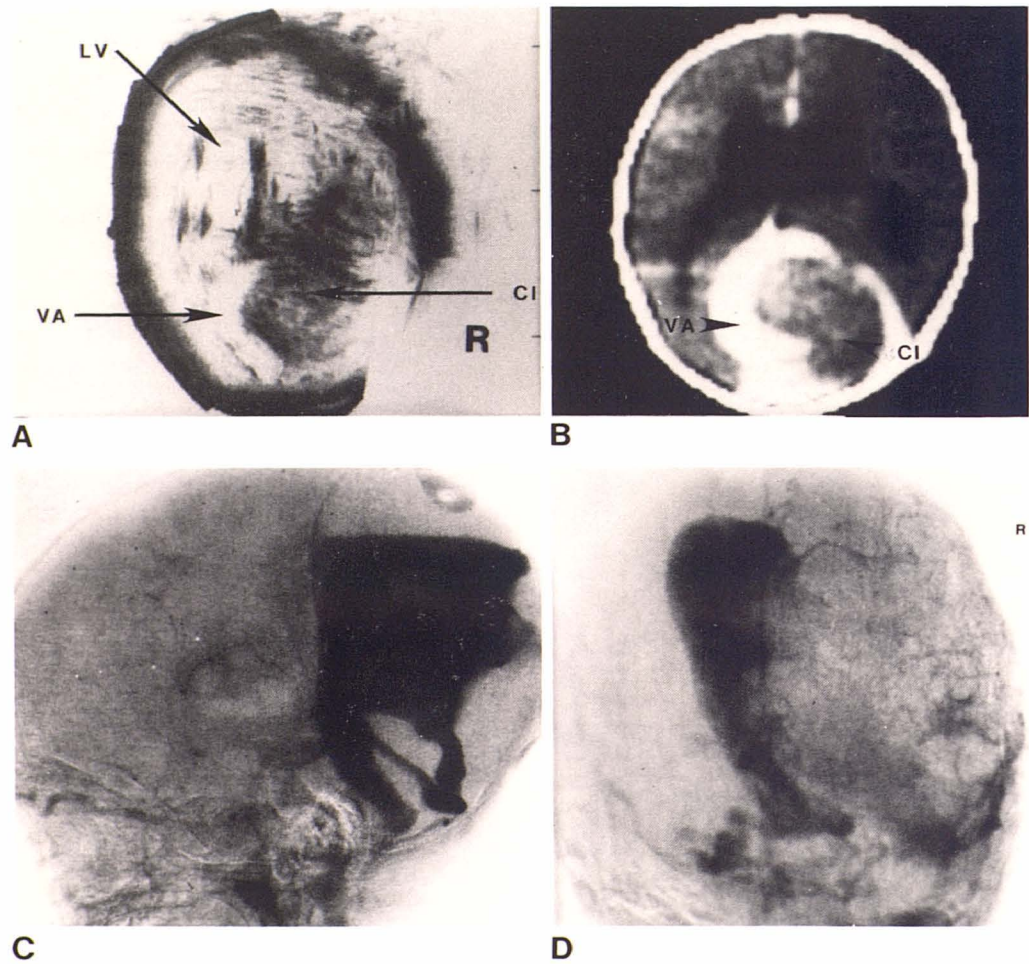


Fig. 15.—Case 11. Arteriovenous malformation in 2-month-old infant with enlarging head, lethargy, and vomiting. Axial ultrasound scan (A) and corresponding CT scan (B). Moderate enlargement of the lateral ventricles (LV). Large echogenic mass (CI) in occipital area with surrounding semicircular anechoic zone (VA). CT findings were similar with semicircular structure enhancing after contrast material injection, suggesting vascular structure. C and D, Angiograms. Large, complex dural venous aneurysm containing blood clot in region of straight sinus and posterior falx cerebri.

echogenic. The impedance mismatch between brain and cerebrospinal fluid allows the demonstration of the walls of any intracranial fluid collection such as the ventricles or cysts. Ultrasonograms show the size and shape of the ventricles and thus hydrocephalus of various etiologies can be evaluated, graded, and followed. Other abnormal cystic

structures within the head such as porencephalic cysts and Dandy-Walker cysts can be identified and evaluated. Solid masses such as blood clot or shunt tubes can be identified within the ventricles and other fluid collections. Abnormal masses within the brain parenchyma such as hematoma and arteriovenous malformations can also be demonstrated. We

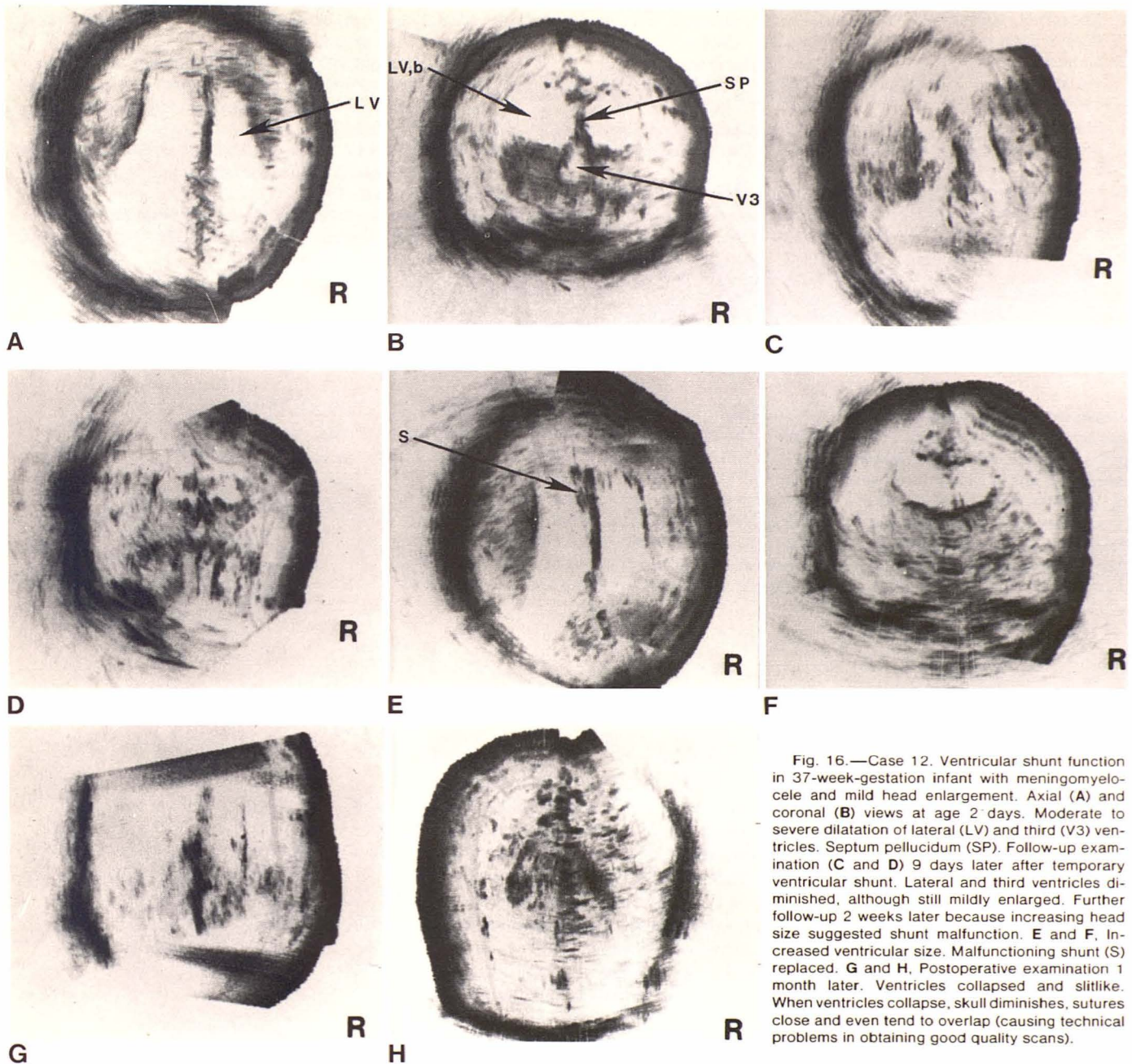


Fig. 16.—Case 12. Ventricular shunt function in 37-week-gestation infant with meningocele and mild head enlargement. Axial (A) and coronal (B) views at age 2 days. Moderate to severe dilatation of lateral (LV) and third (V3) ventricles. Septum pellucidum (SP). Follow-up examination (C and D) 9 days later after temporary ventricular shunt. Lateral and third ventricles diminished, although still mildly enlarged. Further follow-up 2 weeks later because increasing head size suggested shunt malfunction. E and F, Increased ventricular size. Malfunctioning shunt (S) replaced. G and H, Postoperative examination 1 month later. Ventricles collapsed and slitlike. When ventricles collapse, skull diminishes, sutures close and even tend to overlap (causing technical problems in obtaining good quality scans).

have very little experience with brain tumors, partly because they are rare in this age group.

In those cases where CT, pathologic, or other confirmation was available, the correlation between these other methods and ultrasound was excellent. Ultrasound has several advantages compared with CT, angiography, pneumoencephalography, and other methods of evaluating the brain. It uses nonionizing radiation and is noninvasive. The brain can be imaged in several planes, including axial, coronal, modified coronal, and posterior fossa views. No sedation is necessary in most infants. The cost of ultrasound equipment and examinations is lower and ultrasound equipment is available in more hospitals than is CT. We believe the simplicity, safety, and economics of ultrasonography

make it highly desirable as a noninvasive screening procedure. This is particularly true where CT scanning is unavailable or difficult to obtain.

#### ACKNOWLEDGMENTS

We thank Marsha Ellington and Theresa Skelly for technical assistance; Marlena Tyre for secretarial assistance; Corning Benton and J. Scott Dunbar for editorial assistance; and Robert Lukin, Cincinnati General Hospital, for the CT head scans in this paper.

#### REFERENCES

1. Vlioger M de, Sterke A, de Molin CE, Van der Ven C. Ultrasound for two dimensional echoencephalography. *Ultrasonics* 1963;1:148-151

2. Kossoff G, Garrett WJ, Radavanovich G. Ultrasonic atlas of normal brain of infant. *Ultrasound Med Biol* **1974**;1:259-266
3. Garrett WJ, Kossoff G, Jones RFC. Ultrasonic cross-sectional visualization of hydrocephalus in infants. *Neuroradiology* **1975**;8:279-288
4. Shkolnik A. B-mode scanning of the infant brain. A new approach case report. Craniopharyngioma. *JCU* **1975**;3:229-231
5. Lees RF, Harrison RB, Sims TL. Gray scale ultrasonography in the evaluation of hydrocephalus and associated abnormalities in infants. *Am J Dis Child* **1978**;132:376-378
6. Skolnick ML, Rosenbaum AE, Matzuk T, Guthkelch AN, Heinz ER. Detection of dilated cerebral ventricles in infants. A correlative study between ultrasound and computed tomography. *Radiology* **1979**;131:447-451
7. Morgan CL, Trought WS, Rothman SJ, Jimenez JP. Comparison of gray-scale ultrasonography and computed tomography in the evaluation of macrocrania in infants. *Radiology* **1979**;132:119-123
8. Johnson ML, Mack LA, Rumack CM, Frost M, Rashbaum C. B-Mode echoencephalography in the normal and high risk infant. *AJR* **1979**;133:375-381
9. Matsui T, Hirano A. *An atlas of the human brain for computerized tomography*. Tokyo: Igaku-Shoin, **1978**:154, 158, 180, 426, 430, 434, 440, 448, 410