

# MR of Primary CNS Lymphoma in Immunologically Normal Patients

Simon M. Roman-Goldstein,<sup>1,2,6</sup> David L. Goldman,<sup>4</sup> John Howieson,<sup>1</sup> Rod Belkin,<sup>5</sup> and Edward A. Neuwelt,<sup>3</sup>

**Purpose:** To describe the MR findings of primary CNS lymphoma. **Methods:** MR scans of 20 patients with histologically proved primary CNS lymphoma were reviewed. We evaluated the size, multiplicity, signal intensities, and enhancement characteristics of the lesions. We divided the lesions into an enhancing area referred to as Zone 1 and abnormal signal surrounding this, referred to as Zone 2. **Results:** Primary CNS lymphoma presented as solitary enhancing lesions in 40% of the patients and multiple lesions in 40%. Thirty-three separate lesions were visible: 58% abutted the ventricular system, 76% showed a homogenous enhancement pattern, and 79% showed marked enhancement. In 64% of the lesions, Zone 1 and Zone 2 showed different signal intensities on T1-weighted images. **Conclusions:** Primary CNS lymphoma usually presents as solitary or multiple dense homogenous enhancing lesions that abut an ependymal surface. These lesions can be divided into an enhancing area and an area of surrounding abnormal signal. These two areas often have different signal intensities on unenhanced T2-weighted images. These findings are sufficiently suggestive of the diagnosis of primary CNS lymphoma that a needle biopsy be performed based on these findings and appropriate therapy can then be instituted.

**Index terms:** Lymphoma; Brain neoplasms, magnetic resonance

AJNR 13:1207-1213, Jul/Aug 1992

Primary central nervous system (CNS) lymphoma represents about 1% of all intracranial neoplasms and about 1% of all lymphomas (1). It is one of the CNS manifestations of AIDS (2). Although this is an uncommon neoplasm, a three-fold increase in non-AIDS-related CNS lymphoma has been noted in recent years (3). This tumor is histologically similar to lymphomas outside the CNS (4, 5).

The computed tomography (CT) findings of primary CNS lymphoma have been described previously as an isodense to hyperdense lesion before iodinated contrast administration and shows postcontrast enhancement with a variable amount of abnormal density surrounding the enhancing lesion (6, 7). Magnetic resonance (MR) imaging shows a lesion that is isointense or slightly hyperintense to gray matter on T2-weighted images (T2-WI) with minimal mass effect (8). Prior communications have included the imaging findings in both immunocompromised and nonimmunocompromised patients. This communication discusses the MR characteristics of primary CNS lymphoma in immunologically normal patients.

## Patients and Methods

Patients are referred to our institution for treatment of primary CNS lymphoma using osmotic blood-brain barrier disruption with intraarterial chemotherapy, as has been previously described (9). Consecutive patients with pathologically proved primary CNS lymphoma, who had an MR scan before any radiation therapy or chemotherapy, are reported in this study. Patients underwent bone marrow aspiration and abdominal CT scan to exclude systemic

Received August 2, 1991; accepted and revision requested September 16; revision received October 22.

This work was supported by the Veterans Administration Merit Review Grant, and the National Institutes of Health, Grant No. 31770.

<sup>1</sup>Departments of Diagnostic Radiology, <sup>2</sup>Neurology, and <sup>3</sup>Neurosurgery, Oregon Health Sciences University and Portland Veterans Administration Medical Center, 3181 SW Sam Jackson Park Road, Portland, OR 97201-3098.

<sup>4</sup>Fourth Corner Neurosurgical Associates, 2940 Squalicum Parkway, Suite 201, Bellingham, WA 98225.

<sup>5</sup>Department of Radiology, Southwest Washington Medical Center, Vancouver, WA 98663.

<sup>6</sup>Address reprint requests to Simon M. Roman-Goldstein, MD, Department of Diagnostic Radiology—Neuroradiology Division, Oregon Health Sciences University, 3181 SW Sam Jackson Park Road, Portland, OR 97201-3098.

AJNR 13:1207-1213, Jul/Aug 1992 0195-6108/92/1304-1207

© American Society of Neuroradiology

lymphoma. Patients who had prior organ transplants, were immunosuppressed, or had lymphoma outside the CNS were excluded from this study. All pathology specimens were reviewed and classified according to the working formulation before inclusion in the study (10).

All patients received a contrast-enhanced CT Scan on a 9800 CT (General Electric, Milwaukee, WI) prior to treatment. We gave a bolus of either a mixture of diatrizoate meglumine and diatrizoate sodium (Renografin 60, Squibb Diagnostics, New Brunswick, NJ) or iopamidol (Isovue 300, Squibb Diagnostics) and scanned 30 minutes after contrast infusion. MR scans were obtained on a 1.5 T Signa Unit (General Electric). Sagittal T1-weighted images (T1-WI) with 5-mm slice thickness and pulse sequence of 600/20/2 (TR/TE/excitations), and coronal and axial 5 mm thick with parameters 2800/30 for a proton density-weighted image and 2800/80 for a T2-WI were typically obtained. When gadopentetate dimeglumine (Magnevist, Berlex Imaging, Wayne, NJ) became available, our protocol was changed and we acquired sagittal T1-WI with parameters of 600/20 and then obtained axial 5-mm slice thickness proton density-weighted images with parameters of 2800/30 and T2-WI axial 5-mm slice thickness images with parameters of 2800/80. We then gave 0.1 mmol/kg of gadopentetate dimeglumine intravenously and immediately obtained coronal and axial images of 5-mm thickness with a 600/20 sequence. The images were evaluated for the location and multiplicity of lesions. The lesions were divided into two components. We referred to the enhancing area on CT or MR scanning as Zone 1, and the abnormal high signal on T2-WI surrounding the enhancing area as Zone 2. This is similar to a classification system previously used in evaluating astrocytomas (11). This method of describing lesions enables us to avoid the misleading terms "tumor" and "edema" since scans do not show the extent of tumor as would be inferred by when using these terms. The signal intensities of Zone 1 were evaluated as being hypointense, isointense, or hyperintense to normal gray matter prior to gadopentetate dimeglumine administration on T1- and T2-WI. A radial measurement was obtained for each lesion from the center Zone 1 area to the boundary between Zone 1 and Zone 2 and this was the radial measurement for Zone 1. The second radial measurement was from the boundary between Zone 1 and Zone 2 to the boundary between Zone 2 and brain which had normal signal intensity on T2-WI. This was the radial measurement for Zone 2. The total radial measurement for the lesion would be the sum of these two measurements. Mass effect was subjectively graded as none, mild, moderate, or marked by observing displacement of normal structures.

#### Patient Characteristics

In our series (n = 20) the median age was 60 (range 27 to 70 years). Fifteen patients (75%) were men and five (25%) were women. The diagnoses were obtained by biopsy in 17 patients (85%), vitrectomy in two patients (10%) and lumbar puncture in one patient (5%). Most patients (60%) had diffuse large-cell lymphoma, seven (35%) had

the immunoblastic subtype, and one had diffuse small-cell subtype. Their presenting symptoms were varied and included confusion, headaches, seizures, floaters, and other focal neurologic deficits. The clinical data are summarized in Table 1.

## Results

Primary CNS lymphoma presented as solitary enhancing lesions in 12 patients and multiple lesions in eight. Imaging studies showed 33 separate lesions in these 20 patients. Nineteen of the 33 (58%) lesions abutted the ventricular system with three patients showing a diffuse periventricular pattern (Fig. 1). With the exception of five, all lesions in this series were supratentorial. All 33 lesions enhanced with 25 of 33 (76%) showing homogenous enhancement and 26 of 33 (79%) showing marked enhancement. The enhancing portion of the lesions (Zone 1), measured from 0.5 to 3 cm in radial dimension. The areas of enhancement were isointense or hypointense with gray matter on T2-WI in 21 of 33 (64%) masses and hypointense or isointense to gray matter on T1-WI in all cases. In 21 of 33 (64%) lesions, Zone 1 and Zone 2 showed different signal intensities on the T2-WI. The axis of Zone 2 varied from 0 to 5 cm. Most lesions showed little mass effect. Figure 2 shows typical findings of primary CNS lymphoma on noncontrast MR.

TABLE 1: Summary of clinical patient data

Patient	Sex	Age	Presenting Symptoms	Type of Surgery	Histology
1	M	67	Confusion	N	DL
2	F	65	Headaches	C	DL, IBS
3	M	40	Seizures	C	DL, IBS
4	F	58	Headache	C	DL
5	F	64	Transient right hemiparesis	CSF cytology	DL
6	M	60	Seizures	N	DL, IBS
7	M	29	Confusion	C	DL, IBS
8	M	66	Right hemiparesis	N	DL, IBS
9	F	56	Diplopia	N	DL
10	M	50	Left-sided neglect	C	DL
11	M	60	Floaters	V	DL
12	M	68	RUE hemiparesis	C	DL
13	M	60	Seizures	C	DL
14	M	47	Headache	C	DL
15	M	66	Headache	C	DS
16	M	65	Confusion	N	DL
17	M	62	Left facial weakness	N	DL, IBS
18	M	67	Disorientation	C	DL
19	F	70	Dementia	V	DL
20	M	33	Right hemiparesis	N	DL

Note.—N, needle biopsy; C, craniotomy; V, vitrectomy; DL, diffuse large cell lymphoma; IBS, immunoblastic subtype; CSF, cerebrospinal fluid; RUE, right upper extremity; DS, diffuse small cell lymphoma.

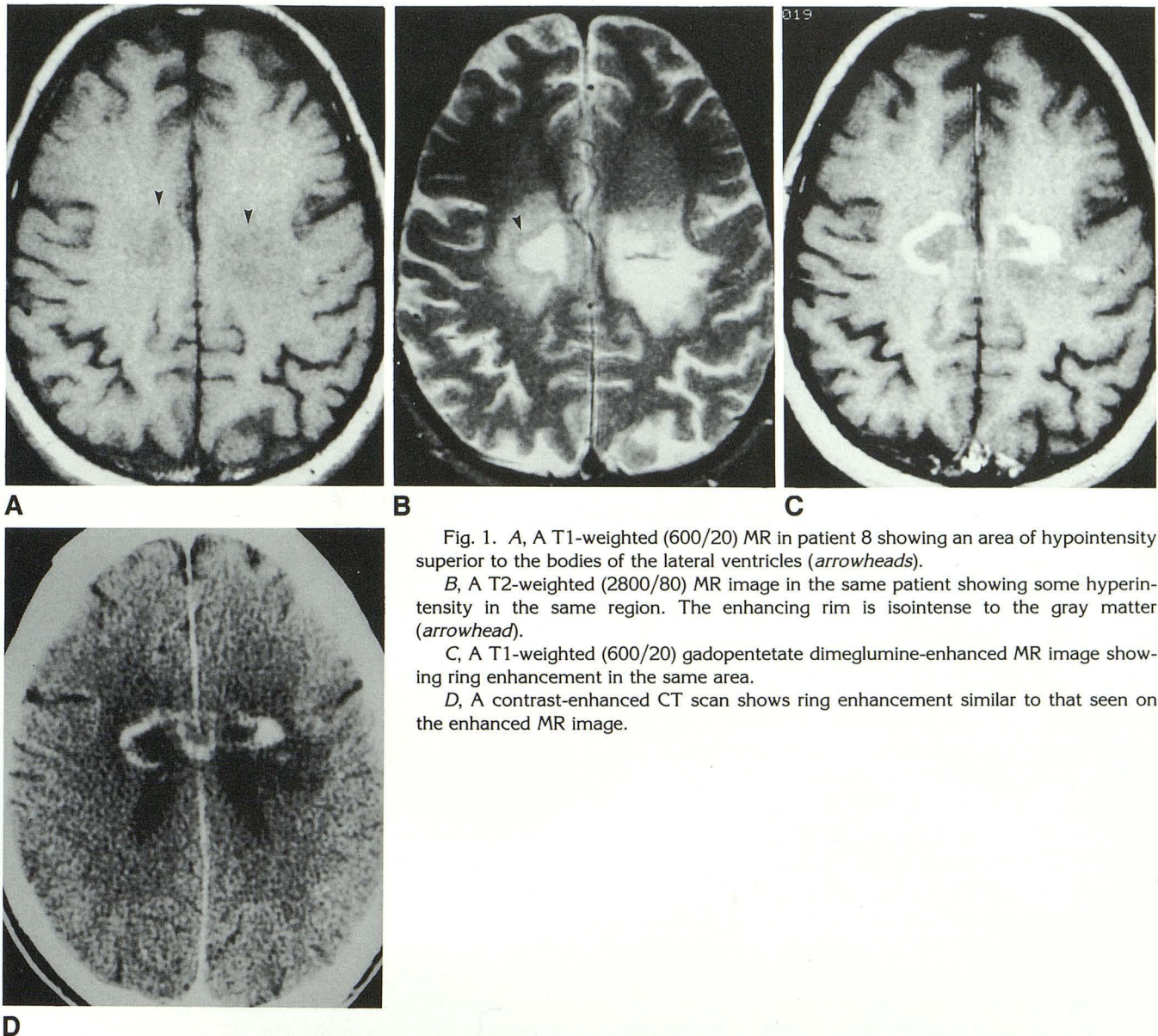


Fig. 1. A, A T1-weighted (600/20) MR in patient 8 showing an area of hypointensity superior to the bodies of the lateral ventricles (*arrowheads*).

B, A T2-weighted (2800/80) MR image in the same patient showing some hyperintensity in the same region. The enhancing rim is isointense to the gray matter (*arrowhead*).

C, A T1-weighted (600/20) gadopentetate dimeglumine-enhanced MR image showing ring enhancement in the same area.

D, A contrast-enhanced CT scan shows ring enhancement similar to that seen on the enhanced MR image.

Thirteen patients received gadopentetate dimeglumine. The degree of enhancement was the same with gadopentetate dimeglumine as with iodine-based contrast media in 12 of 13 (92%) patients and 21 of 24 (88%) lesions. A right frontal lesion was visible on the gadolinium-enhanced MR scan and not noted on the CT or noncontrast MR scans. Figure 3 shows typical findings of primary CNS lymphoma on gadopentetate dimeglumine-enhanced MR scans. The results of the CT and MR scans are summarized in Table 2.

### Discussion

In this series, primary CNS lymphoma showed deep, predominantly supratentorial lesions that

abutted an ependymal surface as shown in prior studies (12, 13). Most lesions showed dense homogenous enhancement on CT and MR, agreeing with prior studies (14–17). The degree and pattern of postcontrast enhancement on CT scanning corresponded to that seen on MR scanning in most instances. In one patient, postenhancement MR showed a lesion not noted on CT scanning or nonenhanced MR images. Forty percent of our patients had multiple lesions. In other series, in primary CNS lymphoma, multiplicity rates varied from 11% to 53% (14–16, 18–20). In our series, in most of the lesions, the enhancing area (Zone 1) had different signal characteristics than the surrounding abnormal signal area (Zone 2). Recently, this finding was reported in a review article

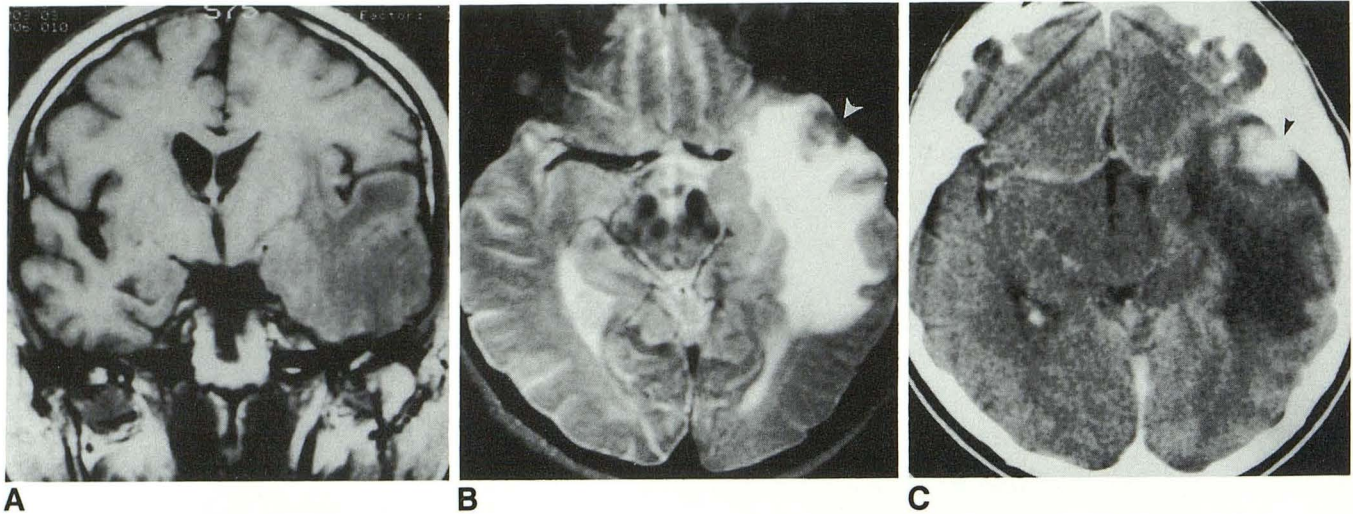


Fig. 2. A, A T1-weighted (600/20) coronal MR image in patient 2 shows a large hypointense area in the left temporal lobe with significant mass effect.  
 B, Axial T2-weighted (2000/80) image in the same patient shows a Zone 1 area isointense to gray matter with surrounding hyperintensity (*white arrowhead*).  
 C, A contrast-enhanced CT in the same patient. A dense homogeneously enhancing left temporal mass with surrounding hypointensity (*black arrowhead*). This area of enhancement corresponded to the isointense area of the T2-weighted MR image.

on primary CNS lymphoma (21), and our series agrees with this observation. We found the size of the Zone 2 area to be variable as has been previously shown (8, 14, 19).

Primary CNS lymphoma is a common CNS manifestation of HIV infection (22–24) and commonly presents as ring-enhancing lesions in immunocompromised patients. Ring enhancement is rare in immunologically competent patients (16). In our study, ring enhancement was an uncommon manifestation of primary CNS lymphoma. One prior study suggested that primary CNS lymphoma associated with AIDS showed multiple lesions, whereas primary CNS lymphoma not associated with AIDS was solitary (25). We show a multiplicity rate of 40% in non-AIDS patients, indicating multiple lesions may be associated with primary CNS lymphoma in immunologically normal and immunocompromised patients.

From a diagnostic viewpoint, the problem is that the MR findings of primary CNS lymphoma overlap with those of other intracranial mass lesions. Metastases, like primary CNS lymphoma, appear as solitary or multiple enhancing lesions (26–29). High-grade astrocytomas exhibit marked “ring” contrast enhancement, a large peripheral infiltration margin, and a large amount of mass effect (30–32). Imaging findings in secondary CNS lymphoma can be identical to those in primary CNS lymphoma (7, 20, 21). Abscesses usually present as ring-enhancing lesions, which

is an uncommon finding in non-AIDS primary CNS lymphoma (33, 34), but is common in AIDS patients as noted above. Meningiomas are extraaxial-enhancing lesions that could rarely be mistaken for primary CNS lymphoma (35). Since the imaging findings of primary CNS lymphoma may overlap with metastatic lesions, high-grade astrocytomas, secondary CNS lymphoma, abscesses, and meningiomas, we can only make a suggestive diagnosis of primary CNS lymphoma, and pathologic confirmation is needed. A recent study of AIDS-related primary CNS lymphoma also showed that it was not possible to make a definitive diagnosis based on imaging studies (36).

In our CNS lymphoma patients, we avoided the term “tumor” to describe the enhancing area, Zone 1, and the term “edema” to describe the surrounding abnormal signal in Zone 2. These terms are misleading since they imply that all tumors enhance and the surrounding area is increased free water without tumor cells. In patients with high grade astrocytomas studied with image-guided stereotactic biopsies, tumor extends beyond the enhancing margin and even extends outside the area of abnormal signal intensity on T2-weighted MR imaging (11, 37). Studies comparing imaging data to postmortem brain examination have found that imaging studies do not accurately delineate the extent of tumor (38, 39). One study compared the recent antemortem CT scans of primary CNS lymphoma with findings on postmortem examination, and in five of eight

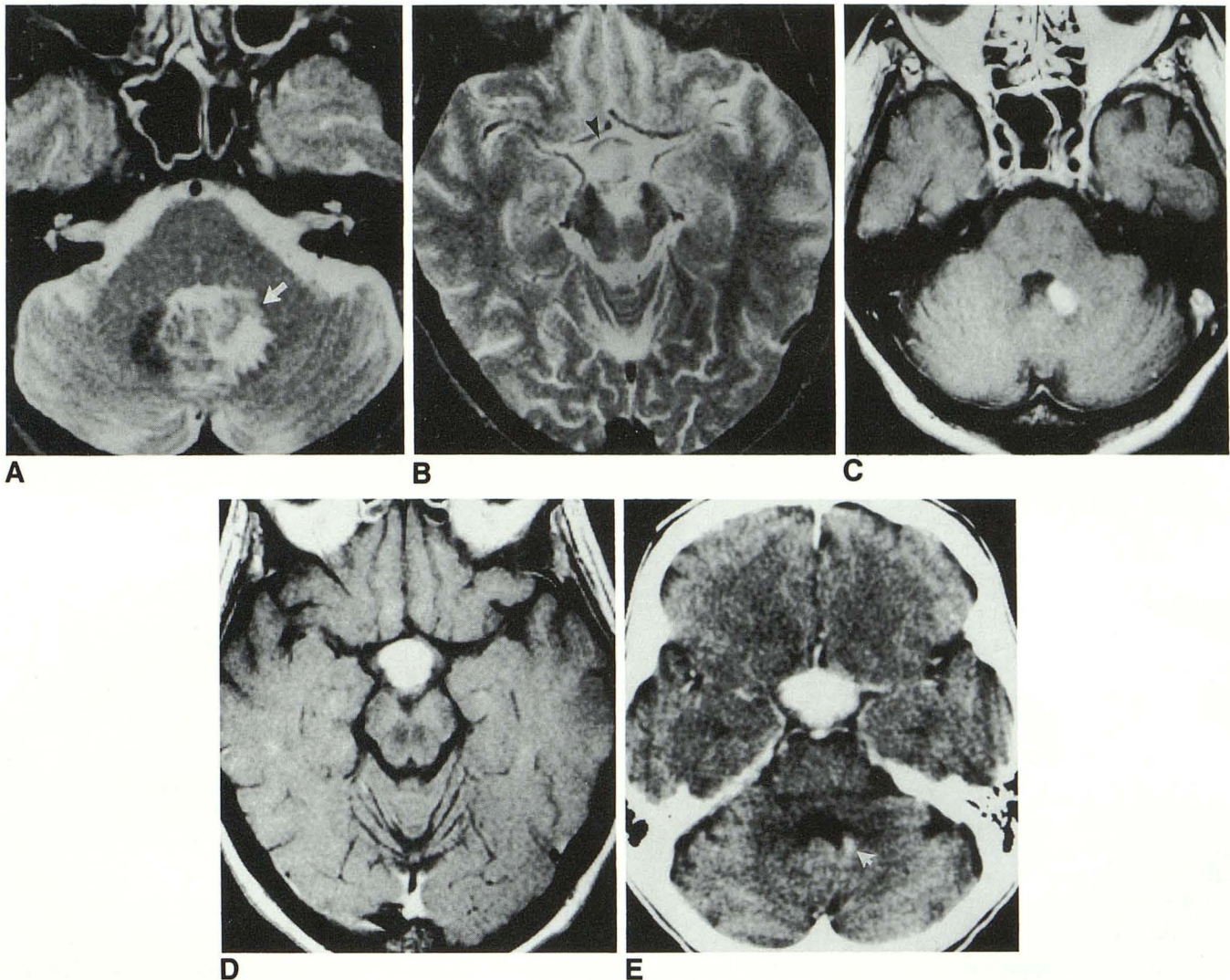


Fig. 3. A, A T2-weighted (2757/80) MR image in patient 9 shows a lesion in the left cerebellar hemisphere with a Zone 1 area isointense to gray matter (*white arrow*) and a Zone 2 area abutting the fourth ventricle.

B, A T2-weighted (2757/80) MR image shows a hyperintense lesion in the hypothalamus (*black arrowhead*).

C, A T1-weighted (800/25) gadopentetate dimeglumine-enhancing MR image shows the Zone 1 area of the left cerebellar lesion with dense homogenous enhancement.

D, A T1-weighted (800/25) gadopentetate dimeglumine-enhanced MR image shows dense homogenous enhancement of the hypothalamic lesion.

E, A contrast-enhanced CT scan shows the left cerebellar lesion to enhance but it appears smaller than on the MR image (*white arrow*). The hypothalamic lesion enhances similarly to the MR image.

patients the tumor extended further than noted on radiologic examination (20). Primary CNS lymphoma is described pathologically as diffuse infiltration of brain parenchyma (40, 41), and the extent of neoplastic infiltration of the brain cannot be defined by imaging studies. We believe that Zone 1 corresponds to an area of packed tumor cells, while Zone 2 corresponds to increased water content and infiltrating tumor cells. We believe that these MR findings can be used to guide the therapy of patients. Needle biopsy is the procedure of choice for obtaining a tissue diagnosis (9,

42). In a patient whose MR scan shows findings suggestive of primary CNS lymphoma, a needle biopsy is a rational next step in the work-up of primary CNS lymphoma. In this way, a diagnosis can be obtained. In primary CNS lymphoma, the extent of resection has no influence on survival (5, 43). Radiation therapy, with or without subsequent chemotherapy, has been the mainstay of treatment for primary CNS lymphoma but has yielded median survival rates of only about 15–20 months (44). Systemic chemotherapy for systemic lymphoma yields a 60% 5-year survival

TABLE 2: Results of radiologic examination of non-AIDS primary CNS lymphoma patients

Patient	No. of Lesions	Enhancement		Signal Intensity of Zone 1		Zone 1 Radial Measurement <sup>a</sup>	Zone 2 Radial Measurement <sup>a</sup>	Mass Effect	Abuts Vent. System	Location	
		Type	I	Gd	T1						T2
1	1	H	3+	ND	Hypo	Iso	1	5	1+	+	DPV
2	1	H	3+	ND	Hypo	Iso	1.5	4	3+	+	Left temporal
3	1	H	3+	ND	Hypo	Iso	2	5	0	+	Left parietal
4	2	R	3+	ND	Hypo	Iso	3	3	2+	+	Left parietal
		H	3+	ND	Hypo	Iso	1	2	2+	+	Left temporal
5	1	H	2+	ND	Iso	Hyper	1	5	0	+	Left parietal
6	1	H	3+	ND	Hypo	Hyper	1	2	0	+	DPV
7	2	H	2+	ND	Iso	Hypo	0.5	1	0	+	Left frontal
		H	1+		Iso	Hypo	0.5	1	0	-	Left frontal
8	1	R	3+	3+	Hypo	Iso	3	3	1+	+	Corpus callosum and periventricular white matter
9	2	H	3+	3+	Iso	Hyper	1	3	1+	+	Hypothalamus
		H	3+	3+	Iso	Iso	0.5	1	1+	+	Left cerebellar hemisphere
10	1	R	3+	3+	Iso	Hyper	2.5	2	0	+	Right parietal
11	3	H	3+	3+	Iso	Iso	1	5	1+	+	Left frontal
		H	3+	3+	Iso	Iso	1	3	1+	-	Left temporal
		H	3+	3+	Iso	Iso	1	3	1+	-	Right frontal
12	1	H	3+	3+	Hypo	Hyper	2	5	2+	-	Right parietal
13	1	H	3+	3+	Hypo	Hyper	1.5	2	2+	+	Left temporal
14	1	H	3+	3+	Hypo	Iso	1.5	3	2+	-	Left frontal
15	1	H	3+	3+	Hypo	Iso	2.5	2	2+	+	Left frontal parietal
16	1	R	3+	3+	Hypo	Iso	1.5	2	1+	+	Left basal ganglia
17	2	H	3+	3+	Hypo	Iso	1	1	1+	+	Pons
		R	3+	3+	Iso	Iso	0.5	9	0	+	Thalamus surrounding 3rd ventricle
18	2	H	3+	3+	Hypo	Iso	2	5	3+	+	Right occipital-large dural base
		H	1+	1+	Hypo	Hyper	0.5	2	0	-	Left parietal
19	5	H	2+	3+	Iso	Hyper	1	0	1+	+	Right cerebellar hemisphere
		H	1+	2+	Iso	Hyper	1	2	1+	-	Right midbrain
		H	1+	1+	Iso	Iso	*	0	0	+	Right lentiform
		H	1+	1+	Iso	Iso	*	0	0	+	Left lentiform
20	3	H	0	3+	Iso	Iso	0.5	0	0	-	Right frontal
		H	3+	3+	Iso	Hyper	0.5	0	2+	-	Right midbrain
		H	3+	3+	Iso	Hyper	0.5	4	0	-	Right lentiform
		H	3+	3+	Iso	Hyper	0.5	4	0	-	Left lentiform

Note.—I, iodine-based enhancement; Gd, gadolinium-based enhancement; ND, not done. The degree of enhancement was graded subjectively as: 0, none; 1+, mild; 2+, moderate; 3+, marked. The type of enhancement was described as H, homogenous or R, ring; +, the lesion abutted the ventricular system; -, the lesion did not abut the ventricular system. Mass effect was graded as: 0, none; 1+, mild; 2+, moderate; 3+, marked. T1, T1-weighted image; T2, T2-weighted image. DPV, diffuse periventricular. Zone 1: refers to the area of enhancement. Zone 2: refers to the abnormal signal surrounding the enhancing area.

<sup>a</sup> The radial measurements in Zones 1 and 2 are in centimeters. The radial measurement of Zone 1 was obtained from the geometric center of Zone 1 to the boundary of Zones 1 and 2. The radial measurement of Zone 2 was obtained from the boundary of Zones 1 and 2 to the boundary of Zone 2 and brain with normal signal intensity on T2-weighted images.

rate (45, 46). Chemotherapy, used alone, has had only modest efficacy in treating primary CNS lymphoma, but may be more effective if given prior to radiotherapy (47-49). However, chemotherapy given in association with osmotic blood-brain barrier disruption parallels the excellent, durable responses seen with systemic disease and may not require radiotherapy (50).

## References

- Jellinger K, Radzskiewicz TH, Slowik F. Primary malignant lymphomas of the central nervous system in man. *Acta Neuropathol (Berl)* 1975;6:95-102
- Levy RM, Bredesen DE, Rosenblum ML. Neurological manifestations of the acquired immunodeficiency syndrome (AIDS): experience at UCSF and review of the literature. *J Neurosurg* 1985;62:475-495
- Eby NL, Grufferman S, Flannelly CM, Schold SC, Vogel FS, Burger PC. Increasing incidence of primary lymphoma in the US. *Cancer* 1988;62:2461-2465
- Allegranza A, Mariani C, Giardini R, Brambilla MC, Boeri R. Primary malignant lymphomas of the central nervous system: a histological and immunohistological study of 12 cases. *Histopathology* 1984;8: 781-791
- Mendenhall NP, Thar TL, Agee OF, Harty-Golder B, Ballinger WE, Million RR. Primary lymphoma of the central nervous system: computerized tomography scan characteristics and treatment results for 12 cases. *Cancer* 1983;52:1993-2000
- Lukin R, Tomsick TA, Chambers AA. Lymphoma and leukemia of the central nervous system. *Semin Roentgenol* 1980;15:246-250

7. Whelan MA, Kricheff II. Intracranial lymphoma. *Semin Roentgenol* 1984;19:91-99
8. Schwaighofer BW, Hesselink JR, Press GA, Wolf RL, Healy ME, Berthoty DP. Primary intracranial CNS lymphoma: MR manifestations. *AJNR* 1989;10:725-729
9. Neuwelt EA, Frenkel EP, Gumerlock MK, Brazier R, Dana B, Hill SA. Developments in the diagnosis and treatment of primary CNS lymphoma: a prospective series. *Cancer* 1986;58:1609-1620
10. The Non-Hodgkin's Lymphoma Pathologic Classification Project. National cancer institute sponsored study of classifications of non-Hodgkin's lymphomas: summary and description of a working formulation for clinical usage. *Cancer* 1982;49:2112-2135
11. Kelly PJ, Daumas-Duport C, Kispert DB, Kall BA, Scheithauer BW, Illig JJ. Imaging-based stereotaxic serial biopsies in untreated intracranial glial neoplasms. *J Neurosurg* 1987;66:865-874
12. Enzmann DR, Krikorian J, Norman D, Kramer R, Pollock J, Faer M. Computed tomography in primary reticulum cell sarcoma of the brain. *Radiology* 1979;130:165-170
13. Spillane JA, Kendall BE, Moseley IF. Cerebral lymphoma: clinical radiological correlation. *J Neurol Neurosurg Psychiatry* 1982;45:199-208
14. Cellier P, Chiras J, Gray F, Metzger J, Bories J. Computed tomography in primary lymphoma of the brain. *Neuroradiology* 1984;26:485-492
15. Jack CR, Resse DF, Scheithauer BW. Radiographic findings in 32 cases of primary CNS lymphoma. *AJNR* 1985;6:899-904
16. Lee Y-Y, Bruner JM, Van Tassel P, Libshitz HI. Primary central nervous system lymphoma: CT and pathologic correlation. *AJNR* 1986;7:599-604
17. Palacios E, Gorelick PB, Gonzalez CF, Fine M. Malignant lymphoma of the nervous system. *J Comput Assist Tomogr* 1982;6:689-701
18. Jack CR, O'Neill BP, Banks PM, Reese DF. Central nervous system lymphoma: histologic types and CT appearance. *Radiology* 1988;167:211-215
19. Leaney BJ, Martin JJ, Lawson JB, Quong GC, Liew KH. Primary brain lymphoma. *Australas Radiol* 1988;32:38-43
20. Thomas M, MacPherson P. Computed tomography of intracranial lymphoma. *Clin Radiol* 1982;33:331-336
21. Zimmerman RA. Central nervous system lymphoma. *Radiol Clin North Am* 1990;28:697-720
22. Ramsey RG, Geremia GK. CNS complications of AIDS: CT and MR findings. *AJR* 1988;15:449-454
23. Sze G, Brant-Zawadzki MN, Norman D, Newton TH. The neuroradiology of AIDS. *Semin Roentgenol* 1987;22:42-53
24. Ciricillo SF, Rosenblum ML. Use of CT and MR imaging to distinguish intracranial lesions and to define the need for biopsy in AIDS patients. *J Neurosurg* 1990;73:720-724
25. Poon T, Matoso I, Tchertkoff V, Weitzner Jr. I, Grade M. CT features of primary cerebral lymphoma in AIDS and non-AIDS patients. *J Comput Assist Tomogr* 1989;13:6-9
26. Davis PC, Hudgins PA, Peterman SB, Hoffman JC. Diagnosis of cerebral metastases: double-dose delayed CT vs. contrast-enhanced MR imaging. *AJNR* 1991;12:293-300
27. Healy ME, Hesselink JR, Press GA, Middleton MS. Increased detection of intracranial metastases with intravenous Gd-DTPA. *Radiology* 1987;165:619-624
28. Russell EJ, Geremia GK, Johnson CE, et al. Multiple cerebral metastases: detectability with Gd-DTPA-enhanced MR imaging. *Radiology* 1987;165:609-617
29. Sze G, Shin J, Krol G, Johnson C, Liu D, Deck MDF. Intraparenchymal brain metastases: MR imaging versus contrast-enhanced CT. *Radiology* 1988;168:187-194
30. Brant-Zawadzki, Berry I, Osaki L, Brasch R, Murovic J, Norman D. Gd-DTPA in clinical MR of the brain. I. intraaxial lesions. *AJNR* 1986;147:1223-1230
31. Claussen C, Laniado M, Kazner E, Schörner W, Felix R. Application of contrast agents in CT and MRI (NMR): their potential in imaging of brain tumors. *Neuroradiology* 1985;27:164-171
32. Felix R, Schörner W, Laniado M, et al. Brain tumors: MR imaging with gadolinium-DTPA. *Radiology* 1985;156:681-688
33. Davidson HD, Steiner RE. Magnetic resonance imaging in infections of the central nervous system. *AJNR* 1985;6:499-504
34. Enzmann DR, Britt RH, Placone R. Staging of human brain abscess by computed tomography. *Radiology* 1983;146:703-708
35. Spagnoli MV, Goldberg HI, Grossman RI, et al. Intracranial meningiomas: high-field MR imaging. *Radiology* 1986;161:369-375
36. Goldstein JD, Zeifer B, Chao C, et al. CT appearance of primary CNS lymphoma in patients with acquired immunodeficiency syndrome. *J Comput Assist Tomogr* 1991;15:39-44
37. Greene GM, Hitchon PW, Schelper RL, Yuh W, Dyste GN. Diagnostic yield in CT-guided stereotactic biopsy of gliomas. *J Neurosurg* 1989;71:494-497
38. Burger PC, Heinz ER, Shibata T, Kleihues P. Topographic anatomy and CT correlations in the untreated glioblastoma multiforme. *J Neurosurg* 1988;68:698-704
39. Johnson PC, Hunt SJ, Drayer BP. Human cerebral gliomas: correlation of postmortem MR imaging and neuropathologic findings. *Radiology* 1989;170:211-217
40. Grant JW, Gallagher PJ, Jones DB. Primary cerebral lymphoma: a histologic and immunohistochemical study of six cases. *Arch Pathol Lab Med* 1986;110:897-901
41. Houthoff HJ, Poppema S, Ebels EJ, Elema JD. Intracranial malignant lymphomas: a morphologic and immunocytologic study of 20 cases. *Acta Neuropathol (Berl)* 1978;44:203-210
42. DeAngelis LM, Yahalom J, Heinemann M-H, Cirrincione C, Thaler HT, Krol G. Primary CNS lymphoma: combined treatment with chemotherapy and radiotherapy. *Neurology* 1990;40:80-86
43. Michalski JM, Garcia DM, Kase E, Grigsby PW, Simpson JR. Primary central nervous system lymphoma: analysis of prognostic variables and patterns of treatment failure. *Radiology* 1990;176:855-860
44. Hochberg FH, Miller DC. Primary central nervous system lymphoma. *J Neurosurg* 1988;68:835-853
45. Connors JM. The clinician's decision of whether CHOP chemotherapy should be standard therapy for treatment of patients with diffuse histiocytic lymphoma 12b. In: DeVita VT Jr, Hellman S, Rosenberg S, eds. *Important advances in oncology 1990*. Philadelphia: Lippincott, 1990:227-233
46. Fisher IF. CHOP chemotherapy as standard therapy for treatment of patients with diffuse histiocytic lymphoma 12a. In: DeVita VT Jr, Hellman S, Rosenberg S, eds. *Important advances in oncology 1990*. Philadelphia: Lippincott, 1990:217-225
47. Chamberlain MC, Levin VA. Adjuvant chemotherapy for primary lymphoma of the central nervous system. *Arch Neurol* 1990;47:1113-1116
48. Gabbai AA, Hochberg FH, Linggood RM, Bashir R, Hotleman K. High-dose methotrexate for non-AIDS primary central nervous system lymphoma. *J Neurosurg* 1989;70:190-194
49. DeAngelis LM. Primary central nervous system lymphoma: a new clinical challenge. *Neurology* 1991;41:619-621
50. Neuwelt EA, Goldman D, Dahlborg SA, et al. Primary central nervous system lymphoma treated with osmotic blood-brain barrier disruption and combination chemotherapy: prolonged survival and preservation of cognitive function. *J Clin Oncol* 1991;9:1580-1590