

High Signal from the Otic Labyrinth on Unenhanced Magnetic Resonance Imaging

Jane L. Weissman,¹ Hugh D. Curtin,^{1,3} Barry E. Hirsch,² and William L. Hirsch, Jr.¹

Summary: High signal from the otic labyrinth was observed on precontrast MR scan of two patients who presented with sudden hearing loss and vertigo. The authors suggest the possibility that the high signal was caused by hemorrhage but that clinical significance and therapeutic implications of this finding need further study.

Index terms: Temporal bone, magnetic resonance

The cochlea, vestibule, and semicircular canals comprise the otic labyrinth. The labyrinth lumen normally has relatively low signal on T1-weighted magnetic resonance (MR) images, intermediate between cerebrospinal fluid (CSF) and brain. On T2-weighted images, the signal from the labyrinth lumen is bright. The lumen is seen well against the signal void of the osseous otic capsule and pneumatized middle ear and mastoid.

Previous authors (1, 2) have described high labyrinthine signal, presumed to be enhancement, on contrast-enhanced T1-weighted MR. This paper describes high signal from the labyrinth on precontrast T1-weighted MR studies of two patients who presented with sudden hearing loss and vertigo, raising the possibility that in some cases the high signal does not represent enhancement but some pathology with intrinsic high signal intensity. One possible explanation of intrinsic high signal is a small amount of hemorrhage into the labyrinth. Precontrast T1-weighted images are necessary to differentiate the high signal of hemorrhage from contrast enhancement of the labyrinth.

Case Reports

Case 1

A 57-year-old man presented with right-sided hearing loss and vertigo of several days duration. He denied experiencing symptoms of an upper respiratory infection. He

had reduced right vestibular response and right-beating nystagmus. An audiogram demonstrated sensorineural hearing loss on the right.

An MR study (GE Max 0.5 T, Milwaukee, WI) was performed. Axial T1-weighted (TR/TE/NEX 480/25/4) overlapping images 3-mm thick were obtained by using 2-mm interslice increments before and after injection of intravenous gadolinium-DTPA (Magnevist, Berlex). Axial proton density and T2-weighted slices (TR/TE/NEX 2571/80/1) 5-mm thick were obtained with 1-mm slice separation. Unenhanced T1-weighted images demonstrated abnormally high signal (hyperintense with respect to the contralateral labyrinth and isointense to the adjacent cerebellum) from the right cochlea and vestibule (Fig. 1A). Region-of-interest signal intensity measurements revealed that the right cochlea measured 54.6, with a standard deviation (SD) of 1.6; the left cochlea measured 22.1 (SD 1.0). The right vestibule measured 54.8 (SD 0.4); the left was 22.3 (SD 1.6). The brain parenchyma measured 56.6 (SD 0.7). On proton density images, the right labyrinth signal was slightly greater than the left, while on T2-weighted images no difference was apparent. There was no change in labyrinth signal after intravenous contrast injection (Fig. 1B). No acoustic neuroma was present.

The patient was treated with steroids and carbogen inhalations. The steroids were given to reduce the inflammation of a possible viral labyrinthitis. Carbogen inhalations produce hypercarbia, which causes intracranial vasodilation and may help to relieve vasospasm.

A follow-up study obtained 6 weeks later utilizing the same imaging parameters demonstrated persistent but less marked hyperintensity on unenhanced T1-weighted images (Fig. 1C). The measurements at this time were: right cochlea, 38.7 (SD 1.2); left cochlea 25.0 (SD 1.5); right vestibule, 30.6 (SD 0.8); left vestibule 21.4 (SD 0.5). Brain measured 56.3 (SD 1.0). At this time, his hearing was still reduced, but his vertigo had resolved.

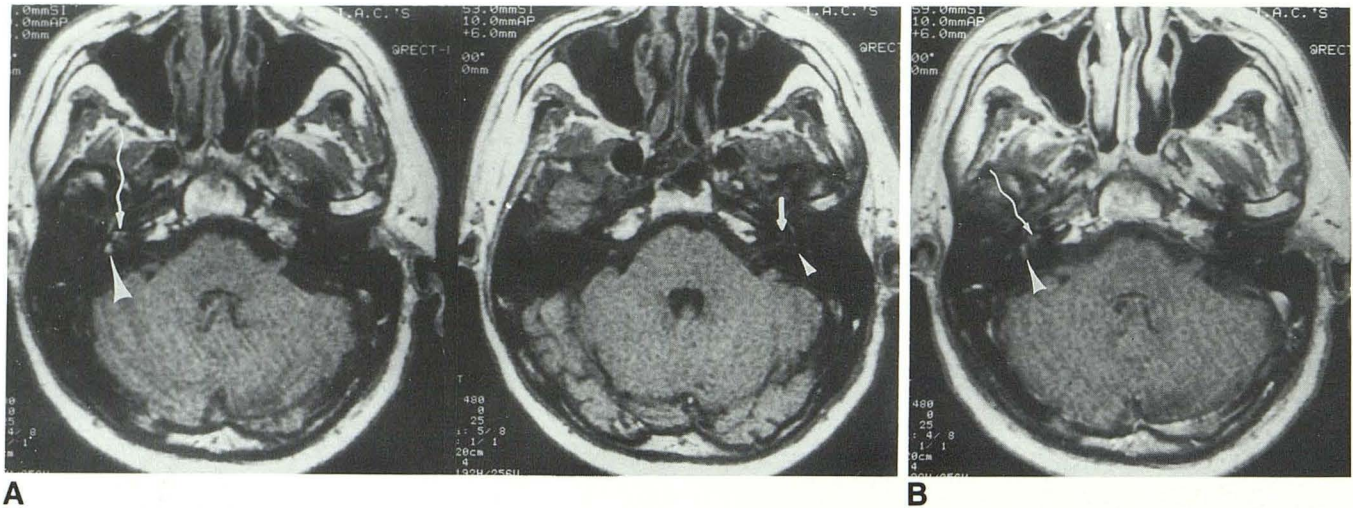
Case 2

A 34-year-old man experienced 4–5 days of left-sided hearing loss. An audiogram performed at this time documented sensorineural hearing loss. Vestibular testing was

Received July 3, 1991; revisions requested September 25; revision received and accepted November 18.

¹ Department of Radiology and ² Department of Otolaryngology, University of Pittsburgh School of Medicine, Pittsburgh, PA

³ Address reprint requests to Hugh D. Curtin, MD, Eye and Ear Hospital, 230 Lothrop Street, PUH 1420, Pittsburgh, PA 15213.

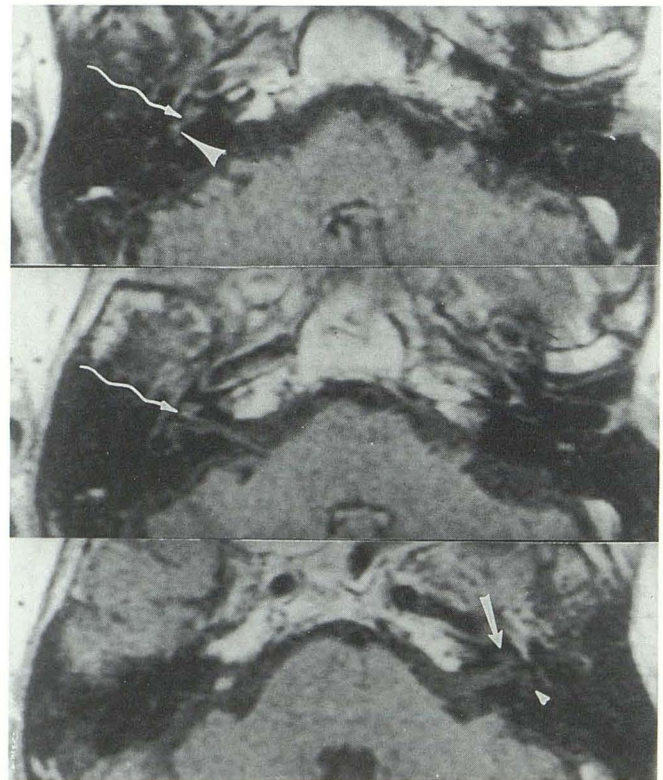


A Fig. 1. Case 1.

A, Precontrast T1-weighted images show high signal from the right cochlea (*wavy arrow*) and vestibule (*large arrowhead*). The signal is hyperintense with respect to brain and to the left cochlea (*small arrow*) and vestibule (*small arrowhead*), which have normal signal, nearly isointense with CSF.

B, Contrast-enhanced T1-weighted image demonstrates high signal from the right cochlea (*wavy arrow*) and vestibule (*arrowhead*). The appearance of the labyrinth is not significantly different from that of A.

C, T1-weighted images 6 weeks later demonstrate persistent but less marked high signal from the right cochlea (*wavy arrows*) and vestibule (*large arrowhead*). The left cochlea (*small arrow*) and vestibule (*small arrowhead*) are hypointense to brain, which is normal.



C were: left vestibule, 67.8 (SD 1.8); right vestibule 50.0 (SD 0.9). After gadolinium administration, there was no change in the appearance of the vestibule (Fig. 2B). No acoustic neuroma was present. The T2-weighted sequences (TR/TE/NEX 2928/80/1) were normal (data not shown).

not performed. His hearing gradually improved. One year later, as part of an anxiety disorder study, he underwent vestibular function tests and an audiogram. He had no complaints of hearing loss, and no vestibular symptoms at that time. His audiogram was normal. However, his vestibular function on the left was abnormal, with reduced vestibular response and absent ice water responses. An MR (GE Max 0.5 T) was obtained, with overlapping T1-weighted images as in case 1. T1-weighted images (TR/TE/NEX 480/25/4) obtained before contrast injection (Fig. 2A) revealed faint but definite increased signal of the left vestibule, both in comparison to the right vestibule and to brain. Region-of-interest signal intensity measurements

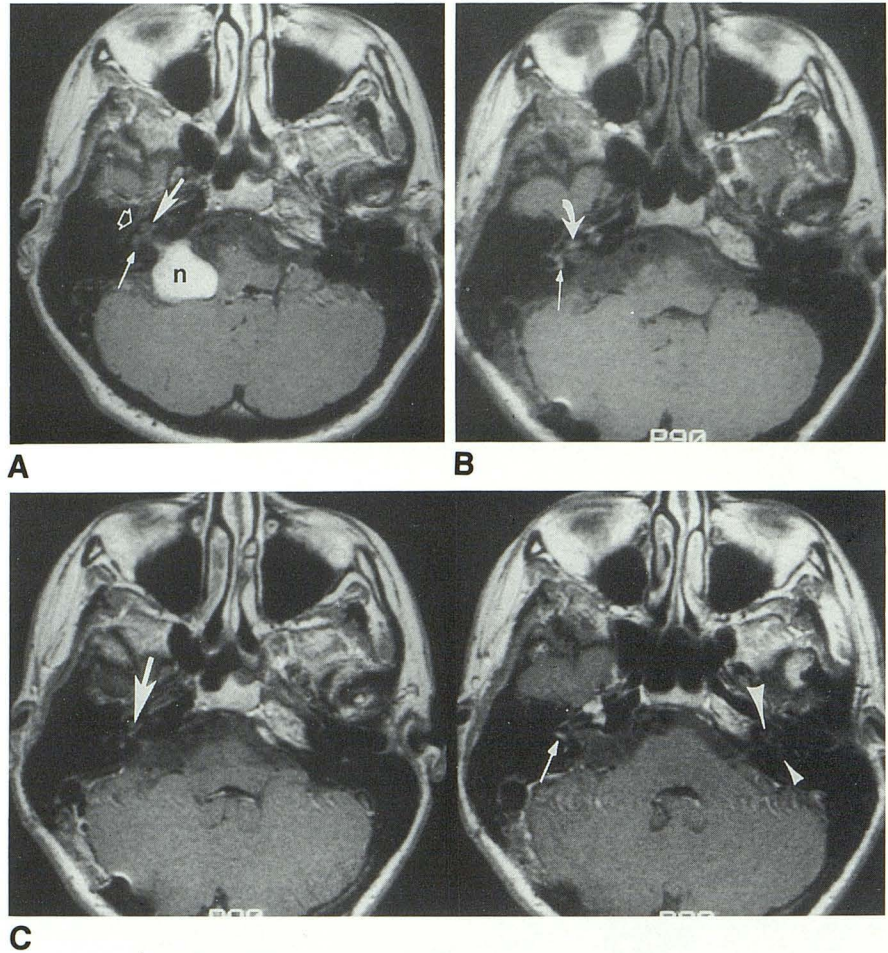
Discussion

The cochlea, the vestibule, and the three semicircular canals comprise the otic labyrinth. The lumen of the labyrinth contains predominantly perilymph and endolymph. Normal endolymph

Fig. 3. A, Contrast-enhanced T1-weighted image before surgery demonstrates a large, enhancing acoustic neuroma (*n*) in the right cerebellopontine angle, extending into the internal auditory canal. The cochlea (*large arrow*) and vestibule (*short solid arrow*) are hypointense to brain, and so considered normal. *Open arrow*, facial nerve.

B, Precontrast T1-weighted image after surgery reveals hyperintense signal from the cochlea (*thick arrow*) and the vestibule (*thin arrow*).

C, Contrast-enhanced images after surgery are not significantly different from the unenhanced image (B). The right cochlea (*thick arrow*) and vestibule (*thin arrow*) remain hyperintense to brain. The left cochlea (*large arrowhead*) and vestibule (*small arrowhead*) are hypointense to brain.



Fat is not found in the labyrinth. There are no large vessels associated with the labyrinth and the endolymph does not circulate significantly in a patient lying immobile in the scanner. Therefore, flow is an unlikely cause of high signal from the labyrinth.

Elevated concentrations of protein macromolecules shorten the T1-relaxation time and yield a high signal most apparent on T1-weighted and proton density images. High protein has been described in the perilymph of patients with acoustic neuromas (5). However, high labyrinthine signal on MR before contrast has not been described in patients with acoustic neuromas.

High protein (serofibrinous precipitates) has also been described in the inner ear of patients with otitis media (6), but we are unaware of any reports of high protein accompanying viral labyrinthitis, which is another cause of sudden sensorineural hearing loss and vertigo (7).

The patients described here had no clinical findings suggestive of a recent viral infection. Although elevated protein cannot be unequivocally

excluded as the cause of high signal, in this setting protein seems an unlikely explanation.

A small amount of hemorrhage within the labyrinth could have been responsible for the signal hyperintensity observed in these patients on the T1-weighted images. Hyperintensity on proton density images, also expected in hemorrhage, may have been less obvious because the slices were thicker than on the T1-weighted sequences. Thicker slices could result in averaging of the signal void of bone with the high signal of the labyrinth to yield a signal of intermediate intensity. The decrease in signal intensity on the follow-up scan may have resulted from turnover of fluid in the labyrinth, gradually diluting or clearing the blood.

Vascular abnormalities such as thrombus, embolus, or vasospasm have been implicated as potential causes of sudden hearing loss. Experimental venous occlusion in animals has been shown to cause hemorrhage into perilymphatic and endolymphatic spaces (8). Idiopathic hemorrhage has not been documented in patients

with sudden hearing loss or vertigo. However, there is very little pathologic correlation of labyrinth abnormalities in sudden hearing loss because surgery is not performed on these patients.

To demonstrate that asymmetric high signal is not an incidental finding, we reviewed 50 consecutive MR examinations of the temporal bones and brain. The patients, all of whom presented with sensorineural hearing loss, vestibulopathy, or tinnitus, were referred for MR to exclude acoustic neuroma. Axial T1-weighted overlapping images 3-mm thick were obtained 2 mm apart, as in the protocols described for the case reports. The signal from the cochlea and vestibule was visually compared to signal from the contralateral cochlea and vestibule and to the adjacent cerebellar hemisphere on precontrast images. The signal from the cochlea and vestibule on both sides was the same, and in all cases was less intense than that of brain. One patient had an acoustic neuroma on the left, but normal signal from cochlea and vestibule. Thus, it seems highly unlikely that the hyperintense signal seen on MR of the two case reports was an incidental finding.

Two other patients with high signal in the labyrinth on precontrast T1-weighted images have been observed recently (Fig. 3). Both patients had undergone retromastoid resection of an acoustic neuroma. Both had normal signal from the labyrinth on preoperative scans (GE Signa 1.5 T) (Fig. 3A). Fat was not used to pack the surgical bed. Follow-up scans obtained 5 months after surgery demonstrated high signal (hyperintense with respect to brain) in the ipsilateral labyrinth on the precontrast (Fig. 3B) and postcontrast (Fig. 3C) T1-weighted images. In this setting, although no pathologic proof is available, it is likely that these observations are attributable to a small amount of blood within the labyrinth, which presumably entered at the time of surgery. The presence of high signal from the labyrinth in these two postoperative patients helps substantiate the hypothesis that blood in the labyrinth could have this appearance.

In conclusion, high signal from the lumen of the labyrinth on precontrast T1-weighted sequences reflects abnormal composition of inner

ear fluids. Prior hemorrhage would seem to be the most likely cause of this high signal in the patients discussed here. However, in no case is there histologic proof. Other causes of high signal on precontrast T1-weighted images, such as high protein content, fat, and slow flow, seem less likely in the clinical settings described.

Prior hemorrhage cannot be differentiated from enhancement if only a postcontrast sequence is obtained. Precontrast T1-weighted images distinguish between enhancement (normal signal before contrast) and prior hemorrhage (high signal before, as well as after, contrast). The observations reported here do not suggest that enhancement does not also occur, rather that precontrast high signal also exists. The clinical significance and therapeutic implications of high signal from the lumen of the inner ear on precontrast T1-weighted images remain to be fully elucidated.

Acknowledgment

The authors are grateful to the staff of the MR Max for their good-natured patience and assistance during the preparation of this article.

References

1. Seltzer S, Mark AS, Chapman JC, Nelson-Drake J. *Labyrinthine enhancement of Gd-MR imaging in patients with sudden hearing loss and vertigo*. Paper presented at the 75th Annual Meeting of the Radiological Society of North America, Chicago, IL, 1989, and at the 23rd Annual Conference of the American Society of Head and Neck Radiology, New Orleans, LA, 1990
2. Seltzer S, Mark AS. Contrast enhancement of the labyrinth on MR scans in patients with sudden hearing loss and vertigo: evidence of labyrinthine disease. *AJNR* 1991;12:13-16
3. Juhn SK, Rybak LP, Jung TTK. Biochemistry of the labyrinth. In: Paparella MM, Shumrick DA, Gluckman JL, Meyerhoff WL, eds. *Otolaryngology*. Vol 1. Philadelphia: Saunders, 1991:537-565
4. Brogan M, Chakeres DW. Gadolinium-DTPA-enhanced MR imaging of a cochlear schwannoma. *AJNR* 1990;11:407-408
5. Silverstein H, Schuknecht HF. Biochemical studies of inner ear fluid in man. *Arch Otolaryngol* 1966;84:59-66
6. Paparella MM, Oda M, Hiraide F, Brady D. Pathology of sensorineural hearing loss in otitis media. *Ann Otol* 1972;81:632-647
7. Snow JB, Telian SA. Sudden deafness. In: Paparella MM, Shumrick DA, Gluckman JL, Meyerhoff WL, eds. *Otolaryngology*. Vol 2. Philadelphia: Saunders, 1991:1757-1766
8. Perlman H, Kimura R. Experimental obstruction of venous drainage and arterial supply of the inner ear. *Ann Otol Rhinol Laryngol* 1957; 66:537-546