

Labyrinthine Ossification Secondary to Childhood Bacterial Meningitis: Implications for Cochlear Implant Surgery

Terry S. Becker¹
Laurie S. Eisenberg²
William M. Luxford³
William F. House³

Of 20 children who underwent cochlear implantation for profound sensorineural hearing loss secondary to bacterial meningitis, 14 had round-window and cochlear ossification at surgery. Preoperative polytomography demonstrated ossification in 11 of these. The incidence of ossification was highest after meningitis secondary to pneumococcal pneumonia. In only one of four children with severe ossification of the labyrinth was implant surgery unsuccessful. Preliminary results indicate that mild labyrinthine ossification is not a contraindication to cochlear implantation.

The value of pluridirectional tomography in the diagnosis of ossification of the membranous labyrinth of the inner ear (labyrinthitis ossificans) has been established [1]. Diagnosis of this condition has been especially important since the advent of cochlear implant surgery, yet no large-scale study has been made of the reliability of polytome diagnosis nor of its clinical impact. We report a series of 20 patients in whom polytomography was helpful in the evaluation of labyrinthitis ossificans.

Materials and Methods

We reviewed the clinical records, surgical findings, plain films, and polytomes of 20 children (12 boys and eight girls) who underwent cochlear implantation. Profound sensorineural hearing loss was secondary to bacterial meningitis. Average age at onset of meningitis was 1 year 10 months (range, 10 months to 3 years 9 months). The causative agent was *Hemophilus influenzae* in 12 patients, *Diplococcus pneumoniae* in six, *Neisseria meningitidis* in one, and unknown in one. All patients experienced profound sensorineural hearing loss at the time of or almost immediately after the meningitis episode. Balance disturbance was a frequent complication but gradually cleared in all patients. Seizures were an infrequent complication, and one patient had had left upper extremity paresis, which resolved.

As part of an extensive clinical evaluation [2], polytomography was performed bilaterally in anteroposterior position at 1-mm intervals. The average age at time of clinical evaluation was 7 years 4 months (range, 3 years and 4 months to 13 years). All patients underwent cochlear implantation shortly after clinical evaluation, usually within 1 week. At the time of surgery, the degree of ossification of the round window and scala tympani was recorded. The response to cochlear implant stimulation was evaluated postoperatively.

Results

The radiographic and surgical findings are summarized in table 1. Ossification of the cochlear labyrinth was demonstrated by polytomography in 11 and identified at surgery in 14 of 20 patients. Ossification was demonstrated radiographically in five of six patients with pneumococcal meningitis; in four of these five, the ossification was dense (fig. 1). *Hemophilus influenzae* meningitis resulted in labyrinthine ossification in seven of 12 patients; ossification was demonstrated radiographically in four of these patients and was less marked, revealing mild bony thickening

Received January 25, 1984; accepted after revision April 29, 1984.

¹ Department of Radiology, University of Southern California, Los Angeles County-USC Medical Center, 1200 N. State St., Los Angeles, CA 90033. Address reprint requests to T. S. Becker.

² House Ear Institute, Los Angeles, CA 90057.

³ Otological Medical Group, Los Angeles, CA 90057.

AJNR 5:739-741, November/December 1984
0195-6108/84/0506-0739
© American Roentgen Ray Society

pneumococcal meningitis did not occur in those with *Hemophilus influenzae* nor in the two patients whose meningitis was attributable to other organisms.

Only one cochlear implant has failed thus far in these children, who have been followed for up to 2 years. The failure occurred in an 8-year-old boy who had pneumococcal meningitis at 2 years of age. Dense ossification of the cochlear capsule was noted on polytomography (fig. 1) and also was demonstrated at surgery. The findings were identical to those in three of four other children who had had pneumococcal meningitis, whose implants have been successful.

Discussion

Ossification of the membranous labyrinth (labyrinthitis ossificans) of the inner ear has been observed secondary to trauma, tumors, surgery, middle ear infection, toxic and vascular factors, and meningitis [3-15]. The most common cause of labyrinthitis ossificans is bacterial invasion of the labyrinth, whether from bacterial otitis media (tympagogenic), meningitis (meningogenic), or, less commonly, septicemia (hematogenic) [12]. In meningogenic labyrinthitis ossificans, bacterial spread from the meninges and cerebrospinal fluid enters the inner ear via the cochlear aqueduct and the internal auditory canal [8]. After polymorphonuclear leukocyte invasion, fibroblasts proliferate and new bone forms in the perilymphatic spaces in the labyrinth. The result is variable fibrosis and ossification of the membranous labyrinth.

Sensorineural hearing loss secondary to bacterial meningi-

tis is the most common cause of severe acquired hearing loss in children, occurring in about 11% of affected children [15]. As noted by others [15] and confirmed by us, *Hemophilus influenzae* is the most common offending organism. Pneumococcal (*Diplococcus pneumoniae*) and staphylococcal meningitis are much less frequent causes of sensorineural hearing loss. No staphylococcal meningitis occurred in our patients.

Although much has been written about the clinical and pathologic assessment of labyrinthitis ossificans, little has been written about its radiographic assessment. Hoffman et al. [1] described complex motion tomography in four patients with tympanogenic labyrinthitis ossificans; extensive to complete bony obliteration of the labyrinth was noted in their patients. Ibrahim and Linthicum [14] reported eight patients with labyrinthitis ossificans, including three in whom the diagnosis was made ante mortem using polytomography. However, no large-scale study has been done to assess the reliability of the polytome in assessing labyrinthitis ossificans and its clinical implications.

Our results show that polytomography is very reliable in diagnosing ossification of the labyrinth in postmeningitic children; the diagnosis was made radiographically in 11 of 14 children with surgical confirmation of ossification at the time of cochlear implantation. Of these 11, four had dense ossification of the labyrinth, all secondary to had pneumococcal meningitis (fig. 1). In the other seven patients, minimal ossification was identified radiographically as a slight narrowing of the basal turn of the cochlear lumen (fig. 2).

The cochlear implant is an electronic auditory prosthesis that has been used primarily in profoundly hearing-impaired adults [16-18]. Polytomography is used routinely in preoperative evaluation of patients seeking the device [2]. Cochlear implantation has only recently been performed in children [19], and there has been some reluctance to implant the device in patients with evidence of ossification of the labyrinth. However, our results indicate that cochlear implantation usually will be successful despite the presence of labyrinthine ossification. After a maximum 2-year follow-up period, all children with mild ossification have had successful implants, according to clinical and audiometric data. Only one child, an

TABLE 1: Postmeningitic Labyrinthine Ossification in Children with Cochlear Implants

Bacterial Agent	No. with Ossification Demonstrated by Polytomography/at Surgery
<i>Hemophilus influenzae</i> (n = 12)	4/7
<i>Diplococcus pneumoniae</i> (n = 6)	5/5
<i>Neisseria meningitidis</i> (n = 1)	1/1
Unknown (n = 1)	1/1
Total (n = 20)	11/14

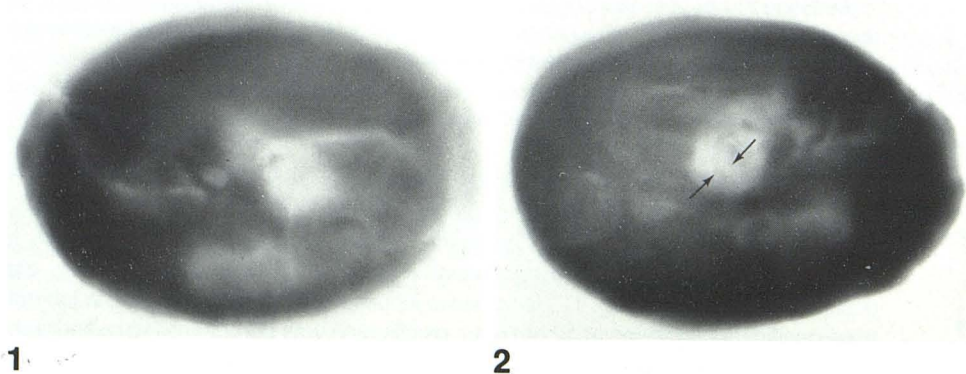


Fig. 1.—Severe labyrinthitis ossificans in 8-year-old boy deafened at age 2 by pneumococcal meningitis. Complete ossification of cochlear labyrinth.

Fig. 2.—Mild labyrinthitis ossificans in 4-year-old boy deafened at age 3 by *Hemophilus influenzae* meningitis. Narrowing of basal turn of cochlea (arrows).

8-year-old boy deafened by pneumococcal meningitis at age 2, has stopped using his implant. Electrical stimulation in this group of children showed good correlation, since only the latter child failed to respond to electronic testing [20].

Because of the high incidence of hearing loss secondary to meningitis, otologic and audiologic follow-up in postmeningitis patients is necessary. The diagnosis of labyrinthitis ossificans is important as a warning of obliteration of key inner-ear landmarks [1] before mastoid surgery. Moreover, since one of the four children with dense ossification in our series had an unsuccessful cochlear implant, this information may alter the parents' and physician's decision to proceed with cochlear implantation.

REFERENCES

- Hoffman RA, Brookler KH, Bergeron RT. Radiological diagnosis of labyrinthitis ossificans. *Ann Otol Rhinol Laryngol* **1979**; 88:253-257
- Berliner KI, House WF. The cochlear implant program: an overview. *Ann Otol Rhinol Laryngol* **1982**;91:11-14
- Brunner H. Otosclerosis associated with osteoporosis and labyrinthitis chronica ossificans. *Arch Otolaryngol* **1949**;184-195
- Igarashi M, Schuknecht HF. Pneumococcal otitis media, meningitis, and labyrinthitis. *Arch Otolaryngol* **1962**;76:126-130
- Paparella MM, Sugiura S. The pathology of suppurative labyrinthitis. *Ann Otol Rhinol Laryngol* **1967**;76:554-586
- Henneford GE, Lindsay JR. Deaf-mutism due to meningogenic labyrinthitis. *Laryngoscope* **1968**;78:251-261
- Paparella MM, Oda M, Fumihida H, Brady D. Pathology of sensorineural hearing loss in otitis media. *Ann Otol Rhinol Laryngol* **1972**;81:632-647
- Lindsay JR. Deafness acquired in early postnatal childhood. In profound childhood deafness: inner ear pathology. *Ann Otol Rhinol Laryngol [suppl]* **1973**;82[5]:88-102
- Igarashi M, Saito R, Alford BR, Fulippone MV, Smith JA. Temporal bone findings in pneumococcal meningitis. *Arch Otolaryngol* **1974**;99:79-83
- Suga F, Lindsay JR. Labyrinthitis ossificans due to chronic otitis media. *Ann Otol Rhinol Laryngol* **1975**;84:37-44
- Sugiura S, Paparella MM. The pathology of labyrinthine ossification. *Laryngoscope* **1976**;77:1974-1989
- Suga F, Lindsay JR. Labyrinthitis ossificans. *Ann Otol Rhinol Laryngol* **1977**;86:17-29
- Prado S, Paparella MM. Sensorineural hearing loss secondary to bacterial infection. *Otolaryngol Clin North Am* **1978**;11:35-41
- Ibrahim RAA, Linthicum FH. Labyrinthine ossificans and cochlear implants. *Arch Otolaryngol* **1980**;106:111-113
- Berlow SJ, Caldarelli DD, Matz FJ, Meyer DH, Harsch GG. Bacterial meningitis and sensorineural hearing loss: a prospective investigation. *Laryngoscope* **1980**;90:1445-1452
- House WF, Berliner KI. Cochlear implants: progress and perspectives. *Ann Otol Rhinol Laryngol* **1982**;91:3-124
- Balkany TJ. An overview of the electronic cochlear prosthesis: clinical and research considerations. *Otolaryngol Clin North Am* **1983**;16:209-215
- Council of Scientific Affairs, Division of Scientific Activities. Cochlear implants. *JAMA* **1983**;250:391-392
- Eisenberg LS, Berliner KI, Thielemeier MA, Kirk KI, Tiber N. Cochlear implants in children. *Ear Hear* **1983**;4:41-50
- Eisenberg LS, Luxford WM, Becker TS, House WF. Electrical stimulation of the auditory system in children deafened by meningitis. Presented at the annual meeting of the American Academy of Otolaryngology-Head and Neck Surgery, Anaheim, CA, October **1983**