

Intraventricular Cysticercal Cysts: Further Neuroradiologic Observations and Neurosurgical Implications

Chi-Shing Zee¹
 Hervey D. Segall¹
 Michael L. J. Apuzzo²
 Jamshid Ahmadi¹
 William R. Dobkin²

Intraventricular cysticercosis is potentially lethal. Six of 46 patients died from acute hydrocephalus shortly after hospital admission. The need for early computed tomographic scanning in immigrants from endemic areas complaining of headaches is emphasized by this experience. If time has elapsed since the initial diagnosis, these cysts may migrate within the ventricular system. Reconfirmation of the location of an intraventricular cysticercal cyst is advisable before surgery. Contrast enhancement of an intraventricular cysticercal cyst implies associated granular ependymitis. Surgical removal of such cysts probably should not be attempted as long as the cysts are not causing significant mass effect with neurologic signs and symptoms. Shunting alone is advocated for the treatment of hydrocephalus.

Not long after computed tomography (CT) became widely available, its great value in the diagnosis and evaluation of patients with intracranial cysticercosis became apparent [1-3]. It was also evident that the value of CT in this condition was improved when used in conjunction with intravenous contrast material and intraventricular metrizamide [1-5].

In recent years, we have observed and reported various neuroradiologic features of intraventricular cysticercal cysts, including cyst mobility, change of cyst configuration, contrast enhancement, and metrizamide entrance into an intraventricular cyst [3, 4]. Since then, as our experience has evolved, the role and value of standard CT scans and the use of intravenous and intraventricular contrast agents in the evaluation of patients with intraventricular cysticercosis cysts have become apparent. This report elaborates the practical significance of some of these findings and updates the application of CT on the basis of our most recent experience with patient management and neurosurgical treatment.

Materials and Methods

During the years 1977-1983, 266 cases of cysticercosis cerebri were diagnosed at the Los Angeles County/University of Southern California (LAC/USC) Medical Center. Diagnosis was made on the basis of a constellation of characteristic clinical, radiologic, and pathologic findings. Of the 266 cases, 46 (17.3%) had intraventricular cysticercal cysts. All of these patients had cranial CT examinations, and most had metrizamide ventriculography or metrizamide CT ventriculography; blood and cerebrospinal fluid (CSF) cysticercosis titers were evaluated by the Centers for Disease Control in Atlanta. The age of these patients was 10-77 years. All had lived in Mexico or Central America.

Results

Forty-six patients were studied with intraventricular cysticercosis. Fourth-ventricle cysticercal cysts were the most common (26 cases), followed by third-ventricle cysts (12 cases) and lateral-ventricle cysts (eight cases). Some important observations concerning intraventricular cysticercal cysts were made on the basis of

Received December 27, 1983; accepted after revision March 14, 1984.

¹ Department of Radiology, Neuroradiology Section, University of Southern California School of Medicine, 1200 N. State St., Los Angeles, CA 90033. Address reprint requests to C.-S. Zee.

² Department of Neurosurgery, University of Southern California School of Medicine, Los Angeles, CA 90033.

AJNR 5:727-730, November/December 1984
 0195-6108/84/0506-0727

© American Roentgen Ray Society

TABLE 1: Clinical and Pathologic Findings in Patients Who Died from Obstructive Intraventricular Cysticercal Cysts

Case No. (age, gender)	Birthplace	Headache Duration	Other Symptoms	Prior Diagnosis	Admission Examination	Pathological Findings
1 (10, F) . . .	El Salvador	3 days	Nausea, vomiting	Meningitis	Nuchal rigidity, lethargy	Cysticercal cyst in left lateral ventricle, occluding foramen of Monro; cerebral edema
(32, F) . . .	Mexico	3 months	Diplopia, numbness	Migraine	Loss of consciousness	Cysticercal cyst, right lateral ventricle; hydrocephalus; cerebral edema, with cerebellar tonsillar herniation
(25, F) . . .	Mexico	6 months	Syncope	No specific diagnosis ("headaches")	Apnea, fixed pupils	Cysticercal cyst, left lateral ventricle; cerebral edema; cerebellar tonsillar herniation
(27, F) . . .	Mexico	3 months	Nausea, vomiting	No specific diagnosis ("headaches")	Seizure	Cysticercal cyst in fourth ventricle; hydrocephalus
(30, F) . . .	Mexico	3 months	Diplopia, numbness	Migraine	Vomiting, loss of consciousness	Cysticercal cysts in the third ventricle; obstruction of right foramen of Monro
(29, F) . . .	Ecuador	4 months	Numbness	Cysticercosis	Lethargy, seizures	Hydrocephalus; obstruction of right foramen of Monro by cysticercal cyst

Note.—Case 1 is described more fully in the Case Reports section of this article.

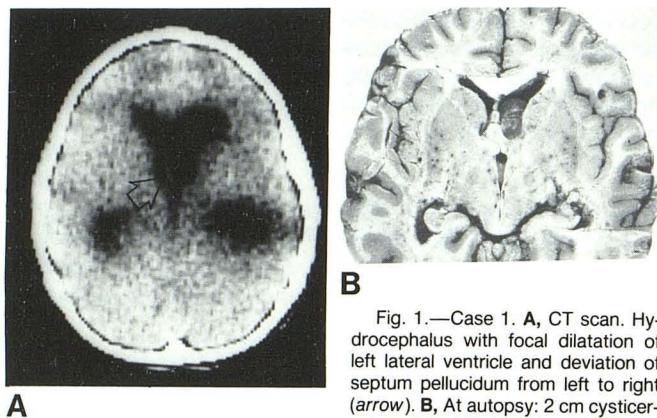


Fig. 1.—Case 1. **A**, CT scan. Hydrocephalus with focal dilatation of left lateral ventricle and deviation of septum pellucidum from left to right (arrow). **B**, At autopsy: 2 cm cysticercal cyst in left lateral ventricle obstructing foramen of Monro.

three findings: (1) acute hydrocephalus and sudden death secondary to intraventricular cysticercal cysts, (2) cyst migration, and (3) contrast enhancement of intraventricular cysticercal cysts and the surgical significance of this phenomenon. Representative case reports illustrate each of these findings. Table 1 summarizes the findings in six patients with intraventricular cysticercal cysts who developed acute obstructive hydrocephalus and died.

Representative Case Reports

Case 1. Acute Hydrocephalus and Sudden Death Secondary to Intraventricular Cysticercal Cysts

A 10-year-old girl from El Salvador had been in the United States for 2 months when she developed headaches, nausea, and vomiting. She was admitted to an outside hospital because of persisting symptoms. Physical examination showed a lethargic, afebrile girl with normal optic disks, equal pupils, and mild nuchal rigidity. Lumbar puncture at the outside hospital showed 18 white blood cells/mm³, normal protein and glucose, and pressure of 210 mm.

The next day, she stopped breathing. She was resuscitated but remained comatose, with fixed pupils. She was then transferred to the LAC/USC Medical Center. Emergency CT showed moderate

dilatation of the left lateral ventricle (fig. 1A). A ventriculostomy was performed immediately, but she failed to improve, and died on hospital day 3. At autopsy, a 2 cm cysticercal cyst was easily removed from the left lateral ventricle at the foramen of Monro (fig. 1B).

Case 2. Cyst Migration

A 12-year-old boy was admitted because of increasing headache, vomiting, and double vision of 2 weeks duration. There had been a 2 month history of headaches. He was born in Mexico, but had lived in the United States for 8 years. Neurologic examination showed a lethargic, intermittently agitated boy. He was able to follow only simple commands and uttered only a few words. There was no papilledema. CT showed dilated third and lateral ventricles with a normal-sized fourth ventricle. The third ventricle, however, appeared disproportionately dilated (fig. 2A). Intracranial calcification was also seen on higher slices.

A left frontal ventriculostomy was performed; the pressure was normal. A metrizamide CT ventriculogram showed a cyst in the third ventricle (fig. 2B). The evening before surgery for removal of the third-ventricle cyst, the patient's level of consciousness decreased, with fixed and dilated pupils, and extensor posturing was noted. His condition improved after right frontal ventriculostomy. A CT scan showed some significant alterations: the third ventricle appeared deflated (fig. 2C), but there was an increase in the size of the fourth ventricle (fig. 2D). Because of this, metrizamide CT ventriculography was performed; it revealed that the cyst was no longer in the third ventricle but in the fourth ventricle (fig. 2E). Thus, a suboccipital, instead of transcallosal, craniectomy was performed for removal of the fourth-ventricle cysticercal cyst. The patient recovered uneventfully after surgery.

Case 3. Contrast Enhancement of Intraventricular Cysticercal Cysts

A 40-year-old woman from El Salvador complained of chronic headache of 4 months duration. A CT scan showed dilatation of the lateral, third, and fourth ventricles (figs. 3A and 3B). A metrizamide ventriculogram showed a cyst in the fourth ventricle with outlet obstruction. The patient was treated with a ventriculoperitoneal shunt and the headache resolved.

Six months later, she was readmitted because of increasing headache. CT revealed an enhancing ringlike lesion at the site of the fourth

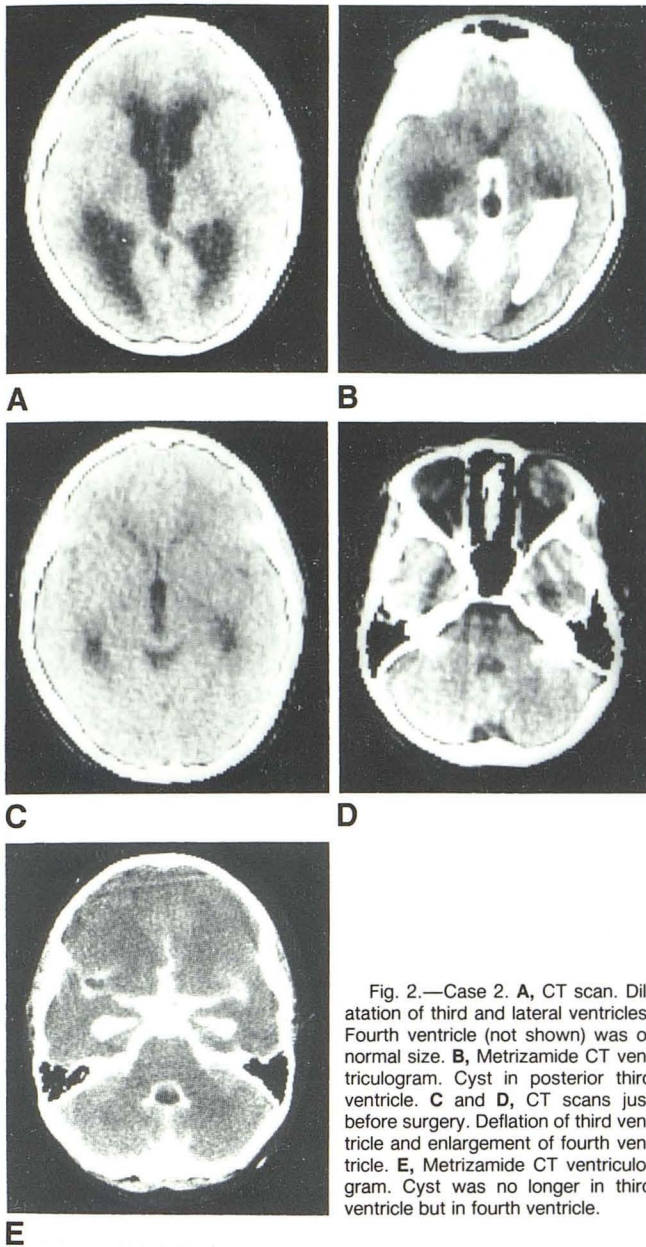


Fig. 2.—Case 2. A, CT scan. Dilatation of third and lateral ventricles. Fourth ventricle (not shown) was of normal size. B, Metrizamide CT ventriculogram. Cyst in posterior third ventricle. C and D, CT scans just before surgery. Deflation of third ventricle and enlargement of fourth ventricle. E, Metrizamide CT ventriculogram. Cyst was no longer in third ventricle but in fourth ventricle.

ventricle, the cavity of which had become obliterated (fig. 3C). A cysticercal cyst was removed from the fourth ventricle; it was adherent to the ventricular wall, and there was evidence of adjacent granular ependymitis and adhesive arachnoiditis. After surgery, diplopia and headache persisted, and a repeat CT scan revealed no change in the size of the third and lateral ventricles. A shunt revision was required to decompress the enlarged ventricles.

Discussion

Intraventricular cysticercal cysts generally cannot be diagnosed directly on CT scans without intraventricular contrast material because they appear to be about the same density as CSF. However, a fourth-ventricle cyst may be suspected if a markedly dilated fourth ventricle appears disproportionately large compared with the third and lateral ventricles

(particularly when normal fourth-ventricle contours are lost). A lateral-ventricle cyst may be suspected when there is unilateral dilatation of one of the lateral ventricles with deviation and bowing of the septum pellucidum (as in case 1). The presence of a third-ventricle cyst can be predicted on standard CT studies (as in case 2) if the configuration of the dilated third ventricle is inappropriate. However, intraventricular contrast agents are generally advocated for ultimate demonstration of the intraventricular cyst (metrizamide is currently preferred) [3].

In recent years, we have studied 46 patients with intraventricular cysticercal cysts. We encountered a number of clinical manifestations and consequences in this group of patients that we consider to be very important. Furthermore, the practical significance of certain CT findings also became apparent during our study.

Although intraventricular involvement is present in a relatively small percentage (11%–17%) of cases of intracranial cysticercosis [2, 6–9], this is a very significant group, since intraventricular cysticercal cysts can be life-threatening.

Six of the 46 patients with intraventricular cysticercal cysts in our series died from acute hydrocephalus shortly after admission. All six complained of headache, nausea, and vomiting for a period of 3 days to 3 months before admission (table 1). In the absence of secondary signs of increased intracranial pressure (such as papilledema or abducens nerve palsy), there was little in their early course to indicate the gravity of their condition. A diagnosis of vascular headache was often made. As shown by the cases presented here, the diagnosis of obstructive hydrocephalus can be exceedingly difficult. It is clear that in view of the high incidence of cysticercosis in immigrants from endemic areas, earlier CT scanning should be performed in such patients complaining of severe or persisting headache. Careful scrutiny of CT scans may reveal subtle changes in patients with intraventricular cysticercosis, such as deviation of the septum pellucidum or focal distension of a ventricular chamber disproportionate to the degree of hydrocephalus. When a ventricular cyst is suspected, a metrizamide ventriculogram or a metrizamide CT ventriculogram can confirm the diagnosis and may help in establishing the surgical approach [3].

In an earlier study, we reported on a freely mobile cyst in the lateral ventricle and a third-ventricle cyst migrating into the right lateral ventricle after combined metrizamide ventriculography and pneumoencephalography [3]. We have adopted the term "migration" for those cysts that have moved from one ventricle to another. In three of our 46 cases cysts were shown to migrate. The case we report here (case 2) clearly illustrates the practical significance of this phenomenon. Had a CT scan not been obtained before surgery, the patient would have had a transcallosal approach for removal of a third-ventricle cyst, with potentially grave consequences.

Awareness of the phenomenon of intraventricular cyst migration and recognition of pertinent CT findings associated with cyst migration is exceedingly important in view of the experience outlined above. We recommend that a CT scan be obtained immediately before surgery to reconfirm the location of an intraventricular cyst. Case 2 documents the passage of a cysticercal cyst from the third ventricle to the

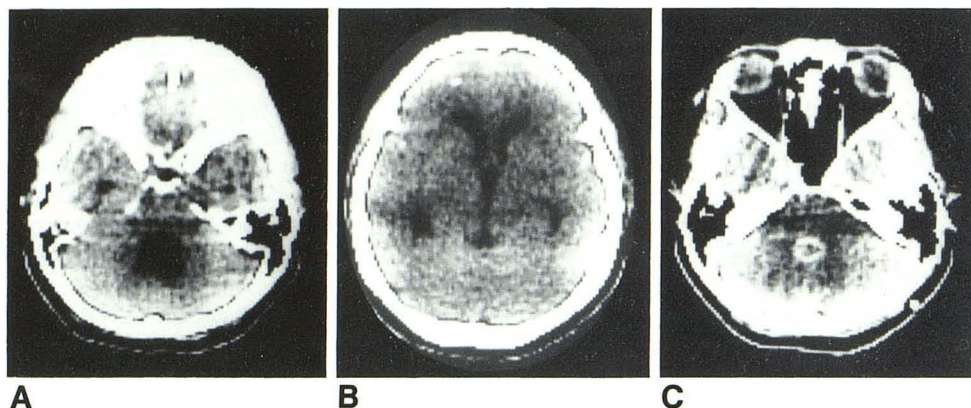


Fig. 3.—Case 3. **A** and **B**, CT scans. Dilatation of third, fourth, and lateral ventricles and intracranial calcifications. Metrizamide ventriculogram (not shown) showed cyst in fourth ventricle with outlet obstruction. **C**, CT scan 6 months later for increasing headache. Enhancing ring-like lesion at site of fourth ventricle, which had become totally obliterated.

fourth ventricle, and may provide an explanation for the preponderance of cysts found in the fourth ventricle, as noted by various authors [5, 10, 11].

The importance of reconfirming the location of an intraventricular cyst immediately before surgery was underscored in another case that came to our attention very recently. In this case, a large cyst was demonstrated within the fourth ventricle on a metrizamide ventriculogram. The location of the cyst was not reconfirmed immediately before surgery, as we recommend. Instead, the patient had a posterior fossa craniectomy and fourth-ventricle exploration without repeat CT. No cyst was found within the fourth ventricle. A repeat metrizamide ventriculogram showed no cyst in the fourth ventricle, which was normal in size. There had been no change in the patient's clinical status or other warning to suggest that cyst migration had occurred. It is possible that the cyst in this case could have migrated into the spinal subarachnoid space; it could have also ruptured spontaneously.

Only a small percentage of intraventricular cysticercal cysts enhance after intravenous injection of contrast material [3, 12]. However, enhancement in such lesions may be an important observation in terms of patient management.

Five of the 46 patients with intraventricular cysticercal cysts were found to have granular ependymitis with adhesions between the cyst wall and ependyma at surgery. It is of great interest that four of these five patients exhibited ringlike contrast enhancement on CT scans obtained shortly before surgery. Conversely, all patients who had no evidence of granular ependymitis at surgery displayed no contrast enhancement on CT scans. All five patients with granular ependymitis developed signs of persistent headache after initial surgery and required CSF-diverting shunts. In contrast, most patients without granular ependymitis showed regression of hydrocephalus and did not require a subsequent shunt procedure. Since four of five patients with granular ependymitis showed contrast enhancement on CT scans, and since all patients with ependymitis found at surgery eventually required CSF-diverting shunts, it is reasonable to conclude that most patients, at least, with enhancing intraventricular cysts will need diverting CSF shunts because surgical removal of the cyst will probably not alleviate the hydrocephalus. Therefore, we advocate treating patients with enhancing intraventricular cysts with shunting alone, as long as the cyst is not causing a significant local mass effect producing neurologic signs and symptoms.

Obviously, other pathologic entities can appear as enhancing lesions having a ring configuration, and these must be given consideration in the differential diagnosis. However, when the patient's ethnic and geographic origins are considered and when there is a convincing constellation of other findings (including such observations as intracranial calcifications on CT, evidence of muscular cysticercosis, positive blood and CSF cysticercosis titers, eosinophilia, etc.), the diagnosis of an enhancing intraventricular cysticercal cyst can be made confidently. When such a diagnosis is well founded, a diverting CSF shunt alone may suffice. In certain cases, however, a surgical or stereotaxic biopsy may be necessary for definite diagnosis.

REFERENCES

1. Bentson JR, Wilson GH, Helmer E, Winter J. Computed tomography in intracranial cysticercosis. *J Comput Assist Tomogr* 1977;1:464-471
2. Carbajal JR, Palacios E, Azar-kia B, Churchill R. Radiology of cysticercosis of the central nervous system including computed tomography. *Radiology* 1977;125:127-131
3. Zee CS, Segall HD, Miller C, et al. Unusual neuroradiological features of intracranial cysticercosis. *Radiology* 1980;137:397-407
4. Zee CS, Tsai FY, Segall HD, Teal JS, Ahmadi J. Entrance of metrizamide into an intraventricular cysticercosis cyst. *AJNR* 1981;2:189-191
5. McCormick GF, Zee CS, Heiden J. Cysticercosis cerebri: review of 127 cases. *Arch Neurol* 1982;39:534-539
6. Dorfsman J. The radiological aspects of cerebral cysticercosis. *Acta Radiol [Diagn] (Stockh)* 1963;1:836-842
7. Bricero CE, Biagi F, Martinez B. Cysticercosis: observaciones sobre 97 casos de autopsia. *Prensa Med Mex* 1961;26:193-197
8. Santin G, Vargas J. Roentgen study of cysticercosis of central nervous system. *Radiology* 1966;86:520-528
9. Segall HD, Rumbaugh CL, Bergeron RT, Teal JS. Neuroradiology in infections of brain and meninges. *Surg Neurol* 1973;1:178-186
10. Loyo M, Kleriga E, Estanol B. Fourth ventricular cysticercosis. *Neurosurgery* 1980;7:456-458
11. Escobar A, Nieto D. Parasitic disease. In: Minckler J, ed. *Pathology of the nervous system*. New York: McGraw-Hill, 1972:2503-2521
12. Jankowski R, Zimmerman RD, Leeds NE. Cysticercosis presenting as a mass lesion at the foramen of Monro. *J Comput Assist Tomogr* 1979;3:694-696