

Persistent Cortical Enhancement in Tuberculous Meningitis

Richard A. Suss,¹ Silvia Resta,² and Jan T. Diehl¹

Intracranial tuberculosis occurs in a diffuse form as a basal, exudative leptomeningitis and in localized forms as tuberculomas and as tuberculous brain abscess. This paper describes two patients with culture-proven tuberculous meningitis whose CT findings differed from any known pattern in tuberculosis of the central nervous system.

Case Reports

Case 1

A 25-year-old woman presented with right lower quadrant abdominal pain, subjective fever, weight loss, diffuse headaches, occasional nausea and vomiting, intermittent right facial numbness and right leg weakness, and mild photophobia. She had recently immigrated to the United States from Mexico, where she had been ill for several months. At admission she was afebrile. There was no abnormality of mentation or speech. The optic disks were erythematous with indistinct margins, suggesting papilledema. Right facial sensation was decreased. Neck flexion was painful but Kernig's and Brudzinski's signs were absent. Tenderness was noted in the right uterine adnexa and right lower quadrant. There was a mild, symmetrical hyperreflexia. Strength was normal. She had a normal leukocyte count and a normochromic, microcytic anemia. There was no evidence of inappropriate antidiuretic hormone secretion. Lumbar puncture performed at admission yielded clear, slightly yellow fluid under an opening pressure greater than 20 cm of CSF, with protein 280 mg/dl, glucose 17 mg/dl, 12 red cells and 610 nucleated cells per mm³ (12% poly, 81% lymph, 7% mono), and a positive Ziehl-Neelsen stain for two acid-fast bacilli. *Mycobacterium tuberculosis* was cultured from a subsequent CSF specimen. CSF studies for bacterial meningitis, syphilis, and fungi were negative. An intermediate-strength PPD was strongly positive, producing a 6 cm × 3 cm erythematous induration that was treated with steroid injections. A chest radiograph was normal. Pelvic sonography showed a right adnexal abnormality consistent with pelvic inflammatory disease, adnexal tuberculosis, or an ovarian cyst. CT at admission showed extensive white matter edema related to large areas of full-thickness gray matter enhancement in the sylvian, convexity, and interhemispheric cortex, and a limited amount of basal leptomeningeal density and enhancement (Figs. 1A–1C).

Initial treatment with nafcillin and chloramphenicol was changed after 2 days to isoniazid, ethambutol, and rifampin for 24 weeks. The course was marked by periodic temperature spikes up to 39.2 degrees C. A week after admission the patient developed lower extremity numbness, gait ataxia, and tunnel vision in the right eye,

which progressed over a few days to bare light perception, while the visual field of the left eye became constricted. By 1 month after initial admission the right eye had no light perception and the left had bare light perception. Evidence against cortical blindness was provided by sluggishness of pupillary responses and by abnormal visual evoked responses consisting of a positive retinal response with a lack of retroretinal potentials. The visual loss was considered too rapid to have been caused by the elevated intracranial pressure and was attributed to perichiasmal scarring. Intracranial pressure was eventually reduced to 17 cm of CSF with prednisone. CT at 2, 5, and 12 weeks after presentation, each time both without and with IV enhancement, demonstrated persistent areas of cortical enhancement essentially unchanged except for moderate reduction in the white matter edema, development of mild ventricular enlargement (Figs. 1D and 1E), and loss of the faint basal meningeal density and enhancement. A flattened right nasolabial fold and equivocal proximal weakness in the lower extremities were the only motor deficits.

Case 2

A 34-year-old man presented with weight loss, subjective fever, headache, and a nonproductive cough. He had been working for 1 year on a ranch after immigrating to the United States from Mexico, living in a dormitory, poorly nourished, and frequently consuming alcohol. "Disorientation" developed a month before admission. On admission he was afebrile, with debatable meningeal signs. The cranial nerves were intact. Strength and deep tendon reflexes were normal but the gait was considered to be somewhat spastic. There was a normochromic, normocytic anemia. Lumbar puncture on the day of admission yielded an opening pressure of 22 cm of CSF, protein 120 mg/dl, glucose 28 mg/dl, and 5 red cells and 510 nucleated cells per mm³ (87% poly, 3% lymph, 9% mono, 1% mesothelial). *Mycobacterium tuberculosis* was cultured from a subsequent CSF specimen. CSF studies for bacterial meningitis, syphilis, and fungi were negative. A sputum smear revealed acid fast bacilli. The chest radiograph showed extensive left upper lobe and patchy right upper lobe infiltrates and apical pleural thickening. CT the second day after admission showed a small, nonenhancing left putaminal lacune, edema in the left insular region, and hyperemia and mild cortical enhancement in the left sylvian fissure (Figs. 2A and 2B).

Treatment was begun with penicillin, isoniazid, rifampin, and pyrazinamide, with the penicillin replaced by streptomycin after 2 days. Marked neck stiffness developed. The patient's mental status deteriorated to muteness and noncooperation, and he was variably considered to have a thought disorder or Wernicke's aphasia. Intestinal

Received April 4, 1985; accepted after revision June 20, 1985.

¹Department of Radiology, University of Texas Health Science Center, 5323 Harry Hines Blvd., Dallas, TX 75235. Address reprint requests to R. A. Suss.

²Department of Internal Medicine, Infectious Disease Division, University of Texas Health Science Center, Dallas, TX 75235.

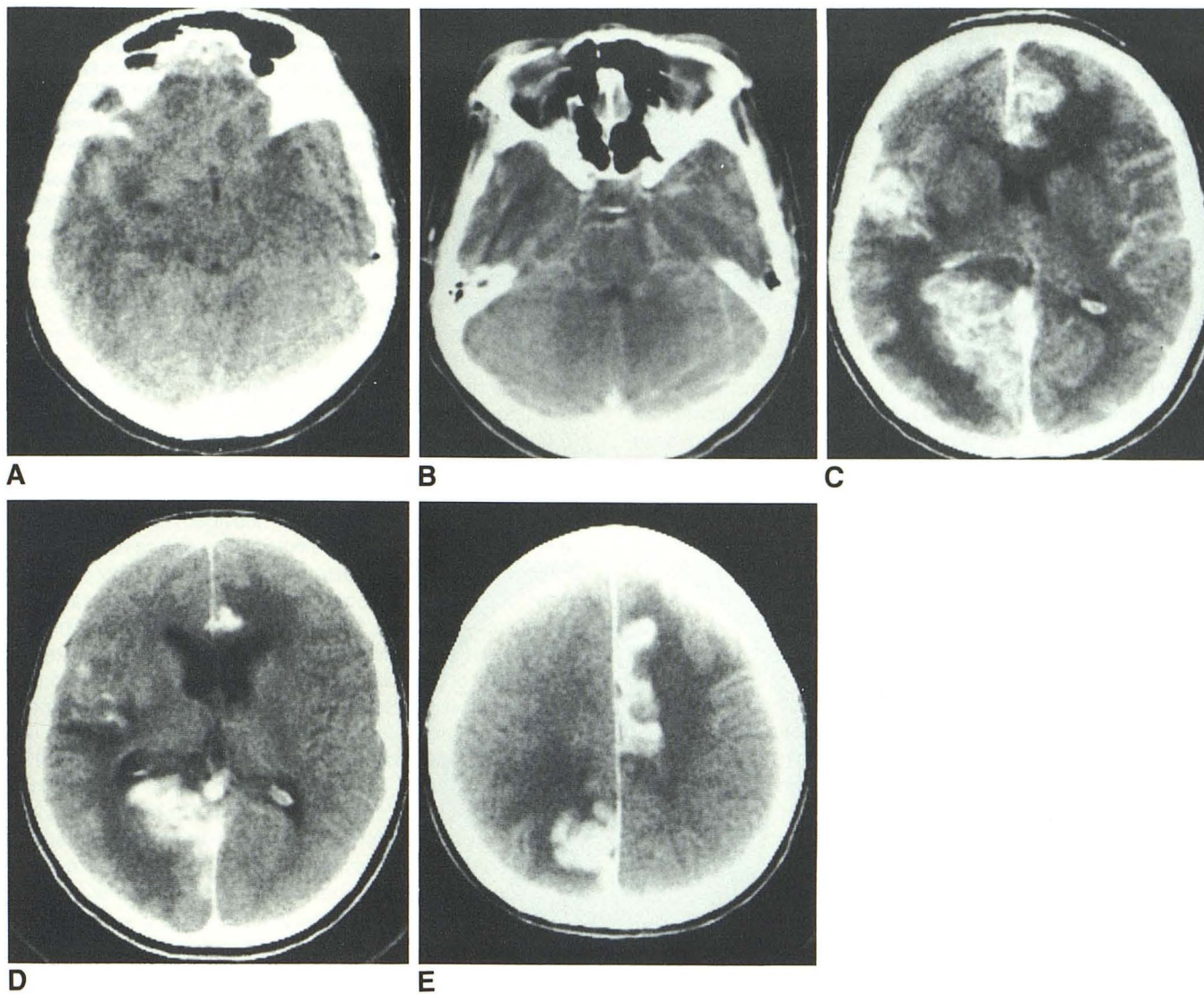


Fig. 1.—Case 1.

A, Noncontrast CT scan at admission. Density (which enhanced with contrast, not shown) in right sylvian fissure. Suggestion of density in anterosuperior suprasellar cistern and anterior interhemispheric fissure, not present on subsequent CT scans.

B, Contrast-enhanced CT scan at admission. Pontomesencephalic junction outlined by delicate enhancement constituting more than normal vascularity, at least partly leptomeningeal enhancement.

C, Higher-section CT scan at admission showing convolitional pattern of enhancement in three different regions, with swelling and ventricular distortion.

D and **E**, CT scans 5 weeks after admission showing persistent areas of convolitional enhancement with diminished mass effect and mild ventriculomegaly. Fourth ventricle remained small and basal cisterns were clear (not shown).

obstruction developed and a tuberculous distal ileum was resected. CT 2 weeks after admission demonstrated dense cortical contrast enhancement in the opercular portions of the left frontal and temporal lobes extending posterosuperiorly well into the parietal lobe, as well as enhancement of the left putaminal lacune (Figs. 2C and 2D). Enhancement extended medially along the sylvian fissure but not into the suprasellar or other basal cisterns. There was no appreciable edema or mass effect. At 5 weeks a moderate decrease in the extent of cortical enhancement was observed, as were the development of lucency without mass effect surrounding the enhancing area, loss of enhancement of the putaminal lacune, and the appearance of a second left putaminal lacune. After he was discharged, the patient's clinical status gradually improved during follow-up.

Discussion

Despite the CT evidence of extensive cerebral edema and blood-brain barrier breakdown, the first patient had neither an encephalopathy nor prominent focal cerebral signs. The three large areas of full-thickness cortical enhancement anatomically highlighting the gray matter all the way down to the gray-white junction conformed to the left pericallosal, right posterior cerebral, and part of the right middle cerebral artery cortical territories. Similar enhancement most commonly represents the subacute stage of a cortical infarct, or perhaps ischemia without infarction [1], but persistence of the enhancement

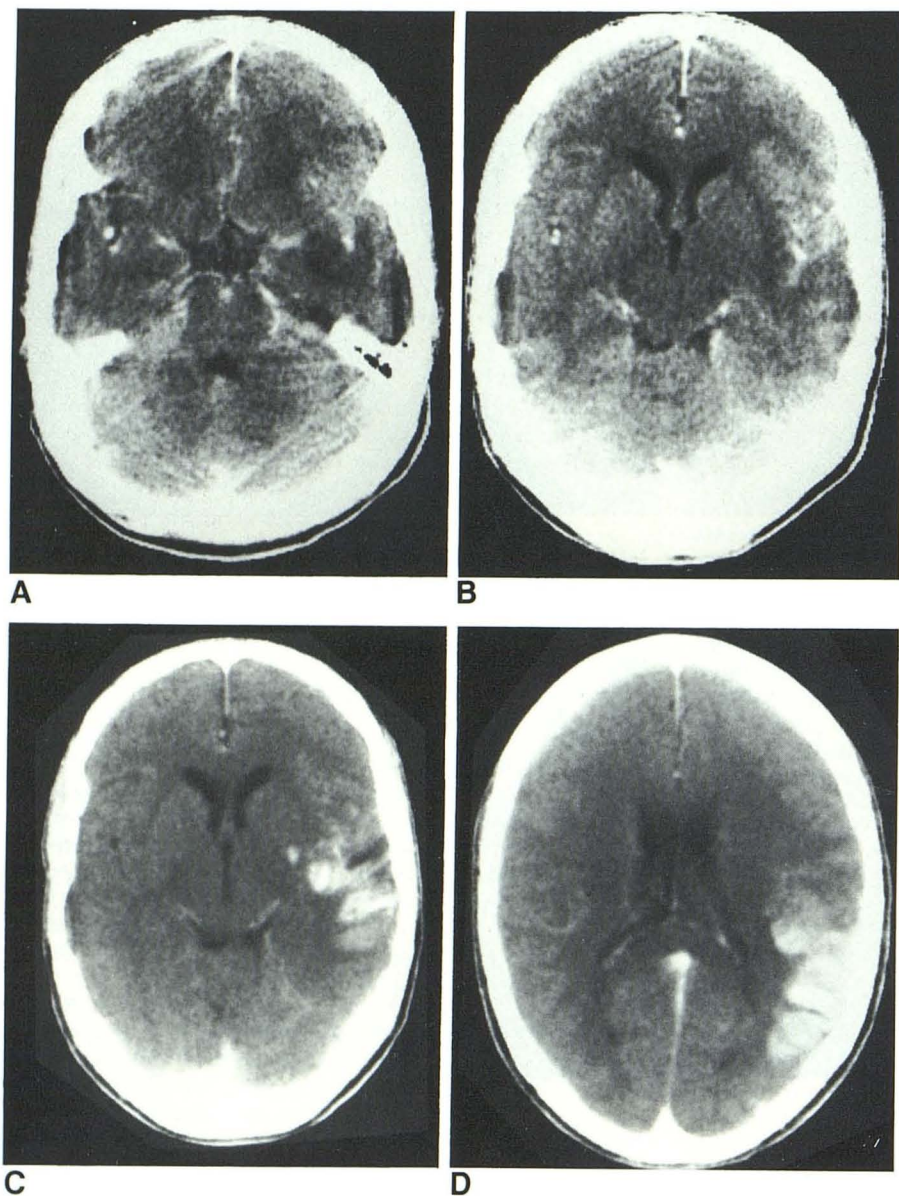


Fig. 2.—Case 2.

A and B, Contrast-enhanced CT scans at admission showing edema and mild cortical enhancement in region of left sylvian fissure, and a suggestion of abnormal enhancement around middle cerebral artery and in interpeduncular cistern. The next higher section (not shown) showed an ill-defined left putaminal lacunar lucency.

C and D, Contrast-enhanced CT scans 2 weeks after admission. Dense enhancement of cortical convolutions with lucent exudate in sylvian fissure. Enhancement of lacunar infarct in putamen.

over 3 months, failure of the involved areas to evolve toward lucency and atrophy, and lack of appropriate fixed-motor and sensory deficits ruled out infarcts and ischemia.

The second patient had a subacute process with a clinical encephalopathy. The temporal lobe edema and hyperemia initially present simulated herpes simplex encephalitis, but immediate recognition of the month-long history of mental abnormality, the pulmonary tuberculosis, and the polymorphonuclear predominance in the CSF prevented diagnostic confusion. The CT picture evolved within 2 weeks to full-thickness cortical enhancement similar to that in the first patient, although in only one vascular territory, with only modest resolution during the next 3 weeks. The development of two putaminal lacunar infarcts on the same side suggested middle cerebral arteritis. Similarities to a case of isolated

sylvian fissure tuberculosis reported by Klingensmith and Datu [2] included lack of hydrocephalus, presence of hyperemia, lack of pronounced enhancement on initial CT, and progression to temporoparietal enhancement in approximately 2 weeks. The appearance of the enhancement in their patient was not clearly described, the image was not published, and autopsy a few days later revealed sylvian meningitis with minimal cortical penetration, thus limiting comparability to our case.

Meningitis is by far the most common form of neurotuberculosis [3]. Tuberculous meningitis classically produces hydrocephalus and a densely enhancing exudate completely or partly filling the basal cisterns [4–10]. Although hydrocephalus is especially prone to develop and to be severe in children [3], its high frequency in adults, too, has been emphasized

[11]. Indeed, in the 18th century hydrocephalus was thought to be the essence of this disease, before the primary meningitic process was recognized [3]. On the other hand, only five of 11 patients in two series had hydrocephalus and only three of these had basal arachnoiditis demonstrable on early-generation CT [12, 13]. Extension of the exudate well out into the sylvian fissure is not uncommon [2, 3, 6, 8] and extension throughout the subarachnoid space of the convexities has been reported [9], but no pathologic or radiologic report has shown discretely segmental, full-thickness involvement or enhancement of the gray matter. Bhargava et al. [8] referred to "high attenuating lesions outlining the gyri compatible with encephalitis," but the appearance of these lesions, not shown, was not clarified. A case of tuberculous meningitis in an infant was described as showing "multiple areas of enhancement throughout the brain" [14], but the illustrated areas were compatible with sylvian and basal meningeal location and did not suggest full-thickness cortical enhancement.

Meningitis was demonstrated in both our patients by the CSF findings of hypoglycorrhachia and pleocytosis. Each had a suggestion of delicate basal meningeal enhancement on the initial CT only. The first patient also had clinical evidence of perichiasmal adhesions, and the second developed a nonenhancing fluid collection within the left sylvian fissure. Nevertheless, with the relatively modest ventriculomegaly in the first patient and absence of hydrocephalus in the second, and the absence in both patients of thick, organizing exudate in the suprasellar and circumsephenoidal cisterns, the picture of tuberculous meningitis was incomplete, while the cortical enhancement demonstrated an atypical location and degree of localization of the meningitic process.

The basal exudate in tuberculous meningitis has frequently been associated with arteritic narrowing or obliteration of large or lenticulostriate arteries and the development of infarcts. The degree of basal arterial narrowing correlates with the prominence of the basal exudate on CT [8], perhaps explaining the absence of or limited tendency to infarction in the present cases. Gray matter enhancement has also been reported in pyogenic bacterial meningitis, possibly consequent to vasculitis, but in such cases, too, it probably represents infarcts [15, 16]. Although it would have been of anatomic interest to establish the condition of the basal and cortical arteries, angiography was not considered justified on the basis of any differential diagnostic value or therapeutic benefit in the present cases with their established diagnosis and lack of significant focal neurologic deficit.

An unusual diffuse manifestation of CNS tuberculosis, occurring primarily in patients under 20, is tuberculous encephalopathy. This is an edematous or hemorrhagic encephalopathy or a postinfectious encephalitis-like process [17]. It usually is accompanied by tuberculous meningitis and almost always produces coma or semicoma. The global involvement of the white and gray matter, with gray matter involvement predominating only in acute cases, does not provide an explanation for the delimited, segmental cortical enhancement in the present cases.

Weil [18] described the tuberculoma as "a conglomeration of small tubercles in which caseation and frequently encap-

sulation occur, thus producing a tumor-like structure . . . a few millimeters in diameter . . . to the size of a hen's egg." Tuberculomas may lead to [18] or follow [4] tuberculous meningitis. Although considerable edema and softening may surround tuberculomas, and edema was evident at some time in both patients, the convolitional pattern of gray matter enhancement did not resemble concentric expansion of a mass such as a tuberculoma or an abscess, nor was there any ring-enhancement. Thus, although the enhancement was observed in localized segments of cortex, there was no evidence of the known localized forms of CNS tuberculosis.

The immunological status of the patient has long been known to influence the course of tuberculosis [18]. In geographic regions of high tuberculosis prevalence, meningitis usually occurs in childhood as primary disease, while in low-prevalence regions it is more common as recrudescence in adults. Tuberculomas, occurring in both children and adults, reflect a strong immune response in recrudescence disease. Both our patients were adults who had lived until recently in a region of high tuberculosis prevalence and had evidence of recrudescence disease. The first had no demonstrable primary focus but had a strong PPD response and the second had typical recrudescence pulmonary tuberculosis. The diffuse enhancement of involved cortex demonstrated a breakdown of the blood-brain barrier that may in turn have been due to an active or healing infection, an allergic response to tuberculoprotein, or another undefined cause. The meningoencephalitis in these patients was a recrudescence tuberculosis distributed to selected cerebrovascular territories either by primary hematogenous means or via an initial basal meningitis. In the cortex it progressed little if at all beyond a (presumed) microvascular arteritis or other microscopic form in the involved territories, implying a limited host response within the CNS that was sufficient for containment but insufficient to produce typical macroscopic tuberculomas.

ACKNOWLEDGMENTS

We are grateful to James P. Luby, Director, Infectious Disease Division, University of Texas Health Science Center at Dallas, for reviewing the manuscript, and to Jerry Cheek for photographic assistance.

REFERENCES

1. Kinkel WR, Jacobs L, Kinkel PR. Gray matter enhancement: a computerized tomographic sign of cerebral hypoxia. *Neurology* 1980;30:810-819
2. Klingensmith WC III, Datu J. Tuberculous meningitis of the Sylvian fissure. *Clin Nucl Med* 1978;3:315-317
3. Tandon PN. Tuberculous meningitis. In: Vinken PJ, Bruyn GW, eds. *Handbook of clinical neurology*, vol. 33. Amsterdam: Elsevier, 1978: 195-262
4. Stevens DL, Everett ED. Sequential computerized axial tomography in tuberculous meningitis. *JAMA* 1978;239:642
5. Arimitsu T, Jabbari B, Buckler RE. Computed tomography in a verified case of tuberculous meningitis. *Neurology* 1979;29:384-386
6. Casselman ES, Hasso AN, Ashwal S, Schneider S. Computed tomography in tuberculous meningitis in infants and children. *J Comput Assist Tomogr* 1980;4:211-216
7. Rovira M, Romero F, Torrent O, Ibarra B. Study of tuberculous meningitis by CT. *Neuroradiology* 1980;19:137-141

8. Bhargava S, Gupta AK, Tandon PN. Tuberculous meningitis—a CT study. *Br J Radiol* **1982**;55:189–196
9. Lehigh JR, Richardson EP. Case records of the Massachusetts General Hospital. *N Engl J Med* **1982**;306:91–97
10. Naheedy MH, Azar-Kia B, Fine M. Radiologic evaluation of tuberculous meningitis. *Invest Radiol* **1983**;18:224–229
11. Newman PK, Cumming WJK, Foster JB. Hydrocephalus and tuberculous meningitis in adults. *J Neurol Neurosurg Psychiatry* **1980**;43:188–190
12. Loizou LA, Anderson M. Intracranial tuberculomas: correlation of computerized tomography with clinico-pathologic features. *Q J Med* **1982**;51:104–114
13. Chambers ST, Hendrickse WA, Record C, Rudge P, Smith H. Paradoxical expansion of intracranial tuberculomas during chemotherapy. *Lancet* **1984**;2:181–184
14. Bachman DS. Letter to the editor. *Neurology* **1980**;30:347
15. Packer RJ, Bilaniuk LT, Zimmerman RA. CT parenchymal abnormalities in bacterial meningitis: clinical significance. *J Comput Assist Tomogr* **1982**;6:1064–1068
16. Weisberg LA. The role of CT in the evaluation of patients with intracranial CNS infectious-inflammatory disorders. *Comput Radiol* **1984**;8:29–36
17. Dastur DK, Udani PM. Pathology and pathogenesis of tuberculous encephalopathy. *Acta Neuropathol (Berl)* **1966**;6:311–326
18. Weil A. *A textbook of neuropathology*. Philadelphia: Lea & Febiger, **1933**:145–148