

Infected Congenital Mucocele of the Nasolacrimal Duct

Joel R. Meyer,¹ Douglas J. Quint,² Jonathan M. Holmes,³ and Brian J. Wiatrak⁴

Summary: The authors report their experience with an infant presenting with an infected nasolacrimal duct mucocele, emphasizing correlation of clinical, CT, and surgical findings. CT is the imaging modality of choice to demonstrate the triad of 1) a cystic medial canthal mass, 2) dilatation of the nasolacrimal duct, and 3) a submucosal nasal cavity mass; findings which are diagnostic of this entity. A brief review of the relevant embryology is also presented.

Index terms: Mucocele; Nose, abnormalities and anomalies; Nose, computed tomography; Pediatric neuroradiology

A congenital mucocele of the nasolacrimal duct is an uncommon lesion which results from maldevelopment of the nasolacrimal drainage system (1–5). Complications of this condition can include epiphora, dacryocystitis, cellulitis, sepsis, and respiratory distress (2). Computed tomography (CT) has been shown to play an important role in the diagnosis of this entity (1).

Case Report

At birth, a full-term white boy, born after an unremarkable pregnancy, was noted to have a purple swelling several millimeters in size just below the medial canthus of the left eye (Fig. 1A). Over the next few days, it became red and exuded yellow pus externally from the puncta at the medial aspect of the left eye. In addition, similar drainage was seen in the posterior left nasal cavity. A submucosal mass in the left lateral nasal wall, bulging medially into the nasal cavity, was noted. Physical and neurologic examinations were otherwise normal. There was no evidence of respiratory distress, and there were no systemic signs of infection. Differential diagnostic considerations at this time included encephalocele, dermoid, and nasolacrimal duct mucocele.

A noncontrast CT scan demonstrated a soft tissue mass in the lateral wall of the left nasal cavity (Fig. 1B). The soft-tissue mass extended inferiorly to the left inferior turbinate and extended superiorly in the expected location of the left nasolacrimal duct, where frank enlargement of the cephalad portion of the nasolacrimal duct was seen. A focal

mass of decreased attenuation was present in the medial aspect of the anterior portion of the left orbit; it was associated with preseptal soft tissue swelling (Fig. 1C). The observed constellation of findings was considered most consistent with a congenital mucocele of the nasolacrimal duct.

At surgery, after dilatation of the upper punctum (Fig. 2), a probe was passed along the superior canaliculus toward the lacrimal sac. Significant resistance was found at the valve of Rosenmuller (Fig. 2). The probe was eventually advanced into the lacrimal sac with decompression of several milliliters of creamy yellow material. Subsequently, endoscopic examination of the nasal cavity revealed a submucosal mass under the left inferior turbinate; it was incised and drained during simultaneous manual compression of the lacrimal sac. The mucosa of the mass was removed and was followed by successful probing of the entire nasolacrimal duct. A stenosis was identified at the valve of Hasner (Fig. 2), which after removal of additional mucosa was rendered probe patent. One day following surgery, there was both significant improvement of the medial canthal swelling and marked diminution in the size of the nasal cavity submucosal mass. There was complete resolution of both abnormalities at the 4-week follow-up examination.

Discussion

Embryologically, the nasolacrimal duct is derived from a linear thickening of ectoderm in the nasooptic fissure (6, 7). This bud of tissue sinks into the mesenchyme and detaches itself from the surface ectoderm with formation of an epithelial cord. At approximately 14 weeks gestation, this ectodermal cord canalizes. Although some authors believe this process occurs segmentally, beginning at the ocular (proximal) end of the cord with progression caudally, others argue that the process begins in the middle of the cord and moves both proximally and distally. There is consensus that the distal portion of the

Received April 28, 1992; revision requested August 21; revision received September 23 and accepted October 6.

¹ Northwestern Memorial Hospital, Olson Pavilion, Suite 3535, 710 North Fairbanks Court, Chicago, IL 60611. Address requests for reprints to Joel R. Meyer, MD.

Departments of ² Radiology, ³ Ophthalmology, and ⁴ Otorhinolaryngology, University of Michigan Hospitals, Ann Arbor, MI 48109-0030

AJNR 14:1008–1010, Jul/Aug 1993 0195-6108/93/1404-1008 © American Society of Neuroradiology

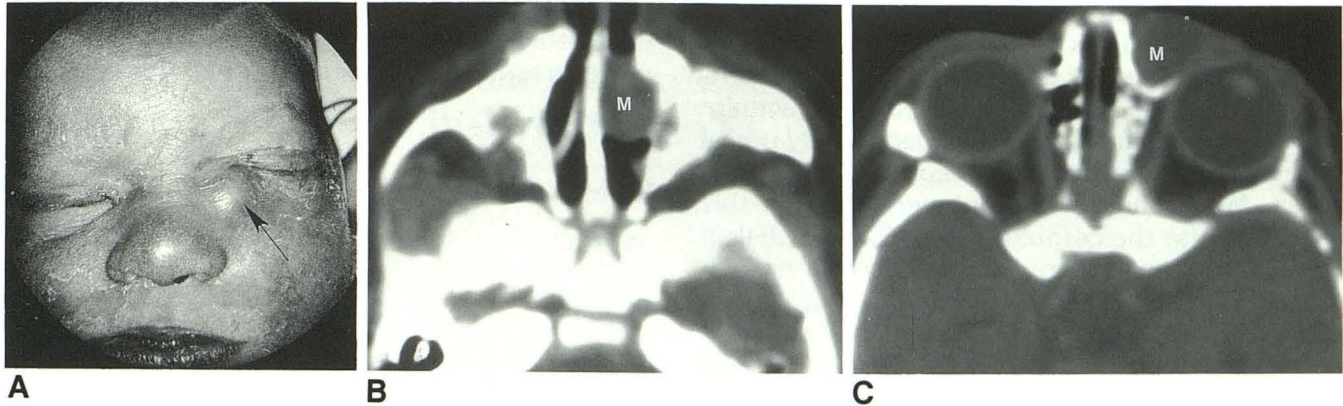


Fig. 1. Newborn with infection of congenital lacrimal duct mucocele. A, Swelling below the medial canthus of the left eye (arrow). Rhinoscopy demonstrated a submucosal mass bulging into the nasal cavity below the left inferior turbinate. Axial CT scans demonstrated the nasal cavity submucosal mass (M) (B) extending to the region of the medial canthus (C).

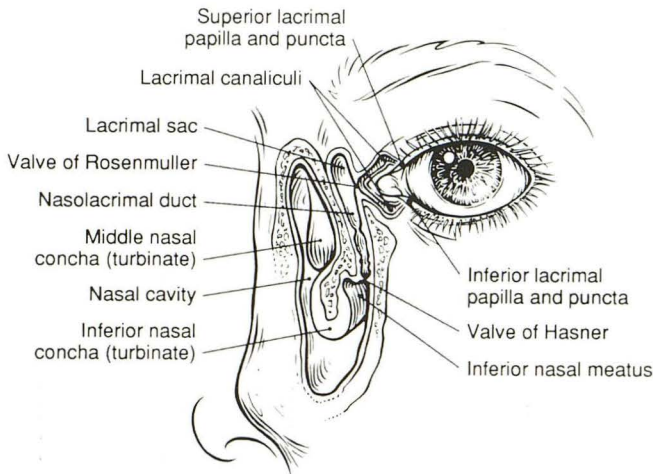


Fig. 2. Normal anatomy of the left nasolacrimal duct drainage system. Note the positions of the lacrimal puncta, valve of Rosenmuller, nasolacrimal duct, and the valve of Hasner.

nasolacrimal duct is the last to canalize routinely (6, 8, 9). A thin mucous membrane separates the distal end of the duct from the inferior meatus, which when patent is referred to as the valve of Hasner (Fig. 2).

An imperforate valve of Hasner at birth is a common finding, with a frequency ranging from 6% to 73%, and with autopsy data from stillborns accounting for the observed upper range (6, 10, 11). It is believed that increased intraluminal pressure in the duct due to initial respiratory efforts and/or crying at birth may cause rupture of the membrane, forming the one-way valve of Hasner.

Rarely, an obstruction at the valve of Hasner

may coexist with an obstruction at the entrance to the lacrimal sac, leading to the formation of a closed cystic space. If present at birth without associated inflammation of the distended lacrimal sac, this lesion is referred to as an amniotocele, as it is believed to contain sterile amniotic fluid (8). If the cyst is filled with epithelial debris and mucous generated by the nasolacrimal system, it is termed a mucocele. Either of these entities may become secondarily infected, as in our case.

Clinically, patients may present at birth or during the first few days of life with an asymptomatic medial canthal mass, epiphora (excessive tearing), dacryocystitis (inflammation of the lacrimal sac), periorbital cellulitis, sepsis, or, rarely, respiratory distress (2). In our case, the clinical findings of a medial canthal mass and a submucosal nasal cavity mass made congenital mucocele of the nasolacrimal duct the most likely differential diagnostic consideration.

CT plays an important role in the diagnosis of a nasolacrimal duct mucocele. The triad of a cystic medial canthal mass, dilatation of the nasolacrimal duct, and a contiguous submucosal nasal cavity mass on CT scan is diagnostic of a congenital nasolacrimal duct mucocele (1). CT is also helpful in differentiating a congenital nasolacrimal mucocele from other causes of a medial canthal mass in infants; these other cases include meningocele, encephalocele, dermoid, dacryocystitis, and some neoplastic processes (eg, hemangioma and lymphangioma). Magnetic resonance (MR) imaging may be more useful than CT for differentiating a nasolacrimal duct mucocele from some of these other conditions, which can pre-

sent as medial canthal masses. MR does not use ionizing radiation, is considered less invasive than CT, and has superior contrast resolution in comparison with CT. In addition, the ability to acquire images in any plane with MR is particularly useful for evaluating for possible encephaloceles in neonates. MR scanning was not performed in this case, because the combination of CT and clinical findings were considered diagnostic of a nasolacrimal duct mucocele.

The correct identification of these lesions is essential in planning appropriate therapy. Though manual compression of the lacrimal sac may result in decompression of the mucocele, in our case, probing the proximal (valve of Rosenmuller) and distal (valve of Hasner) nasolacrimal duct, combined with resecting the redundant mucosa at the valve of Hasner, resulted in a surgical cure of the lesion. Nasolacrimal duct probing, with relief of both proximal and distal obstructions, has been emphasized as the best initial treatment of nasolacrimal mucoceles presenting with respiratory distress (2).

In summary, a congenital mucocele of the nasolacrimal duct is an uncommon entity in the newborn. Effective therapy requires prompt recognition of the entity. CT plays a crucial role in diagnosis and differentiation of this entity from other conditions, which can present as medial

canthal masses. Surgical treatment directed at establishing patency of the nasolacrimal duct usually results in a complete cure of this disorder.

References

1. Rand P, Ball WS, Kulwin DR. Congenital nasolacrimal mucoceles: CT evaluation. *Radiology* 1989;173:691-694
2. Edmond JC, Keech RV. Congenital nasolacrimal sac mucocele associated with respiratory distress. *J Pediatr Ophthalmol Strabismus* 1991;28:287-289
3. Cibis GW, Spurney RO, Waeltermann J. Radiographic visualization of congenital lacrimal sac mucoceles. *Ann Ophthalmol* 1986;18:68-69
4. Weinstein GS, Biglan AW, Patterson JH. Congenital lacrimal sac mucoceles. *Am J Ophthalmol* 1982;94:106-110
5. Scott WE, Fabre JA, Ossoinig KC. Congenital mucocele of the lacrimal sac. *Arch Ophthalmol* 1979;97:1656-1658
6. Cassady JV. Developmental anatomy of nasolacrimal duct. *Arch Ophthalmol* 1952;47:141-158
7. Sevel D. Development and congenital abnormalities of the nasolacrimal apparatus. *J Pediatr Ophthalmol Strabismus* 1981;18:13-19
8. Jones LT, Wobig JL. *Surgery of the eyelids and lacrimal system*. New York: Aesculapius, 1976:157-173
9. Duke-Elder S, Cooke C. Normal and abnormal eye development: embryology. In: Duke-Elder S, ed. *System of ophthalmology*. Vol 3. St. Louis: Mosby, 1963:241-245
10. Guerry D III, Kendig EL Jr. Congenital impatency of the nasolacrimal duct. *Arch Ophthalmol* 1948;39:193-202
11. Korchmaros I, Sazlaay E, Fodor M, et al. Spontaneous opening rate of congenitally blocked nasolacrimal ducts. In: Yamaguchi M, ed. *Recent advances in the lacrimal system*. Tokyo: Asahi, 1980:30-35