

# CT in Penetrating Craniocervical Injury by Wooden Foreign Bodies: Reminder of a Pitfall

Lawrence E. Ginsberg,<sup>1</sup> Daniel W. Williams III,<sup>1</sup> and Vincent P. Mathews<sup>1</sup>

**Summary:** The authors report three cases of penetrating craniocervical injury by wooden foreign bodies, which were initially hypodense on CT and thought to be air. When these structures were scrutinized with higher window settings, they had a higher attenuation and a unique striated internal architecture which the authors propose may be specific to wood.

**Index terms:** Foreign bodies, CT assessment; Computed tomography, artifacts; Head, computed tomography; Neck, computed tomography

Numerous imaging modalities have been employed for the detection of retained foreign bodies, including plain film, ultrasound, computed tomography (CT), and xeroradiography (1–7). The utility of CT has been demonstrated, particularly if plain radiography is normal (6, 7). Wooden foreign bodies, however, present a vexing problem to the radiologist because of the potential for misinterpretation or failure to detect such foreign bodies on CT. Given the likelihood that such a miss will result in an abscess or neurovascular injury, we present three similar cases to remind radiologists of the possible appearance of wooden foreign bodies on CT.

## Case Reports

### Case 1

A 55-year-old tree trimmer was admitted after being struck in the left ear and neck by a limb while sawing a tree. He rapidly developed postauricular swelling, and hoarseness followed soon thereafter by dysphagia and odynophagia. Outside plain films showed soft-tissue swelling in the left side of the neck and soft-tissue air. Physical exam revealed a small laceration of the left conchal bowl and tragal notch and soft-tissue swelling. There was non-pulsatile left-sided neck swelling that was nontender and without crepitation or bruit. Fiberoptic laryngoscopy revealed left posterolateral oral and hypopharyngeal swelling obscuring the left pyriform fossa. There was no mucosal

laceration, cartilage exposure, or hematoma. The left vocal cord was immobile and laterally positioned. Esophagography showed deformity but no extravasation. Arteriography was performed to exclude vascular injury and revealed only anterior displacement of the proximal left internal carotid artery, presumably by hematoma. A noncontrast CT (Fig. 1A) demonstrated extensive pre- and infraauricular soft-tissue swelling and an associated central hypodensity interpreted as soft-tissue air. The parotid gland appeared disrupted. The “air” and swelling continued inferiorly and extended into the left carotid space. Extensive fullness was seen in the left posterolateral supraglottic larynx and there was evidence of left-sided vocal cord paralysis. As the history of auricular laceration was not known to the radiologist, the precise origin of the soft-tissue “air” was obscure. No source was identified on CT. There was no evidence of skull-base fracture.

Over the course of several days, the patient continued to complain of dysphagia and odynophagia, and on the fourth hospital day, pus was expressed from the left ear laceration. Conservative measures and drainage failed to resolve the purulent discharge, and the patient stated “there’s something in there.” To exclude retained foreign body, the patient was explored 7 days after admission. An 8.5 × 1.5 cm spike-shaped piece of wood was discovered (Fig. 1B) at a point 2.5 cm deep to the auricular laceration and extending intermedially, ending posteromedial to the left carotid space at the level of the hyoid bone. The patient did well postoperatively. The initial CT exam was reviewed and the structure initially interpreted as air had an attenuation coefficient of –284 HU. Upon closer scrutiny after widening the window and decreasing the level, the structure no longer appeared homogeneously hypodense but instead clearly had a striated internal architecture, and was separable from adjacent air (Fig. 1C).

### Case 2

A 26-year-old man was involved in a motor-vehicle accident in which his car struck a house. Upon examination, he had numerous facial lacerations and obvious deformity. CT was performed because of the likelihood of facial fractures and to exclude intracranial injury. The soft-tissue

Received May 28, 1992; accepted after revision August 28.

<sup>1</sup> Department of Radiology, Bowman Gray School of Medicine, Medical Center Blvd., Winston-Salem, NC 27157–1088. Address reprint requests to Lawrence E. Ginsberg, MD.

AJNR 14:892–895, Jul/Aug 1993 0195-6108/93/1404-0892 © American Society of Neuroradiology

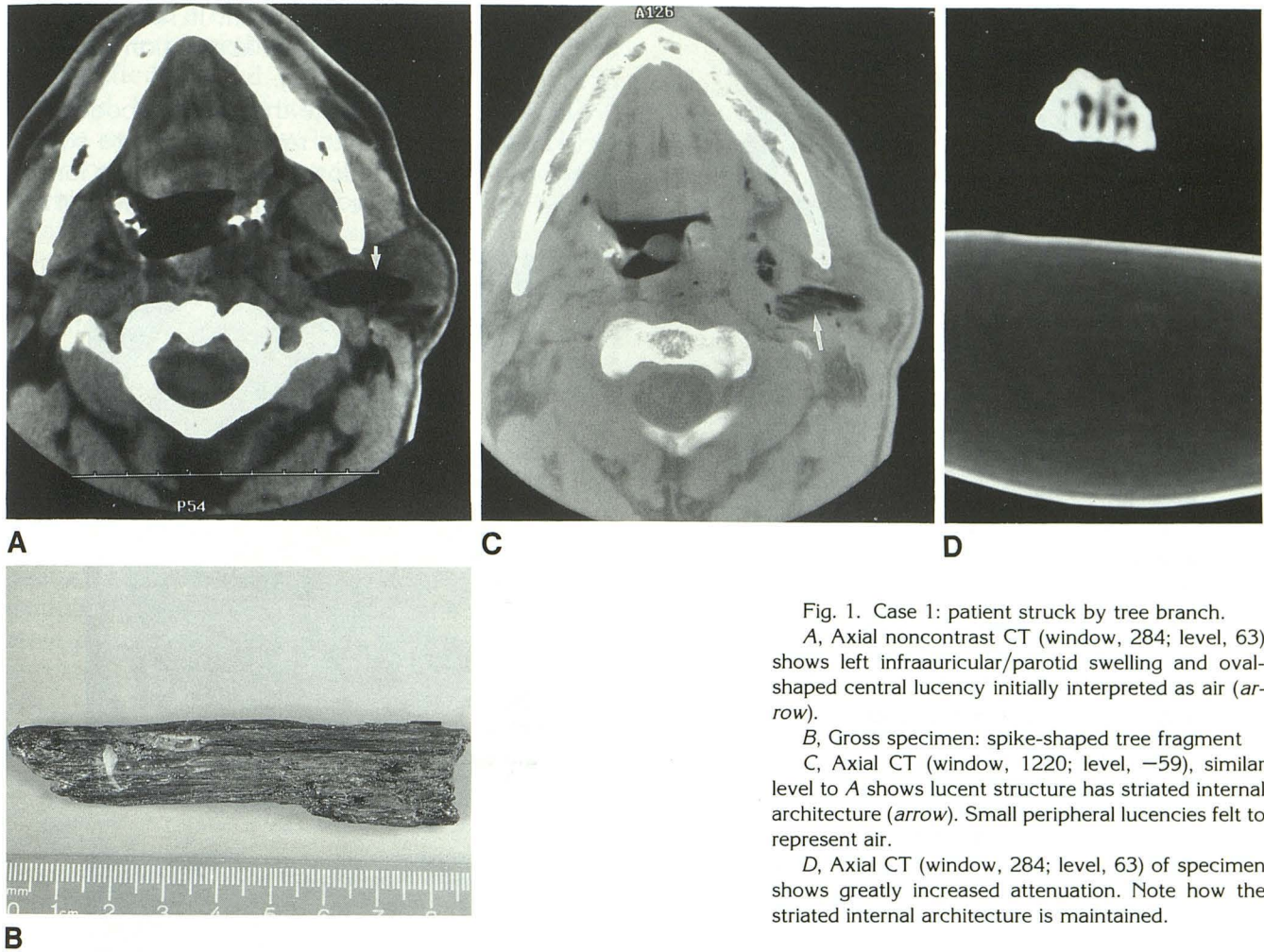


Fig. 1. Case 1: patient struck by tree branch.  
 A, Axial noncontrast CT (window, 284; level, 63) shows left infraauricular/parotid swelling and oval-shaped central lucency initially interpreted as air (arrow).  
 B, Gross specimen: spike-shaped tree fragment  
 C, Axial CT (window, 1220; level, -59), similar level to A shows lucent structure has striated internal architecture (arrow). Small peripheral lucencies felt to represent air.  
 D, Axial CT (window, 284; level, 63) of specimen shows greatly increased attenuation. Note how the striated internal architecture is maintained.

window images showed obvious bony disruption and what appeared to be air in the right infratemporal fossa (Fig. 2A). Bone windows demonstrated the facial fractures to better advantage, and showed that the low-density structures that mimicked air in the right nasal cavity and infratemporal fossa were not of appropriate attenuation for air but instead were higher density with a striated appearance (Fig. 2B). Surgical exploration yielded multiple wood fragments from these locations, the largest of which was 4 × 7 × 2 cm in dimension.

Case 3

While playing, a 13-year-old boy was struck on the head by a falling tree branch, which penetrated his left temporal squamosa. CT demonstrated the site of bone disruption, and soft-tissue windows showed intracranial air as well as hemorrhagic contusion in the left temporal lobe (Fig. 3A). However, on bone windows (not shown), the largest "air" pocket was actually higher in attenuation than air. Upon evacuation of the parenchymal hematoma, a small fragment of wood was removed. Despite surgical removal of this foreign body, the patient subsequently developed a mixed fungal and bacterial abscess within the surgical bed

(Fig. 3B). With further surgical intervention and antifungal and antibacterial therapy, the patient ultimately recovered.

Discussion

Imaging of wooden foreign bodies can be difficult (1-4, 6-9). Plain films are often normal (1, 2). Xeroradiography may be more sensitive, but the equipment is not widely available (2-4). Sonography has also been employed in the detection of wooden foreign bodies (4, 5). Beginning with the report by Healy in 1980 (8), and several others since, it has been known that wooden foreign bodies can be strikingly hypodense on computed tomography (9-14). Such a finding is often misinterpreted as air, as in our case 1. In fact, one report mistakenly interpreted wood as an abscess (11). Wood is an extremely porous substance, composed primarily of cellulose, which likely accounts for its low attenuation in the acute state. Certain woods have a tendency to change their CT attenuation in vivo over time as they absorb water, as demonstrated by Hansen

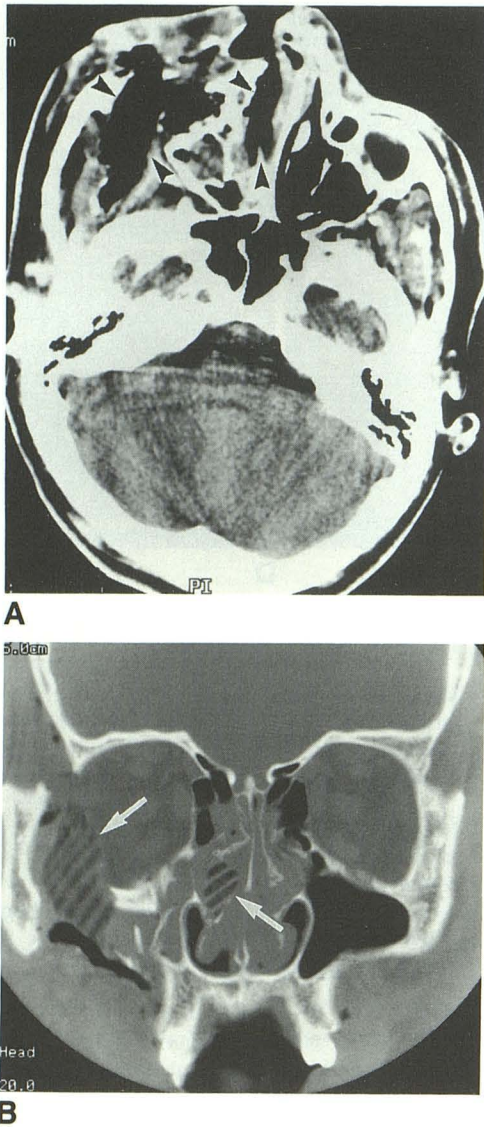


Fig. 2. Case 2: patient involved in motor-vehicle accident.

A, Axial noncontrast CT (window, 100; level, 40) shows disruption of the right maxillofacial region and what appears to be air in the right nasal cavity and right infratemporal fossa (*arrowheads*).

B, Coronal CT (window, 4178; level, 222) shows the structures in the right infratemporal fossa and right nasal cavity are not hypodense as air elsewhere but are higher density and possess a striated internal architecture (*arrows*). Wood fragments were recovered from both sites.

et al (9). In an experiment with various types of wood imaged in a dry state and after immersion in water, there was a marked increase in attenuation in certain woods as opposed to others, which presumably reflected differential water absorption (9). Retained wooden foreign bodies therefore may become more dense or even iso-dense depending on the time course of scanning. When the removed tree fragment from case 1

was imaged atop a water bath, it had a significantly higher density due to absorption of water or blood products (Fig. 1D).

Our cases demonstrate that when wooden objects initially thought to represent air are scrutinized with higher window settings, they no longer appear as hypodense as would be expected for

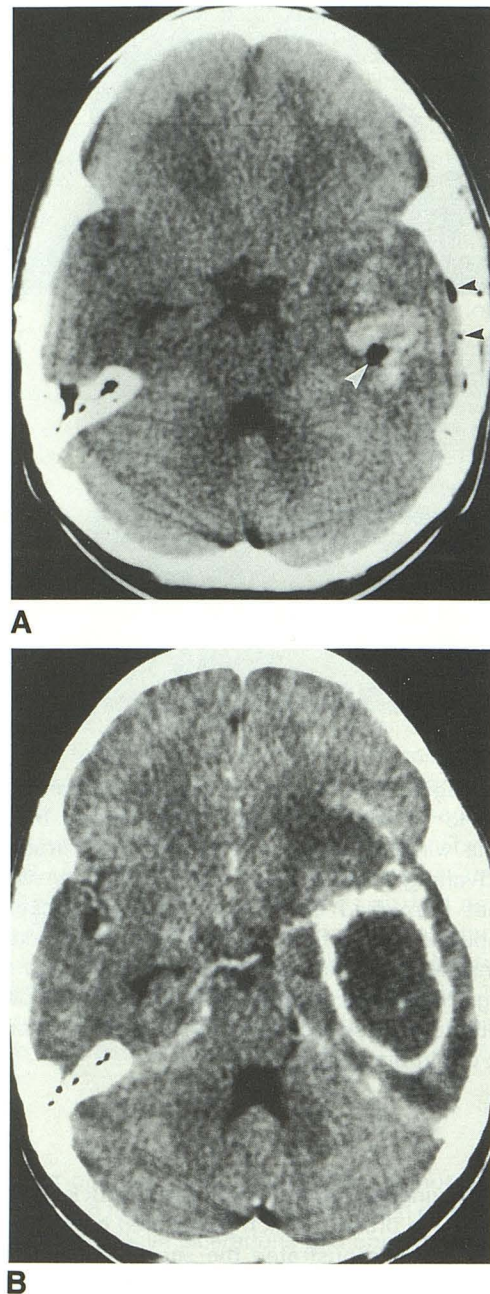


Fig. 3. Case 3: 13-year-old boy struck by tree branch.

A, Axial noncontrast CT (window, 100; level, 40) shows intracranial air near puncture site laterally (*black arrowheads*). Within temporal lobe hemorrhagic contusion, hypodense structure proved to be a wood fragment (*white arrowhead*).

B, Axial postcontrast CT (window, 100; level, 40) shows rim-enhancing left temporal lobe abscess.

air, but have a higher attenuation and a unique striated internal architecture that we propose may be specific for wood.

Wood, because of its soft, organic, vegetable nature and its porosity, is an excellent source of infection (14, 15) as seen in our case 3. Because of this high rate of infection, removal of such a retained foreign body is essential, particularly in critical locations such as the head and neck. Radiologists should be aware of the potential for misinterpretation of CT images. In questionable cases, the window and level should be adjusted to evaluate for internal heterogeneity, which may suggest the presence of a wooden foreign body. Examination of bone window images and Hounsfield numbers should also readily differentiate air and non-air hypodense material such as fat, or possibly wood. Being aware of the potential appearance of wood, we may also find CT useful in excluding small retained fragments in postoperative patients with persistent symptoms.

## References

1. Anderson MA, Newmeyer WL III, Kilgore ES Jr. Diagnosis and treatment of retained foreign bodies in the hand. *Am J Surg* 1982;144:63-67
2. Carneiro RS, Okunski WJ, Heffernan AH. Detection of a relatively radiolucent foreign body in the hand by xerography. *Plast Reconstr Surg* 1977;59:862-863
3. Woesner ME, Sanders I. Xeroradiography: a significant modality in the detection of nonmetallic foreign bodies in soft tissues. *AJR: Am J Roentgenol* 1972;115:630-640
4. De Flaviis L, Scaglione P, Del Bó P, Nessi R. Detection of foreign bodies in soft tissues: experimental comparison of ultrasonography and xeroradiography. *J Trauma* 1988;28:400-404
5. Gooding GAW, Hardiman T, Summers M, Stess R, Graf P, Grunfeld C. Sonography of the hand and foot in foreign body detection. *J Ultrasound Med* 1987;6:441-444
6. Firooznia H, Bjorkengren A, Hofstetter SR, Rafii M, Golimbu C. Computed tomography in localization of foreign bodies lodged in the extremities. *Comput Radiol* 1984;8:237-239
7. Bodne D, Quinn SF, Cochran CF. Imaging foreign glass and wooden bodies of the extremities with CT and MR. *J Comput Assist Tomogr* 1988;12:608-611
8. Healy JF. Case Report: computed tomography of a cranial wooden foreign body. *J Comput Assist Tomogr* 1980;4:555-556
9. Hansen JE, Gudeman SK, Holgate RC, Saunders RA. Penetrating intracranial wood wounds: clinical limitations of computerized tomography. *J Neurosurg* 1988;68:752-756
10. Kaiser MC, Rodesch G, Capesius P. CT in a case of intracranial penetration of a pencil: case report. *Neuroradiology* 1983;24:229-231
11. Lydiatt DD, Hollins RR, Moyer DJ, Davis LF. Problems in evaluation of penetrating foreign bodies with computed tomography scans: report of cases. *J Oral Maxillofac Surg* 1987;45:965-968
12. Jooma R, Bradshaw JR, Coakham HB. Computed tomography in penetrating cranial injury by a wooden foreign body. *Surg Neurol* 1984;21:236-238
13. Myllylä V, Pyhtinen J, Päivänsalo, Tervonen O, Koskela P. CT detection and location of intraorbital foreign bodies. *Fortschr Röntgenstr* 1987;146:639-643
14. Vandertop WP, de Vries WB, van Swieten J, Ramos LMP. Recurrent brain abscess due to an unexpected foreign body. *Surg Neurol* 1992;37:39-41
15. Miller CF, Brodkey JS, Colombi BJ. The danger of intracranial wood. *Surg Neurol* 1977;7:95-103