

Toxoplasma Encephalitis in Haitian Adults with Acquired Immunodeficiency Syndrome: A Clinical-Pathologic-CT Correlation

M. Judith Donovan Post¹
 Joseph C. Chan²
 George T. Hensley³
 Thomas A. Hoffman²
 Lee B. Moskowitz³
 Susan Lippmann⁴

The clinical data, histologic findings, and computed tomographic (CT) abnormalities in eight adult Haitians with toxoplasma encephalitis were analyzed retrospectively. Diagnosis was established by identification of *Toxoplasma gondii* on autopsy in five and brain biopsy in three specimens and subsequently confirmed by the immunoperoxidase method. All these patients, six of whom had been in the United States for 24 months or less, had severe idiopathic immunodeficiency syndrome. All were lymphopenic and six were on treatment for tuberculosis when the toxoplasma encephalitis developed. All patients were studied with CT when they developed an altered mental status and fever associated with seizures and/or focal neurologic deficits. Scans before treatment showed multiple intraparenchymal lesions in seven and a single lesion in the thalamus in one. Ring and/or nodular enhancement of the lesions was found in six and hypodense areas in two. Progression of abnormalities occurred on serial studies. These CT findings that were best shown on axial and coronal thin-section double-dose contrast studies were useful but not diagnostically pathognomonic. In patients with similar clinical presentation CT is recommended to identify focal areas of involvement and to guide brain biopsy or excision so that prompt medical therapy of this often lethal infection can be instituted.

Toxoplasma encephalitis is caused by the obligate intracellular protozoan, *Toxoplasma gondii*. Typically it occurs in those adults whose immune mechanism has been altered by underlying malignancy, collagen vascular disease, organ transplantation, corticosteroids, chemotherapy, and/or radiotherapy [1-8]. It usually is progressive and fatal but when detected early can be successfully treated by sulfadiazine and pyrimethamine [1-4, 8]. Early diagnosis is therefore critical. However, diagnosis can be difficult [2, 3, 9, 10], especially in those without a known immunodeficiency. Such was the case in eight Haitians who recently presented to our institution with toxoplasma encephalitis. The correct diagnosis was not suspected antemortem in four. Postmortem recognition was also delayed in two. Final diagnosis was established by using the immunoperoxidase method and electron microscopy to identify the *Toxoplasma gondii* organism.

Although CT has been used previously as a diagnostic aid in adults with toxoplasma encephalitis, the reports of its use have been limited and have usually involved only isolated case reports [8-15]. To further define the usefulness and specificity of CT in this condition, we retrospectively reviewed the CT scans of these eight Haitians. We correlated the CT findings with the clinical and pathologic data to establish criteria for earlier diagnosis and treatment of this potentially fatal disease. To our knowledge this is the largest reported series of patients with histologically proven toxoplasma encephalitis who have been studied by CT.

Materials and Methods

After an autopsy diagnosis of toxoplasma encephalitis in a 37-year-old Haitian male in

This article appears in the March/April 1983 issue of *AJNR* and the May 1983 issue of *AJR*.

Received August 3, 1982; accepted after revision October 20, 1982.

¹ Department of Radiology (R-130), Neuroradiology Section, University of Miami School of Medicine, P.O. Box 016960, Miami, FL 33101. Address reprint requests to M. J. D. Post.

² Department of Medicine, Infectious Disease Division, University of Miami School of Medicine, Miami, FL 33101.

³ Department of Pathology, University of Miami School of Medicine, Miami, FL 33101.

⁴ Department of Neurology, University of Miami School of Medicine, Miami, FL 33101.

AJNR 4:155-162, March/April 1983
 0195-6108/83/0402-0155 \$00.00
 © American Roentgen Ray Society

TABLE 1: CT Features of *Toxoplasma* Encephalitis before Surgical Intervention or Definitive Medical Therapy

	No. patients
Numbers and location of lesion:	
Single intraparenchymal:	
Thalamus	1
Subtotal	1
Multiple intraparenchymal:	
Cerebral hemispheres (deep and/or superficial)	7
Thalamus	4
Midbrain, pons, and/or medulla	2
Cerebellum	2
Subtotal	7
Total	8
Appearance on contrast studies:	
Focal contrast uptake:	
Single nodular enhancing lesion	1
Three nodular enhancing lesions	1
Single ring-enhancing lesion associated with two focal low-density lesions and with gyral enhancement	1
Multiple ring-enhancing lesions only	2
Multiple ring-enhancing lesions associated with multiple nodular enhancing lesions	1
Subtotal	6
No focal contrast uptake:	
Multiple low-density lesions only	1
Multiple low density lesions associated with diffuse gyral enhancement	1
Subtotal	2
Total	8
Edema:	
Mild	1
Moderate	3
Marked	3
Total	7
Mass effect:	
Mild	3
Moderate	2
Marked	3
Total	8
Hydrocephalus (2° partial outlet obstruction):	
Mild	2
Moderate	3
Total	5

1981, the department of pathology retrospectively reviewed the autopsy records of other Haitians who had died recently at the University of Miami/Jackson Memorial Medical Center and identified two Haitian refugees who were not previously known to have died from intracranial toxoplasmosis. While this review was being conducted five more Haitians were seen in our institution with this disease. This experience prompted a thorough review of the medical charts, histologic data, and radiographic studies of these eight Haitians. The clinical and pathologic aspects are being reported in detail elsewhere [16] (Hensley GT et al. and Chan JC, Moskowitz

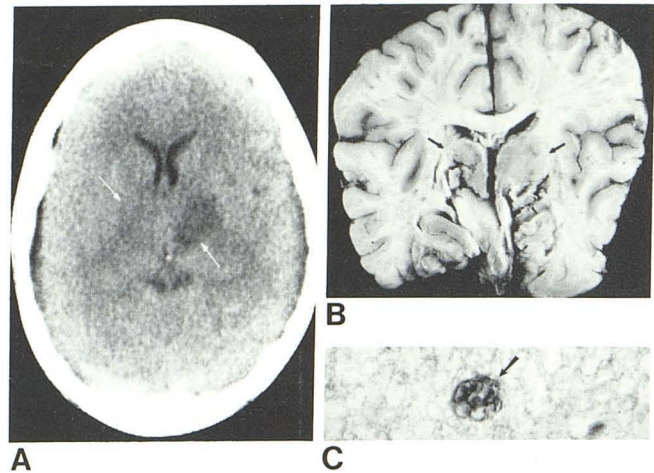


Fig. 1.—A, Plain CT. Bilateral low-density lesions that did not enhance in thalamus, basal ganglia, and internal capsule (arrows). B, Coronal sectioned brain confirms areas of necrotizing encephalitis (arrows) in thalamus and basal ganglia and shows new lesions in hypothalamus and gray matter of cortex bilaterally. C, Immunoperoxidase stain for *Toxoplasma gondii* shows grouped tachyzoites (arrow). (Magnification $\times 785$.)

LB, Olivella J, Hensley GT, Greenman RL, Hoffman TA, unpublished data).

The six male and two female patients were all native Haitians. Six had lived in the United States for 24 months or less. They were 21–48 years old (median, 26.5 years). Past history was pertinent in that five patients had disseminated tuberculosis and one patient had pulmonary tuberculosis within 7 months before the onset of toxoplasma encephalitis. All of these were being treated with anti-tuberculous medication when their neurologic symptoms developed. Other recent infections included esophageal candidiasis, cutaneous herpes, cryptococcal meningitis, and *Pneumocystis carinii* pneumonia. Six patients were described as thin, chronically ill-appearing, or malnourished.

These cases of toxoplasma encephalitis occurred between April 1980 and June 1982. Symptoms included fever of 38.3°C–40°C in eight, altered mental status (lethargy, confusion, and/or disorientation) in eight, seizures in three, focal neurologic deficits in four, and headache in four. In addition to neurologic symptoms, all patients had systemic complaints, such as malaise, generalized weakness, and myalgias.

Laboratory investigation revealed a peripheral lymphocytopenia in all. In the four patients who were tested at the onset of their encephalitis, all were anergic. Cerebrospinal fluid (CSF) analysis showed moderately elevated levels of total protein but normal glucose levels in every patient. A mild mononuclear pleocytosis was noted in only one. Cultures were negative for bacterial, mycobacterial, and fungal organisms. Toxoplasmosis serology performed in four was positive at titers less than or equal to 1:256.

The diagnosis in five patients who died within 15 days of being hospitalized for neurologic symptoms was established at autopsy. Three patients underwent brain biopsy (one open and two closed) and were treated with sulfadiazine and pyrimethamine. One of these patients who had signs of transtentorial herniation on admission markedly improved on therapy. Another who improved subsequently relapsed after completing a course of therapy, however, his clinical course has been complicated by cryptococcal meningitis and other superimposed infections. The third person with the most extensive involvement by CT remained comatose despite 4 weeks of definitive treatment and died.

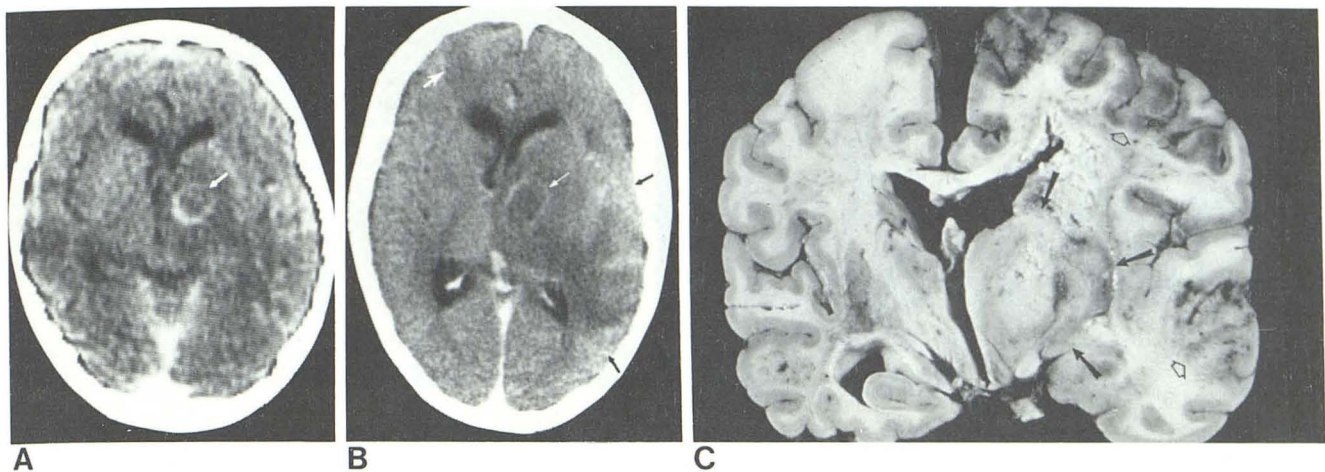


Fig. 2.—A, Ring-enhancing lesion in left thalamus, internal capsule, and basal ganglia (arrow) with mild mass effect and peripheral edema. B, 4 days later at slightly higher level. Larger ring-enhancing lesion (small white arrow) and edema. New area of hypodensity in right frontal lobe (large white arrow), new gyral enhancement (black arrows), and more marked compression of left lateral ventricle. C, Gross specimen confirms focal area of necrotizing encephalitis in left thalamus and basal ganglia (closed arrows). Involvement of corticomedullary junction in left frontal and temporal lobes (open arrows) corresponding to areas of gyral enhancement on CT.

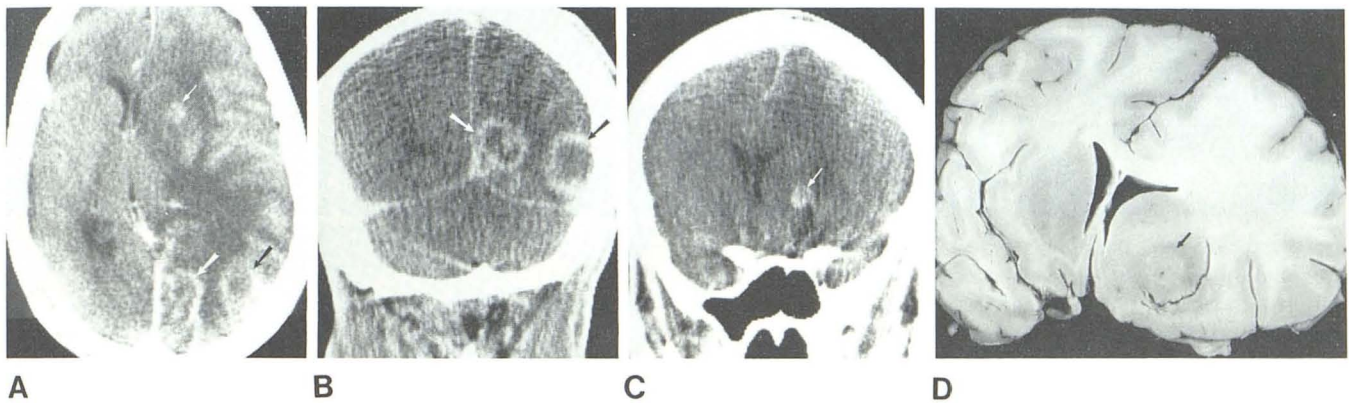


Fig. 3.—Second CT study with 79.3 g of iodine in axial (A) and coronal (B and C) views documented four lesions with hypodense centers and enhancing rims of variable thickness. Largest lesions were in left occipital lobe and at parietal-posterior temporal junction (long arrows); the smallest were in the left basal ganglia (small arrows, A and C) and left frontal lobe (not shown). Midline shift to right, left lateral ventricular compression, and extensive edema were also seen. Coronal sections of brain (e.g., D) showing left basal ganglionic mass (arrow) correlated well with corresponding coronal scan (C).

Observations

Computed Tomography

Plain and contrast CT scans of the brain were obtained in all patients, with the initial studies being obtained on a GE 8800 CT/T scanner in six and an EMI 1010 unit in two. Seven patients had serial studies. Initial enhanced scans were obtained using an intravenous drip of 150 ml of iohalamate meglumine U.S.P. 60% (42.3 g of iodine). However, double-dose contrast material was administered on follow-up scans in four, usually using 100 ml of Renograffin-76 (37g of iodine) via a bolus intravenous injection followed by the routine intravenous drip. Coronal scans with 5-mm-thick sections supplemented the axial projection in four patients.

The CT findings are summarized in table 1. CT scans obtained either initially or before treatment revealed a mul-

tiplicity of intraparenchymal lesions in seven cases. These lesions were usually bilateral (six of eight) and usually affected the cerebral hemispheres (seven of eight). Even the patient in whom CT showed a single nodule in the thalamus before medical therapy was subsequently recognized to have another intraparenchymal nodule. Edema and mass effect around these lesions were also noted. There seemed to be a predilection for the lesions to involve the basal ganglia, since this region was affected in seven of the eight patients. The corticomedullary junction in the cerebral hemispheres was also a common site of involvement. The thalamic region was found to be affected either before or shortly after initiation of therapy in six. The midbrain, pons, medulla, and cerebellum, however, were infrequently abnormal and were not the sole site of disease in any individual.

In only two patients did the lesions fail to show focal enhancement after contrast administration. Although one of these patients did have diffuse gyral staining, the primary

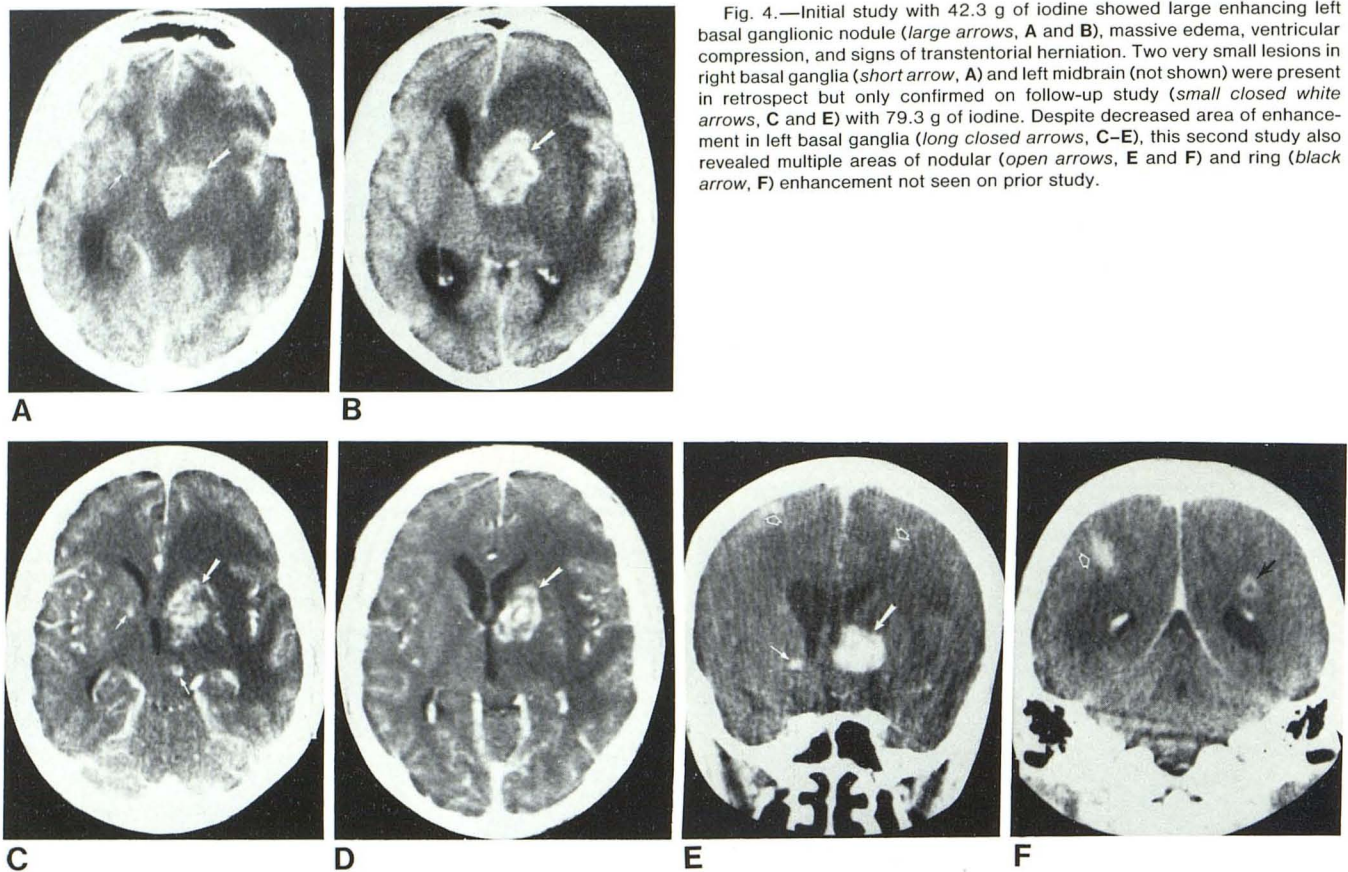


Fig. 4.—Initial study with 42.3 g of iodine showed large enhancing left basal ganglionic nodule (*large arrows, A and B*), massive edema, ventricular compression, and signs of transtentorial herniation. Two very small lesions in right basal ganglia (*short arrow, A*) and left midbrain (not shown) were present in retrospect but only confirmed on follow-up study (*small closed white arrows, C and E*) with 79.3 g of iodine. Despite decreased area of enhancement in left basal ganglia (*long closed arrows, C–E*), this second study also revealed multiple areas of nodular (*open arrows, E and F*) and ring (*black arrow, F*) enhancement not seen on prior study.

disease process in both individuals was characterized by low density areas in the brain parenchyma (fig. 1). Hypodense lesions seen best on plain scans were poorly defined and were difficult to appreciate. Although review using narrow window widths enhanced detection of these lesions, the extent of the process was definitely underestimated.

Most lesions focally enhanced. Patterns of focal contrast material uptake included ring enhancement and nodular enhancement, seen alone or in combination in six patients. Ring-enhancing lesions (figs. 2, 3, and 4F), ranging in size from under 0.5 cm to over 2.5 cm in width and in number from one to over 14, were hypodense centrally and usually had thin, smooth margins. Thick, irregular borders, however, were also seen. Usually isodense on plain scans, the margins enhanced to the greatest degree with double-dose contrast, making possible the identification of additional lesions. Enhancing nodules (figs. 4–6), ranging in size from under 0.5 cm to 3.3 cm in width and in number from one to 12, were smooth, sharply defined, and best appreciated on coronal view. Appearing usually isodense on plain scans, they enhanced homogeneously in most cases. Their density increased with time delay.

Neither the type of contrast uptake nor the density measurements of the low- or high-density lesions was found useful in differentiating toxoplasmosis from other intracranial infections. Similar absorption coefficients have been

found in the enhancing or hypodense lesions of other types of intracranial inflammation.

Despite this lack of specificity, however, CT confirmed the presence of multiple intracranial lesions, which was an integral part of recognizing this disease process, determined the amount of mass effect, the size of the ventricles, and the extent of edema. Lumbar punctures were averted in several patients when CT revealed considerable mass effect. Increasing obstructive hydrocephalus seen on CT in one patient resulted in the placement of a ventricular drain. In two individuals CT provided evidence of transtentorial herniation (fig. 4A); medical therapy was instituted to decrease the amount of edema shown on CT scan.

CT was particularly useful for localizing lesions for biopsy. Optimal visualization of lesions occurred using 5-mm-thick axial and coronal scans with double-dose contrast injection. Coronal views were more likely to demonstrate the extent of lesions (fig. 3B) and were used for precise localization of disease before neurosurgical intervention. Sagittal reconstructions also aided the biopsy of a deep lesion (fig. 6F).

Evolution of disease was observed in five untreated patients. Serial CT scans demonstrated progression of disease manifested by increases in the size and number of lesions, in the mass effect, and/or in the amount of edema. CT changes correlated well with worsening of the clinical picture in these patients.

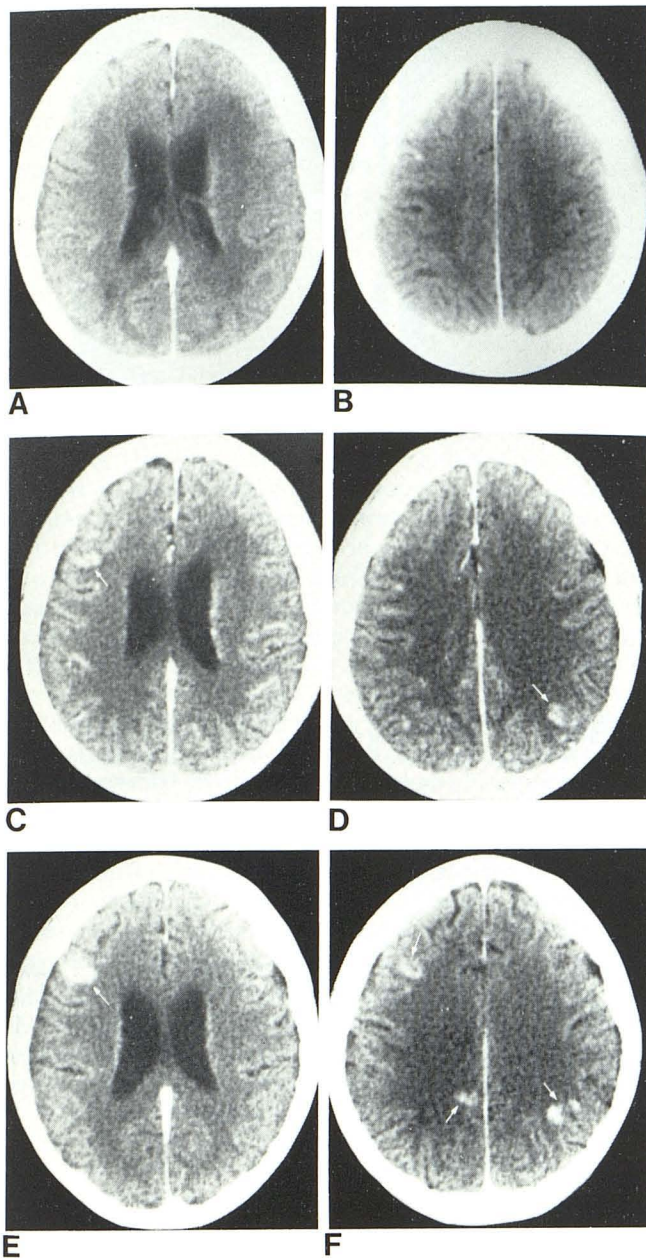


Fig. 5.—Immediate single-dose (A and B), immediate double-dose (C and D), and delayed double-dose (E and F) contrast scans show importance of CT technique in same patient as in fig. 4. On these selected CT images more lesions are visualized and other lesions become more apparent (arrows) as amount of contrast and time between injection and scanning are increased.

CT was also used to monitor changes during the course of sulfadiazine and pyrimethamine therapy. In one patient serial CT scans obtained during 4 weeks of treatment demonstrated a progressive decrease in the area of nodular enhancement in the thalamus (figs. 6A and 6B). After this course of therapy, the patient was clinically improved and was discharged. However, he returned 1 month later with recurrent symptoms, at which time CT revealed an increase

in the left thalamic nodular enhancement (fig. 6C). In addition, a second nodule was detected in the midbrain. Abnormal areas of enhancement were not detected by CT 5 weeks later (fig. 6D) after further therapy. However, 2½ weeks later, the fever and malaise recurred and CT showed reappearance of nodular enhancement in both locations (figs. 6E and 6F). These findings prompted biopsy.

The radiographic picture appeared to worsen in another patient on toxoplasmosis therapy despite marked clinical improvement (figs. 4 and 5). However, the initial and follow-up scans were obtained with considerably different techniques. The first scan, with routine contrast injection and with 1-cm-thick axial sections, showed three lesions: a large left basal ganglionic nodule and two very small right basal ganglionic and midbrain nodules (figs. 4A and 4B). After brain biopsy and 11 days of therapy a follow-up scan was obtained using a double-dose of contrast material with 5-mm-thick axial and coronal sections. This study revealed over 15 newly visualized areas of nodular or ring enhancement in the cerebral hemispheres, brainstem, and cerebellum (figs. 4C–4F). Despite these CT abnormalities, the patient's clinical status was considerably improved.

Two possibilities were considered to explain this apparent paradox. First, it was postulated that the clinical improvement was related to a considerable reduction in edema and mass effect noted on the follow-up scan. Secondly, it was suggested that the use of high-dose contrast material and thinner sections was more sensitive for detecting parenchymal lesions. It seemed unlikely that all the newly visualized areas of enhancement on the follow-up study represented true progression of disease. Only four lesions were seen on the next scan that was obtained 10 days later with a single dose of contrast material and 1-cm-thick sections. The scan was repeated 3 days later with immediate and delayed double-dose contrast material and 5-mm-thick axial and coronal sections. Eleven areas of abnormal enhancement were demonstrated, indicating that technique was responsible for the short time interval changes (fig. 5). In addition, it was apparent that the 1 hr delayed study was more effective in discerning lesions than the immediate contrast examination. The delayed scan made it possible to distinguish true enhancing lesions from normal vascular structures, since contrast material was no longer visible in blood vessels on the later scan. Furthermore, the delayed study detected five more lesions than the immediate study. In addition, three lesions were more apparent on the delayed scan than on the immediate study due to an increase in density and/or size of these lesions. Small lesions were best seen on the coronal double-dose delayed scan. In fact, several small lesions were not confirmed until the coronal views were obtained.

Angiography

Four patients had selective cerebral angiography; avascular mass lesions were noted in three. The major benefit of angiography was to identify draining cortical veins, which were used as landmarks for biopsy.

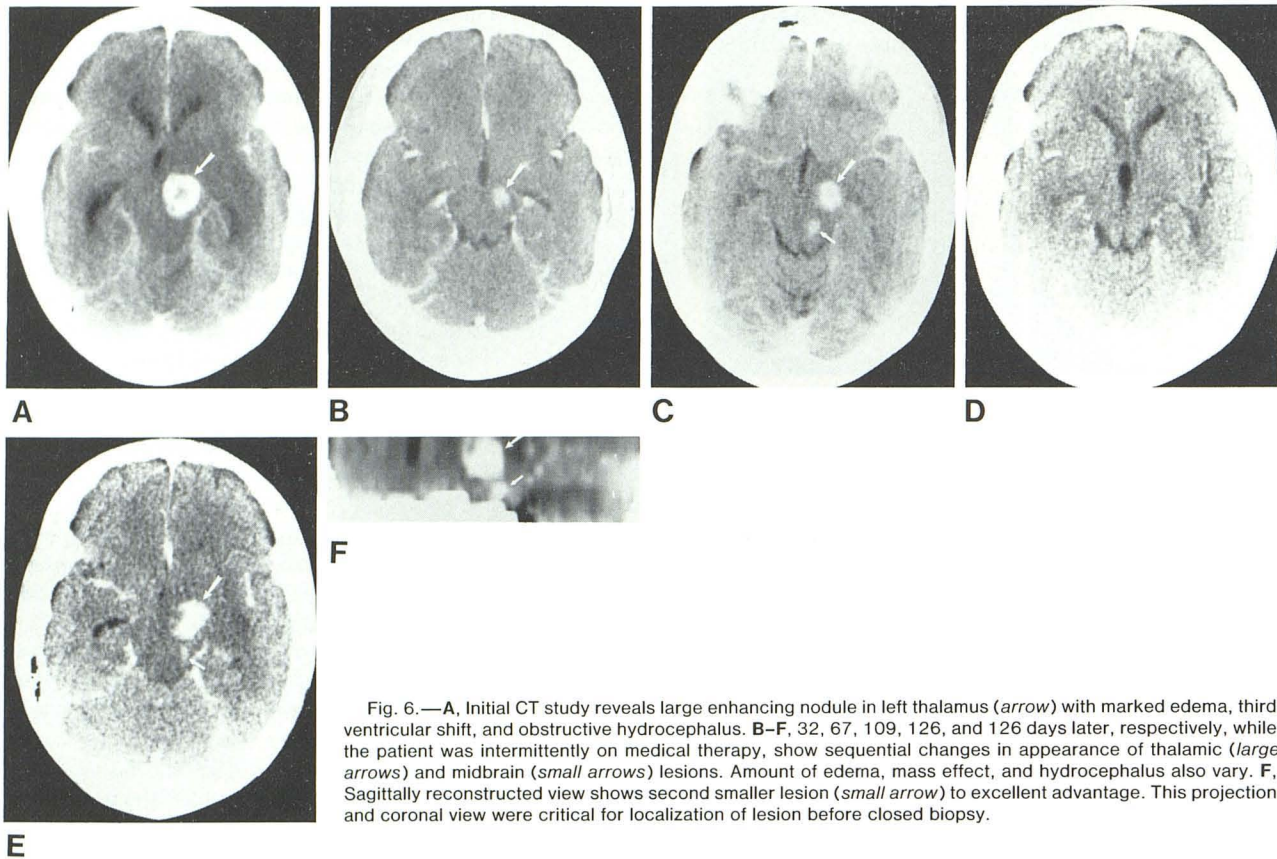


Fig. 6.—A, Initial CT study reveals large enhancing nodule in left thalamus (*arrow*) with marked edema, third ventricular shift, and obstructive hydrocephalus. B–F, 32, 67, 109, 126, and 126 days later, respectively, while the patient was intermittently on medical therapy, show sequential changes in appearance of thalamic (*large arrows*) and midbrain (*small arrows*) lesions. Amount of edema, mass effect, and hydrocephalus also vary. F, Sagittally reconstructed view shows second smaller lesion (*small arrow*) to excellent advantage. This projection and coronal view were critical for localization of lesion before closed biopsy.

Pathology

In the five patients who were autopsied, the histologic features were similar (figs. 1B, 1C, 2C and 3D). The lesions were all characterized by three distinct zones without capsule formation. The central zone was avascular, contained very few organisms, and had a solid and coagulated necrotic center. When vessels were seen, they were occluded by fibrin thrombi and were necrotic. In contrast, the intermediate zone was engorged with blood vessels, exhibited only spotty areas of necrosis, and contained numerous free extracellular and intracellular tachyzoites but rare encysted forms. Inflammatory reaction was intense. Venules were cuffed by lymphocytes, plasma cells, and macrophages. There was endothelial cell swelling and proliferation. In the peripheral zone, necrosis was rare, vascular lesions minimal, and free tachyzoites less numerous. More encysted forms were present, however.

Leptomeningitis, which was not frequent, was seen only in direct association with these areas of encephalitis. Arteritis of large vessels was absent. Vascular involvement was usually limited to occasional secondary small vessel thrombosis.

The time interval between CT scanning and autopsy was 2–6 days. Nevertheless, central nervous system involvement was more widespread than indicated on the CT scan. Newer lesions not seen on CT were found adjacent to those

more well developed areas of encephalitis that had been identified on CT. However, part of the discrepancy was also due to the failure of CT to correctly estimate the size of some of the original lesions. Focal areas of encephalitis that appeared hypodense on CT were particularly prone to be underestimated by CT with respect to size.

Discussion

Toxoplasma encephalitis is a disease that can be diagnostically elusive [2, 3, 8–11, 13]. Although worldwide in distribution [4, 5] *Toxoplasma gondii* usually causes subclinical and benign infections in the immunologically intact adult [7, 10, 17]. Self-limited lymphadenopathy and fever are the most common clinical manifestations of the disease [1, 2, 6]. Fulminant necrotizing encephalitis has been reported only in the immunocompromised host. Reactivation of latent intracranial toxoplasmosis in those with compromised cellular immunity causes diffuse encephalopathy, meningoencephalitis, and space-occupying lesions [3]. The neurologic symptoms and signs, however, are nonspecific and can be incorrectly attributed to the patient's underlying disease process [3, 8].

Laboratory tests are usually not specific either. As in our patients CSF and serologic tests may be abnormal, but not diagnostic [3]. *Toxoplasma gondii* is rarely isolated from the

CSF [1]. Even brain biopsy may not be revealing if the correct staining method is not used to identify this organism [10, 11, 13].

To help establish the diagnosis of toxoplasma encephalitis, conventional radiographic studies have been used. However, as in our cases, angiograms have been unremarkable or have demonstrated only nonspecific changes such as avascular masses [1, 3, 5, 15]. Radionuclide brain scans have shown nonspecific uptake of technetium [3, 5, 15].

Lately, CT has been added to the diagnostic armamentarium. In eight recent reports CT was used to evaluate a total of 10 patients [8–15]. The predominance of focal contrast enhancement over areas of low density, the multiplicity of lesions, the progression of disease, and the predilection for the cerebral hemispheres were similar to the CT findings in our study. However, basal ganglionic and thalamic involvement were demonstrated more frequently in our series. In contrast to congenital toxoplasmosis [18] calcification was not found on the CT scan of any untreated patient with acquired toxoplasma encephalitis [8–15]. In one of the patients reported in the literature, however, calcification was found on CT in the basal ganglia after treatment [11]. Calcifications not apparent on CT have also been described in the autopsy specimens of treated patients [12, 13]. We did not see calcifications on CT or autopsy in our group of patients, although the development of calcification may have been precluded by the short follow-up of our treated patients.

Neither the reports in the literature nor the results of our study indicate that patterns of changes seen on CT are pathognomonic for toxoplasma encephalitis. We found a tendency for CT to show multiple bilateral focally enhancing lesions located in the basal ganglia, corticomedullary junction, and thalamus with edema and mass effect and with rapid progression of abnormalities on sequential studies. In patients with fever and mental status change with an acquired idiopathic immune deficiency syndrome, these findings were highly suspicious for toxoplasmosis. However, we also found that neither the location of the lesions, the presence or absence of contrast enhancement, the pattern of contrast uptake, the thickness or smoothness of the rings, nor the absorption coefficient of the lesions on plain or contrast scans were specific for this disease.

Ring enhancing, nodular enhancing, and/or low-density lesions can be seen in other parasitic infections, in various fungal, mycobacterial, and viral diseases, and in bacterial cerebritis, pyogenic abscesses, and septic emboli [19–27]. Ring-enhancing lesions can also be seen in cerebral vascular occlusive disease, neoplastic disease, (particularly metastatic), and resolving hematomas [26]. However, in the latter group of patients differentiation can usually be made on clinical grounds. Differentiation of toxoplasmosis from other CNS infections can prove more difficult. Clinical and laboratory data can separate only some of these infections. Diagnostic difficulties are especially common in the immunocompromised host because of his susceptibility to a wide variety of opportunistic infections.

In our cases, CNS tuberculosis was the most difficult infection to exclude from the differential diagnosis because

of the recent history of tuberculosis in six of our eight patients, some of whom were noncompliant to their medications. On CT tuberculomas can resemble toxoplasmosis and can appear as single or multiple nodular and/or ring-enhancing lesions in the cerebral hemispheres and cerebellum with edema [19, 20]. The size of the rings can vary from micro to macro and they can have central contrast uptake or calcification in them [19, 20]. Meningeal enhancement can accompany these changes [19].

Tuberculous abscesses, a rare form of CNS tuberculosis, can also simulate toxoplasmosis. These lesions, which lack the giant cell and epithelioid granulomatous reaction of tuberculomas, usually occur in the cerebral hemispheres of patients in the third or fourth decades of life with a prior history of tuberculosis [21, 22]. They can be multiple and can occur in those with immune deficiency, malnutrition, and sudden onset of neurologic deficits [21, 22]. Our recent experience with a histologically proven case of tuberculous abscesses in a Haitian indicates that they can appear on CT as multiple supratentorial ring enhancing lesions. Definite diagnosis is not possible without biopsy.

Because of this lack of specificity, we believe that the role of CT in toxoplasmosis is to detect lesions, to determine their number, and to localize the most accessible ones for immediate biopsy or excision. The precise localization of these lesions by axial, coronal, and sagittally reconstructed scans is of critical importance because of the rapidly lethal nature of this disease in untreated patients.

Another role of CT is to demonstrate progression of disease and to monitor medical and surgical therapy. This use of CT has been suggested previously in the literature [10–12, 14]. We recommend, however, caution in the interpretation of follow-up scans. Similar techniques must be vigorously used before an accurate comparison of changes on CT can be made. Improvement in CT picture should not be claimed when different doses of contrast material and different slice thicknesses are used. Furthermore, a negative CT scan does not necessarily indicate complete eradication of the disease process as our one case attests. Possibly close time-interval, thin-section scans should be obtained since with this technique very small lesions have a greater chance of being detected.

The importance of CT technique in evaluating patients with toxoplasma encephalitis has not been emphasized in the literature. We found technique to be critical for the detection and localization of disease as well as for the satisfactory evaluation of patients on medical therapy. Our experience revealed that immediate double-dose contrast scans with 79.3 g of iodine were diagnostically superior to standard single-dose contrast scans with 42.3 g of iodine. More lesions were detected and faintly seen lesions were much better visualized.

Expanded high-iodine-dose scans have been used in those without contraindication to enhance the visualization of neoplasms and demyelinating disease [28–30]. Delayed high-dose contrast CT scans have also been used in these same diseases to detect additional lesions [29, 30]. Hayman et al. [29] suggested that the detection of those lesions with only a minimally impaired blood-brain barrier was made

possible by a prolonged exposure time to this high blood-iodine level. This time delay allowed more contrast material to accumulate in the interstices of the lesion.

Despite these reports the potential usefulness of these techniques in evaluating intracranial infection has not been appreciated. Our study suggests that the double-dose delayed contrast scan can be beneficial in evaluating and following patients with toxoplasma encephalitis. (From this early experience we predict that the delayed high-dose contrast scan may be the most beneficial study for evaluating patients with other types of intracranial infection too.) The added information this study provides directly affects surgical and medical management. We recommend that following a plain CT scan for optimal demonstration of low-density lesions that patients suspect for this disease have delayed double-dose thin-section contrast CT scans in multiple projections to enhance detection of lesions.

ACKNOWLEDGMENTS

We thank Tamera Johnson and Paula Garcia for manuscript preparation, Chris Fletcher and Chris Gargano for the illustrations, and Stacy Friden for technological assistance.

REFERENCES

1. Vietzke WM, Gelderman AH, Grimley PM, Valsamis MP. Toxoplasmosis complicating malignancy. Experience at the National Cancer Institute. *Cancer* 1968;21:816-827
2. Carey RM, Kimball AC, Armstrong D, Lieberman PH. Toxoplasmosis. Clinical experiences in a cancer hospital. *Am J Med* 1973;54:30-38
3. Townsend JJ, Wolinsky JS, Baringer JR, Johnson PC. Acquired toxoplasmosis. A neglected cause of treatable nervous system disease. *Arch Neurol* 1975;32:335-343
4. Frankel JK. Toxoplasmosis. In: Minckler J, ed. *Pathology of the nervous system*. New York: McGraw-Hill, 1968:2521-2538
5. Bamford CR. Toxoplasmosis mimicking a brain abscess in an adult with treated scleroderma. *Neurology (NY)* 1975;25:343-345
6. Krick JA, Remington JS. Current concepts in parasitology. Toxoplasmosis in the adult—an overview. *N Engl J Med* 1978;298:550-553
7. Remington JS. Toxoplasmosis in the adult. *Bull NY Acad Med* 1978;50:211-227
8. Green JA, Spruance SL, Cheson BD. Favorable outcome of central nervous system toxoplasmosis occurring in a patient with untreated Hodgkin's disease. *Cancer* 1980;45:808-810
9. Menges HW, Fischer E, Valavanis A, Schubiger O. Cerebral toxoplasmosis in the adult. *J Comput Assist Tomogr* 1979;3:413-416
10. Conley FK, Jenkins KA, Remington JS. *Toxoplasma gondii* infection of the central nervous system. *Hum Pathol* 1981;12:690-698
11. Emerson RG, Jardine DS, Milvenan ES, et al. Toxoplasmosis: a treatable neurologic disease in the immunologically compromised patient. *Pediatrics* 1981;67:653-655
12. McLeod R, Berry PF, Marshall WH Jr, Hunt SA, Rynning FW, Remington JS. Toxoplasmosis presenting as brain abscesses. Diagnosis by computerized tomography and cytology of aspirated purulent material. *Am J Med* 1979;67:711-714
13. Summerfield G. Demonstration of lesions of cerebral toxoplasmosis by computerized tomography. *Postgrad Med J* 1980;56:112-114
14. Enzmann DR, Brant-Zawadzki M, Britt RH. The CT appearance of central nervous system infection in immunocompromised patients. *AJNR* 1980;1:239-243
15. Wilson WB, Sharpe JA, Deck JHN. Cerebral blindness and oculomotor nerve palsies in toxoplasmosis. *Am J Ophthalmol* 1980;89:714-718
16. Hensley GT, Moskowitz LB, Tabei S, Kory P, Post MJ, Connely FK. Opportunistic infections and Kaposi's sarcoma among Haitians in the United States. *Morbid Mortal Weekly Rep* 1982;31:No. 26
17. Remington JS, Jacobs L, Kaufman HE. Toxoplasmosis in the adult. *N Engl J Med* 1969;262:180-186
18. Collins AT, Cromwell LD. Computed tomography in the evaluation of congenital cerebral toxoplasmosis. *J Comput Assist Tomogr* 1980;4:326-329
19. Whelan MA, Stern J. Intracranial tuberculoma. *Radiology* 1981;138:75-81
20. Welchman JM. Computerized tomography of intracranial tuberculomata. *Clin Radiol* 1979;30:567-573
21. Whitener DR. Tuberculous brain abscess. Report of a case and review of the literature. *Arch Neurol* 1978;35:148-155
22. Rab SM, Bhatti IH, Ghani A, Khan A. Tuberculous brain abscess. Case report. *J Neurosurg* 1975;43:490-494
23. Newton TH, Norman D, Alvord EC, Shaw CM. The CT scan in infectious disease of the CNS. In: Norman D, Korobkin N, Newton TH, eds. *Computed tomography*. San Francisco: University of California, 1977:719-740
24. Enzmann DR, Britt RH, Yeager AS. Experimental brain abscess evolution: computed tomographic and neuropathologic correlation. *Radiology* 1979;133:113-122
25. Britt RH, Enzmann DR, Yeager AS. Neuropathological and computerized tomographic findings in experimental brain abscess. *J Neurosurg* 1981;55:590-603
26. Coulam CM, Seshul M, Donaldson J. Intracranial ring lesions: can we differentiate by computed tomography? *Invest Radiol* 1980;15:103-112
27. Long JA Jr, Herdt JR, Di Chiro G, Cramer HR. Cerebral mass lesions in torulosis demonstrated by computed tomography. *J Comput Assist Tomogr* 1980;4:766-769
28. Davis JM, Davis KR, Newhouse J, Pfister RC. Expanded high iodine dose in computed cranial tomography: a preliminary report. *Radiology* 1979;131:373-380
29. Hayman LA, Evans RA, Hinck VC. Delayed high iodine dose contrast computed tomography. Cranial neoplasms. *Radiology* 1980;136:677-684
30. Vinuela FV, Fox AJ, Debrun GM, Feasby TE, Ebers GC. New perspectives in computed tomography of multiple sclerosis. *AJNR* 1982;3:277-281

Addendum

Since the time of our original study, four additional adult Haitians with acquired immunodeficiency syndrome have presented to our institution with toxoplasma encephalitis, diagnosed by brain biopsy (one patient) or autopsy (three). CT abnormalities were similar to those found in our first eight patients.