

Direct Thrombolytic Therapy for Superior Sagittal Sinus Thrombosis

Randall T. Higashida,¹ Edward Helmer,² Van V. Halbach,¹ and Grant B. Hieshima¹

Dural venous sinus thrombosis (DVST) in the neonatal period has a spectrum of clinical and radiologic findings. At the present time, the treatment for venous sinus thrombosis is mainly one of supportive therapy. In a patient with documented DVST, whose clinical status is deteriorating despite conventional supportive therapy, there may be a rationale for more aggressive therapy. We report a case of DVST that was successfully managed by direct puncture of the superior sagittal sinus and infusion of urokinase, resulting in clot lysis over 12 hr.

Case Report

The patient, a 3.7-kg male infant delivered at 42 weeks gestation, was in moderate respiratory distress at birth with an Apgar score of 6–7. At 8 hr of age, the infant began to exhibit right-sided focal twitching, which then progressed to generalized convulsions. Phenobarbital therapy, 80 mg (20 mg/kg), was begun at that time, but his seizure activity continued to increase. Because of the increase in seizure activity, Dilantin*, 50 mg (12 mg/kg), was given along with an additional bolus of phenobarbital (10 mg).

The phenobarbital blood level at 12 hr of age was 16.2 mg/ml (therapeutic level = 10–30 mg/ml). The Dilantin blood level at 12 hr of age was 8.6 mg/ml (therapeutic level = 10–20 mg/ml). The patient was maintained on a dose of phenobarbital of 10 mg twice a day and Dilantin 10 mg twice a day. Despite this therapy, the child became apneic and required intubation and ventilatory support. A lumbar puncture showed 3880 RBCs and 22 WBCs.

Electroencephalography (EEG) revealed bitemporal seizure activity. Cranial CT scan revealed bilateral periventricular hemorrhages associated with irregular scattered areas of low density in the subcortical hemispheric white matter (Fig. 1A). Cerebral arteriogram showed anomalous cortical venous drainage, poor filling of the sagittal sinus, and nonfilling of the dominant left transverse sinus. Dural sinus venogram was performed after direct percutaneous puncture of the superior sagittal sinus through the anterior fontanelle with a 21-gauge scalp vein needle (Fig. 1B). The venogram confirmed complete thrombosis of the left transverse sinus and poor venous drainage through

the right transverse sinus (Fig. 1C). After the diagnostic venograms and with the needle still remaining in the superior sagittal sinus, a continuous perfusion of urokinase (1000 IU/ml) was administered at 1 ml/hr for 12 hr. After infusion, a repeat venogram was performed; it showed the superior sagittal sinus and both transverse sinuses to be patent owing to lysis of clot (Fig. 1D). The patient did well clinically after the transvenous thrombolytic therapy. Seizure activity abated, and his seizure medication was gradually discontinued.

A follow-up CT scan 11 days later showed resolution of hemorrhage and decreasing mass effect (Fig. 1E). A repeat EEG revealed no specific abnormality. Clinical follow-up 6 months after the initial insult showed the child to be well neurologically and developmentally. CT scan at that time, however, showed some residual leukoencephalomalacia. At 1 and 3 years of age, the child remained neurologically intact with normal development.

Discussion

The diagnostic aspects of intracranial DVST (including its wide spectrum of clinical problems), as well as the CT, MR and angiographic findings of DVST, have been well-documented in the literature [1–12]. Treatment of patients with DVST usually consists of supportive therapy, sometimes in association with systemic anticoagulant therapy. This treatment regimen often suffices, with resultant complete or partial clinical recovery of the patient. In some instances, however, the patient continues to deteriorate [1, 3]. It is in this group of patients that the need for more aggressive local thrombolysis might be considered. A large number of reports are now available in the literature that describe both local and systemic thrombolytic therapy in a wide variety of cases [13–18]. To date, however, no case has been reported in which successful local thrombolysis of a dural venous sinus thrombosis is achieved in a neonate.

The most important factors in choosing to start thrombolytic therapy are (1) accurate patient selection, (2) choice and dosage of the specific thrombolytic agent, and (3) choice for route of administration of the thrombolytic agent. Patient

* Parke-Davis, Morris Plains, NJ.

Received November 4, 1988; revision requested December 19, 1988; revision received February 28, 1989; accepted March 6, 1989.

¹ Departments of Radiology and Neurosurgery, Neurointerventional Section, University of California, San Francisco, San Francisco, CA 94143-0628. Address reprint requests to R. T. Higashida, Department of Radiology, L352, Neurointerventional Section, University of California, San Francisco, San Francisco, CA 94143-0628.

² Department of Radiology, Kaiser Permanente Medical Center, 1505 N. Edgemont Ave., Los Angeles, CA 90027.

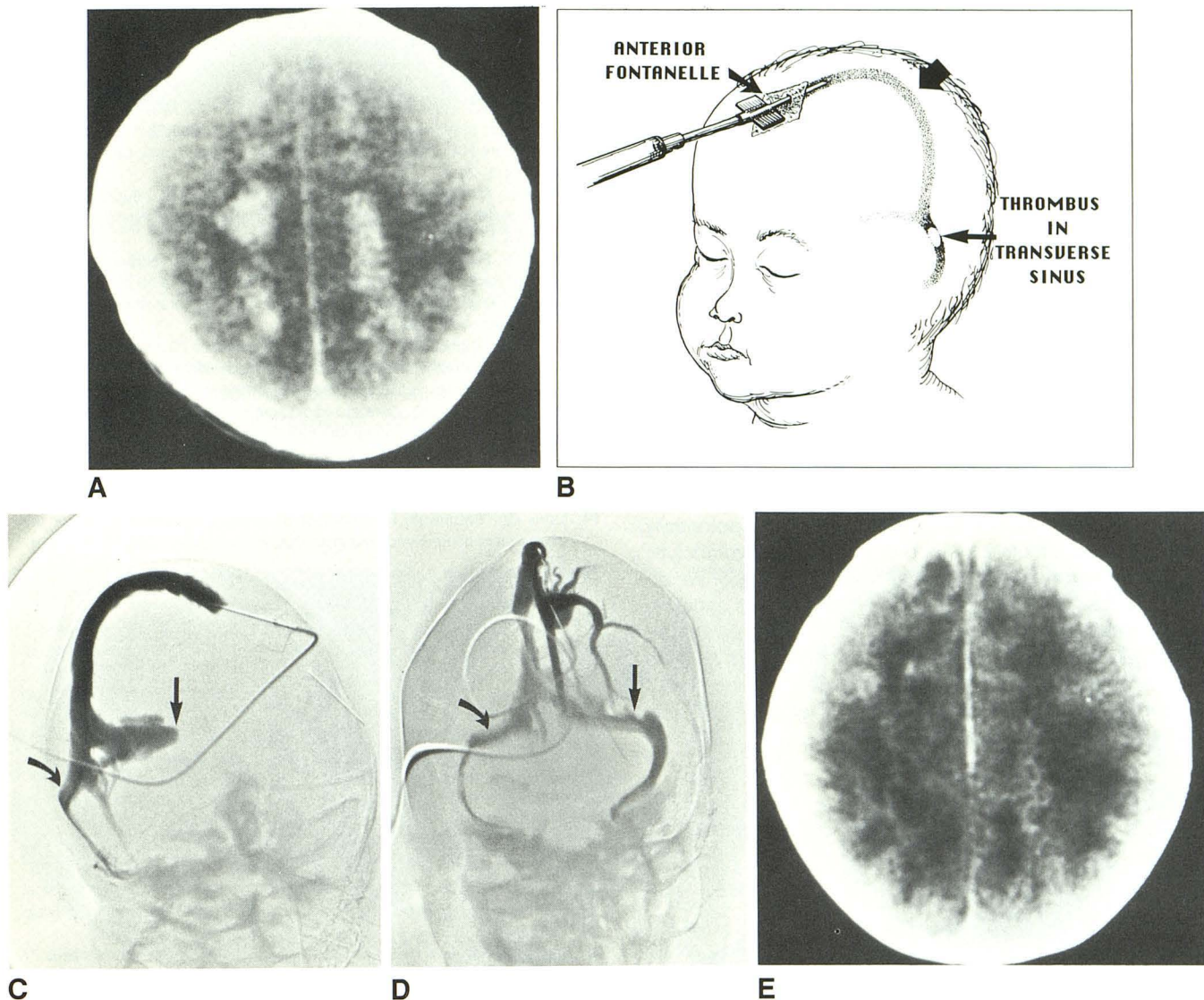


Fig. 1.—A, CT head scan over high cortical region shows hemorrhages in both hemispheres.

B, Direct puncture of superior sagittal sinus with a 21-gauge scalp vein needle through anterior fontanelle. Thick arrow (in middle) points to superior sagittal sinus.

C, Sinus venogram shows complete occlusion of dominant left transverse sinus (straight arrow). Drainage is poor through right transverse sinus (curved arrow).

D, After direct infusion of urokinase into the sagittal sinus, clot lysis occurs and both left (straight arrow) and right (curved arrow) transverse sinuses are patent.

E, Follow-up CT scan shows resolution of hematoma and resolving edema.

selection, in our case, was based on the patient's continued clinical deterioration. Because of persistent seizure activity from hemorrhagic venous infarcts despite adequate anticonvulsive therapy and because of the already marked CT changes directly resulting from his venous sinus thrombosis, we thought that more aggressive thrombolytic therapy was warranted to forestall further progressive neurologic deterioration.

Urokinase was chosen as the thrombolytic agent, partly because fewer systemic allergic reactions occur with urokinase than with streptokinase, and partly to avoid the necessity of giving a large initial loading dose of thrombolytic agent (as

is sometimes necessary with streptokinase) [14–24]. In regards to dose, however, neither systemic nor local dose/response curves were available for administration of urokinase in children. Having used local intraarterial perfusion doses of 20,000 UL/hr in adults, we estimated a weight-adjusted dose for this 3.7 kg infant. Considering the patient's weight to be approximately 1/20 of the average adult weight, we chose a perfusion dose of 1000 UL/hr. In regards to the route of administration for the thrombolytic agent, we considered both systemic perfusion and local intraarterial perfusion to be contraindicated because of the bilateral intracerebral hemorrhage. We chose the direct transvenous sinus route to

avoid direct local perfusion of the areas of intracerebral hemorrhage. Because of the slow rate of urokinase infusion (1 ml/hr) and the patency of the nondominant transverse sinus (which allowed antegrade flow), we considered the superior sagittal sinus to be the preferred site for infusion. Also, because of the very rapid systemic inactivation of urokinase, we believed that the systemic concentration of the thrombolytic agent would remain very low. In addition, in the neonate, direct percutaneous puncture of the sagittal sinus was an especially convenient route owing to the patency of the anterior fontanelle. With functional closure of the fontanelle in the child and adult, a surgical osteotomy or burr hole would be necessary to gain access to the sagittal sinus.

In the future, newer types of catheters and guidewires may allow catheterization of and access to distant intravascular sites. Then, we may be able to reach the site of dural venous sinus occlusion directly through a retrograde venous catheterization via the jugular vein, and then directly into either the transverse sinus or sagittal sinus.

Our experience in this single case reveals a potentially rapid, safe, and effective method of performing thrombolytic therapy of intracranial dural venous sinus thrombosis. We do not, of course, suggest this therapy for all patients suffering from venous sinus thrombosis; many of these patients will recover spontaneously. We should select only those patients who are failing standard therapy. In addition, long-term data are necessary to assess properly the clinical efficacy of this treatment.

ACKNOWLEDGMENT

We thank Joel Schechter for the medical illustration.

REFERENCES

- Bailey OT, Hass EM. Dural sinus thrombosis in early life, clinical manifestations and extent of brain injury in acute sinus thrombosis. *J Pediatr* **1937**;11:755-771
- Barnes BD, Brant-Zawadzki M, Mintzer W. Digital subtraction angiography in the diagnosis of superior sagittal sinus thrombosis. *Neurology* **1983**;33:508-512
- Bousser MG, Chiras J, Bories J, Castaigne P. Cerebral venous thrombosis. A review of 38 cases. *Stroke* **1985**;16(2):199-213
- Castaigne P, Laplane D, Bousser MG. Superior sagittal sinus thrombosis. *Arch Neurol* **1977**;34:788-789
- Ford K, Sarwar M. Computed tomography of dural sinus thrombosis. *AJNR* **1981**;2:539-543
- Hanigan WC, Rossi LJ, McLean JM, Wright RM. MRI of cerebral vein thrombosis in infancy: a case report. *Neurology* **1986**;36:1354-1356
- Krayenbuhl HA. Cerebral venous and sinus thrombosis. *Clin Neurosurg* **1967**;14:1-24
- Patronas NJ, Duda EE, Mirfakhraee M, Wallmann RL. Superior sagittal sinus thrombosis diagnosed by computed tomography. *Surg Neurol* **1981**;15:11-14
- Purvin V, Dunn DW, Edwards M. MRI and cerebral venous thrombosis. *Comput Radiol* **1987**;11(2):75-79
- Rao KC, Knipp HC, Wagner EJ. CT findings in cerebral sinus and venous thrombosis. *AJNR* **1981**;2:539-543
- Sagall HD, Ahmad J, McComb JG, Zee CH, Becker TS, Han JS. Computed tomographic observations pertinent to intracranial venous thrombotic and occlusive disease in childhood. *Radiology* **1982**;143:441-449
- Vines FS, Davis DO. Clinical radiological correlation in cerebral venous occlusive disease. *Radiology* **1971**;98:9-22
- Scott JA, Pascuzzi RM, Hall PV, Becker GJ. Treatment of dural sinus thrombosis with local urokinase infusion. Case report. *J Neurosurg* **1988**;68:284-287
- Laffel GL, Braunwald E. Thrombolytic therapy: a new strategy for the treatment of acute myocardial infarction. *N Engl J Med* **1984**;311(11):710-776
- Meyer JS, Gilroy J, Barnhart MI. Anticoagulant plus streptokinase therapy in progressive stroke. *JAMA* **1964**;189:373-377
- Nenci CE, Gesele P, Taranelli M, Agnelli G, Signorini E. Thrombolytic therapy for thromboembolism of vertebrobasilar artery. *Angiography* **1983**;34(9):561-571
- Verstraete M. Biochemical and clinical aspects of thrombolysis. *Semin Hematol* **1978**;15:35-42
- Zaumer H, Hacke W, Ringelstein EB. Local intraarterial thrombolysis in vertebrobasilar thromboembolic disease. *AJNR* **1983**;4:401-404
- Porter JM, Seaman AJ, Common HH. Comparison of heparin and streptokinase in the treatment of venous thrombosis. *Am Surg* **1975**;40(a):511-519
- Bell WR. Thrombolytic therapy: a comparison between urokinase and streptokinase. *Semin Thromb Hemost* **1975**;2:1-13
- Brogden LN, Speight TM, Avery GS. Streptokinase. A review of its clinical pharmacology, mechanism of action, and therapeutic use. *Drug* **1973**;5:357-365
- Fratantoni JC, Ness P, Simon TL. Thrombolytic therapy. Current status. *N Engl J Med* **1975**;293:1073-1078
- Lawson M, Bottino JC, Hartubise MR, McCredie K. The use of urokinase to restore the patency of occluded central venous catheters. *Am J IV Ther Clin Nutr* **1982**;9(9):29-32
- Marder VJ. The use of thrombolytic agents: choice of patient, drug administration, laboratory monitoring. *Ann Intern Med* **1979**;90(5):802-808