

Traumatic Pseudoaneurysm of Ascending Cervical Artery in Neurofibromatosis: Complication of Chiropractic Manipulation

B. Richard Lenington,^{1,2} D. Wayne Laster,
Dixon M. Moody, and Marshall R. Ball

The association of chiropractic manipulation with injuries of the internal carotid and vertebral arteries has been reported [1-9]. We describe a case of chiropractic manipulation injury of the thyrocervical trunk resulting in false aneurysm formation.

Case Report

A 53-year-old white man with neurofibromatosis suffered neck discomfort after manual labor. He was treated by a chiropractor three times in 1 week. During the third manipulation, the patient experienced a "crunching" sensation in his lower left neck. Progressive swelling and pain in this region occurred over the next

several hours. Physical examination revealed a continuous bruit over a large left neck mass, numerous café au lait spots, and cutaneous neurofibromas.

Radiographs of the cervical spine demonstrated marked bone dysplasia and kyphosis consistent with neurofibromatosis (fig. 1A). A fracture of the left transverse process of T1 was also present.

Angiography disclosed branches of the left external carotid artery supplying the superior part of the mass, a cervical neurofibroma (fig. 1B). Left subclavian artery injection demonstrated an enlarged and irregular thyrocervical trunk with contrast material filling a 5 × 6 cm false aneurysm within a large cervical neurofibroma (fig. 1C). Surgery confirmed the angiographic diagnosis of false aneurysm formation within the inferior part of the neurofibroma.

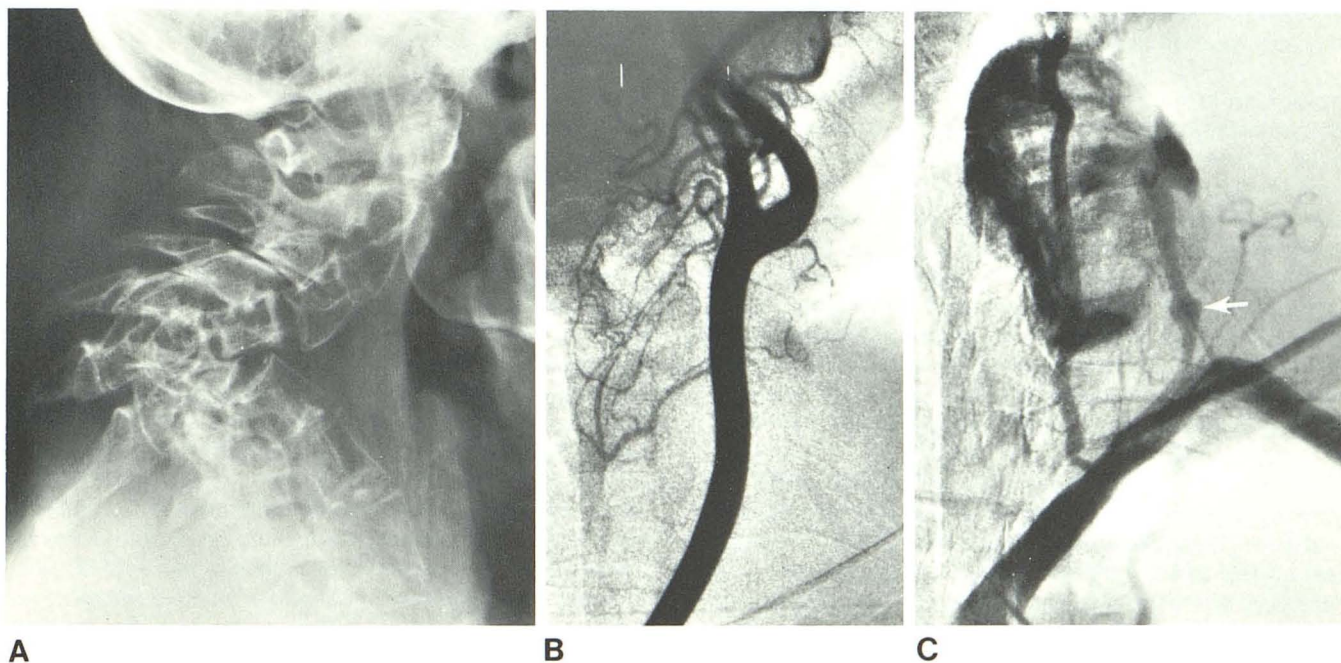


Fig. 1.—A, Lateral cervical spine. Marked kyphotic deformity and dysplasia. B, Left common carotid arteriogram. External carotid branches supply superior aspect of tumor. C, Left subclavian injection. False aneurysm fills from enlarged and irregular thyrocervical trunk (arrow).

Received October 16, 1979; accepted after revision December 19, 1979.

Marshall R. Ball is a James Picker Advanced Fellow in Radiology.

¹ All authors: Department of Radiology, Section of Neuroradiology, Bowman Gray School of Medicine, Winston-Salem, NC 27103. Address reprint requests to D. W. Laster.

² Present address: Department of Radiology, Coliseum Park Hospital, Macon, GA 31201.

Discussion

The mechanism of injury in this case is speculative. We propose that the thyrocervical trunk was subject to the stress of cervical manipulation because it was enlarged and tethered to the neurofibroma by tumor vasculature. Stretching of the tethered vessel during cervical manipulation could have resulted in intimal dissection with false aneurysm formation similar to the mechanism of injury in traumatic dissection of the high extracranial internal carotid artery and vertebral artery in chiropractic manipulation.

REFERENCES

1. Pratt-Thomas HR, Berger KE. Cerebellar and spinal injuries after chiropractic manipulation. *JAMA* **1947**;133:600-603
2. Ford FR, Clark D. Thrombosis of the basilar artery with softening in the cerebellum and brainstem due to manipulation of the neck. *Bull Johns Hopkins Hosp* **1956**;98:37-42
3. Green D, Joynt RJ. Vascular accidents to the brainstem associated with neck manipulation. *JAMA* **1959**;170:522-524
4. Mehalic T, Farhat SM. Vertebral artery injury from chiropractic manipulation of the neck. *Surg Neurol* **1974**;2:125-129
5. Mueller S, Sahs AL. Brainstem dysfunction related to cervical manipulation: report of three cases. *Neurology (Minneapolis)* **1976**;26:547-550
6. Easton JD, Sherman DG. Cervical manipulation and stroke. *Stroke* **1977**;8:594-597
7. Davidson KC, Weiford EC, Dixon GD. Traumatic vertebral artery pseudoaneurysm following chiropractic manipulation. *Radiology* **1975**;115:651-662
8. Beatty RA. Dissecting hematoma of the internal carotid artery following chiropractic cervical manipulation. *J Trauma* **1977**;17:248-249
9. Miller RG, Burton R. Stroke following chiropractic manipulation of the spine. *JAMA* **1974**;229:189-190