

# MR Imaging in Progressive Multifocal Leukoencephalopathy

Marie-Hélène Guilleux<sup>1</sup>  
Robert E. Steiner<sup>2</sup>  
Ian R. Young<sup>3</sup>

The MR imaging appearance of progressive multifocal leukoencephalopathy is described in four cases that were confirmed by brain biopsy. Characteristic aspects are long T1 and long T2 lesions limited to white matter. At first the lesions are round or oval, then confluent and large. There is no mass effect. The involvement is most often asymmetric and distant from the periventricular region. The differential diagnosis includes other diseases affecting white matter: demyelination, infarction, infection, and tumors.

Progressive multifocal leukoencephalopathy (PML) is a viral demyelinating disease of the central nervous system that primarily affects immunocompromised hosts. The ability of MR imaging to detect white-matter abnormalities is now well known [1–4]. Four pathologically proven cases of PML were reviewed to assess the MR appearance and to compare that with the CT features.

## Subjects and Methods

The clinical features and CT and MR scans of four patients in whom PML was diagnosed on pathologic study were reviewed. MR was performed with the approval of the Research Ethics Committee of the Royal Postgraduate Medical School, following the guidelines published by the National Radiological Protection Board [5]. The patients were examined on a Picker prototype MR system operating at 0.15 T, as previously described [6]. The sequences used included spin-echo (SE), with a repetition time (TR) 1580 ms and echo time (TE) 80 ms (SE 1580/80), and inversion-recovery (IR) with a repetition time (TR) 1500 ms, inversion time (TI) 500 ms, and echo time (TE) 44 ms (IR 1500/500/44).

## Results

### Case 1

A 62-year-old woman was admitted for assessment of a 4-month history of left hemiparesis. She was on treatment with steroids for fibrosing alveolitis. CT showed multifocal low-density lesions in the right frontal and parietal white matter and adjacent to the right anterior ventricular horn, which did not display contrast enhancement (Fig. 1). MR showed multiple confluent areas of increased signal intensity in the right hemisphere (frontal, parietal, and occipital white matter) using the SE 1580/80 sequence (Fig. 1). There was no mass effect. A right frontal biopsy was performed and the pathologic study revealed lesions consistent with PML.

### Case 2

A 46-year-old man with a 1-year history of chronic lymphocytic leukemia presented with a 3-month history of adverse seizures, left hemiparesis, left side neglect, gait apraxia, dressing apraxia, left homonymous hemianopia, and drowsiness. CT revealed low-density lesions in the white matter (both frontal lobes and right parietal lobe) that did not enhance. On SE 1580/80 sequences, MR showed asymmetric areas of increased signal intensity in both hemi-

Received March 3, 1986; accepted after revision May 20, 1986.

This work was supported in part by the Department of Health and Social Security, and the Medical Research Council, United Kingdom.

<sup>1</sup> Service de Radiologie Pr Delorme, Hôpital Pellegrin, 33076 Bordeaux Cedex, France. Address reprint requests to M. H. Guilleux.

<sup>2</sup> Department of Diagnostic Radiology, Royal Postgraduate Medical School, Hammersmith Hospital, Ducane Road, London W12 OHS, England.

<sup>3</sup> Hirst Research Centre, Wembley, Middlesex, HA9 7PR, England.

*AJNR* 7:1033–1035, November/December 1986  
0195–6108/86/0706–1033

© American Society of Neuroradiology

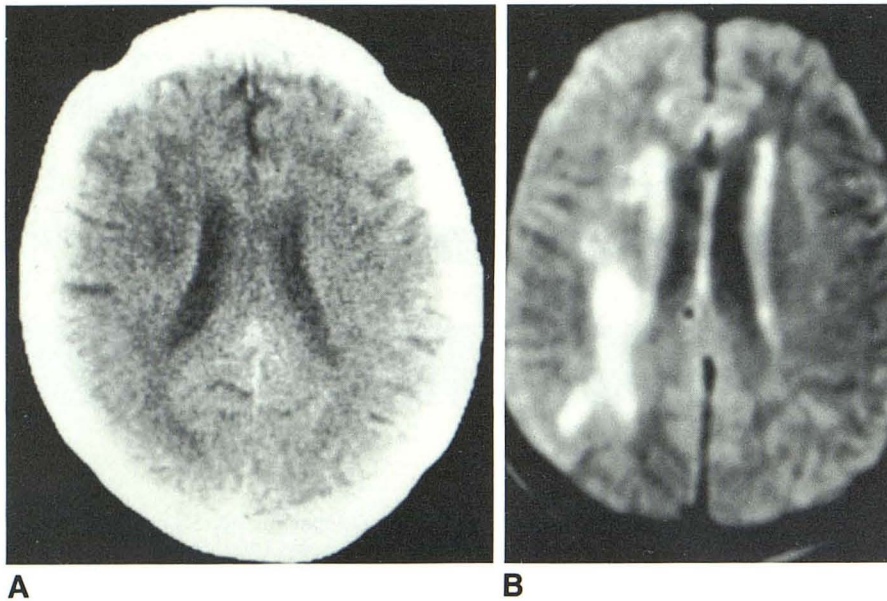


Fig. 1.—Case 1. **A**, CT shows discrete low-density lesions in right parietal white matter. **B**, MR (SE 1580/80) shows multiple confluent lesions in right frontal and parietal white matter.

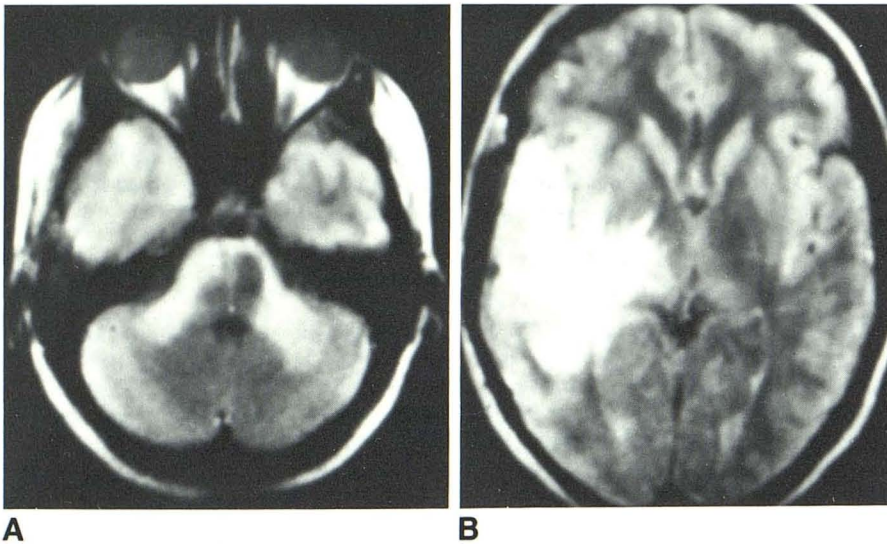


Fig. 2.—Case 4. **A**, MR (SE 1580/80) shows increased-signal-intensity lesions in cerebellar peduncles and right temporal white matter. **B**, Increased-signal-intensity areas in right parietal white matter and right internal and external capsules.

spheres; there were two large lesions in the right frontal and right parietal white matter, and smaller lesions in the right internal capsule and left frontal white matter. On IR 1500/500/44 sequences, the lesions appeared as areas of decreased signal intensity in the same topography. No mass effect was noted. A right frontal biopsy was performed and the pathologic examination showed typical features of PML.

#### Case 3

A 47-year-old woman developed left hemiplegia, pseudobulbar palsy, cerebellar ataxia, and disorientation over a 5-month period. CT showed multifocal and bilateral low-density lesions in the white matter; there was a moderate and homogeneous contrast enhancement at the periphery of a right parietal lesion. On MR (SE 1580/80), the lesions appeared as areas of increased signal intensity in frontal and parietal white matter (both sides), in right internal and external cap-

sules, and in right occipital white matter. No mass effect was observed. The pathologic examination, after a right frontal biopsy, showed definite PML.

#### Case 4

A 34-year-old woman presented with a 6-month history of right-sided headaches and left hand and leg paresthesia. She subsequently developed unsteady gait, nystagmus, drowsiness, and slurred speech. CT showed low-density lesions in right parietal and temporal lobes without contrast enhancement or mass effect (Fig. 2). On SE 1580/80 sequences, MR showed areas of increased signal intensity in the right frontal, temporal, and parietal white matter, right mesencephalon, cerebellar peduncles, and left temporal white matter (Fig. 2). There was no mass effect. A biopsy was performed in the right temporal lobe and the pathologic study indicated a probable PML. There was no clinical follow-up.

In all four patients, the lesions were better seen on MR than on CT, with a good contrast between normal and abnormal white matter, and the extent appeared greater on MR in all cases.

### Discussion

PML is related to an infection by a Papovavirus in an immunocompromised host, mostly in Hodgkin's disease and chronic lymphocytic leukemia, but also in AIDS patients and in patients treated with steroids or immunosuppressive drugs. Some cases have been reported without associated disease [7, 8]. The pathologic study reveals a demyelination with major abnormalities of oligodendrocytes. There is a destructive alteration of oligodendrocytes, most often at the periphery of the lesion. The nucleus is enlarged and contains irregular basophilic or eosinophilic inclusions. Within the center of the lesion, oligodendrocytes are absent. Initially, the lesions are small and either round or oval; later, they become confluent and large. The disease begins in the subcortical white matter, then spreads to deeper areas. The cortical gray matter is usually spared. There is no relationship to cerebral vessels, meninges, or the ventricular system. The involvement is most often asymmetrical. There is no preferential localization in the central nervous system but the spinal cord is infrequently reached. The clinical presentation varies with the sites involved: hemiparesis and intellectual disorders are frequent. The CT appearances have been described by several authors [7, 9]. There are low-intensity lesions in the white matter following the contours of the gray-white matter interface. They correspond to the association of demyelination and edema. Contrast enhancement and mass effect are rarely encountered.

MR has now demonstrated its accuracy in detecting white-matter diseases [1-4]. In PML, the common aspect is multiple long T1, long T2 lesions, involving asymmetrically the white matter, without mass effect or connection with blood vessels, meninges, or ventricles. The regions of long T1 and long T2 probably result from the combination of demyelination and edema. It is not possible at present to differentiate the two abnormalities. MR appears more precise than CT in the detection and assessment of PML as it gives a better contrast between normal and abnormal white matter and gray matter. The biopsy site, too, may be more easily determined. In the differential diagnosis, other demyelinating conditions may be considered. In multiple sclerosis, there is an important periventricular involvement; in the other leukoencephalopathies, the extent is often symmetrical. Cerebral infarcts have a vascular topography in gray and white matter. The chronic vascular lesions in elderly patients have a periventricular distribution. In primary and secondary brain tumors, the mass

effect is important and there is no limitation to the white matter, but the surrounding edema may be very similar to PML. Primary brain lymphoma may sometimes look like PML, with abnormalities confined to white matter and absence of mass effect. An association between these two diseases has been described [10]. As PML occurs mainly in immunodepressed patients, various cerebral infections may be encountered (toxoplasmosis, bacterial infections). In the early stages, the multiple lesions are not limited to the white matter; when an abscess is formed, a mass effect is frequent.

PML may therefore be diagnosed when MR shows long T1, long T2 asymmetrical lesions confined to white matter, distant from the periventricular region, without mass effect. The definitive diagnosis must be confirmed by brain biopsy.

### REFERENCES

1. Runge VM, Price AC, Kirshner HS, Allen JA, Partain CL, James AE. Magnetic resonance imaging of multiple sclerosis. A study of pulse technique efficacy. *AJNR* **1984**;5:691-702, *AJR* **1984**;143:1015-1026
2. Sheldon JJ, Siddharthan R, Tobias J, Sheremota WA, Boila K, Viamonte M. MR imaging of multiple sclerosis: comparison with clinical and CT examinations in 74 patients. *AJNR* **1985**;6:683-690, *AJR* **1985**;145:957-966
3. Young IR, Randell CP, Kaplan PW, James A, Bydder GM, Steiner RE. Nuclear magnetic resonance (NMR) imaging in white matter disease of the brain using spin echo sequences. *J Comput Assist Tomogr* **1983**;7:290-294
4. Young IR, Hall AS, Pallis CA, Legg NJ, Bydder GM, Steiner RE. Nuclear magnetic resonance imaging of the brain in multiple sclerosis. *Lancet* **1981**;ii:1063-1066
5. National Radiological Protection Board ad hoc Advisory Group on NMR Clinical Imaging. Revised guidance on acceptable limits of exposure during nuclear magnetic resonance clinical imaging. *Br J Radiol* **1983**;56:944-947
6. Young IR, Bailes DR, Burl M, et al. Initial clinical evaluation of a whole body nuclear magnetic resonance (NMR) tomograph. *J Comput Assist Tomogr* **1982**;6:1-18
7. Heinz ER, Drayer BP, Haenggeli CA, Painter MJ, Crumrine P. Computed tomography in white matter disease. *Radiology* **1979**;130:371-378
8. Richardson EP. Progressive multifocal leukoencephalopathy. In: Vinken PJ, Bruyn GW, eds. *Handbook of Clinical Neurology, vol. 9. Multiple Sclerosis and Other Demyelinating Diseases*. Amsterdam: North Holland Publishing Co., **1970**:485-499
9. Carroll BA, Lane B, Norman D, Enzmann D. Diagnosis of progressive multifocal leukoencephalopathy by computed tomography. *Radiology* **1977**;122:137-141
10. Ho K, Garahcis JC, Paegle RD, Gerber MA, Borkowski WJ. Progressive multifocal leukoencephalopathy and malignant lymphoma of the brain in a patient with immunosuppressive therapy. *Acta Neuropathol (Berlin)* **1980**;52:81-83