

MR of Reversible Thalamic Lesions in Wernicke Syndrome

John F. Donnal,¹ E. Ralph Heinz,¹ and Peter C. Burger²

Wernicke syndrome is a disease of thiamine deficiency. The clinical and pathologic manifestations are known but imaging reports are sparse. We present a patient with Wernicke syndrome whose MR studies showed thalamic lesions associated with the disease. Resolution of these lesions followed vitamin therapy and paralleled clinical improvement.

Case Report

A 68-year-old alcoholic woman was brought to the emergency room by her son who reported severe lethargy and bizarre behavior. She was apathetic, with flat speech and marked latency to questions and commands. She had fixed vertical nystagmus, could not sit or walk, and was dysmetric. CSF examination was normal. A clinical diagnosis of Wernicke encephalopathy was proposed. An MR image was obtained on the day of admission, prior to the institution of thiamine therapy. The study, performed on a 1.5-T superconducting magnet (Signa, General Electric, Milwaukee), was remarkable for increased signal in the dorsal medial nuclei of the thalami on T2-weighted images (Fig. 1). Signal was brighter on first echo 2800/30/.75 (TR/TE/excitations) than on second echo 2800/80/.75. Cerebral cortical atrophy and vermian atrophy were average for age. The mamillary bodies were faintly visualized in the suprasellar cistern, as is usual on axial scans.

The patient's symptoms improved dramatically with thiamine therapy. Nystagmus resolved and she was able to ambulate and care for herself. A follow-up MR scan 4 weeks after admission demonstrated near total resolution of the thalamic lesions (Fig. 2) accompanied by an apparent interval increase in the size of the third ventricle.

Discussion

Wernicke syndrome is a triad of mental symptoms, abnormal eye movements, and truncal ataxia [1]. Mentation abnormalities include confusion, inattentiveness, and lethargy. Nystagmus is often present and patients are usually unable to walk. Stigmata of alcoholism such as malnutrition, liver disease, and autonomic dysfunction often accompany Wernicke syndrome, but other cases are unrelated to alcoholism. The related clinical syndrome, Korsakoff syndrome, differs from Wernicke syndrome in the severity of mental dysfunction and is distinguished clinically by the presence of dementia and confabulation. Either syndrome can occur alone, although Wernicke syndrome is more common.

The cause of these syndromes is chronic thiamine, or vitamin B₁, deficiency, brought on by alcoholism or other disorders [1, 2]. This vitamin is a cofactor in transketolase,

an enzyme, and there is decreased activity of this enzyme in the thiamine-deficient state. The link between this biochemical observation and the well known CNS lesions of Wernicke syndrome remains to be established. Decreased serum levels of transketolase can aid in diagnosis, but clinical observations usually suffice. Treated Wernicke syndrome has a 10% mortality, but most patients improve rapidly. Prognosis is less favorable when Korsakoff syndrome is present.

The pathology of Wernicke and Korsakoff syndromes is identical and was extensively studied by Victor et al. [3]. These researchers examined 53 pathologic specimens and found all to be abnormal. The most common gross pathologic findings were mamillary body atrophy (74%), vermian atrophy (36%), and cerebral atrophy (27%). Microscopic disease was present in all mamillary bodies (100%) and most thalami (89%). The dorsal medial nuclei were affected in 88% of involved thalami; other thalamic nuclei were affected less often (Fig. 3). Lesions were observed frequently at the mid-brain, especially the oculomotor nucleus. Histopathology at affected sites ranged from nearly complete tissue necrosis to presence of reactive glial cells and mild neuronal and myelin destruction. In the most minimally diseased foci, only proliferation of astrocytes and prominence of blood vessels were observed, with intact neurons and myelin.

Imaging findings of Wernicke syndrome have been reported. In one study [4], sagittal MR scanning consistently demonstrated mamillary body atrophy, with seven of nine patients having smaller mamillary bodies than did controls. The less specific finding of global atrophy was often found. Importantly, mamillary atrophy was considered relatively more prominent than the cerebral atrophy. CT scanning in a case strikingly similar to ours was described by McDowell and LeBlanc [5]. A 45-year-old woman with florid Wernicke-Korsakoff syndrome had bilateral low-density lesions in the dorsal medial nuclei of the thalami, which partially regressed with treatment. Drayer [6] reported increased signal on T2-weighted images at the thalami of patients with Wernicke syndrome, along with increased signal at other deep gray structures. These changes were associated with mamillary body and cerebellar vermian atrophy.

Mamillary body atrophy is an irreversible marker of chronic Wernicke syndrome caused by tissue destruction. It is best assessed in the sagittal or coronal planes. Frequently, these bodies are not well seen on axial scans because they are lost in partial volume with the suprasellar cistern. Pathologic ma-

Received January 2, 1990; revision requested February 5, 1990; revision received March 6, 1990; accepted March 12, 1990.

¹ Department of Radiology, Duke University Medical Center, Box 3808, Durham, NC 27710. Address reprint requests to J. F. Donnal.

² Department of Pathology, Duke University Medical Center, Durham, NC 27710.

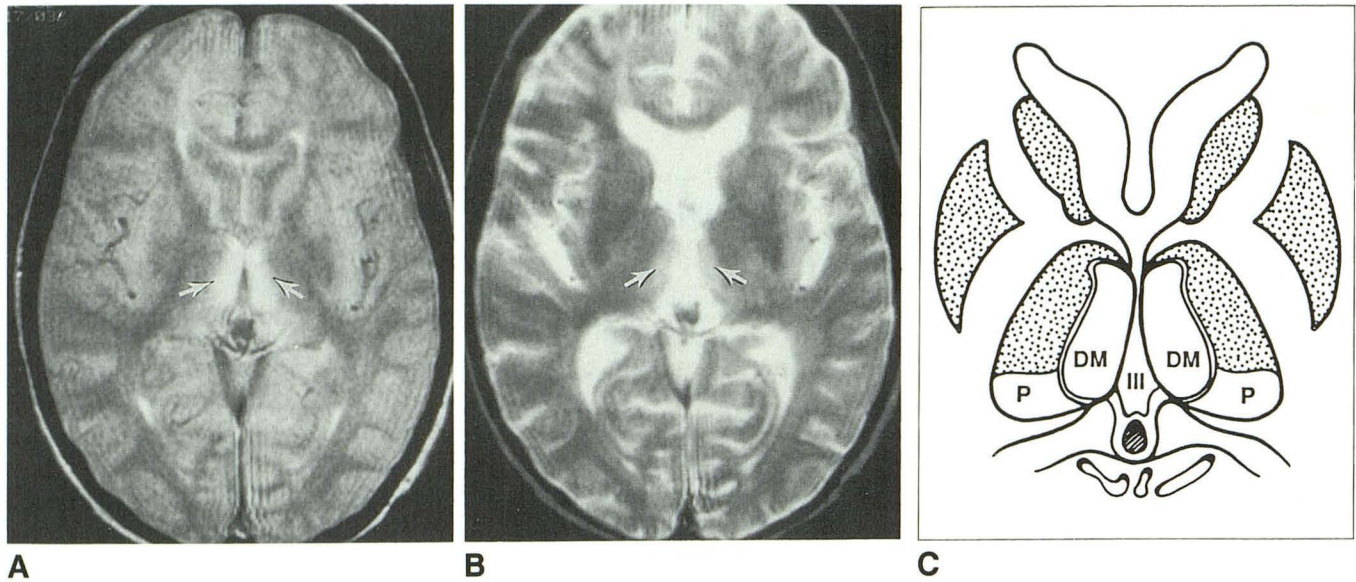


Fig. 1.—A and B, Lesions at dorsal medial nuclei (arrows) are better visualized on first echo (A) (2800/30) than on second echo (B) (2800/80) of T2-weighted pulse sequence. Third ventricle appears compressed.

C, Schematic of A. The dorsal medial nucleus (DM) can be identified at this level lying ventral to the pulvinar (P) and lateral to the third ventricle (III).

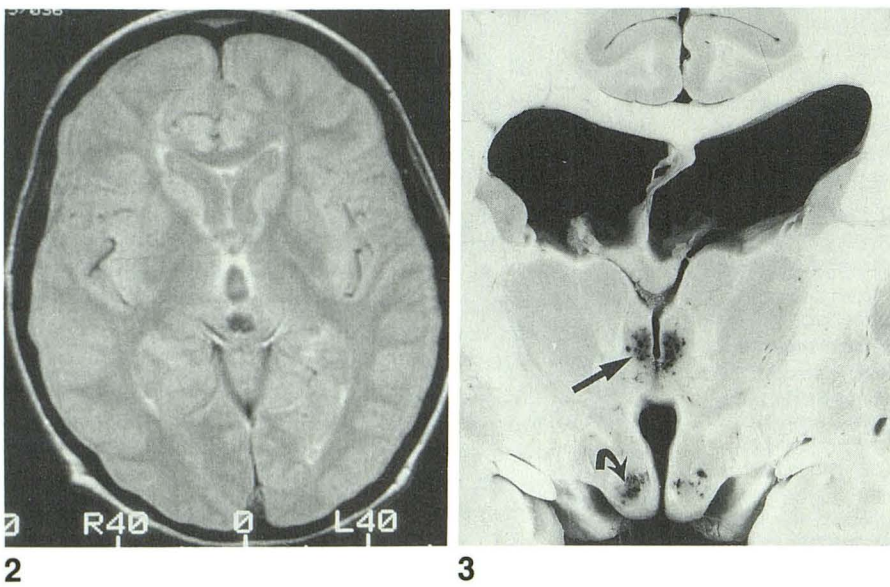


Fig. 2.—T2-weighted (2800/30) MR image after vitamin treatment and clinical improvement shows near total resolution of thalamic lesions. The third ventricle is larger than on initial scan.

Fig. 3.—Coronal pathologic section (from archives) demonstrates typical necrosis at dorsal medial nucleus of thalamus (straight arrow) and at mammillary bodies (curved arrow) in a patient who died of acute Wernicke syndrome.

terial demonstrating reversibility of Wernicke lesions is unavailable, but the clinical correlate of improvement with treatment is well established. We believe the present case demonstrates the reversibility of the initial pathologic changes of Wernicke syndrome at the dorsal medial nucleus of the thalamus. Resolution of abnormal high T2 signal and reexpansion of the third ventricle are consistent with biological reversal, and the patient's essentially complete recovery substantiates this hypothesis. Further MR investigations of this disease, untreated and treated, are warranted, but this case suggests that MR may have a role in the diagnosis of Wernicke-Korsakoff syndrome at a time when treatment can effectively reverse the course of the disease.

REFERENCES

1. Rowland LP. *Merritt's textbook of neurology*, 8th ed. Philadelphia: Lea & Febiger, 1989:903-904
2. Nadel A, Burger PC. Wernicke encephalopathy following prolonged intravenous therapy. *JAMA* 1976;235:2403-2405
3. Victor M, Adams RD, Collins GM. *The Wernicke Korsakoff syndrome*. Philadelphia: Davis, 1971:71-127, 155-160
4. Charness ME, Delapaz RL. Mammillary body atrophy in Wernicke's encephalopathy: antemortem identification using magnetic resonance imaging. *Ann Neurol* 1987;22:595-600
5. McDowell JR, LeBlanc HJ. Computed tomographic findings in Wernicke-Korsakoff syndrome. *Arch Neurol* 1984;41:453-454
6. Drayer BP. Imaging of the aging brain. Part II. Pathologic conditions. *Radiology* 1988;166:797-806

The reader's attention is directed to the commentary on this article, which appears on the following pages.