

# Brain Parenchyma Penetration by Intrathecal Nonionic Iopamidol

Michael R. Sage<sup>1</sup>  
John Wilcox<sup>1</sup>

Iopamidol, a nonionic, water-soluble contrast medium, has been recently recommended for myelography. As with other such media, the extent of parenchymal penetration is of interest in relation to the genesis of clinical complications. In this study the degree and depth of brain penetration of intrathecal iopamidol, using an iodine concentration of 280 mg I/ml, were compared at 15 and 60 min in adult greyhound dogs using coronal computed tomographic scanning of the brain after removal. A significant but patchy penetration corresponding to the cortical sulci was demonstrated at 15 min, while by 60 min there had been a further increase in the distribution and concentration of the contrast medium. Comparing the present study with a previous series using metrizamide and methylglucamine iothalamate at a similar iodine concentration (280 mg I/ml), no significant difference in the depth or degree of penetration at 60 min was found between the three contrast media, indicating a similar rate of diffusion across the cerebrospinal fluid/brain interface. Therefore, any difference in neurotoxicity is not explained by a reduced concentration of contrast medium due to variation in the rate of diffusion across this interface.

Metrizamide, a nonionic, water-soluble contrast medium, is now used widely for myelography and ventriculography [1]. Its lack of neurotoxicity compared with ionic water-soluble contrast media has been well documented in experimental [2, 3] and clinical [1] studies. However, it is not completely biologically inert, and it has been suggested that complications from intrathecal metrizamide are directly related to penetration of the contrast medium into the brain parenchyma [4-6]. A recent study comparing the brain penetration by intrathecal ionic and nonionic contrast media suggested that the rate of diffusion across the cerebrospinal fluid (CSF)/brain interface is similar [7], and therefore their difference in neurotoxicity cannot be explained on this basis alone. A new, nonionic, water-soluble contrast medium, iopamidol (Bracco, Milan), has been developed [8], and initial clinical trials suggest that it is well tolerated intrathecally [9]. We report a study in dogs to determine the rate and degree of brain penetration by intrathecal iopamidol.

## Materials and Methods

Using previously established experimental techniques [7], 25-36 kg male and female greyhound dogs were anesthetized with intravenous pentobarbital (Pentothal), 25 mg/kg, and, after intubation, anesthesia was maintained using 1% halothane in a 1:1 mixture of nitrous oxide and oxygen. Respiration was controlled at 8 breaths/min with an Oxford ventilator.

With the dog in a prone position with the neck flexed, cisternal puncture was performed using a 22 gauge needle, and 5 ml of iopamidol (fig. 1) at a concentration of 280 mg I/ml was injected into the subarachnoid space slowly over 2 min. After the intrathecal injection of the contrast medium, the dog was placed in a head-down position for 2 min, during which time the head was rotated gently from side to side; after this, the dog was returned to a supine position to encourage the intracranial contrast medium to lie adjacent to the

Received February 18, 1983; accepted after revision June 24, 1983.

<sup>1</sup>Department of Radiology, Flinders Medical Centre, Bedford Park, South Australia. Address reprint requests to M. R. Sage.

AJNR 4:1181-1183, Nov/Dec 1983  
0195-6108/83/0406-1181 \$00.00  
© American Roentgen Ray Society



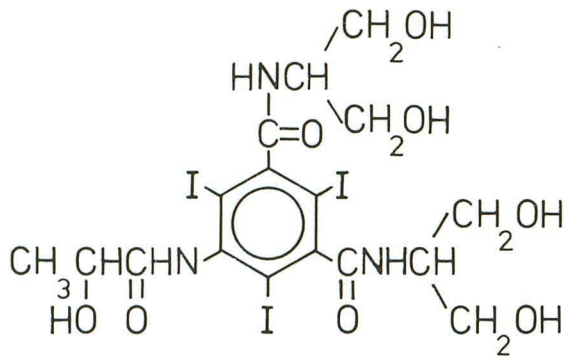


Fig. 1.—Structural formula of iopamidol; molecular weight = 777.29;  $I = 49.0\%$ ; pH of solution = 7.4.

cerebral hemispheres.

Ten studies were performed in which five animals were killed at 15 min and five at 60 min after the end of the intrathecal injection. An intravenous injection of 10–15 ml of saturated potassium chloride solution was used for euthanasia. The brains were removed within 15 min, and the surfaces rinsed with an isotonic solution (Hartmann solution, Travenol Labs., Sydney, Australia) to remove overlying CSF and contrast medium. The brains were then suspended in water in a sealed cylindrical Perspex container and positioned in the computed tomographic (CT) scanner (EMI model 5005). After phantom studies to ensure the accuracy of attenuation values, coronal scans were obtained at 1 cm intervals using 13 mm collimation (pixel size,  $0.75 \times 0.75$  mm) (fig. 2).

The coronal CT sections were assessed for evidence of brain penetration by the contrast medium. Previous studies [7] indicated that consistent and maximum penetration was demonstrated in the anterior and midtemporal region bilaterally, and therefore quantitative assessments were made in these regions by calculating the mean EMI number in a 100 pixel region of interest in the middle of the gray matter in both temporal lobes (fig. 3). The mean of both temporal lobes was established for each study.

The maximum attenuation value of the normal canine brain has been established [7]. Blind subjective assessment of the distribution and depth of penetration of contrast medium into both temporal lobes was therefore assessed at two adjacent levels in the 10 specimens. The window width of the diagnostic display console was placed on the "measure" setting and the level set at 24 EMI units as the gray matter in previous control studies had never been greater than this [7]. Therefore, the distribution of the contrast medium and the depth of attenuation values above that of normal gray matter could be measured directly at right angles to the brain surface in the same region of the temporal lobe for each study (fig. 3).

## Results

The mean EMI number for a 100 pixel region of interest for each series of experiments was  $27.9 \pm 6.7$  at 15 min and  $36.7 \pm 6.6$  at 60 min. Analysis using Student *t* test showed a significant increase in the concentration of contrast medium at 60 min compared with 15 min ( $p < 0.05$ ).

The maximum depth of penetration of contrast medium into the gray matter was similar after the two time periods, being  $13.4 \pm 1.3$  mm at 15 min and  $13.7 \pm 0.8$  mm at 60 min. However, the distribution of contrast medium was very

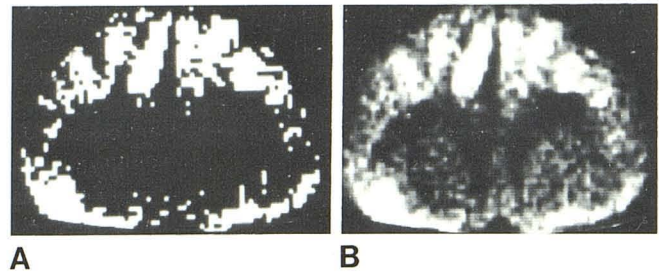


Fig. 2.—Brain contact with iopamidol for 15 min. Coronal CT scan of canine brain at "measure" setting of 24 EMI units (A) and window width of 20 EMI units (B) after intrathecal iopamidol has been in contact with cortical surface in supine position for 15 min. Contrast medium has already penetrated into gray matter. Although depth of penetration is similar to 60 min, distribution is more patchy, corresponding to site of cortical sulci.

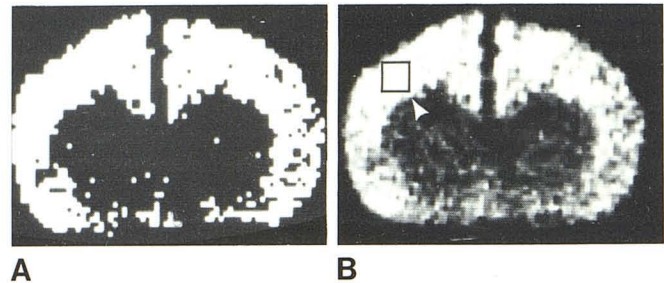


Fig. 3.—Brain contact with iopamidol for 60 min. Coronal CT scan of canine brain at "measure" setting of 24 EMI units (A) and window width of 20 EMI units (B) after intrathecal iopamidol has been in contact with cortical surface in supine position for 60 min. Hyperdense gray matter is from contrast penetration across CSF-brain interface. Uniform distribution compares with patchy penetration at 15 min (fig. 2). Region-of-interest sites ( $10 \times 10$  pixels) for concentration assessment (box) and level for depth of penetration measurement (arrowhead).

patchy at 15 min (fig. 2). The maximum penetration appeared to correspond to the site of cortical sulci with some sparing of gray matter between. After 60 min, the distribution of contrast medium was uniform throughout the gray matter (fig. 3) without an obvious increase in the maximum depth of penetration.

## Discussion

While a physiologic barrier between the blood and brain parenchyma has been well documented [10, 11], there is an apparent lack of a diffusion barrier at the pial surfaces to the passage of small (iopamidol has a maximum dimension of about  $20 \text{ \AA}$ ) water-soluble molecules between the cerebrospinal fluid (CSF) and the extracellular fluid of the brain parenchyma [10, 12–14].

Penetration of nonionic metrizamide into the brain parenchyma has been demonstrated both experimentally [4, 7, 14–16] and clinically [4–6, 17]. Our study confirms that there is also marked brain penetration by nonionic iopamidol after subarachnoid injection.

Considerable iopamidol was demonstrated within the brain parenchyma only 15 min after intrathecal injection,



supporting the evidence that small water-soluble molecules enter the brain parenchyma from the CSF by simple diffusion into the extracellular space [19] rather than by active transport across a physiologic barrier.

Although the maximum depth of penetration at 15 and 60 min was similar, the distribution of contrast medium at 15 min was very patchy, corresponding to the sites of cortical sulci. At 60 min, the distribution was more uniform and the iodine concentration was greater, indicating that progressive penetration of contrast medium had occurred up to 60 min.

In a previous study [7] using a similar 5 ml dose and iodine concentration of 280 mg I/ml, mean EMI numbers of  $37.0 \pm 9.1$  for methylglucamine iohalamate and  $39.2 \pm 10.8$  for metrizamide were obtained after 60 min. A value of  $36.7 \pm 6.6$  was obtained with iopamidol at 60 min in the present study, indicating that the rate of penetration of this new contrast medium is similar to that of both ionic methylglucamine iohalamate and nonionic metrizamide. This confirms the previous suggestion [7] that the difference in neurotoxicity between various water-soluble contrast media is not explained simply by a reduced concentration of contrast medium in the brain parenchyma but also depends on the molecular structure.

It has been suggested, but not yet confirmed, that the brain distribution of metrizamide after subarachnoid injection is primarily extracellular [15, 16, 18]. Certain metabolically active molecules such as cycloserine and 2-deoxyglucose are distributed intra- as well as extracellularly [5, 19] after subarachnoid injection. Deoxyglucose is part of the metrizamide molecule, and therefore it has been suggested that metrizamide may compete with glucose for penetration into the intracellular space [5]. Competitive inhibition of brain hexokinase by metrizamide has been demonstrated [20], lending support to this suggestion. Presumably, the distribution of iopamidol in the brain parenchyma is predominantly extracellular, like metrizamide, and our study confirms that the rate of penetration or diffusion across the pia mater is similar for both contrast media to 60 min. This however does not mean that the subsequent clearance of the two contrast media from the extracellular space will be the same, and the need for further work in this area is indicated.

#### REFERENCES

- Sackett JF, Strother CM. *New techniques in myelography*. Hagerstown, MD: Harper & Row, 1979
- Gonsette RE. Biologic tolerance of the central nervous system to metrizamide. *Acta Radiol [Suppl]* (Stockh) 1973;335:25-44
- Haughton VM, Ho K, Larson SJ, Unger GF, Correa-Paz F. Comparison of arachnoiditis produced by meglumine iocarmate and metrizamide myelography in an animal model. *AJR* 1978;131:129-132
- Drayer BP, Rosenbaum AE. Metrizamide brain penetrance. *Acta Radiol [Suppl]* (Stockh) 1977;355:280-293
- Caillé JM, Guibert-Tranier F, Howa JM, Billerey J, Calabet A, Piton J. Cerebral penetration following metrizamide myelography. *J Neuroradiol* 1980;7:3-12
- Cala LA. Cerebral absorption of metrizamide. *Lancet* 1981;2:922-923
- Sage MR, Wilcox J, Evill CA, Benness GT. Brain parenchyma penetration by intrathecal ionic and nonionic contrast media. *AJNR* 1982;3:481-483
- Hammer B, Lackner W. Iopamidol, a new non-ionic hydrosoluble contrast medium for neuroradiology. *Neuroradiology* 1980;19:119-121
- Drayer B, Suslavich F, Luther J, et al. Clinical trial of iopamidol for lumbosacral myelography. *AJNR* 1982;3:59-64
- Bradbury M. *The concept of a blood-brain barrier*. Chichester, England: Wiley, 1979
- Sage MR. Blood-brain barrier: phenomenon of increasing importance to the imaging clinician. *AJNR* 1982;3:127-138, *AJR* 1982;138:887-898
- Oldendorf WH, Davson H. Brain extracellular space and the sink action of the cerebrospinal fluid. Measurement of rabbit brain extracellular space using sucrose labeled with carbon 14. *Arch Neurol* 1967;17:196-205
- Dunker RO, Harris AB, Jenkins DP. Kinetics of horseradish peroxidase migration through cerebral cortex. *Brain Res* 1976;118:199-217
- Cserr HF. Relationship between cerebrospinal fluid and interstitial fluid of brain. *Fed Proc* 1974;33:2075-2078
- Golman K. Distribution and retention of  $^{125}\text{I}$ -labelled metrizamide after intravenous and suboccipital injection in rabbit, rat and cat. *Acta Radiol [Suppl]* (Stockh) 1973;335:300-311
- Fenstermacher JD, Bradbury MW, du Boulay G, Kendall BE, Radu EW. The distribution of  $^{125}\text{I}$ -metrizamide and  $^{125}\text{I}$ -diatrizoate between blood, brain and cerebrospinal fluid in the rabbit. *Neuroradiology* 1980;19:171-180
- Hammer B. The pathophysiology of intrathecally injected contrast media: In: Felix R, Kazner E, Wegener OH, eds. *Contrast media in computed tomography*. Amsterdam: Excerpta Medica, 1981:52-57
- Winkler SS, Sackett JF. Explanation of metrizamide brain penetration: a review. *J Comput Assist Tomogr* 1980;4:191-193
- Davson H. The environment of the neurone. *Trends Neurosci* 1978;2:39-41
- Bertoni JM, Steinman CG. Competitive inhibition of brain hexokinase by metrizamide. *Neurology* (NY) 1982;32:320-323