

Contrast Enhancement of Normal Intervertebral Disks: Time and Dose Dependence

Michael A. Ibrahim, Andrzej Jesmanowicz, James S. Hyde, Lloyd Estkowski, and Victor M. Haughton

PURPOSE: To determine the dose of contrast medium and the imaging strategy sufficient to detect diffusion of low-molecular-weight gadolinium-containing contrast media into normal intervertebral disks. **METHODS:** In 11 rabbits, sequential MR images were obtained of the spine for 120 minutes after intravenous injection of gadopentetate dimeglumine in doses of 0.1 to 2.8 mmol/kg. Images were inspected for evidence of contrast enhancement. Signal intensity was measured and plotted as a function of time and dose. **RESULTS:** Contrast enhancement was detected by inspection of images and by measurement in animals receiving doses of 0.3 mmol/kg and larger. **CONCLUSIONS:** Diffusion of gadolinium-containing chelates into the intervertebral disk can be detected with clinically used doses of commercially available contrast medium. Therefore, with MR and a gadolinium-containing contrast medium, diffusion into intervertebral disks can be studied.

Index terms: Contrast media, effects; Contrast media, paramagnetic; Spine, intervertebral disks; Spine, magnetic resonance; Animal studies

AJNR Am J Neuroradiol 15:419-423, Mar 1994

The normal intervertebral disk, like cartilage in other locations, has no vascularity. Nutrients such as oxygen, nitrate, sulfate, and glucose diffuse into the intervertebral disk through the vertebral end plate and annulus fibrosus (1-8). Diffusion, not perfusion, provides the nutrients necessary to sustain the several thousand cells per cubic millimeter that are located in the disk. Hypothetically, diminished diffusion as a result of changes in the vertebral end plate precedes degenerative changes in the disk. This hypothesis has been difficult to test because a noninvasive method for measuring diffusion in vivo in human intervertebral disks has not been reported (8). Diffusion of low-molecular-weight paramagnetic contrast me-

dia into the intervertebral disk is likely despite the lack of enhancement of intervertebral disks (9-14). The magnetic resonance (MR) techniques used clinically are usually not optimized to detect diffusion into the intervertebral disk. Therefore, we studied the dose of contrast medium and the imaging strategy sufficient to detect diffusion of gadolinium-containing contrast medium into intervertebral disks.

Methods

Seven adult New Zealand White rabbits (3.0 to 3.6 kg, 2 years old) underwent MR imaging with the administration of gadopentetate dimeglumine. Before MR imaging the rabbits were sedated with intramuscular Ketaset (30 to 35 mg/kg) and Rompun (6 mg/kg). A 25-gauge needle was inserted into the posterior auricular vein and flushed with heparin. The rabbit was placed in a single turn surface coil of our own construction in a 1.5-T scanner.

Sagittal images were obtained with a spin-echo pulse sequence modified to provide small fields of view. Imaging parameters were: 500/25/1 (repetition time/echo time/excitations); matrix, 256 × 256; field of view, 6 × 6 cm; section thickness, 3.0 mm; and no phase wrap. Images were obtained before and 2, 10, 20, 30, 45, 60, 90, and 120 minutes after gadopentetate dimeglumine (Magnevist, Berlex Laboratories, Wayne, NJ) was injected in a dose of 0.1 to 2.8 mmol/kg through the 25-gauge needle. Signal

Received January 27, 1993; accepted pending revision March 15; revision received June 8.

This work was supported in part by National Institutes of Health Grant R01 AR33667-05A3S.

From the Biophysics Research Institute (M.A.I., A.J., J.S.H., L.E.) and Department of Radiology (V.M.H.), Medical College of Wisconsin, Milwaukee.

Address reprint requests to Victor M. Haughton, MD, Department of Radiology, Froedtert Memorial Hospital, 9200 W Wisconsin Ave, Milwaukee, WI 53226.

AJNR 15:419-423, Mar 1994 0195-6108/94/1503-0419

© American Society of Neuroradiology

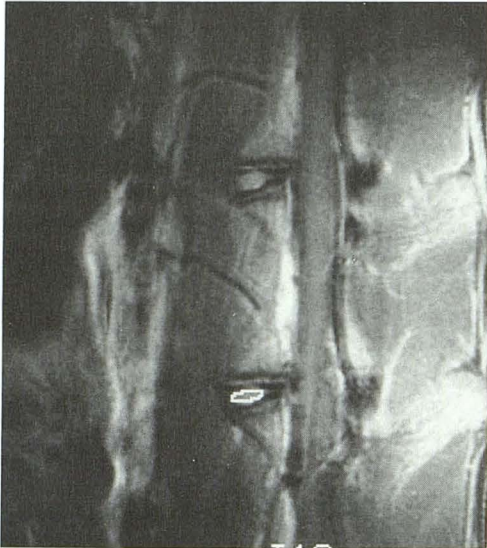

Fig. 1. Sagittal MR image of a rabbit spine showing a cursor placed on the intervertebral disk to measure contrast enhancement.

intensities were measured in the lumbar intervertebral disk that was located closest to the center of the surface coil's sensitive volume in each image with an elliptical cursor area of 2.0 mm^2 and the region of interest program on the system console (Fig 1). Contrast enhancement was calculated as the percent change in signal intensity from baseline divided by the baseline signal intensity.

Four additional rabbits (3.0 to 3.5 kg) were studied with the same technique. These rabbits received 0.1 or 0.3 mmol/kg of gadopentetate dimeglumine. A quadrature coil was substituted for the solenoid coil. Average contrast enhancement and standard deviations were calculated. The Wilcoxon sign test was used to calculate significance.

Results

Satisfactory precontrast and postcontrast images of the intervertebral disk were obtained in all rabbits. No complications of the anesthesia or contrast media were noted.

Enhancement of the intervertebral disk was observed in all experiments with doses of 0.3 mmol/kg or greater. Enhancement was seen near the end plates at 10 minutes for the 0.3-mmol/kg dose and at 2 minutes for the 0.6-mmol/kg and larger doses (Figs 2 and 3). The central disk area was noted to enhance at 60 to 120 minutes for all doses greater than 0.3 mmol/kg (Figs 2 and 3). Contrast enhancement appeared more intense in the central portion of the disk, which is fibrocartilagenous, than in the peripheral portion of the disk, which is predominantly collagen (9). No enhancement of the disk was observed for the 0.1-mmol/kg dose (Fig 4).

Contrast enhancement measurements in the intervertebral disk for the seven experiments in the solenoid coil are plotted in Figure 5. Contrast enhancement shows a progressive increase with time for all doses except 0.1 mmol/kg. Less than 15% to 26% enhancement was noted for the 0.1-mmol/kg doses. With the 0.3-mmol/kg dose, 46% enhancement was detected. The maximum enhancement detected was 185% at 120 minutes after the 2.8 mmol/kg dose. Enhancement of 25% or greater was always evident on inspection of the images.

Average contrast enhancements for six rabbits that received 0.1 or 0.3 mmol/kg are shown in Table 1. Average contrast enhancement with 0.3 mmol/kg was 45% at 90 and 120 minutes and with 0.1 mmol/kg was 20%. The differences after 30 minutes between the 0.1- and 0.3-mmol/kg doses were significant at the 0.05-mmol/kg level.

TABLE 1: Average contrast enhancement (and SD) of intervertebral disks after intravenous administration of contrast medium

Time After Injection of Gadopentetate-Dimeglumine (min)	Dose (mmol/kg)	
	0.1 (n = 4)	0.3 (n = 2)
0	0	0
2	10 (7)	0
10	5 (5)	15 (5)
20	15 (5)	25 (5)
30	17 (4)	25 (5)
45	13 (8)	35 (5)
60	15 (11)	35 (5)
90	20 (7)	45 (5)
120	20 (12)	45 (5)

Discussion

After the intravenous injection of gadopentetate dimeglumine, contrast enhancement was detected in normal rabbit intervertebral disks. The study shows that diffusion of gadolinium into normal intervertebral disk tissue can be detected by inspection of images or measurement of contrast enhancement. This result may seem to conflict with previous reports that the intervertebral disk does not enhance (10-13). In most of the previous studies, however, contrast enhancement was not studied quantitatively, and smaller doses of contrast medium and shorter intervals between injection of contrast medium and imaging were used. In our study, with the small doses of contrast medium and shorter intervals between imaging and contrast medium administration, no

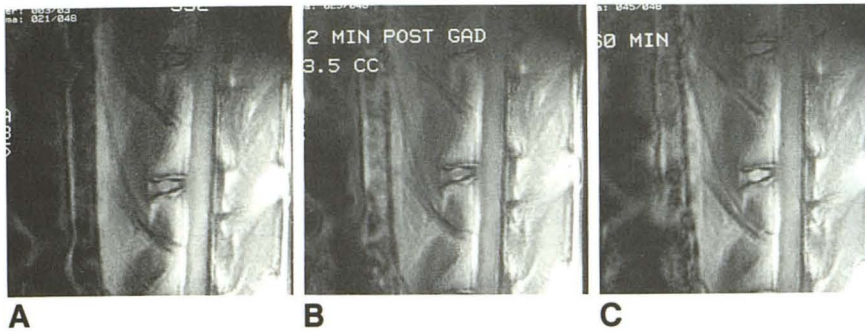


Fig. 2. T1-weighted MR images before (A) and at 2 (B) and 60 (C) minutes after intravenous administration of 0.6 mmol/kg of gadopentetate dimeglumine. Note that at 2 minutes there is a narrow band of increased signal intensity near the vertebral end plates, and at 60 minutes the disk has generally increased signal intensity.

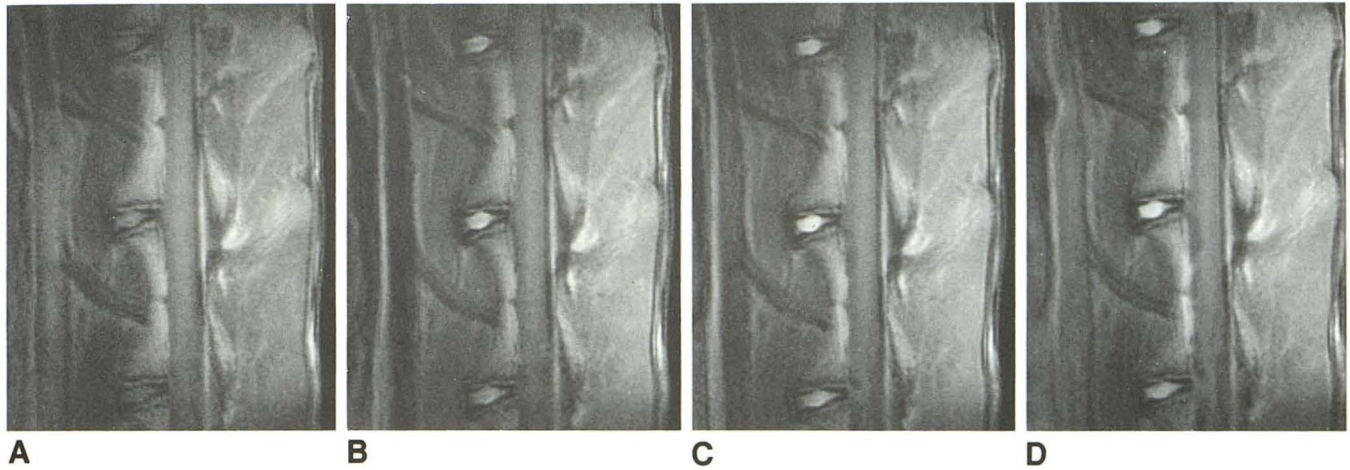


Fig. 3. T1-weighted MR images before (A) and 10 (B), 30 (C), and 120 minutes (D) after intravenous administration of 2.8 mmol/kg of gadopentetate dimeglumine. Note that at 10 minutes, signal intensity increased near the end plates and subsequently increased diffusely in the disk.

enhancement of the intervertebral disks was observed. With the conventional 0.1-mmol/kg dose of gadopentetate dimeglumine at the times usually selected for imaging, less than 10% enhancement is measured in rabbit intervertebral disks, and 10% enhancement is not detected by inspection. The small amount of enhancement achieved with the 0.1-mmol/kg dose probably explains why it has not been described in humans. Enhancement of cartilage in pediatric spines with this dose has been reported (11).

Enhancement of the intervertebral disk is not unique to rabbits; it has been observed in dogs with doses of contrast medium similar to those used in rabbits (Nguyen C and Haughton V, unpublished results). Rabbits and dogs have fibrocartilagenous intervertebral disks and porous osseous end plates similar to human intervertebral disks (16–20). The study suggests that in humans, MR images obtained between 20 and 45 minutes after intravenous injection of a paramagnetic contrast medium in a dose of 0.3 mmol/kg may demonstrate enhancement in normal inter-

vertebral disks. Gadoteridol and gadodiamide have been approved for clinical use in doses of 0.1 and 0.3 mmol/kg.

Conditions for these experiments were selected to minimize the number of experimental animals needed. Doses of contrast medium equal to and higher than the conventional clinical doses were used in our study to facilitate detection, comparison, and measurement in the animals. The inaccuracies in the measurement of contrast enhancement introduced by the inhomogeneous sensitivity of a surface coil were minimized, because contrast enhancement was normalized to preenhancement signal intensity. Maximal enhancement of the intervertebral disk may not have been achieved in this study because the experiments were terminated at 2 hours after contrast injection. The animals and replications were limited to a number sufficient to attain the goals of this study: to estimate the dose and imaging strategy necessary to detect contrast enhancement in the normal disk.

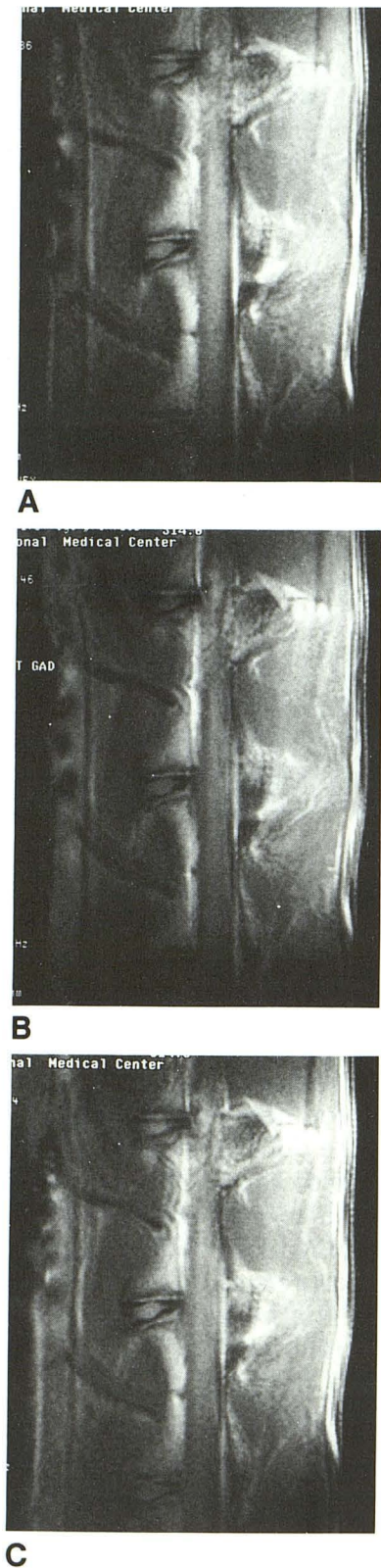

Fig. 4. T1-weighted MR images after intravenous injection of 0.1 mmol/kg of gadopentetate dimeglumine. A, Before injection; B, 2 minutes after injection; and C, 60 minutes after injection. No enhancement of the disk is noted.

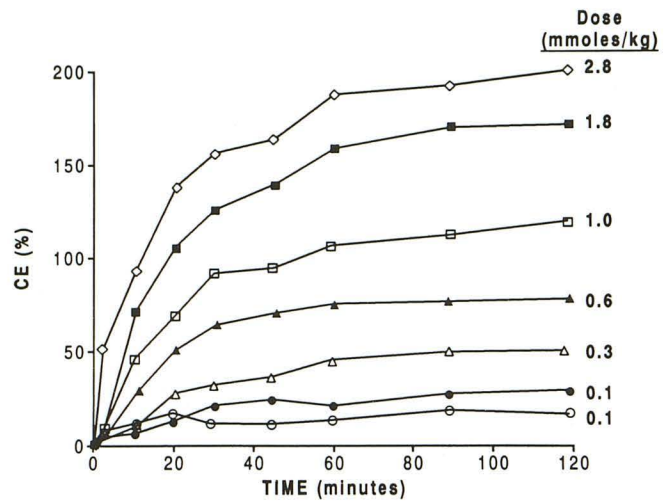


Fig. 5. Percentage of contrast enhancement versus time in rabbit disks after intravenous injection of gadopentetate dimeglumine in doses of 0.1 to 2.8 mmol/kg.

The significance of this study is that with MR and an intravenous contrast agent, diffusion into the normal intervertebral disk may be detected. Diffusion into the disk has been demonstrated previously by means of radioisotopes (1–8, 21). Labeled sulfate, glucose, and nitrates diffuse into the intervertebral disk within 1 hour after intravenous injection (6) and tend to accumulate near the periphery of the disk as did gadopentetate dimeglumine. The rate of diffusion for gadopentetate dimeglumine is likely slower than for the smaller solutes used in previous isotope studies because diffusion is a function of molecular weight and radius. Charge may also affect the rate of diffusion.

Measurement of diffusion into the intervertebral disk has been proposed as a method of detecting early disk degeneration. MR with intravenous paramagnetic contrast medium may provide a noninvasive tool to measure diffusion into intervertebral disks clinically.

Acknowledgments

We thank Suzanne Madden, Debra Bauer, and Margaret Wold for processing this manuscript, Richard Johnson for fabricating the surface coil, and Mrs D. Karen Hyde for plotting of the data.

References

1. Maroudas A. Biophysical chemistry of cartilaginous tissues with special reference to solute and fluid transport. *Biorheology* 1975;12:233–248

2. Stairman JW, Holm S, Urban JPG. Factors influencing oxygen concentration gradients in the intervertebral disc: a theoretical analysis. *Spine* 1991;16:444-449
3. Maroudas A. Distribution and diffusion of solutes in articular cartilage. *Biophys J* 1970;10:365-379
4. Maroudas A, Stockwell RA, Nachemson A, Urban JPG. Factors involved in the nutrition of the human lumbar intervertebral disc: cellularity and diffusion of glucose in vitro. *J Anat* 1975;120:113-130
5. Urban JPG, Holm S, Maroudas A, Nachemson A. Nutrition of the intervertebral disc: an in vivo study of solute transport. *Clin Orthop* 1977;129:101-114
6. Urban JPG, Holm S, Maroudas A, Nachemson A. Diffusion of small solutes into the intervertebral disc: an in vivo study. *Biorheology* 1978;15:203-223
7. Urban JPG, Holm S, Maroudas A, and Nachemson A. Nutrition of the intervertebral disc: effect of fluid flow on solute transport. *Clin Orthop* 1982;170:296-302
8. Maroudas A. Nutrition and metabolism of the intervertebral disc. In: Ghosh P, ed. *The biology of the intervertebral disc*. Vol. II. Boca Raton: CRC, 1968:1-38
9. Yu S, Haughton VM, Lynch KL, et al. Fibrous structure of the intervertebral disc: correlation of the MR appearance with anatomic sections. *AJNR Am J Neuroradiol* 1989;10:1105-1110
10. Baierl P, Mühlsteffen A, Haustein J, et al. Comparison of plain and Gd-DTPA enhanced MR imaging in children. *Pediatr Radiol* 1990;20:515-519
11. Sze G, Bravo S, Baierl P, Shimkin PM. Developing spinal column: gadolinium-enhanced MR imaging. *Radiology* 1991;180:497-502
12. Hickey DS, Aspden RM, Hukins DWL, Jenkins JPR, Isherwood I. Analysis of magnetic resonance images from normal and degenerate lumbar intervertebral discs. *Spine* 1986;11:702-708
13. Ross JS, Modic MT, Masaryk TJ, Carter J, Marcus RE, Bohlman H. Assessment of extradural degenerative disease with Gd-DTPA-enhanced MR imaging: correlation with surgical and pathological findings. *AJR Am J Roentgenol* 1990;154:151-157
14. Parizel PM, Rodesch G, Balériaux D, et al. Gd-DTPA-enhanced MR in thoracic disc herniations. *Neuroradiology* 1989;31:75-79
15. Miller GM, Forbes GS, Onofrio BM. Magnetic resonance imaging of the spine. *Mayo Clin Proc* 1989;64:986-1004
16. Walmsley R. Development and growth of the intervertebral disc. *Edinburgh Med J* 1953;60:341-364
17. Lipson SJ, Muir H. Experimental intervertebral disc degeneration. *Arthritis Rheum* 1981;24:12-21
18. Lipson SJ, Muir H. Proteoglycans in experimental intervertebral disc degeneration. *Spine* 1981;6:194-210
19. Smith JW, Walmsley R. Experimental incision of the intervertebral disc. *J Bone Joint Surg* 1951;33B:612-625
20. Urayama S. Histological and ultrastructural study of degeneration of the lumbar intervertebral disc of the rabbit following nucleotomy, with special reference to the topographical distribution pattern of the degeneration. *Nippon Seikeigeka Gakkai Zasshi* 1986;60:649-662
21. Souter WA, Taylor TKF. Sulphated acid mucopolysaccharide metabolism in the rabbit intervertebral disc. *J Bone Joint Surg* 1970;52B:371-384