

Decreased Pituitary Gland Height after Radiation Treatment to the Hypothalamic-Pituitary Axis Evaluated by MR

Eija Pääkkö, Kimmo Talvensaari, Juhani Pyhtinen, and Marjatta Lanning

PURPOSE: To evaluate treatment-related changes in pituitary gland morphology after childhood cancer and to compare these findings with growth data. **METHODS:** Forty-three survivors of childhood cancer were evaluated by cranial MR imaging. Twenty-nine of the patients had received radiation therapy to the hypothalamic-pituitary axis with doses of 10 to 46 Gy. The height of the pituitary gland was measured from midline sagittal images and compared with age- and sex-matched controls. Pituitary gland heights were compared with body height standard deviation scores in patients. **RESULTS:** The patients who had received radiation therapy to the hypothalamic-pituitary axis had significantly smaller pituitary glands than patients in the nonirradiated group or their age- and sex-matched controls (mean, 3.5 mm versus 5.9 and 5.8 mm, respectively). They were also significantly shorter than patients in the nonirradiated group. **CONCLUSION:** Radiation therapy to the hypothalamic-pituitary area may lead to poor growth of the pituitary gland and short stature.

Index terms: Pituitary gland, abnormalities and anomalies; Pituitary gland, magnetic resonance; Brain, growth and development; Therapeutic radiology, in infants and children; Iatrogenic disease or disorder

AJNR Am J Neuroradiol 15:537-541, Mar 1994

Cancer treatment, especially radiation therapy to the brain, may have endocrinologic sequelae. When the hypothalamic-pituitary axis falls within the radiation field, deficiency of the pituitary hormones may follow (1, 2). Growth hormone deficiency leads to poor growth in children with acute lymphoblastic leukemia who have received cranial irradiation as a part of central nervous system therapy (2).

Despite endocrinologic evaluations, the morphology of the pituitary gland has not been systematically studied after cancer treatment. A small anterior lobe, absence of the posterior pituitary high signal, or nonvisualization of the stalk

may be seen by magnetic resonance (MR) imaging after cranial irradiation and/or chemotherapy in children (3). A reduction of about 50% in weight of the pituitary gland has been shown in animals after irradiation (4).

Our purpose was to evaluate the morphology of the pituitary gland by MR imaging after treatment for childhood cancer with or without irradiation to the hypothalamic-pituitary axis, comparing the results with figures for age- and sex-matched controls. The clinical relevance of the pituitary findings was evaluated by comparing pituitary height with growth data in patients.

Patients and Methods

Forty-three persons with childhood cancer diagnosed at the Department of Pediatrics at our institution from 1973 through 1982 were studied by cranial MR scanning. The patients represent a portion of a larger survey on late deleterious effects of therapy for childhood cancer. Patients with brain tumors were excluded. There were 19 male and 24 female patients (age range, 10.5 to 31.2 years; median, 18.3 years). The diagnoses and ages at diagnosis and follow-up are shown in Table 1. All the patients were free of disease at the time of this evaluation, therapy having been discontinued 2.0 to 20.0 years ago, median 10.9

Received December 17, 1992; accepted pending revision February 25, 1993; revision received May 24.

This research was supported by the Medical Research Council of the Academy of Finland, Alma and K. A. Snellman Foundation and the Fund for Children's Cancer, Oulu University Central Hospital, Oulu, Finland.

From the Departments of Diagnostic Radiology (E.P., J.P.) and Pediatrics (K.T., M.L.), Oulu University Central Hospital, Oulu, Finland.

Address reprint requests to Eija Pääkkö, MD, Department of Diagnostic Radiology, Oulu University Central Hospital, Kajaanintie 50, 90220 Oulu, Finland.

AJNR 15:537-541, Mar 1994 0195-6108/94/1503-0537

© American Society of Neuroradiology

years. Twenty-nine of the patients had received irradiation to the hypothalamic-pituitary axis. The doses for patients with acute lymphoblastic leukemia and lymphoma varied between 20 to 25 Gy, except for six who had received 10, 15, 34, 44, 45, and 46 Gy, respectively. The calculated doses to the pituitary region in one patient with orbital rhabdomyosarcoma and one with Hodgkin disease were 20 and 21 Gy, respectively.

All but two patients received multidrug cytostatic therapy after different protocols for 1 to 3 years. Two children with acute lymphoblastic leukemia were in their second remission at the time of follow-up. Allogenic bone marrow transplantation had been performed on two patients.

Four patients in the radiation therapy group received growth hormone therapy because of hormone deficiency. Seven of the 14 male patients in the radiation therapy group received testosterone therapy. One of the patients was prepubertal, 25 pubertal, and 17 postpubertal. None of them had precocious puberty. There were no pregnancies among the female patients, and only one had irregular menstruation. None of the patients had diabetes insipidus.

Patients were measured for body height, and a height standard deviation score was calculated comparing the actual height with Finnish normal height standards (5). Body height measurements at the time of diagnosis were obtained from the patients' charts and parental heights by a questionnaire. From these data height standard deviation score change from diagnosis to study and target height deficit were calculated. Target height deficit is the actual relative height minus midparental height. In the nonirradiated group one patient with Turner syndrome and one with Mulibrey nanism were excluded from the height analysis.

Forty-three age- and sex-matched subjects without cancer or pituitary disorders were taken as controls (age range, 10.5 to 31.1 years, median 18.1 years). None had received cranial radiation therapy or chemotherapy, and they had all been referred for MR imaging for various neurologic reasons. Most of the controls had normal scans. There were six subjects with findings suggesting multiple sclerosis, four with focal atrophic areas, and two with arachnoid cysts. One subject with a possible hamartoma, one with an

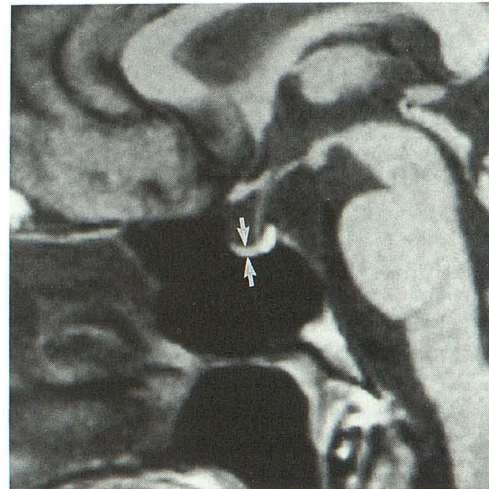


Fig. 1. Anterior lobe of the pituitary gland in a 16-year-old female patient, measuring 1.6 mm (between the arrows). She had received 25 Gy of cranial irradiation as central nervous system treatment for acute lymphoblastic leukemia at the age of 4.

arteriovenous malformation, and one with partial temporal resection for epilepsy were seen.

MR examinations were performed with a 1.0-T superconducting unit (Magnetom; Siemens, Erlangen, Germany). Sagittal and coronal T1-weighted images (500/15/2 [repetition time/echo time/excitations]) with a section thickness of 3 mm and a 21-cm field of view were obtained through the sella region. The protocol also included T2-weighted axial and T1-weighted precontrast and postcontrast coronal series through the brain. The height of the anterior lobe of the pituitary gland was measured from the midline sagittal scan using a cursor on the display with 2.3X magnification (Fig 1). A line perpendicular to the long axis of the pituitary gland was used. Attention was paid to the bright signal of the posterior pituitary gland and the integrity of the stalk. The height of the pituitary gland in the control subjects was measured using the same criteria as above on 5-mm sagittal cuts that were a part of a routine head examination protocol. It has been shown previously

TABLE 1: Clinical data on 43 survivors of childhood cancer

Diagnosis	Number of Patients (Male/Female)	Median (Range) Age at Diagnosis (Years)	Age at Follow-Up Median (Range) (Years)	Ht-pit Axis Irradiation (Yes/No)
Acute lymphoblastic leukemia	27 (11/16)	3.6 (0.3–14.0)	17.5 (10.8–25.7)	25/2
Nephroblastoma	7 (2/5)	2.1 (0.1–5.9)	16.9 (10.5–24.6)	0/7
Neuroblastoma	2 (0/2)	1.0 (0.9–1.2)	14.3 (11.3–17.2)	0/2
Lymphoma	2 (2/0)	13.8 (12.7–14.9)	26.8 (25.9–27.7)	2/0
Sarcoma	3 (3/0)	11.1 (9.4–14.4)	25.7 (18.3–31.2)	2/1
Other	2 (1/1)	10.5 (9.1–11.9)	23.8 (21.0–26.7)	0/2
Total	43 (19/24)	3.6 (0.1–14.9)	18.3 (10.5–31.2)	29/14

Note.—Ht-pit indicates hypothalamic-pituitary.

that 3- and 5-mm cuts are comparable for measuring pituitary height (6, 7).

Confidence intervals of 95% were calculated for the mean pituitary heights in each group, and differences between the groups were analyzed using Student two-tailed *t* test. Probability values less than 0.05 were considered significant.

The research was approved by the Ethics Committee of the medical faculty at our institution. Informed consent was obtained from the patients and their parents.

Results

The heights of the pituitary glands in patients and control subjects are shown in Figure 2 and Table 2. The mean height was significantly smaller in the patients than in the controls, and the pituitary glands were smaller in the patients who had received radiation therapy to the hypothalamic-pituitary area (mean, 3.5 mm, 95% confidence intervals, 3.0 to 4.0 mm) than in either the nonirradiated patients (mean 5.9 mm, 95% confidence intervals, 5.1 to 6.7 mm) or the controls (mean, 5.8 mm, 95% confidence intervals, 5.4 to 6.2 mm); the latter two groups did not

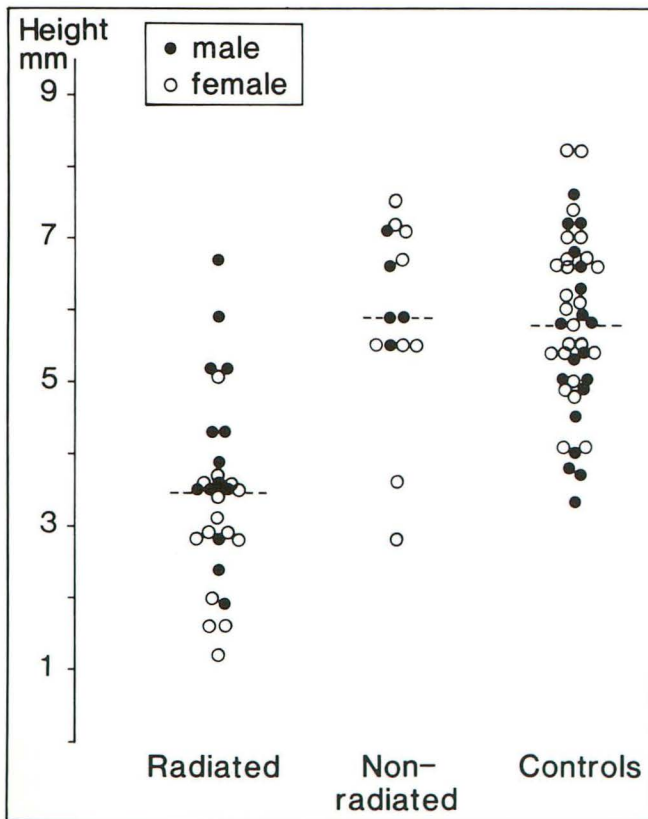


Fig. 2. Individual pituitary gland heights (in millimeters) in irradiated and nonirradiated patients and in control subjects. The mean pituitary gland heights are shown with a short line for each group.

TABLE 2: Height of the pituitary glands (mm)^a in patients with and without radiation therapy to the hypothalamic pituitary axis, and age- and sex-matched control subjects

	Total	Male	Female
Patients	4.3 (1.7) ^b (n = 43)	4.6 (1.5) ^c (n = 19)	4.0 (1.9) ^b (n = 24)
Irradiated	3.5 (1.3) ^b (n = 29)	4.0 (1.3) ^d (n = 14)	2.9 (1.0) ^b (n = 15)
Nonirradiated	5.9 (1.4) ^e (n = 14)	6.2 (0.6) ^f (n = 5)	5.7 (1.6) ^g (n = 9)
Control subjects	5.8 (1.2) (n = 43)	5.5 (1.3) (n = 19)	6.0 (1.1) (n = 24)

^a Mean with SD in parenthesis.

^b *P* = .0001.

^c *P* = .076.

^d *P* = .015.

^e *P* = .681.

^f *P* = .112.

^g *P* = .751.

differ significantly. Pituitary gland height in the radiation treatment group did not depend on the age at diagnosis. The heights of the pituitary glands in the four patients with growth hormone therapy and seven patients with testosterone therapy did not differ significantly from other patients in the radiation therapy group.

The female control subjects had higher pituitary glands than the male subjects (mean, 6.0 versus 5.5 mm), but female patients in each group had smaller glands than the male patients in the same group (mean, 2.9 versus 4.0 mm in irradiated cases and 5.7 versus 6.2 mm in nonirradiated cases).

The posterior pituitary bright signal was absent in four patients, three of whom had not received radiation therapy, and in one control subject. Two other control subjects had barely visible posterior pituitary lobes. There was no evidence of aberrant posterior pituitary tissue in any of the patients or control subjects. No pituitary stalk interruption was observed in the patients, but three control stalks could not be seen, possibly because of the acquisition of thicker sections.

The body height data on the two patient groups are shown in Table 3. The patients in the radiation treatment group were significantly shorter than those without irradiation. The decrease of the height standard deviation score from diagnosis to study was also significantly greater in irradiated patients, as well as the target height deficit.

Discussion

The size of the pituitary gland was evaluated here by measuring the height on a midline sagittal

TABLE 3: Body height data in patients with and without radiation treatment to the hypothalamic-pituitary axis

	H-SDS, mean (SD)	Δ H-SDS, mean (SD)	Target height deficit, mean (SD)
Irradiated (n = 29)	-1.50 (1.0)	-1.40 (0.9)	-1.14 (1.0)
Nonirradiated (n = 12) ^a	-0.05 (1.1)	-0.02 (0.9)	0.07 (1.0)
P value	.0002	.0003	.0012

Note.—H-SDS indicates height standard deviation score at the time of study; Δ H-SDS, change of H-SDS from the time of diagnosis to study; and target height deficit, the actual relative height minus midparental height.

^a One patient with Mulibrey nanism and one with Turner syndrome were excluded from the body height analysis.

image. It has been shown in an adult population that pituitary height correlates well with both pituitary area and volume and thus can be used as an indicator of size (8), although it probably underestimates the size of the smallest concave glands and may overestimate that of convex glands. Because no reliable data could be obtained on the volume of the control pituitary glands, we measured the heights of the glands. The mean heights of the pituitary glands of both male and female control subjects were similar to previously reported normal values (6, 9, 10).

The pituitary gland increases in size from 1 year to puberty during normal development, gradually decreasing after age 20 years (9–11). Our results show that brain radiation therapy, even with the small doses used for acute lymphoblastic leukemia central nervous system treatment, interferes with the normal growth of the pituitary gland when the hypothalamic-pituitary axis falls within the radiation therapy field. It is also documented that doses as low as 18 Gy may have effect on the function of the developing pituitary gland (12), growth hormone secretion being the most sensitive of pituitary hormones to deleterious effects of radiation (2). Significant body height reduction in irradiated patients in our study provides indirect evidence of impaired hormonal secretion. Small pituitary glands in these patients may thus reflect poor functioning, although impaired growth hormone secretion was documented only in four patients. Many cases of growth hormone deficiency probably have remained undetected, because not until recently has awareness of this problem arisen. Cranial irradiation may increase the risk of testicular damage in survivors of childhood acute lymphoblastic leukemia (13). The mean pituitary heights

in seven male patients with testosterone deficiency did not differ from that of other irradiated male patients in our study. Thorough hormonal analyses in patients with radiation therapy to the hypothalamic-pituitary axis are needed to confirm the possible association of a small gland with impaired functioning, although in patients with idiopathic growth hormone deficiency the size of the pituitary gland did not correlate with its functioning (14, 15).

It has been supposed that the endocrine deficiencies observed after cranial radiation therapy are attributable to sublethal damage, which becomes evident as the slowly dividing pituitary cells undergo mitosis and consequently die (16). Radiation therapy also may interfere with the vascular supply of the pituitary gland, which would lead to hormone deficiencies (16). These mechanisms are also likely to be responsible for the pituitary height reduction seen here.

Chemotherapy may have an effect on the growth of children with acute lymphoblastic leukemia (17). The exact mechanism of this effect is not known, but it is thought to affect bone growth (2). Chemotherapy alone did not seem to interfere with either growth of the pituitary gland or body height in the present patients, although the group who had not received cranial radiation treatment was admittedly somewhat heterogeneous, with a variety of chemotherapy regimens, so that the roles of individual chemotherapeutic agents and more intensive treatment protocols remain unclear.

Although female pituitary glands are slightly higher in a normal population (6, 9), as confirmed in our control subjects, the female patients in the radiation therapy group had smaller pituitary glands than the male patients. The female patients had been younger at the time of diagnosis (mean, 3.6 versus 7.5 years), but this does not explain the difference, because there was no correlation between age at diagnosis and pituitary height. Why the female patients had smaller glands remains unclear, but there must be other factors besides age and fractionation that determine the deleterious effects of radiation. There was also a small, nonsignificant difference in favor of the male patients in the nonirradiated patient group, but the number of cases was small (five male and nine female), and the difference may have been a chance effect.

Because there were no pituitary stalk interruptions in our patients, we cannot confirm the previous experience of pituitary stalk nonvisuali-

zation after irradiation and/or chemotherapy (3). The absence of the posterior pituitary high signal in four patients and one of the control subjects is not of concern, because this hyperintensity may not be seen in all healthy subjects, although its absence is often associated with diabetes insipidus (18). None of our patients had evidence of diabetes insipidus, nor did any of them have aberrant posterior pituitary tissue.

We have demonstrated here that radiation to the hypothalamic-pituitary axis in children leads to poor growth of the pituitary gland and short stature. If a small pituitary gland is observed in a patient who has previously received radiation therapy to the hypothalamic-pituitary area, hormonal analysis is warranted to detect growth hormone deficiency not yet clinically evident. It may take years before hormonal changes appear after radiation therapy (2). Impaired growth of the pituitary gland also may be a late phenomenon. Patients with acute lymphoblastic leukemia would provide a more homogeneous group for follow-up of pituitary gland size and function, because nowadays only a limited subset of patients receive cranial radiation therapy.

References

- Lannering B, Albertsson-Wikland K. Growth hormone release in children after cranial irradiation. *Horm Res* 1987;27:13-22
- Shalet SM, Clayton PE, Price DA. Growth and pituitary function in children treated for brain tumours or acute lymphoblastic leukaemia. *Horm Res* 1988;30:53-61
- Ball WS Jr, Prenger EC, Ballard ET. Neurotoxicity of radio/chemotherapy in children: pathologic and MR correlation. *AJNR Am J Neuroradiol* 1992;13:761-776
- Mosier HD Jr, Jansons RA. Stunted growth in rats following X-irradiation of the head. *Growth* 1967;31:139-148
- Sorva R, Perheentupa J, Tolppanen E-M. A novel format for a growth chart. *Acta Paediatr Scand* 1984;73:527-529
- Elster AD, Chen MYM, Williams DW III, Key LL. Pituitary gland: MR imaging of physiologic hypertrophy in adolescence. *Radiology* 1990;174:681-685
- Kuroiwa T, Okabe Y, Hasuo K, Yasumori K, Mizushima A, Masuda K. MR imaging of pituitary dwarfism. *AJNR Am J Neuroradiol* 1991;12:161-164
- Lurie SN, Doraiswamy PM, Husain MM, et al. In vivo assessment of pituitary gland volume with magnetic resonance imaging: the effect of age. *J Clin Endocrinol Metab* 1990;71:505-508
- Suzuki M, Takashima T, Kadoya M, et al. Height of normal pituitary gland on MR imaging: age and sex differentiation. *J Comput Assist Tomogr* 1990;14:36-39
- Argyropoulou M, Perignon F, Brunelle F, Brauner R, Rappaport R. Height of normal pituitary gland as a function of age evaluated by magnetic resonance imaging in children. *Pediatr Radiol* 1991;21:247-249
- Doraiswamy PM, Potts JM, Axelson DA, et al. MR assessment of pituitary gland morphology in healthy volunteers: age- and gender-related differences. *AJNR Am J Neuroradiol* 1992;13:1295-1299
- Rappaport R, Brauner R. Growth and endocrine disorders secondary to cranial irradiation. *Pediatr Res* 1989;25:561-567
- Siimes MA, Lie SO, Andersen O, Marky I, Rautonen J, Hertz H. Prophylactic cranial irradiation increases the risk of testicular damage in adult males surviving ALL in childhood. *Med Pediatr Oncol* 1993;21:117-121
- Kikuchi K, Fujisawa I, Momoi T, et al. Hypothalamic-pituitary function in growth hormone-deficient patients with pituitary stalk transection. *J Clin Endocrinol Metab* 1988;67:817-823
- Maghnie M, Triulzi F, Larizza D, et al. Hypothalamic-pituitary dysfunction in growth hormone-deficient patients with pituitary abnormalities. *J Clin Endocrinol Metab* 1991;73:79-83
- Littley MD, Shalet SM, Beardwell CG. Radiation and the hypothalamic-pituitary axis. In: Gutin PH, Leibel SA, Sheline GE, eds. *Radiation injury to the nervous system*. New York: Raven, 1991:303-324
- Clayton PE, Morris-Jones PH, Shalet SM, Price DA. Growth in children treated for acute lymphoblastic leukaemia. *Lancet* 1988;1:460-462
- Colombo N, Berry I, Kucharczyk J, et al. Posterior pituitary gland: appearance on MR images in normal and pathologic states. *Radiology* 1987;165:481-485