

Fast Spin-Echo MR in the Detection of Vertebral Metastases: Comparison of Three Sequences

Kendall M. Jones, Richard B. Schwartz, Michael T. Mantello, Sungkee S. Ahn, Ramin Khorasani, Suresh Mukherji, Koichi Oshio, and Robert V. Mulkern

PURPOSE: To examine the relative capabilities for the detection of vertebral metastases of three available fast spin-echo sequences: T1-weighted fast spin-echo, short tau inversion recovery (STIR) fast spin-echo, and T2-weighted fast spin-echo sequences with chemical shift selective saturation pulse fat suppression. **METHODS:** Fourteen patients were evaluated prospectively over a 2-month period with T1-weighted fast spin-echo (four echo train, four acquisitions, 1 min 59 sec–2 min 37 sec), STIR fast spin-echo (16 echo train, four acquisitions, 2 min 30 sec–3 min 19 sec), and T2-weighted fast spin-echo (16 echo train, 4 acquisitions, 2 min 27 sec–3 min 16 sec). For all three pulse sequences, measurements were obtained of the signal intensities of normal marrow, abnormal marrow, fat, and noise posterior to the spine. Contrast-to-noise ratios were calculated for metastases in each case. Lesions were evaluated by three observers and rated for size, location, and conspicuity. **RESULTS:** Signal intensities of fat, normal marrow, and noise were highest for T1-weighted fast spin-echo sequences. STIR fast spin-echo and fat-suppressed T2-weighted fast spin-echo had approximately similar fat-suppression capabilities. Though contrast-to-noise ratios were highest overall for STIR fast spin-echo, the finding was not statistically significant and lesion conspicuity was deemed better with fat-suppressed T2-weighted fast spin-echo and T1-weighted fast spin-echo images. Discrete lesions were well identified on all three pulse sequences. **CONCLUSION:** Fast spin-echo sequences appear promising for the detection of vertebral metastases. Further work should be directed toward comparison with conventional spin-echo to determine whether fast spin-echo may replace conventional spin-echo sequences for evaluation of vertebral metastases.

Index terms: Magnetic resonance, technique; Magnetic resonance, comparative studies; Magnetic resonance, fat suppression; Spine, neoplasms; Spine, vertebrae; Neoplasms, metastasis

AJNR Am J Neuroradiol 15:401–407, Mar 1994

Fast spin-echo is a technique for rapid acquisition of spin-echo images, and is based on the original radio frequency echo planar methods introduced by Hennig et al (1). Manipulation of image parameters such as the echo train length, interecho interval, repetition time, and pseudo-echo time permits acquisition of images far more rapidly than is possible with conventional spin-echo, while retaining contrast features similar to conventional spin-echo (2–6). Though demon-

strating similar contrast features in general to conventional spin-echo images, fast spin-echo spine images differ in one important respect: fat appears bright on routine fast spin-echo pulse sequences including T1-weighted proton density-weighted, and T2-weighted images. This is reflected in the relatively bright appearance of vertebral marrow in most patients, even on heavily T2-weighted images. This is particularly true in elderly patients with yellow (fatty) vertebral marrow, who are most prone to develop marrow metastases. Because marrow metastases often display high signal intensity on T2-weighted images, metastatic lesions may be missed adjacent to a background of bright fatty marrow.

The purpose of our study is to evaluate and compare the relative conspicuity of vertebral metastatic lesions on three fast spin-echo pulse

Received November 10, 1992; accepted pending revision January 28, 1993; revision received May 14.

From the Department of Radiology, Brigham and Women's Hospital, The Children's Hospital, Harvard Medical School, Boston, MA 02115. Address reprint requests to R. V. Mulkern, Ph.D.

AJNR 15:401–407, Mar 1994 0195-6108/94/1503-0401
© American Society of Neuroradiology

sequences: T1-weighted fast spin-echo, short tau inversion recovery (STIR) fast spin-echo, and T2-weighted fast spin-echo with chemical shift selective saturation (CHESS) fat suppression.

Materials and Methods

We prospectively evaluated 14 patients (eight men and six women) 29 to 80 years of age (mean, 57) using a Signa 1.5-T scanner (GE Medical Systems, Milwaukee, Wis). Fifteen separate scans were performed from October to December, 1991. Patients were selected based on known metastatic disease with demonstrated vertebral metastases. Twelve scans were performed through the thoracic spine, two scans through the lumbar spine, and one scan through the cervical spine. One patient had two scans on separate dates (one cervical spine, one thoracic spine). The primary sites of the metastatic lesions included lung (three cases), gastrointestinal adenocarcinoma (two cases), melanoma (two cases), lymphoma (one nodular sclerosing Hodgkin, 1 non-Hodgkin), prostate (two cases), breast (one case), transitional cell bladder carcinoma (one case), and adenocarcinoma of unknown primary (one case). In all cases, patient charts were reviewed and the primary diagnosis was established by surgical or needle biopsy. Metastatic disease was documented in each case by multiple modalities, and vertebral metastases in particular were confirmed in all cases by multiple techniques including bone scan (nine cases), plain films (six cases), computed tomography (five cases), conventional magnetic resonance (five cases), bone biopsy (three cases), and gallium scan (one case).

In all 15 examinations, T1-weighted fast spin-echo, T2-weighted fast spin-echo, and STIR fast spin-echo scans were obtained. In 14 cases, the T2-weighted images were obtained with fat suppression using the CHESS technique. In one patient, T2-weighted fast spin-echo scans were obtained both with and without the fat suppression.

All fast spin-echo sequences were performed in the sagittal plane using a 4/0.5-mm section/gap profile with either a 28 or a 32 cm field of view, with the field of view fixed for all three sequences in any given patient. For the T1-weighted fast spin-echo sequence 600/12/4 (repetition time/echo time [effective]/excitations) the echo spacing was 12 msec, echo train length was 4, and a centric phase encode ordering was used (2, 3). A total of 10 section locations were acquired with this set of parameters. In 13 cases, a 256 × 192 matrix was used with a total imaging time of 1 minute 59 seconds. In two cases, a 256 × 256 matrix was used (2 min 37 sec).

T2-weighted fast spin-echo images with CHESS fat suppression were obtained in 14 cases. In 12 cases, acquisition parameters were 3000/102/4 with 13 section locations obtained in 2 minutes 27 seconds (256 × 192 matrix, 12 cases) or 3 minutes 15 seconds (256 × 256 matrix, one case). In two cases, parameters were 4000/102/4 with 16 section locations obtained in 3 minutes 16 seconds (256 × 192 matrix). A 12-msec echo spacing and 16 echo train length were used with a straight phase encode ordering,

placing the effective echo time at the center of the echo train (7).

STIR fast spin-echo images were obtained in 15 cases. In 12 cases, acquisition parameters were 3104/90/4 (inversion time of 110). Images were obtained at seven section locations in 2 minutes 30 seconds (256 × 192 matrix, 11 cases) or in 3 minutes 19 seconds (256 × 256 matrix, two cases). In three cases, acquisition parameters were 4105/90/4, inversion time 110, with nine section locations obtained in 3 minutes 18 seconds (256 × 192 matrix). The echo spacing was 18 msec and echo train length was 16. The reordered phase encoding scheme introduced by Melki et al (3) was used to manipulate the effective echo time.

For all 15 cases of marrow metastases, measurements were obtained of the absolute signal intensity of specific regions of interest on the scanner console. For all three pulse sequences, measurements were obtained within normal marrow, metastatic marrow, fat, and noise posterior to the spine. The regions of interest were matched as closely as possible between sequences. In each case, the largest metastatic lesion was selected for measurement. In all 15 cases, T1-weighted fast spin-echo, STIR fast spin-echo, and T2-weighted fast spin-echo images were evaluated by consensus of three trained neuroradiologists (K.J., R.S., M.M.) and all lesions were evaluated with respect to location, margination, and conspicuity. In addition, size measurements were obtained on each sequence for each discrete lesion. The three pulse sequences were then ranked in each case in terms of overall lesion conspicuity, and artifacts were recorded.

Statistical analyses included calculation of the mean and standard deviation of all signal intensities from each tissue for each sequence. Contrast-to-noise ratios were then calculated by taking the difference in mean values between normal marrow signal and lesion signal and dividing by the mean noise value obtained for that sequence. In addition, each signal intensity measurement was divided by the standard deviation of the signal within that region of interest. The mean of all such measurements for both normal marrow and lesion was calculated and the difference between these two means yielded an alternate measure of contrast-to-noise ratios for each sequence. The statistical significance of differences between contrast-to-noise ratios for different sequences was calculated using paired *t* tests. The overall conspicuity of lesions on each of the pulse sequences was appraised by three readers and these results were tabulated and ranked; statistical significance of these rankings was determined using paired *t* tests.

Results

Mean signal intensities of normal marrow, lesion, fat, and background noise for all three pulse sequences are listed in Table 1. As expected, the signal intensity of normal marrow and fat was significantly higher for T1-weighted fast spin-echo sequences than for the inversion recovery or T2-weighted fast spin-echo sequences with

TABLE 1: Means and standard deviations of all signal intensity measurements and the contrast-to-noise ratio

	Marrow	Lesion	Fat	Noise	C/N
T1-weighted FSE	139 ± 41	66 ± 31	326 ± 143	9 ± 5	-8.1
STIR FSE	14 ± 7	55 ± 20	25 ± 10	3 ± 1	13.7
T2-weighted FSE	15 ± 6	61 ± 23	61 ± 31	4 ± 1	11.5

Note: Contrast-to-noise (C/N) ratios were obtained by subtracting mean lesion signal from mean marrow signal and dividing by the mean noise value. FSE indicates fast spin-echo.

their fat-suppression techniques. Though subcutaneous fat showed lower signal intensity for STIR fast spin-echo than for T2-weighted images with fat suppression, normal marrow had nearly identical signal intensity on both sequences. T1-weighted images demonstrated considerably more noise than either inversion-recovery or T2-weighted images. There was no statistical significance among any of the three sequences as far as overall mean signal intensity for metastatic lesions.

The contrast-to-noise ratios reported in Table 1 were calculated directly from the mean lesion, marrow, and noise values in the table and indicate that contrast-to-noise for STIR fast spin-echo is highest, followed by T2-weighted fast spin-echo with fat suppression and T1-weighted fast spin-echo. The contrast-to-noise ratios calculated with the alternate method using region of interest signal intensity and its standard deviation demonstrated the same rank order, with contrast-to-noise for STIR fast spin-echo being the highest (7.9), followed by T2-weighted fast spin-echo with fat suppression (5.4) and T1-weighted fast spin-echo (3.0). Paired *t* tests indicated no statistical significance for the differences in the magnitude of contrast-to-noise values between sequences ($P > .05$).

Subjectively, T1-weighted fast spin-echo images appeared more prone to noise, and the spinal cord appeared less sharp than on the T2-weighted fast spin-echo images. Inversion recovery (STIR) images appeared less sharp than T2-weighted fast spin-echo images with CHES fat suppression, and images were more prone to motion and flow-related artifact, particularly in the thoracic spine, where respiratory motion is greatest.

A total of 42 discrete lesions were identified. Of these, 40 were detected on T1-weighted fast spin-echo; 40 were detected on STIR fast spin-echo; and 39 were detected on T2-weighted fast spin-echo with fat suppression. Lesion detection was concordant for all three pulse sequences in 38 of 42 cases. In one patient, two of nine lesions

were seen on STIR which were not apparent on the other two sequences. In another patient, two of seven lesions seen on the T1-weighted fast spin-echo sequence were not apparent on the STIR fast spin-echo sequence, and one of the seven lesions was not apparent on the T2-weighted fast spin-echo sequence with fat suppression. In four patients, lesions were too ill defined or diffuse to number and measure discrete lesions.

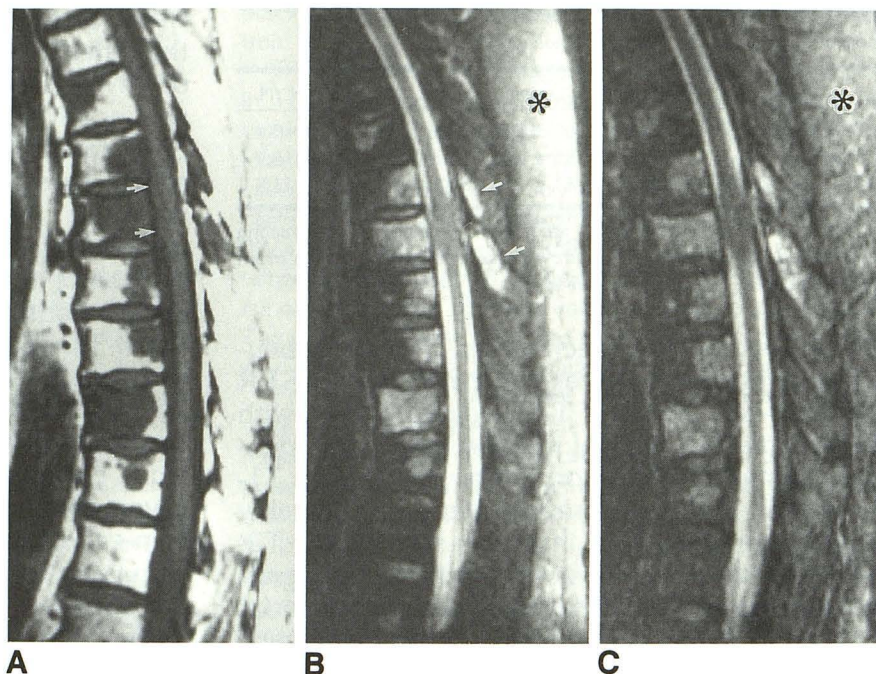
On T1-weighted fast spin-echo sequences, lesions were rated as well circumscribed in 10 of 15 cases, and poorly circumscribed in 5 of 15 cases. On T2-weighted fast spin-echo sequences, eight cases were rated well circumscribed and seven cases poorly circumscribed. On STIR fast spin-echo sequences, seven cases were rated well circumscribed and eight cases were rated poorly circumscribed.

The 42 discrete lesions identified in all patients were measured in greatest cross-sectional diameter. Twelve lesions measured greater than 2 cm in diameter; 11 lesions measured 1.5 to 2 cm in diameter; nine lesions measured 1 to 1.5 cm in diameter; and 10 lesions measured less than 1 cm in diameter (smallest lesion: 6 mm). The two lesions seen on STIR but not on the other two sequences each measured 7 mm in diameter. One lesion seen on the T1-weighted sequence but not seen on the other sequences measured 8 mm. Finally, one lesion not seen on STIR but seen on the other sequences measured 1.2 cm.

The three techniques were rated with respect to conspicuity of vertebral lesions. They were accorded a ranking of 1, 2, or 3 based on descending order of preference (tied ranks were assigned the average of the ranks they would have been assigned had there been no tie). The preferred sequence was T2-weighted fast spin-echo with CHES pulse fat suppression, which received a ranking of 1.83 ± 0.45 , followed by T1-weighted fast spin-echo at 1.93 ± 0.8 , and STIR at 2.23 ± 0.56 . The difference between the T2-weighted fast spin-echo and STIR ranking was significant at the .05 level; the other differences in ranking did not reach statistical significance.

Epidural metastatic disease was noted in six cases. In three cases, conspicuity was rated equal on all pulse sequences. However, in three cases, epidural disease was rated more conspicuous on both T2-weighted fast spin-echo and STIR fast spin-echo sequences than on T1-weighted fast spin-echo sequences. Metastatic disease involving the posterior elements was noted in nine

Fig. 1. A, T1-weighted fast spin-echo image of the thoracic spine in a patient with metastatic melanoma. Metastases are well seen adjacent to bright fatty marrow. Epidural metastasis is also evident (arrows). B, T2-weighted fast spin-echo image with fat suppression of the same region. Metastases are again well seen involving the vertebral bodies and the posterior elements (arrows). Cord expansion is also well seen on this sequence presumably because of intramedullary metastases. Note bright fat adjacent to the coil (asterisk). C, STIR fast spin-echo image photographed at same settings demonstrates similar findings. The signal intensity of metastases is lower, and fat suppression is more complete (asterisk).



cases. In seven cases, conspicuity was rated equal on all pulse sequences. In two cases, conspicuity was rated higher on T2-weighted fast spin-echo and STIR fast spin-echo sequences than on T1-weighted sequences. In two cases, the vertebral mass extended posteriorly into the spinal canal, and in these cases the conspicuity of the lesion was rated equal on all three pulse sequences.

Discussion

Fast spin-echo sequences are relatively recent modifications (2–7) of the hybrid relaxation-enhanced rapid acquisition (RARE) sequences originally described by Hennig et al (1). Manipulation of imaging parameters including repetition time, echo train length, interecho interval and phase-encode order allows manipulation of image contrast and speed to obtain images far more rapidly than is possible using conventional spin-echo techniques. With the most recent modifications, RARE/fast spin-echo has become widely applicable for the generation of high-quality T1-weighted, proton density-weighted, and T2-weighted images, with or without fat suppression. For proton density-weighted and T2-weighted fast spin-echo images, acquisition time is significantly (three- to four-fold) shorter than in conventional spin-echo sequences. For T1-weighted images, the time savings is not as impressive when expressed in terms of time-to-section ratio compared with conventional spin-echo se-

quences. However, if only a limited number of sections is required (as may be the case in sagittal spine imaging), a four-fold reduction in scan time may be obtained.

Recent studies have emphasized the similarity of fast spin-echo images to conventional spin-echo images in terms of spin-echo contrast features and lesion conspicuity (3–6). Although in most respects fast spin-echo images show similar contrast characteristics to conventional spin-echo images, there are some important differences. Fast spin-echo images display decreased magnetic susceptibility effects, as described in previous reports (3–6). Fat has a uniformly bright appearance on all standard fast spin-echo sequences, most likely because of the effect of multiple closely spaced 180 degree refocusing pulses reducing contributions to T2 decay processes from spin-spin splitting interactions (8).

The bright appearance of fat on fast spin-echo pulse sequences has important implications for the evaluation of marrow using this technique. On T1-weighted conventional spin-echo sequences, the bright appearance of vertebral marrow fat results in excellent conspicuity of most metastatic lesions, which are usually hypointense on this pulse sequence. Similarly, the high signal intensity of fat on T1-weighted fast spin-echo images leads to hypointense metastatic lesions demonstrating good contrast adjacent to a background of bright fatty marrow (Fig 1A).

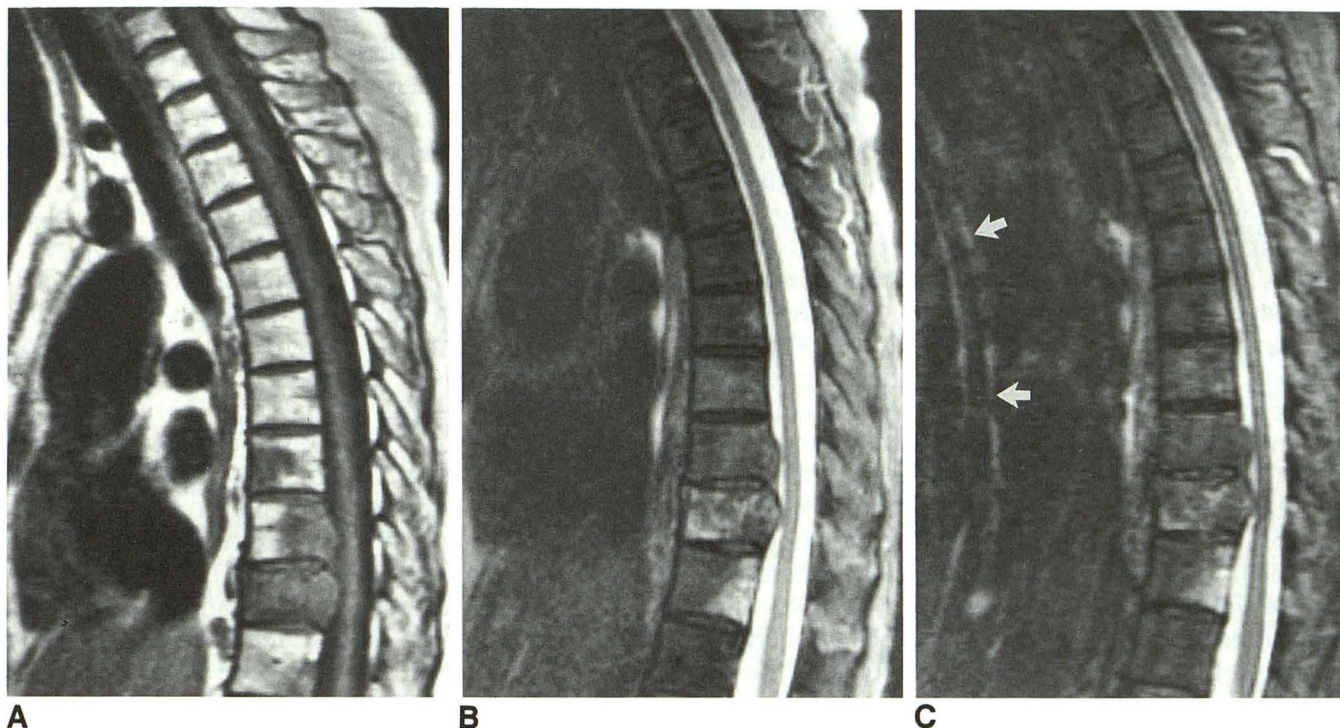


Fig. 2. A, T1-weighted fast spin-echo image of the thoracic spine in a patient with metastatic adenocarcinoma of unknown primary. Lesions are well seen, but the spinal cord shows suboptimal anatomic detail. B, T2-weighted fast spin-echo image with fat suppression shows improved cord detail. Posterior extent of lesions is well seen. C, STIR fast spin-echo image with identical findings. Note bright cerebrospinal fluid-related artifact (*arrows*).

Despite the good conspicuity of most vertebral lesions on T1-weighted fast spin-echo images, we feel that they should be supplemented with additional pulse sequences in cases of suspected vertebral metastases. Such additional sequences may be useful for evaluating intrinsic cord lesions, which may not be seen on T1-weighted fast spin-echo images, and for differentiating degenerative changes from metastatic lesions. Also, lesions may be well seen on one sequence but poorly seen or not seen at all on another, as in one case of lymphoma which was nearly isointense to normal marrow on T1-weighted images, but well seen on T2-weighted and STIR images. Although this was not a common occurrence in our series (4 of 42 lesions were seen on only one sequence but not on either of the other sequences), the consequences may be significant for the individual patient if a small number of lesions or a single lesion is present. In particular, small lesions (less than 1 cm) were missed in three of our four discordant cases. Also, in our series, metastases to the posterior elements or epidural space were often more conspicuous on T2-weighted fast

spin-echo or STIR fast spin-echo than on T1-weighted fast spin-echo sequences, offering additional evidence that T1-weighted sequences should be supplemented with T2-weighted images using fat suppression.

In general, lesion margins appeared sharper on T1-weighted fast spin-echo images than on T2-weighted fast spin-echo images. This may be related, in part, to the sensitivity of T2-weighted sequences to associated marrow edema around the periphery of the lesion, with associated loss of sharpness. The more sharply demarcated appearance of lesions on T1-weighted fast spin-echo images may also help to explain why small lesions (less than 1 cm) were more often detected on T1-weighted images.

Although motion and flow-related artifact were not significant problems in our study, T1-weighted fast spin-echo images demonstrated increased noise over the other two sequences. This was manifested in some cases by an indistinct margin to the cord (Fig 2A).

In previous studies, T2-weighted conventional spin-echo images have not been found to be

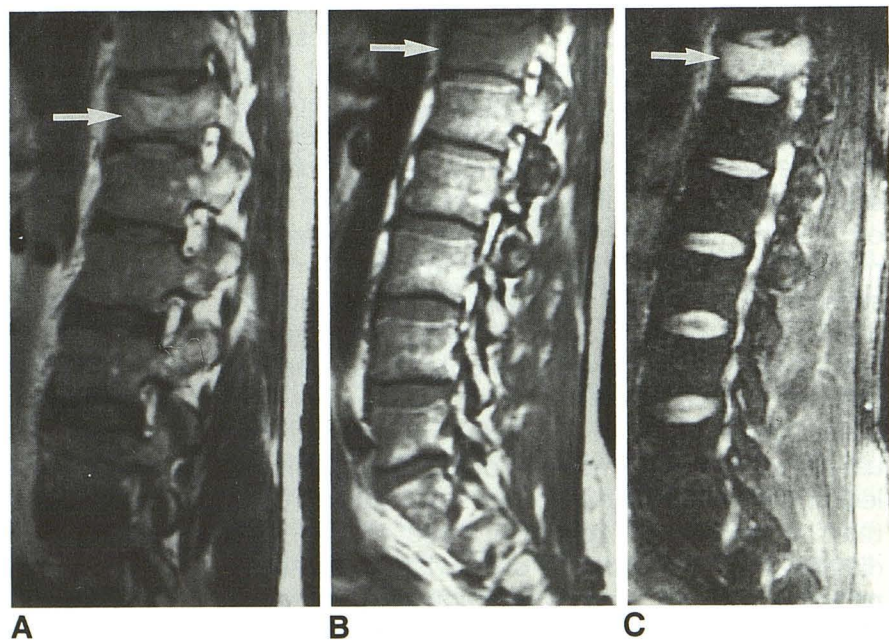
useful for the detection of vertebral metastases (9–12). Because fat has a relatively long T2, vertebral marrow appears somewhat hyperintense on T2-weighted images, particularly in older patients with fatty marrow replacement. For this reason, marrow metastases (usually hyperintense on T2-weighted images) are often poorly seen against a background of hyperintense fatty marrow. The problem is compounded on T2-weighted fast spin-echo images, in which fat appears very bright even on heavily T2-weighted images. In our one case in which fat suppression was not applied, an isolated metastatic marrow lesion appeared nearly isointense to normal marrow (Fig 3A). It is interesting to note that this same lesion was nearly isointense to normal marrow on the T1-weighted fast spin-echo sequence (Fig 3B), whereas the lesion was clearly detected on the T2-weighted sequence with CHESS fat suppression pulse (Fig 3C). By applying a presaturation frequency selective pulse to the fat resonance, fat in the vertebral marrow may be rendered dark, resulting in high conspicuity of bright adjacent metastatic lesions.

Overall, excellent images were obtained in two to three minutes, with very little motion- or flow-related artifact. Anatomic detail, in particular the spinal cord, appeared sharper on T2-weighted fast spin-echo images than on the other two sequences (Fig 2B). However, T2-weighted fast spin-echo images showed less complete fat suppression than STIR images (Table 1), though it is possible that more complete fat suppression

could be obtained on T2-weighted fast spin-echo images by manipulating the presaturation pulse. Other methods, unique to fast spin-echo-type sequences, may also be used to increase fat suppression further in T2-weighted fast spin-echo sequences (13).

In STIR imaging, fat is rendered dark through the application of an inversion recovery pulse approximately 100 to 140 msec before the excitation pulse of the imaging sequence. By selecting an inversion time so that the fat magnetization lies in the transverse plane at the time of the excitation pulse, fat signal is suppressed. The additive T1 and T2 contrast of STIR sequences often makes lesion conspicuity quite high. Conventional STIR sequences have proved useful in many clinical settings (9–12). However, use of this sequence has been limited because of long scan times and artifact (motion- and flow-related), particularly at high field strength (12). Our study demonstrated that lesion conspicuity for STIR fast spin-echo images is lower overall than for T2-weighted fast spin-echo images with fat suppression, though the difference between contrast-to-noise ratios was not statistically significant. In addition, STIR fast spin-echo images did not appear as sharp as T2-weighted fast spin-echo images, and appeared more prone to motion- and flow-related artifacts, particularly in the thoracic spine (Fig 2C). Problems with motion and flow-related artifact should be substantially reduced with the addition of gradient moment nulling, though this has not as yet been imple-

Fig. 3. A, T2-weighted fast spin-echo image without fat suppression of the lumbar spine in a 53-year-old patient with metastatic melanoma shows marrow lesion appearing only slightly higher in signal intensity than adjacent normal marrow. In an older patient, normal marrow would be expected to show even higher signal intensity because of fatty replacement. B, T1-weighted fast spin-echo image shows even less conspicuity of the marrow metastasis. C, T2-weighted fast spin-echo image after application of CHESS fat suppression now demonstrates high conspicuity of the marrow lesion.



mented. The use of a long repetition time (3000–4000 msec) for both T2-weighted fast spin-echo and STIR fast spin-echo sequences, feasible because of the rapid imaging times of fast spin-echo, permitted excellent cord detail and rendered cerebrospinal fluid very bright adjacent to the cord.

Our study was limited by the lack of direct comparison with conventional spin-echo images. Because of imaging time constraints, only three sequences were performed at the level of interest; the purpose of our study was rather to compare directly the various fast spin-echo pulse sequences that might prove efficacious in the detection of spinal metastases. However, comparison with conventional spin-echo sequences is clearly warranted. Fast spin-echo must also demonstrate conspicuity similar to conventional spin-echo before fast spin-echo sequences can reliably replace conventional spin-echo for the detection of spinal metastases.

In conclusion, fast spin-echo sequences appear promising for the detection of vertebral metastases. Images may be obtained far more rapidly than conventional spin-echo images, while retaining spin-echo contrast features. Although other sequences (gradient-echo, conventional STIR) also appear promising for the detection of vertebral metastases (9–12), fast spin-echo may provide a feasible alternative to conventional spin-echo imaging. STIR fast spin-echo sequences may become more useful with the addition of gradient moment nulling. At present, however, we feel that T1-weighted and T2-weighted images with fat suppression are the most useful fast spin-echo sequences for detection of vertebral metastases.

Acknowledgments

We thank individuals from the group at Yale including Todd Constable, Gordon Sze, and Robert Smith for providing us with the STIR fast spin-echo sequence.

References

1. Hennig J, Naureth A, Friedburg H. RARE imaging: a fast imaging method for clinical MR. *Magn Reson Med* 1986;3:823–833
2. Mulkern RV, Wong STS, Winalski C, Jolesz FA. Contrast manipulation and artifact assessment of 2D and 3D RARE sequences. *Magn Reson Imaging* 1990;8:557–566
3. Melki PS, Mulkern RV, Panych LP, Jolesz FA. Comparing the FAISE method with conventional dual echo sequences. *J Magn Reson Imaging* 1991;1:319–326
4. Jones KM, Mulkern RV, Mantello MT, et al. Evaluation of brain hemorrhage: comparison of fast spin-echo and conventional dual spin-echo images. *Radiology* 1992;182:53–58
5. Jones KM, Mulkern RV, Schwartz RB, Oshio K, Barnes PD, Jolesz FA. Fast spin-echo imaging of the brain and spine: current concepts. *AJR Am J Roentgenol* 1992;158:1313–1320
6. Ahn SS, Mantello MT, Jones KM, et al. Rapid MR imaging of pediatric brain using fast spin-echo (fast spin-echo) technique. *AJNR Am J Neuroradiol* 1992;13:1169–1177
7. Oshio K, Jolesz FA, Melki PS, Mulkern RV. T2-weighted thin-section imaging with the multislab three-dimensional RARE technique. *J Magn Reson Imaging* 1991;1:695–700
8. Allerhand A. Analysis of Carr-Purcell spin-echo NMR experiments on multiple-spin systems. I. The effect of homonuclear coupling. *J Chem Phys* 1966;44:1–9
9. Stimac G, Porter B, Olson D, Gerlach R, Genton M. Gadolinium-DTPA-enhanced MR imaging of spinal neoplasms: preliminary investigation and comparison with unenhanced spin-echo and STIR sequences. *AJNR Am J Neuroradiol* 1988;9:839–946
10. Shuman WP, Patten RM, Baron RL, Liddell RM, Conrad EU, Richardson ML. Comparison of STIR and spin-echo imaging at 1.5T in 45 suspected extremity tumors: lesion conspicuity and extent. *Radiology* 1991;179:247–252
11. Shuman WP, Baron RL, Peters MJ, Tazioli PK. Comparison of STIR and spin-echo MR imaging at 1.5T in 90 lesions of the chest, liver and pelvis. *AJR Am J Roentgenol* 1989;152:853–859
12. Jones KM, Unger EC, Granstrom P, Seeger JF, Carmody RF, Yoshino M. Bone marrow imaging using STIR at 0.5T and 1.5T. *Magn Reson Imaging* 1992;10:169–176
13. Higuchi N, Hiramatsu K, Mulkern RV. A novel method for fat suppression in RARE sequences. *Magn Reson Med* 1992;27:107–117