

# Use of a Doppler Guide Wire for Intravascular Blood Flow Measurements: A Validation Study for Potential Neurologic Endovascular Applications

John C. Chaloupka, Fernando Viñuela, Carolyn Kimme-Smith, John Robert, and Gary R. Duckwiler

**PURPOSE:** To conduct a validation study of a Doppler guide wire for potential neuroendovascular applications. **METHODS:** A 12-MHz, 0.018-inch Doppler guide wire was evaluated in eight swine under various blood flow conditions using two types of in vivo cerebrovascular models (physiologic and arteriovenous shunting). Flow conditions were mechanically and pharmacologically altered. Doppler average peak velocity was compared with volumetric blood flow, and flow profile corrections were calculated and analyzed. Qualitative aspects of the Doppler guide wire spectra were also assessed. **RESULTS:** Plots of average peak velocity versus volumetric blood flow showed excellent linear relationships ( $r^2 > 0.94$ ), which were maintained at high flow conditions (average peak velocity, 99 to 236 cm/sec; volumetric blood flow, 392 to 889 mL/min). Values of flow profile correction varied from 0.43 to 0.94 and showed no consistent relationship to changes in volumetric blood flow. **CONCLUSIONS:** The excellent correlation between average peak velocity and volumetric blood flow over a wide range of blood flow conditions and the additional qualitative information of the Doppler guide wire spectra establish a foundation for clinical implementation. The unpredictable variations of flow profile corrections remain obstacles for calculating volumetric blood flow based on Doppler guide wire average peak velocity.

**Index terms:** Interventional neuroradiology, experimental; Interventional instrumentation, guide wires; Cerebral blood flow; Ultrasound, Doppler; Animal studies

*AJNR Am J Neuroradiol* 15:509–517, Mar 1994

Many cerebrovascular diseases encountered in neurointerventional practice are characterized by elevated blood flow through low-resistance arteriovenous shunts. The pathophysiologic significance of these cerebral arteriovenous shunting lesions is attributable to direct and indirect effects of excessive blood flow on the brain and cerebral vasculature. Consequently, the fundamental goal of endovascular therapy of cerebral arteriovenous

shunting lesions is either to eliminate or reduce substantially the abnormal blood flow produced by arteriovenous shunting.

Hemodynamic assessment of cerebral arteriovenous shunting lesions during endovascular therapy has been done conventionally by serial angiography. Although this method may be adequate for demonstrating gross hemodynamic changes, it is insensitive to less dramatic (yet possibly significant) alterations in blood flow. Angiographic assessment of blood flow also lacks quantitative precision and reproducibility because of its highly subjective nature and its susceptibility to variability by technical factors (eg, rate of injection of contrast media, vessel selectivity, and streaming effect).

Recently, measurements of intravascular pressure have been used to infer baseline and post-therapeutic hemodynamics of cerebral arteriovenous shunting lesions during neurointerventional procedures (1–3). This method has some technical and theoretical limitations, including inaccu-

---

Received November 30, 1992; accepted pending revision March 1, 1993; revision received October 11.

This study was presented at the 30th Annual Meeting of the American Society of Neuroradiology, St Louis, Mo, June 4, 1992.

From the Interventional Neuroradiology Service (J.C.C.), Department of Radiology, Yale University School of Medicine, New Haven, Conn; and Endovascular Therapy Service (F.V., G.R.D.), Division of Ultrasound (C.K.-S.), and The Leo Rigler Laboratory (J.R.), Department of Radiological Sciences, University of California Los Angeles Medical Center.

Address reprint requests to John C. Chaloupka, MD, Interventional Neuroradiology Service, Department of Radiology, Yale University School of Medicine, 333 Cedar St, PO Box 3333, New Haven, CT 06510.

*AJNR* 15:509–517, Mar 1994 0195-6108/94/1503-0509

© American Society of Neuroradiology



racies produced by dampening and direction of blood flow and uncertainty in the precise relationship between changes in upstream intravascular pressure and downstream blood flow (4).

Quantitative methods of measuring blood flow within vessels involved with cerebral arteriovenous shunting lesions, such as transcranial Doppler, stereoscopic digital subtraction angiography, and digital video densitometry, are also currently available (5-7). Unfortunately, the practical implementation of these methods during neurointerventional procedures is extremely limited by several factors, including lack of vascular selectivity, inaccessibility of involved vasculature, and technical limitations in obtaining reliable and repeatable measurements.

Selective intravascular monitoring of blood flow within vessels involved with cerebral arteriovenous shunting lesions may be a desirable means to characterize these lesions more precisely and objectively during neurointerventional procedures. This hemodynamic information could directly impact various therapeutic decisions, such as choice of embolic materials, selection of appropriate polymerization time for liquid adhesives, need for flow arrest, and indications for staged embolization. Furthermore, selective intravascular hemodynamic monitoring could lead to refinements in assessing the impact of embolization of cerebral arteriovenous shunting lesions, which may improve staging embolizations and establish objective therapeutic end points.

A Doppler guide wire has been recently developed and validated for interventional cardiology applications (8-14). Two validation studies (8, 9) showed excellent correlation between time-averaged peak velocity measured by the Doppler guide wire and volumetric blood flow. Early clinical studies also have shown the Doppler guide wire to be useful for assessing coronary collateral flow, hemodynamic significance of marginal stenoses, and efficacy of coronary angioplasty (9-14).

Clinical use of the Doppler guide wire for neurointerventional procedures has not been previously attempted to our knowledge. Unlike its conventional use in interventional cardiology, the Doppler guide wire usually would be used for demonstration of either relative or absolute changes in volumetric blood flow in a very wide range of hemodynamic conditions. This wider hemodynamic range will be the result of marked baseline elevations and posttherapeutic fluctua-

tions in volumetric blood flow that are characteristic of cerebral arteriovenous shunting lesions. Consequently, it is anticipated that large changes in average peak velocity and significant laminar flow disturbances will be encountered, which are not usually seen in the coronary circulation.

The Doppler guide wire could be implemented for neurointerventional hemodynamic monitoring in two ways. First, the device could be used to assess relative changes in volumetric blood flow by observing parallel changes in measured average peak velocity. If a linear relationship exists between average peak velocity and volumetric blood flow, then observed changes in average peak velocity in a vessel will be directly proportional to changes in volumetric blood flow. Second, the Doppler guide wire could be used to derive absolute values of volumetric blood flow based on measurements of average peak velocity. This method has been previously described and tested (8, 9) in which volumetric blood flow is calculated from measurements of average peak velocity and internal diameter of the vessel (to calculate cross-sectional area of the vessel). This method of calculating volumetric blood flow must also take into account laminar profile of flowing blood within the vessel, because Doppler measurements of blood flow velocity are obtained from the leading edge of a flow field (which usually has a parabolic configuration) and thus systematically overestimates true average peak velocity. Without correcting for laminar flow profile, calculations of volumetric blood flow will always overestimate true volumetric blood flow. Previous studies (8, 9) have used empiric estimations of laminar flow profile to make such calculations, although it is uncertain how stable laminar profile is under a variety of different flow conditions.

Thus, a validation study was performed to compare the relationship between average peak velocity and volumetric blood flow in a wide range of flow conditions that occur in clinical neurointerventional practice. This validation study also evaluated the range and variability of laminar flow profile that may be encountered clinically in order to determine the feasibility of making accurate calculations of volumetric blood flow based on measurements of average peak velocity and vessel internal diameter.

## Materials and Methods

The Doppler guide wire (Flowwire, Cardiometrics, Mountain View, Calif) consists of a 12-MHz piezoelectric ultra-



sonic transducer mounted on the tip of a 175-cm-long flexible and steerable 0.018-inch (0.46 mm) guide wire (Fig 1). The distal flexible coil portion of the guide wire is available in 15-, 30-, and 45-cm lengths. The ultrasonic beam diverges approximately  $14^\circ$  from the axis of the transducer with a range gate depth of 5 mm and gate integration distance of 1 mm. These specifications produce an estimated axial sample diameter of 2.5 mm and sample volume of  $5 \text{ mm}^3$ . The pulse repetition frequency varies between 12–96 kHz with a burst length of 1 microsecond. The pulsed Doppler signals are processed by a real-time spectrum analyzer (Flowmap, Cardiometrics, Mountain View, Calif), using a fast Fourier transform at a rate of 100 spectra per second. The data are displayed on a scrolling gray-scale monitor in standard spectral wave form format. On-line computation of time-averaged spectral peak velocity, instantaneous maximal peak velocity, pulsatility index, and other spectral-derived parameters are also available.

The experiments were performed in accordance with guidelines for the use of laboratory animal subjects in research by the University Chancellor's Animal Research Committee and the National Institutes of Health. Eight red Duroc swine were first sedated with intramuscular diazepam (0.5 mg/kg) and ketamine (20 mg/kg). After intubation, general anesthesia was induced and maintained with continuous inhalation of 1% to 1.5% halothane.

Each experiment consisted of creating one of the following two types of in vivo validation models per swine. The first model was created to simulate a range of physiologic blood flows within a normal vascular circuit. This was accomplished by surgically exposing a long segment of the common carotid artery to which an ultrasonic volumetric blood flow probe (Transonic Systems, Ithica, NY) was externally applied. The ultrasonic volumetric blood flow probe uses a novel method of volumetric integration of pulse transit time to measure volumetric blood flow (15). The probe used for this study operates at 2.4 MHz and is precalibrated and self-zeroing. A thumb-screw arterial clamp was applied in the distal common carotid artery to vary volumetric blood flow measured by the probe ( $\text{VBF}_p$ ).

A second model was created to simulate blood flow conditions produced by an arteriovenous shunt. This objective was accomplished by a similarly constructed model with the addition of an arteriovenous fistula. Using standard microsurgical technique, a side-to-side anastomosis was created between the common carotid artery and the exter-

nal jugular vein with a running 7-0 prolene suture. The volumetric blood flow probe was placed at least 1 cm proximal to the fistula and the tip of the Doppler guide wire placed 1 cm proximal to the probe.

In both models a 4-F guiding catheter was used for selective catheterization of the most proximal portion of the common carotid artery. A calibration marker was placed adjacent to the segment of the common carotid artery that was studied by the Doppler guide wire. Anticoagulation was induced (heparin 8000 U initially followed by 1000 U/h, intravenous bolus). Flow conditions in both models were also changed by infusion of intravenous dopamine (10–20 mcg/kg per min) and cross-clamping the contralateral common carotid artery. Angiography was performed just before and after each Doppler guide wire measurement to confirm proper positioning of the Doppler guide wire and provide a means for measurement of vessel internal diameter in a single projection plane.

The Doppler guide wire was advanced 2.5 cm beyond the guiding catheter to ensure that disturbances in laminar flow produced by the 4-F catheter were minimized within the common carotid artery (this distance is greater than the ideal theoretical requirement of 20 diameters needed for reestablishment of undisturbed laminar flow from a point of its interruption). Similarly, the 5-mm range gate depth used by the Doppler guide wire transducer was within 10 diameters for minimizing disturbances of laminar flow produced by the Doppler guide wire itself.

For the first six experiments, Doppler guide wire average peak velocity was compared to  $\text{VBF}_p$ . Experiments 1 and 2 used the low flow model, and experiments 3 to 6 used the high-flow arteriovenous fistula model. Measurements were obtained by intermittent switching of the volumetric blood flow probe and Doppler guide wire to eliminate cross-coupling interference. When stable flow conditions were achieved by any of the above-described maneuvers, 10 measurements of average peak velocity were obtained within a 30-second interval, which was immediately followed by 10 measurements of  $\text{VBF}_p$  within an additional 30-second interval. These consecutive measurements of average peak velocity and  $\text{VBF}_p$  obtained over a 1-minute period of time were then averaged to obtain a set of data points for regression analysis.

Measurements of average peak velocity (APV) and  $\text{VBF}_p$  were compared for each experiment by use of linear regression (Statview 512+, Abacus Concepts, Calabasas, Calif.)

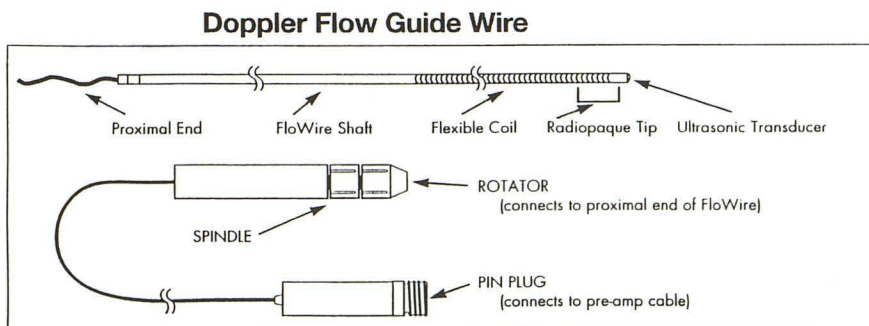


Fig. 1. Diagram of Doppler guide wire.



in which  $r^2$ , slope, and y-intercept were calculated. A calculated volumetric blood flow ( $VBF_c$ ) was obtained from Doppler guide wire measurements of average peak velocity and vessel internal diameter based on single plane angiography, using the following formula:  $VBF_c = \text{average peak velocity} \times \pi(D/2)^2$ . This formula incorrectly assumes the existence of plug flow for the calculation of  $VBF_c$ . An empiric correction for laminar flow profile (ideal value of 0.5) was intentionally not used. Rather, the  $VBF_c$  was compared with  $VBF_p$  ( $VBF_p/VBF_c$ ) to derive directly a laminar flow profile coefficient for each pair of measurements. It was our intention to see if the laminar flow profile coefficient significantly varied in these experiments. Both linear and polynomial regression analysis were used to compare  $VBF_p$  with the laminar flow profile coefficient for each experiment.

A separate study using another arteriovenous fistula model (experiment 7) was performed to compare simply both qualitative and quantitative Doppler spectra derived from the Doppler guide wire with that obtained from an external duplex scanner. A duplex color Doppler device (Ultramark 9) with a 5.0-MHz linear-array transducer was used. To ensure that the same segment of the common carotid artery was studied by both systems, duplex color Doppler imaging was performed with the Doppler guide wire in position. This allowed the tip of the Doppler guide wire to be used as a marker for proper sampling by the duplex color Doppler device. Optimal visualization of the common carotid artery segment was first achieved with color flow imaging and was immediately followed by acquisition of Doppler spectra with the duplex color Doppler device and Doppler guide wire. Intermittent switching of the devices was necessary to avoid cross-coupling interference. Maximum peak velocities were compared in this experiment because these measurements were more readily available from the duplex color Doppler device. As in the previous experiments, volumetric blood flow was varied with the thumb-screw arterial clamp.

A final experiment (experiment 8) was performed using an arteriovenous fistula model in which hemodynamic conditions were varied to study the qualitative and semi-quantitative spectral data from the Doppler guide wire. This was accomplished by temporary clamping of the proximal and/or distal portions of the external jugular vein and the previously described mechanical and pharmacologic manipulations used in the other models. These manipulations caused predictable qualitative changes in downstream resistance, flow disturbance, and flow profile.

An estimate of the effective downstream vascular resistance was calculated as follows. Intravascular pressure measurements ( $P$ ) were made proximally in the common carotid artery at the location of the tip of the Doppler guide wire and distally within the segment of the internal jugular vein immediately adjacent to the fistula site. The effective downstream vascular resistance was then calculated using the formula  $\Delta P/VBF_p \times 1333$  (to convert to units of dyne-sec/cm<sup>3</sup>). These calculated values of effective downstream vascular resistance were then compared with the inferred relative changes in effective downstream vascular resist-

ance reflected by changes in pulsatility index and acceleration measured by the Doppler guide wire. On-line computation of changes in pulsatility index (CPI) was performed using the formula:  $CPI = MPV - \text{minimum instantaneous peak velocity/average peak velocity over a period of two cardiac cycles}$ . The acceleration was an on-line measurement of the slope of temporal change in instantaneous peak velocities for a given maximum pulse velocity (ie, the acceleration of upstroke in m/sec<sup>2</sup>). It was anticipated that decreases in effective downstream vascular resistance are usually associated with decreases in change in pulsatility index and acceleration.

The relative degree of flow disturbance (turbulent blood flow) was first characterized by duplex color Doppler and direct visualization through the venous pouch of the arteriovenous fistula. Increases in flow disturbance were expected to be reflected by the presence of Doppler guide wire spectral broadening. Finally, changes in flow profile were assessed by changes in the instantaneous frequency shift spectrum, in which the loss of low-frequency spectra were expected to correspond to a flattened parabolic flow profile.

## Results

Baseline measurements of the common carotid artery internal diameter for each experiment were as follows: experiment 1, 3 mm; experiment 2, 3 mm; experiment 3, 3.5 mm; experiment 4, 3.3 mm; experiment 5, 5 mm; experiment 6, 2.9 mm. During the acquisition of the various sets of average peak velocity and  $VBF_p$  in each experiment, no measurable change in the single-plane internal diameter of the common carotid artery occurred. The averaged values of average peak velocity and  $VBF_p$  for each data set showed very small standard errors (less than  $\pm 2\%$ ) which were neglected for regression analysis. In two of the high-flow models (experiments 3 and 6) some difficulty was encountered in achieving incremental stable flow conditions. Consequently, fewer data sets of average peak velocity versus  $VBF_p$  were obtained.

Plots of  $VBF_p$  versus average peak velocity in each experiment showed excellent linear relationships (Fig 2), with  $r^2$  values varying from 0.94 to 0.998. Only at extremely low flow states ( $VBF_p < 10$  mL/min) was there a trend toward considerable disparity between  $VBF_p$  and average peak velocity. The linear relationship between  $VBF_p$  and average peak velocity was maintained at highly elevated flow conditions in the arteriovenous fistula models, in which  $VBF_p$  varied from 392 to 889 mL/min (vessel internal diameter, 2.5 to 3.2 mm), with corresponding average peak velocity varying from 99 to 236 cm/sec. In a



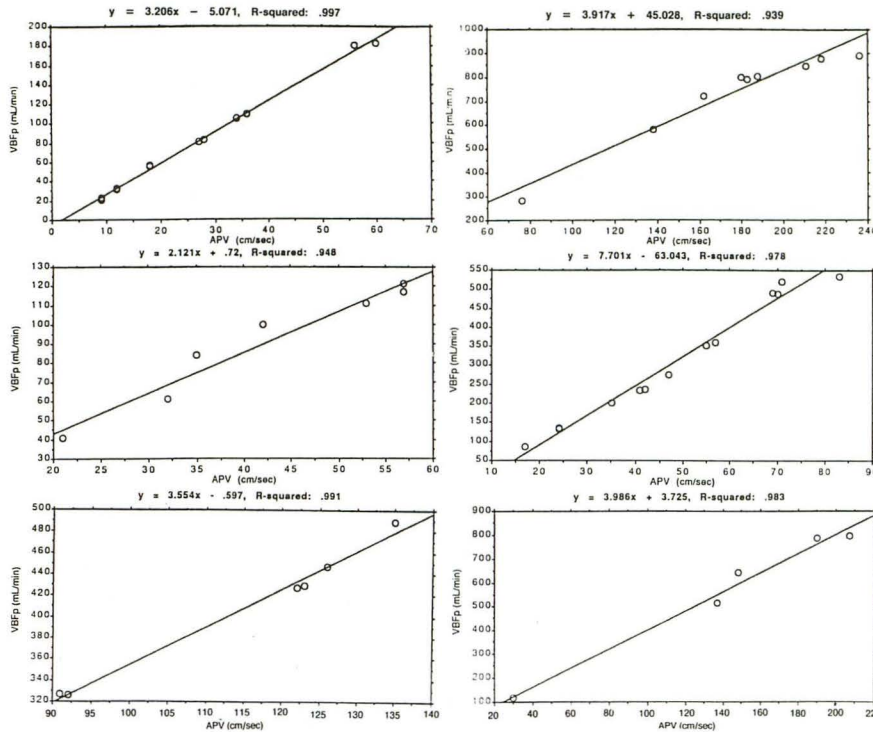


Fig. 2. Linear regression plots of VBF<sub>p</sub> and average peak velocity (experiments 1 to 3 in the first column, 3 to 6 in the second column).

separate arteriovenous fistula model used for assessing qualitative and semiquantitative spectral data from the Doppler guide wire, a maximal stable VBF<sub>p</sub> of 1100 mL/min produced a corresponding average peak velocity of 303 cm/sec in a 3-mm common carotid artery.

As expected, the VBF<sub>c</sub> was always greater than VBF<sub>p</sub> because of the parabolic flow profile of flowing blood. The laminar flow profile coefficient values calculated from the ratio of VBF<sub>p</sub>/VBF<sub>c</sub> varied significantly from 0.43 to 0.93. These variations occurred in both individual and different models and appeared to be unrelated to vessel internal diameter. Comparisons of laminar flow profile coefficient with VBF<sub>p</sub> using linear and polynomial regression showed a variety of different, unpredictable relationships (Fig 3).

In experiment 7 the continuous spectral display from the Doppler guide wire was similar to those generated by simultaneously obtained external duplex color Doppler of the common carotid artery at five different rates of volumetric blood flow. Measurements of maximum peak velocity with the duplex color Doppler device were 90, 180, 210, 230, and 275 cm/sec, which corresponded to values of 80, 179, 188, 246, and 249 cm/sec obtained with the Doppler guide wire, respectively. The appearance of the Doppler guide wire spectra was also very similar to that

of the duplex color Doppler at all five flow rates (Fig 4).

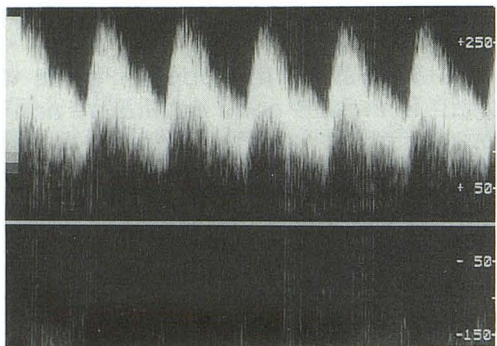
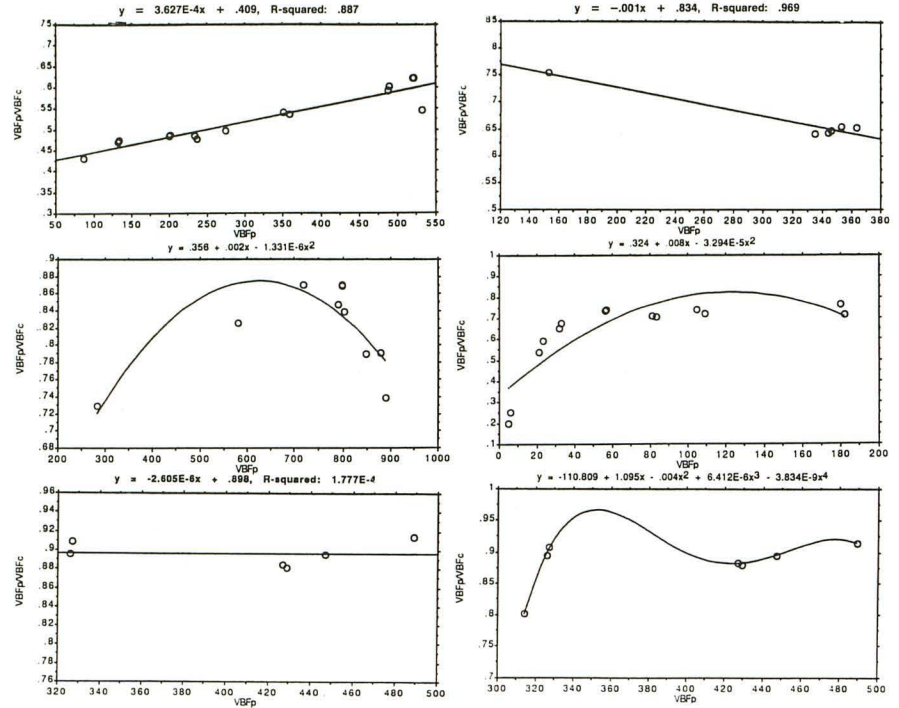
Spectral analysis of the Doppler guide wire in experiment 8 showed good qualitative and semiquantitative insight into the degree of effective downstream vascular resistance (Table 1). A consistent decline in Doppler guide wire change in pulsatility index and acceleration mirrored decreases in qualitative and quantitative estimates of effective downstream vascular resistance. Spectral analysis also provided accurate qualitative insight into changes in the nature of laminar blood flow within the arteriovenous fistula model of experiment 8. Significant disturbances in laminar blood flow were produced at higher values of VBF<sub>p</sub>, which were subjectively assessed by direct inspection and observation from real-time color flow duplex color Doppler imaging. These blood flow disturbances were nicely detected by the Doppler guide wire demonstration of spectral broadening (Fig 5A). At the highest VBF<sub>p</sub> values, the Doppler guide wire spectra showed a loss of the lower and intermediate frequency shifts, which indicated a relatively flattened parabolic flow profile seen in plug flow (Fig 5B).

## Discussion

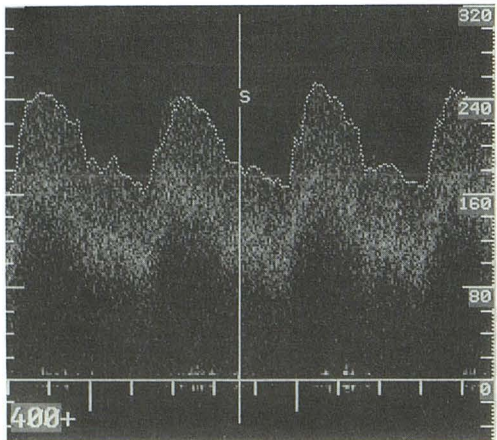
A linear relationship between average peak velocity and volumetric blood flow occurred over



Fig. 3. Linear and polynomial regressions plots of  $VBF_p$  and correction coefficient ( $VBF_p/VBF_c$ ).



A



B

Fig. 4. Example of simultaneously obtained duplex color Doppler (A) and Doppler guide wire (B) spectra.

a wide range of blood flow conditions in both types of validation models. In all regression plots there was excellent correlation, as indicated by the large  $r^2$  values ( $\geq 0.939$ ). In two experiments (3 and 6), a smaller number of data pairs were obtained because of lack of hemodynamic stability of the arteriovenous fistula models. This resulted in a skewed clustering of data pairs, which potentially produced influential points within the regression plots. These influential points could bias the apparent linear relationships observed in these experiments. This is probably not a major problem, however, because the other plots with more even distribution and larger numbers of data pairs showed comparable linearity.

Most importantly, the linear relationship between average peak velocity and volumetric blood flow was maintained in arteriovenous shunting conditions. These high-flow conditions are the most important factor that can adversely affect the performance and reliability of the Doppler guide wire.

It must be emphasized that linearity between average peak velocity and volumetric blood flow is dependent upon the assumption that no significant changes in vessel internal diameter occur between measurements: according to the principle of conservation of flow field (at equilibrium), any change in vessel internal diameter will pro-



**TABLE 1: Comparison of effective downstream vascular resistance with pulsatility index and acceleration in four flow conditions of an arteriovenous fistula model**

Flow Condition	VBF <sub>p</sub> (ml/min)	ΔP (mmHg)	Effective Downstream Vascular Resistance (dyne-sec/cm <sup>3</sup> )	Pulsatility Index	Acceleration	Average Peak Velocity (cm/sec)
A	118	9	102	1.6	18.9	30
B	508	35	92	0.81	12.0	117
C	785	43	73	0.39	9.18	189
D	1100	30	36	0.2	4.2	303

A indicates temporary clamping of the arteriovenous fistula; B, temporary clamping of the distal internal jugular vein; C, partial clamping of proximal common carotid artery with dopamine; D, unclamped arteriovenous fistula and cross-clamped contralateral common carotid artery.

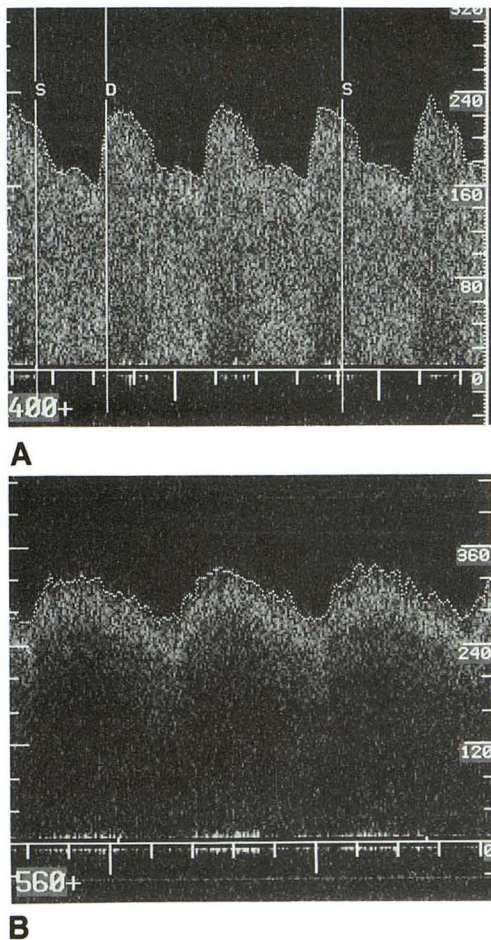


Fig. 5. A, Example of detection of disturbance in laminar blood flow in an arteriovenous fistula model by spectral broadening in the Doppler guide wire spectra.

B, Example of detection of flattening of normal parabolic flow profile in a high-flow arteriovenous fistula model by loss of lower frequency spectra.

duce an inversely proportional change in flow velocity. This could be a potential pitfall of clinical use of the Doppler guide wire, because intracra-

nial arteries may exhibit significant vasoreactivity in response to changes in blood pressure, carbon dioxide, and so forth.

Only a few studies have documented the range of blood flow velocities occurring in cerebral arteriovenous malformation feeders. Nornes et al (16, 17) reported intraoperative Doppler mean velocities of arteriovenous malformation feeders in the range of 17 to 73 cm/sec; Lindgaard et al (18) reported considerably higher values ranging from 75 to 237 cm/sec. These arteriovenous malformation feeder blood flow velocities are well within the range of Doppler guide wire average peak velocities produced in these experiments.

It is well known that VBF<sub>c</sub> consistently overestimates true volumetric blood flow because of parabolic flow profile. The correction coefficient for parabolic flow, however, is not relatively constant at 0.5 as has been often previously assumed (8, 9) but varies significantly (in this study from 0.43 to 0.94) according to undefined factors effecting flow conditions. Unfortunately, as shown in Figure 3, the correction coefficient showed no consistent relationship with average peak velocity (and thus volumetric blood flow), making it impossible simply to adjust the correction coefficient based on average peak velocity measurements. Thus, the uncertainty in the correction coefficient would lead to large unpredictable errors in VBF<sub>c</sub>, which currently makes the second proposed use of the Doppler guide wire less acceptable.

The spectral data from the Doppler guide wire correlated well with simultaneously obtained duplex color Doppler spectra, further validating the quality of the Doppler guide wire spectra. Information obtained from Doppler guide wire spectral analysis provided additional useful hemodynamic



information, such as direction of blood flow, disturbances in laminar blood flow, and effective downstream vascular resistance. As shown in Table 1, change in pulsatility index and acceleration accurately reflected relative changes in effective downstream vascular resistance. This qualitative information may be useful for providing further objective insight into the pathophysiology and clinical behavior of cerebral arteriovenous shunting lesions.

There are additional limitations of this study and the proposed clinical implementation of the Doppler guide wire. Previous validation studies (8, 9) have shown that inaccuracies in measurements of average peak velocity and its relationship to volumetric blood flow can occur in very tortuous vessels or near branches arising from a parent vessel. This can be attributed to well-known flow disturbances that occur in these situations (19). Although not addressed in the current study, the inability of average peak velocity to reflect volumetric blood flow in tortuous or branching vessels accurately can be a potential problem in some clinical cases in which increased tortuosity has occurred in a feeding pedicle of a cerebral arteriovenous shunting lesion.

Another potential limitation of the Doppler guide wire is the requirement for careful and consistent positioning of the Doppler guide wire within the central portion of a vessel to optimize signal. Thus, the comparability of Doppler guide wire measurements at different times may be suspect if the guide wire position significantly differs. Although this problem has not been systematically addressed in this study or previous validation studies, the issue of comparability and reliability of Doppler guide wire measurements may be an issue in large, tortuous, and irregularly shaped vessels (8).

For normal, essentially nontapering segments of the swine common carotid artery, we assumed cross-sectional symmetry of the internal diameter when calculating cross-sectional area. This may have introduced error in calculating  $VBF_c$  and the correction coefficient, although it is likely that these errors are systematic and would not significantly alter relative changes in the correction coefficient observed in this study.

Assuming no significant change in vessel internal diameter when single or multiple Doppler guide wire measurements are obtained is also a potential source of error when one is making inferences of blood flow based on measurements of average peak velocity. This problem can be

partly overcome by measuring the vessel internal diameter at the time of each Doppler guide wire measurement and then calculating the  $VBF_c$ . However, this is not entirely satisfactory because, as demonstrated in this study, significant uncertainties in the correction coefficient may occur that can introduce errors in  $VBF_c$ . The problem of vessel internal diameter change may not be serious in actual clinical practice, however; it is well known that pedicles supplying cerebral arteriovenous shunting lesions often lose much of their normal vasomotor reactivity.

The size and proximal shaft stiffness of the 0.018-inch Doppler guide wire limits its overall utility for neurointerventional applications; it cannot be used with commonly used microcatheters and is unsuitable for safely navigating through the proximal intracranial arteries. The 0.018-inch Doppler guide wire is suitable, however, for use in the extracranial brachiocephalic arteries and possibly the larger posterior fossa dural sinuses. A prototype 0.014-inch Doppler guide wire has recently become available; it is compatible with the most frequently used neurovascular microcatheter (Tracker 18, Target Therapeutics, Fremont, Calif). Our laboratory has recently conducted technical feasibility and performance studies with this new Doppler guide wire and have found it to have very favorable mechanical characteristics compared with other commercially available micro-guide wires (20). Thus, far broader applications of this device may now be possible.

We believe that intravascular blood flow velocity monitoring will provide valuable hemodynamic information that can be used for more precise and detailed pretreatment characterization of cerebral arteriovenous shunting lesions. Such hemodynamic characterization may enhance our understanding of the pathophysiology of these lesions, leading to an improved ability to predict clinical behavior, prognosis, and response to therapy. Furthermore, this type of hemodynamic monitoring can be used for objective, quantitative assessment of therapeutic efficacy. This may be especially useful in situations in which staged embolization is desirable or necessary.

We envision incorporating the Doppler guide wire into the peritherapeutic hemodynamic monitoring regimen of patients undergoing various neurointerventional procedures. The Doppler spectral blood flow data derived from the Doppler guide wire will provide an added dimension of



insight into the overall conditions of a flow field system. This ability to quantify blood flow within a blood vessel in combination with intravascular pressure measurements can enable investigators to define more completely a given flow field system, because two of the three basic components of the flow equation ( $\Delta P = Q \times R$ ) will be known.

## References

1. Jungreis CA, Hortom JA, Hecht ST. Blood pressure changes in feeders to cerebral arteriovenous malformations during therapeutic embolization. *AJNR Am J Neuroradiol* 1989;10:575-577
2. Quisling RG, Mickle JP. Venous pressure measurements in vein of Galen aneurysms. *AJNR Am J Neuroradiol* 1989;10:411-417
3. Duckwiler G, Dion J, Vinuela F, Martin N, Bentson J. Intravascular microcatheter pressure monitoring: experimental results and early clinical evaluation. *AJNR Am J Neuroradiol* 1990;11:169-175
4. Chaloupka JC, Vinuela F, Duckwiler GR. Relationship of perfusion pressure to risk of hemorrhage from AVMs (letter). *J Neurosurg* 1993;78:850-851
5. Lindegaard KF, Grolimund P, Aaslid R, Nornes H. Evaluation of cerebral AVMs using transcranial Doppler ultrasound. *J Neurosurg* 1986;65:335-344
6. Fencil LE, Doi K, Chua KG, Hoffman KR. Measurement of absolute flow rate in vessels using a stereoscopic DSA system. *Phys Med Biol* 1989;6:659-671
7. Close RA, Duckwiler GR, Vinuela F. Fluid equations applied to blood flow measurement using digital videodensitometry. *Invest Radiol* 1992;27:504-509
8. Doucette JW, Corl D, Payne HM, et al. Validation of a Doppler guide wire for intravascular measurement of coronary artery velocity. *Circulation* 1992;85:1899-1911
9. Segal J, Kern MJ, Scott NA, et al. Alteration of phasic coronary artery flow velocity in humans during percutaneous coronary angioplasty. *J Am Coll Cardiol* 1992;20:276-286
10. Ofili E, Kern MJ, Tatineni S, et al. Detection of coronary collateral flow by a Doppler-tipped guide wire during coronary angioplasty. *Am Heart J* 1991;122:221-225
11. Segal J., Sheehan D, Corl PD, et al. A Doppler guidewire used to assess coronary flow during PTCA in humans (abstract). *Circulation* 1990;82 (suppl III):2470
12. Donohue TJ, Kern MJ, Aguirre FV, et al. Determination of hemodynamic significance of angiographically intermediate coronary stenoses by intracoronary Doppler flow velocity (abstract). *J Am Coll Cardiol* 1992;19:242A
13. Ofili EO, Kern MJ, Segal J, et al. Improvement of coronary flow dynamics after angioplasty: analysis by guidewire spectral Doppler (abstract). *Circulation* 1990;82 (suppl III):2796
14. Kaufman J, Rosenfield K, Pieczek A, et al. Combined intravascular ultrasound and intravascular Doppler wire provide complementary anatomic and physiologic imaging during percutaneous revascularization (abstract). *J Am Coll Cardiol* 1992;19:293A
15. Drost CJ. Vessel diameter-independent volume flow measurements using ultrasound. *Proc San Diego Biomed Symp* 1978;17:299-302
16. Nornes H, Grip A, Wikeby P. Intraoperative evaluation of cerebral hemodynamics using directional Doppler technique. *J Neurosurg* 1979;50:145-151
17. Nornes H, Grip A. Hemodynamic aspects of cerebral arteriovenous malformations. *J Neurosurg* 1980;53:456-464
18. Lindegaard KL, Grolimund P, Aaslid R, Nornes H. Evaluation of cerebral AVMs using transcranial Doppler ultrasound. *J Neurosurg* 1986;65:335-344
19. Asakura T, Karino T. Flow patterns and spatial distribution of atherosclerotic lesions in human coronary arteries. *Circ Res* 1990;66:1045-1066
20. Chaloupka JC, Vinuela F, Malanow RP, et al. Technical feasibility and performance studies of a Doppler guide wire for potential neuroendovascular applications. *AJNR Am J Neuroradiol* 1994;15:503-507