

Self-Expanding and Balloon-Expandable Stents in the Treatment of Carotid Aneurysms: An Experimental Study in a Canine Model

Ajay K. Wakhloo, Frank Schellhammer, Joost de Vries, Joerg Haberstroh, and Martin Schumacher

PURPOSE: To assess the efficacy of metal stents for the treatment of different forms and sizes of carotid aneurysms. **METHODS:** A total of 14 experimentally constructed aneurysms in dogs were treated with transfemorally placed balloon-expandable tantalum and self-expanding nitinol stents. **RESULTS:** In 10 cases, stenting produced either immediate complete occlusion of the aneurysm (n = 7) or complete delayed thrombosis after 7 to 10 days (n = 3). In two cases treated with balloon-expandable tantalum endoprostheses, repeated angiography showed a persistent aneurysmal neck with a diameter of 1 mm. No incompletely occluded aneurysms were visible after implantation of nitinol stents. Nine-month angiographic follow-up revealed maximal stenosis of the stented vessel segment of up to 40% after placement of tantalum endoprostheses. However, no more than 15% stenosis followed the deployment of nitinol stents. Histologic examination confirmed these findings. Significantly greater intimal fibrocellular tissue growth surrounded tantalum filaments than nitinol filaments, which were covered with a smooth, thin neointimal layer. In two carotid arteries a subtotal and total occlusion of the parent vessel occurred after the insertion of a tantalum and nitinol stent, respectively. No recanalization of completely occluded aneurysms or delayed migration of a stent was observed. **CONCLUSIONS:** Porous, tubular self-expanding nitinol stents may become the treatment of choice for broad-based and fusiform aneurysms of the internal carotid artery. However, blood flow dynamics of the aneurysms must be studied carefully in order to select an appropriate mesh size for complete occlusion while preserving the parent vessel. Improvements in the introducing system, stent material, and stent shape are required for simple implantation and reduction of intimal hyperplasia.

Index terms: Arteries, carotid; Aneurysm, therapeutic blockade; Interventional instrumentation, stents; Interventional neuroradiology, experimental; Animal studies

AJNR Am J Neuroradiol 15:493-502, Mar 1994

Improvements in endovascular techniques for the treatment of intracranial aneurysms with detachable balloons and microcoils have led to excellent angiographic and clinical results (1-3). However, intrinsic technical problems remain, especially for the occlusion of surgically difficult giant aneurysms. Packing of large aneurysms

with microcoils may insufficiently decrease the mass with failure to improve the existing clinical deficits (eg, oculomotor palsy caused by intracavernous giant aneurysm of the carotid artery) (Viñuela F, North American Experience in the Embolization of Intracranial Aneurysms with the GDC System, and Moret J, Endovascular Therapy of SAH and Intracranial Aneurysms with Balloons, presented at the 30th Annual Meeting of the ASNR, St Louis, Mo, May 31-June 6, 1992). As yet, there is no satisfactory endovascular treatment for fusiform aneurysms or for those aneurysms associated with stenosis of the parent vessel without occluding the latter (4). Furthermore, complete occlusion of broad-based aneurysms may be hazardous because misplaced occlusive material may enter and block the parent vessel (5, 6) (Moret J, Endovascular Therapy of SAH and Intracranial Aneurysms with Balloons).

Received September 14, 1992; accepted pending revision November 23; revision received April 13, 1993.

Presented in part at the 30th annual meeting of the American Society of Neuroradiology, St Louis, Mo, May 31-June 5, 1992.

From the Departments of Neuroradiology (A.K.W., F.S., M.S.), Neurosurgery (J.d.V.), and Experimental Surgery (J.H.), University of Freiburg, Federal Republic of Germany.

Address reprint requests to Ajay K. Wakhloo, MD, Department of Neurosurgery, State University of New York at Buffalo, School of Medicine and Biomedical Sciences, 3 Gates Cir, Buffalo, NY 14209.

AJNR 15:493-502, Mar 1994 0195-6108/94/1503-0493

© American Society of Neuroradiology

Thromboembolic complications also occur (1, 6), and neck remnants may cause regrowth (7–11). Surgical clipping of an aneurysm attempts to reapproximate the normal sides of the arterial wall. Endovascular treatment, however, leaves the defect in the elastic lining of the parent vessel. The blood pressure acting on the thrombosed part of the aneurysm, described as “water-hammer effect” (10), may cause regrowth of the neck region, which is important to the origin and progression of intracranial aneurysms (12, 13).

To examine potentially better techniques, we investigated the efficacy of metal stents for treating experimentally produced aneurysms in canines. Changes in the hemodynamics of an aneurysm and its parent vessel after insertion of a stent will be discussed.

Animals, Materials, and Methods

A total of 24 lateral aneurysms were created bilaterally in the carotid arteries of 12 Labrador dogs (body weight 17 to 28 kg) by slight modification of a method previously described (14). After a medial skin incision and isolation of the vessels, the carotid artery and the external jugular vein were anastomosed side to side with 9–0 prolene sutures. At the anastomosis the arterial wall was punched. The size of the artificially created arterial wall defect was based on the desired dimension of the aneurysmal neck. The proximal and distal parts of the external jugular vein were ligated, and the remaining pouch was detached from the parent vein. Fourteen aneurysms were selected for stenting. Two aneurysms showed early spontaneous thrombosis on control angiograms obtained 2 weeks after surgery. The remaining eight aneurysms were used for other purposes. Measurements of the 14 aneurysms were obtained from four-projection angiography (lateral, anterior-posterior, right anterior, and left anterior oblique) performed before stent implantation using the special built-in software of DSA equipment (Digitron, Siemens, Erlangen, Germany). The aneurysms had a mean volume of $1.8 \pm 1.6 \text{ cm}^3$ (mean \pm SD, range 0.07 to 5.5 cm^3) and a mean neck size of $6.0 \pm 1.9 \text{ mm}$ (range 2.5 to 9.7 mm). The volume of the aneurysm was computed employing the formula for the volume of a cylinder or spherical body. The mean diameter of the parent vessel was $3.7 \pm 0.2 \text{ mm}$ (range 3.4 to 3.9 mm).

Five single balloon-expandable tantalum (12 loops per circumference, 34.7 pores/cm² at 5 mm inner diameter, Strecker stent, Medi Tech, Boston Scientific Corporation, Watertown, Mass) and 10 self-expanding nitinol stents (heat-treated nickel-titanium alloy, 12 loops per circumference, 62.4 pores/cm² at 5 mm inner diameter, Strecker stent, Medi Tech) were implanted using a transfemoral approach. The stents were 5 mm in diameter and 25 to 30 mm in length in the expanded state. In one case two nitinol stents placed in tandem (overlapping) were required to

cover the large orifice of the aneurysm. The stents are knitted elastic, loosely connected woven loops made of a single biocompatible tantalum or nitinol filament 100 μm in caliber forming a tube (Fig 1). Ninety-nine percent pure tantalum has a greater radiopacity than nitinol, which is more flexible and adapts more easily to the vessel course. Because of alloy properties and heat treatment, nitinol stents can be compressed without losing their original shape.

Endovascular treatment was undertaken between 21 and 130 days (mean 40 days) after construction of the aneurysm. Both the construction of the carotid aneurysm and the stenting were carried out under general anesthesia. Heparin (100 IU/kg body weight) was administered before introducing the stent. After stenting and during the post-implantation follow-up period, the animals received 80 mg aspirin per day orally.

The first step of the stenting procedure was to place a 10-F teflon introducer sheath (Cook, Bloomington, Ind) surgically in the femoral artery and to attach it to a pressurized saline drop in order to preclude clot formation. For implantation the balloon-expandable tantalum and the nitinol self-expanding stents were fixed to a 5-F angioplasty catheter (balloon diameter 4 to 5 mm, length 40 mm; Schneider, Lausanne, Switzerland) by a simple crochet technique using a continuous thin nylon line which runs along the catheter shaft from tip to the proximal end. The nylon line was fixed to the catheter with small polyurethane rings.

After diagnostic angiography, a 4.5-F catheter (Cook) was replaced with the stented 5-F balloon catheter by using a 0.020-inch guide wire (280-cm gold wire, Schneider). A 60-mm piece of 9-F introducer sheath served as a cover to avoid damaging the stent during the passage through the valve of the teflon sheath. All angiographic procedures were carried out on a DSA unit, and the road mapping technique was used to precisely position the stent. After gradual retraction of the nylon line at the proximal end of the catheter, the balloon-expandable tantalum stents were firmly dilated against the arterial wall with a maximum inflation pressure of 3 to 4 atm, starting at the proximal end of the endoprosthesis. The pressure was monitored

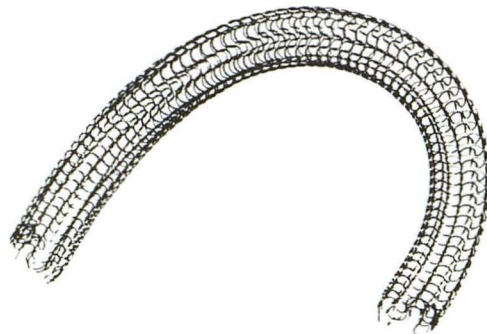


Fig. 1. Fully expanded nitinol Strecker stent with 5-mm inside diameter. The tubular self-expanding porous stent is made of heat-treated loosely woven single filaments of 100 μm diameter. The longitudinal flexibility is well appreciated.

using a pressure gauge (Medi Tech) attached to the angioplasty catheter. The nitinol endoprosthesis expanded up to the luminal diameter of the parent blood vessel starting at the proximal end after retracting the nylon line. Carotid arteriography was repeated immediately after inserting the stent and also after 7 to 10 days, 3 weeks, and 3, 6, and 9 months after the endovascular treatment. The minimal luminal diameter of the stented vessel segment and the adjacent proximal and distal parts of the common carotid artery were measured on the four-projection angiograms by two different investigators (A.K.W., F.S.). The angiography was performed with four to six frames per second and videotaped to study hemodynamic changes after stenting.

Nine stented vessel segments with approximately 5 to 15 mm of adjacent normal arterial tissue on each side were removed for histologic interval study after 3, 6, and 9 months (Table 1). Hematoxylin-eosin and elastica Van Gieson staining were used to identify fibrocellular proliferative tissue growth and to identify disruption of elastic fibers after stent placement. Additionally, the Berlin blue reaction was performed to detect hemosiderin deposits in the vessel wall, which indicate damage caused by either stent placement or balloon inflation.

Results

Except in two cases treated with tantalum balloon-expandable stents, the insertion of the prostheses produced either immediate complete occlusion of the aneurysm ($n = 7$) or complete delayed thrombosis after 7 to 10 days ($n = 3$), with the carotid artery remaining patent (Figs 2, 3, and 4). In two cases control angiograms revealed a subtotal stenosis and an occlusion of the parent vessel 1 week after insertion of a tantalum and a nitinol stent, respectively. Both aneurysms were completely occluded as confirmed histopathologically. Repeated angiography obtained after 3, 6, and 9 months showed no refilling of

TABLE 1: Summary of 14 stented aneurysms

	Balloon-Expandable Tantalum Stent (n = 5)		Self-Expanding Nitinol Stent (n = 9)	
	Angiography	Explantation	Angiography	Explantation
Week 1	5		9 ^a	
Week 3	5		8	
Month 3	5	1	8	2
Month 6	4	1 ^b	6	2
Month 9	3	1 ^c	4	2
Long-term follow-up		2 ^d		2

^a One complete occlusion of parent vessel at first angiographic control.

^b Incomplete occlusion of aneurysm.

^c Subtotal stenosis of stented segment of parent vessel.

^d One incomplete occlusion of aneurysm.

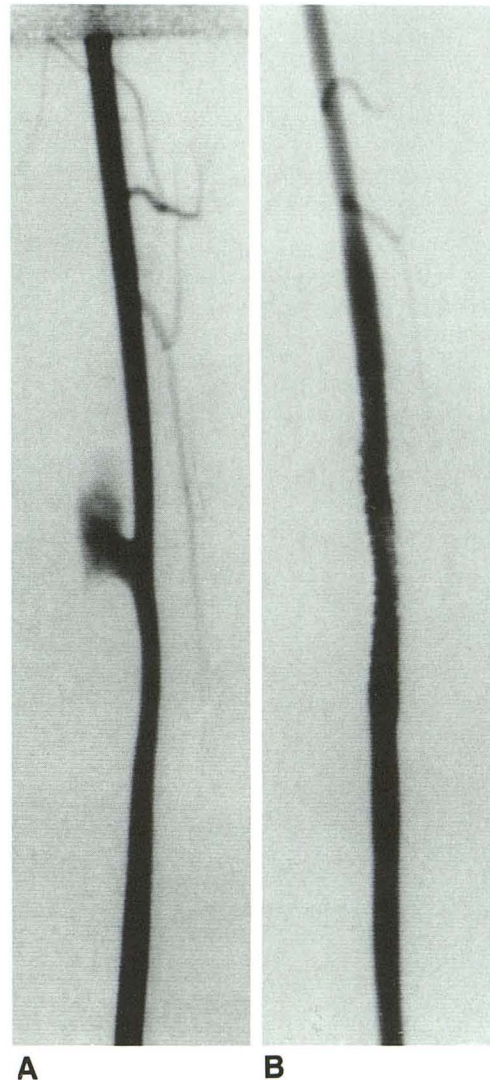


Fig. 2. Experimentally constructed lateral aneurysm of the right common carotid artery with a well-defined neck (anterior-posterior projection). Parent vessel diameter is approximately 3.9 mm. Angiogram before (A) and immediately after transfemoral placement of a balloon-expandable tantalum stent (B). Complete obliteration of the aneurysm with patency of parent vessel was accomplished. Note the slight overdilatation of the parent vessel at the stented segment and distal vasospasm.

the aneurysms. The vessel measurements on arteriograms showed a maximal stenosis of the stented parent vessel up to approximately 15% 3 weeks after implantation of a nitinol graft (Figs 3 and 5). However, balloon-expandable tantalum endoprosthesis caused a significantly higher degree of stenosis, approximately 40% (Figs 5 and 6). The narrowing was located usually at the distal rather than at the proximal portion of the stented segment. Control angiograms showed minor improvement after 6 months.

Fig. 3. A, Anterior-posterior arteriogram shows a broad-based lateral aneurysm of the right common carotid artery (approximate diameter of the parent vessel 3.8 mm).

B, Control angiogram performed immediately after introducing a heat-treated nitinol self-expanding stent (arrows) shows no significant structural change of the aneurysm.

C, Angiogram 7 days after insertion of the stent (arrow) demonstrates a complete occlusion of the aneurysm without any narrowing of the parent vessel.

D, Control angiogram after 6 months shows no recurrence. Note the slight narrowing of the vessel (arrow) caused by the thin layer of neointima covering the stent (D, see also Fig 7).

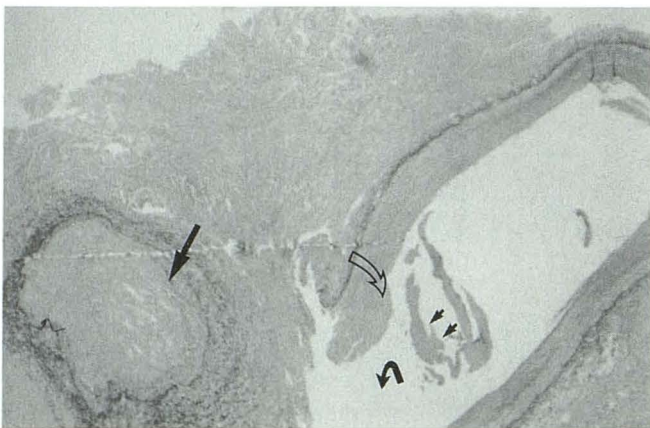
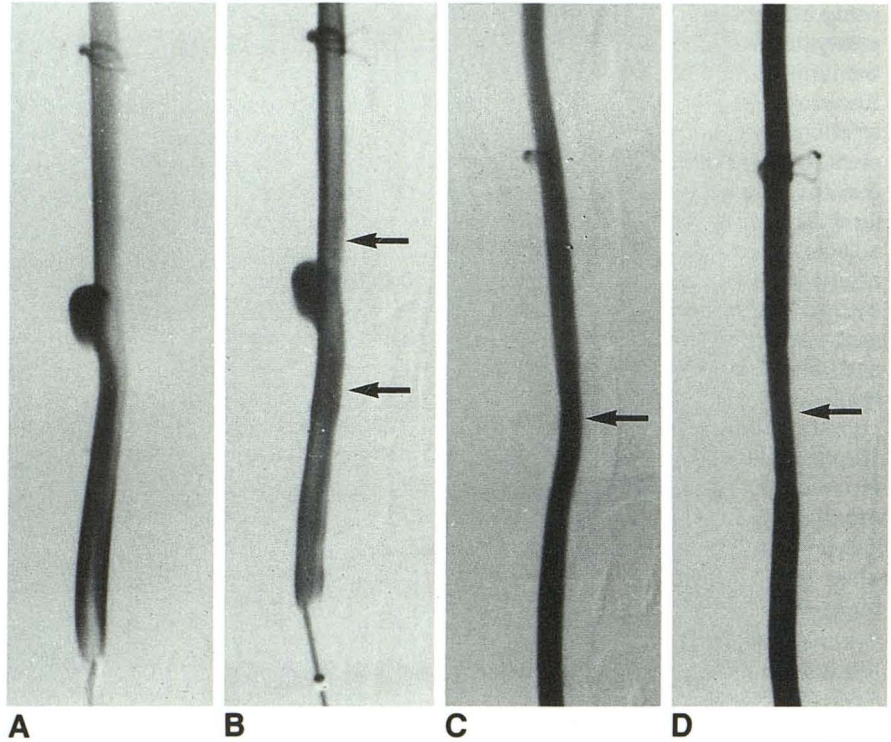


Fig. 4. Low-power cross-section photomicrograph of aneurysm treated with tantalum stent, harvested 3 months after implantation (elastica van Gieson staining). Organized thrombus formation within the aneurysm (*large straight arrow*) and intimal fibrocellular proliferation (*open curved arrow*) of the parent vessel wall. The smooth neointimal tissue covering the stent has been removed for histologic preparation (*small arrows*). Note the ostium of the aneurysm (*solid curved arrow*) corresponding to arterial wall defect at the site of anastomosis with the external jugular vein.

In none of our dogs did an immediate or delayed migration of the stent occur. Two aneurysms treated with balloon-expandable tantalum stents showed incomplete occlusion of the aneurysm with persistent aneurysmal necks approximately 1 mm in diameter. The aneurysms were

still visible on subtracted angiograms after 3 and 9 months but could not be appreciated on non-subtracted angiograms (Fig 6). Both aneurysms had approximately the same initial ostium diameter (4.3 mm and 5.5 mm) but were different in fundus size (3.6 × 3.6 × 4.2 mm and 14.0 × 3.0 × 4.0 mm). No incomplete occluded aneurysms were found in the nitinol-treated animals, and no recanalization of initially completely thrombosed aneurysms occurred.

Histologic examination confirmed the angiographic findings. Complete thrombosis of the aneurysm was present in all six harvested vessels treated with nitinol (Fig 7) and in two dogs treated with the tantalum stent (Fig 4). The tantalum filaments were encased in a much thicker intimal fibrocellular proliferative tissue layer (300 to 350 μm) than nitinol struts, which were covered with a smooth and regular neointimal layer of approximately 150 μm (Fig 7). Few hemosiderin-laden macrophages were present in the fibrotically thickened intimal wall underlying either type of stent. Also, there was no evidence of foreign-body cellular reaction around the filaments in either type of stent. The media of the stented vessel segment showed minor signs of atrophy and fibrocellular tissue growth. In almost all histopathologically studied cases, a few areas of discrete irregular intimal fibrosis of the parent

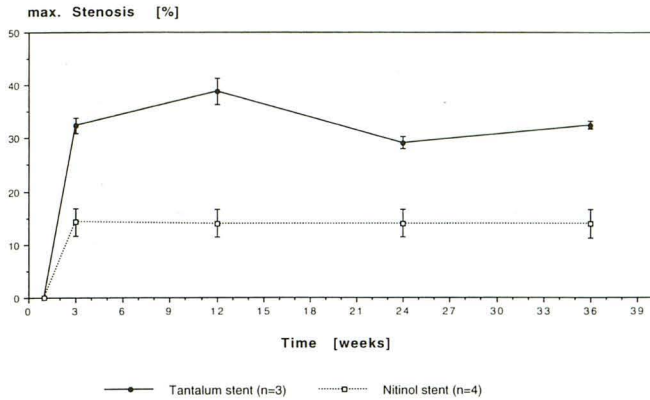


Fig. 5. Angiographic medium-term follow-up of stented common carotid arteries in dogs. Maximum observation time is 9 months (mean carotid diameter 3.7 mm, range 3.4 to 3.9 mm). Vessel measurements are based on four-plane angiography with calculation of the minimal luminal diameter of the stented arterial segment. After placement of the heat-treated nitinol self-expanding stent, maximum narrowing of the vessel is seen at week 3 ($14.3 \pm 2.6\%$) without any further progression. Implantation of tantalum balloon-expandable stents led to a maximum stenosis of $38.8 \pm 2.5\%$ after 3 months with slight improvement at 6 months control angiography (mean \pm SD).

vessel were seen 5 to 15 mm proximal to the treated arterial segment. However, these areas were inconspicuous on control angiograms. No change occurred in the luminal diameter of the proximal or distal portions of the parent vessel adjacent to the endoprosthesis.

The videotapes of control angiograms showed that stenting led to enhanced flow of contrast material toward the distal part of the vessel with decreased and delayed flow into the aneurysm. The typical inflow at the aneurysmal ostium was disturbed by the covering stent; a delayed outflow of contrast material with longer intraaneurysmal circulation was observed (Fig 8).

Discussion

Detachable balloons and microcoils have made endovascular treatment of aneurysms easier. However, reconstruction of the parent vessel harboring a fusiform-shaped or broad-based giant aneurysm remains hazardous. Furthermore, current endovascular techniques require placement of a microcatheter into the aneurysm, thus incurring the risk of rupture and dislodging thrombus (15). Surgical or endovascular occlusion of the internal carotid artery is performed in those aneurysms provided that the balloon test occlusion confirms sufficient cerebral blood supply (1, 4, 7, 16–18). The danger of delayed cerebral ischemia and stroke after permanent internal carotid artery

occlusion still remains in patients who tolerate the balloon test occlusion (19–21). Thus, the value of balloon test occlusion in predicting stroke in individual cases remains controversial. Extradural or C-3–C-5 bypass have been performed before occlusion of the internal carotid artery for treating patients harboring unclippable cavernous and petrous aneurysms (18, 19, 22). Vascular bypass at this location is time consuming, requires great microsurgical skill, and is not always successful.

In our study we investigated porous tubular-shaped vascular metal stents to treat experimentally constructed lateral aneurysms in dogs. Stents have been introduced as additional aids to treat peripheral and coronary occlusive arterial disease (23–27). These stents have proved useful in some cases of postangioplasty elastic recoil, postangioplasty restenosis, and angioplasty-induced dissection (28). Favorable results using these stents have been described for treating patients who had aortic and renal arterial dissecting aneurysms. Stents effectively obliterate the false lumen of dissection without occluding the side branches or damaging the vessel (29–31). Nylon-covered tantalum and nitinol stents have been investigated to treat both saccular and fusiform aneurysms of the aorta (32, 33).

We chose the canine model for our study because most stent studies have been carried out successfully in dogs. Results of experiments with different porous and impervious vascular grafts have shown that healing of implanted prostheses in dogs approximates human healing, which is much slower than other species such as pig, calf, and baboon (34). Other advantages to using the canine model are the size of the carotid vessel (which makes stenting feasible) and comparability with other studies (including angioplasty and endovascular treatment of experimental aneurysms with microcoils [35–37]). However, experimentally constructed lateral aneurysms in dogs infrequently demonstrate spontaneous thrombosis (35, 36), especially in aneurysms with narrow necks. In fact, early spontaneous occlusion occurred in two of our 24 aneurysms, probably because of an insufficient diameter of the anastomosis compared with the volume of the aneurysm (38). Subsequently, we modified the technique described first by Varsos et al (14) and punched the arterial wall at the anastomosis. Because the therapeutic intervention was carried out 25 to 130 days after the construction of the

Fig. 6. A, Small aneurysm of the common carotid artery (vessel diameter approximately 3.6 mm).

B, Control angiogram obtained immediately after introducing a tantalum balloon-expandable stent shows a persistent filling of the aneurysm (curved arrow). A slight vasospasm is distal to the stented segment.

C, Control angiogram after 6 months shows filling of the aneurysmal neck (straight arrow). (This was not appreciated on the nonsubtracted angiogram, D.) There is significant stenosis of the distal portion of the parent vessel with reflux of contrast material into the vertebral artery (open curved arrow). Histologic findings confirm increased intimal fibrosis, although no over-dilatation is seen on the initial angiogram. Note second tantalum stent placed in the left carotid artery (straight open arrow).

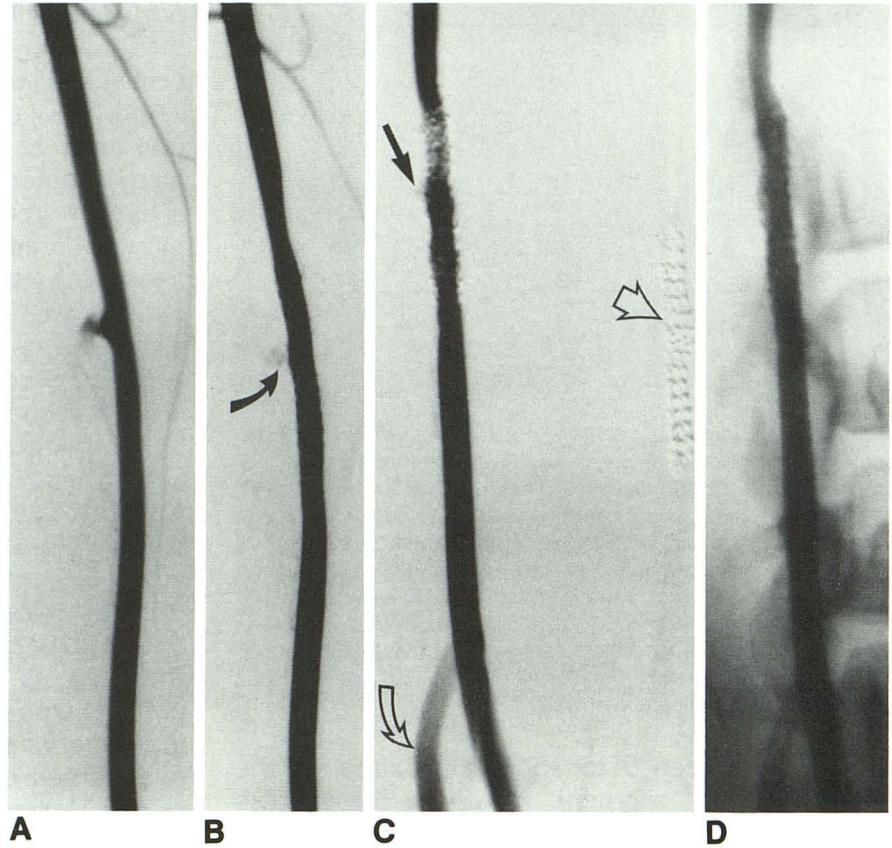
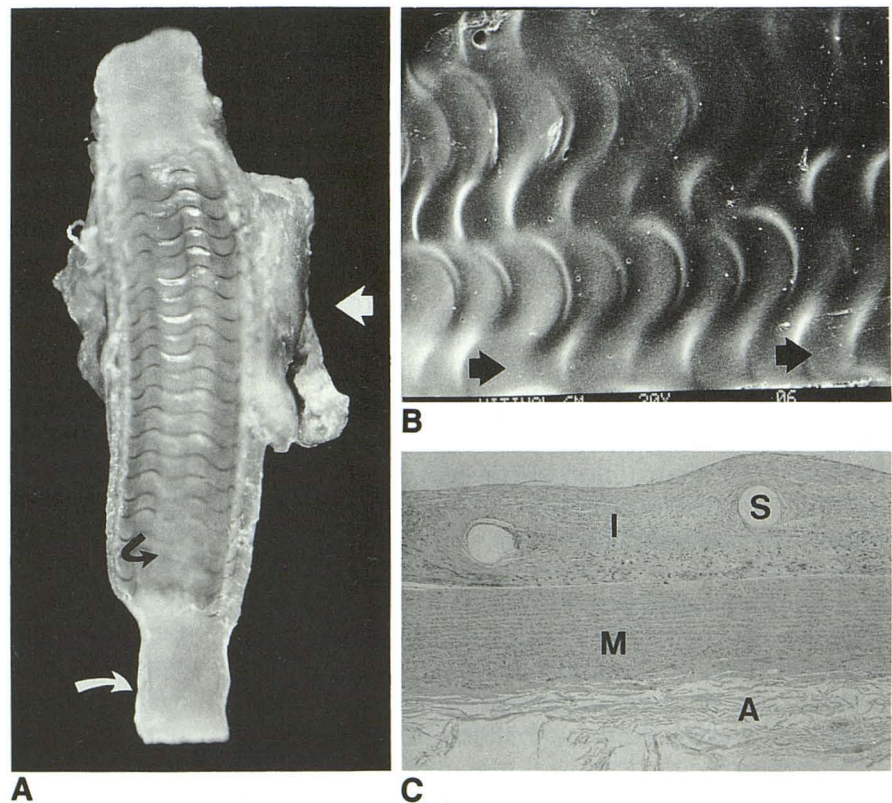


Fig. 7. Longitudinal section of a formaldehyde-fixated common carotid artery with thrombosed and organized lateral aneurysm (short arrow). The vessel (original diameter approximately 3.8 mm) was harvested 6 months after implantation of a heat-treated self-expanding nitinol stent (5-mm diameter in fully expanded state). A thin intimal fibrocellular tissue is covering the struts (curved black arrow). There is a markedly thickened vessel wall in the stented portion including the ostium of the aneurysm because of intimal proliferation. (Note the artificial reduction of the nonstented vessel segment after resection and fixation compared with the treated rigid part, curved white arrow).

B, Scanning electron photomicrograph of a carotid artery harvested 6 months after nitinol stent placement demonstrates the flow-induced macroscopic architecture of the neointima (original magnification $\times 20$).

C, Transverse section of a common carotid artery 6 months after implantation of a nitinol stent (hematoxylin and eosin stain, original magnification $\times 25$). I indicates intima; M, media; A, adventitia; S, empty space corresponding to stent filaments. Thickness of intima covering the filaments is approximately $80 \mu\text{m}$ and between the wires $200 \mu\text{m}$ (range 35 to $250 \mu\text{m}$, mean $120 \mu\text{m}$, SD $62.95 \mu\text{m}$).



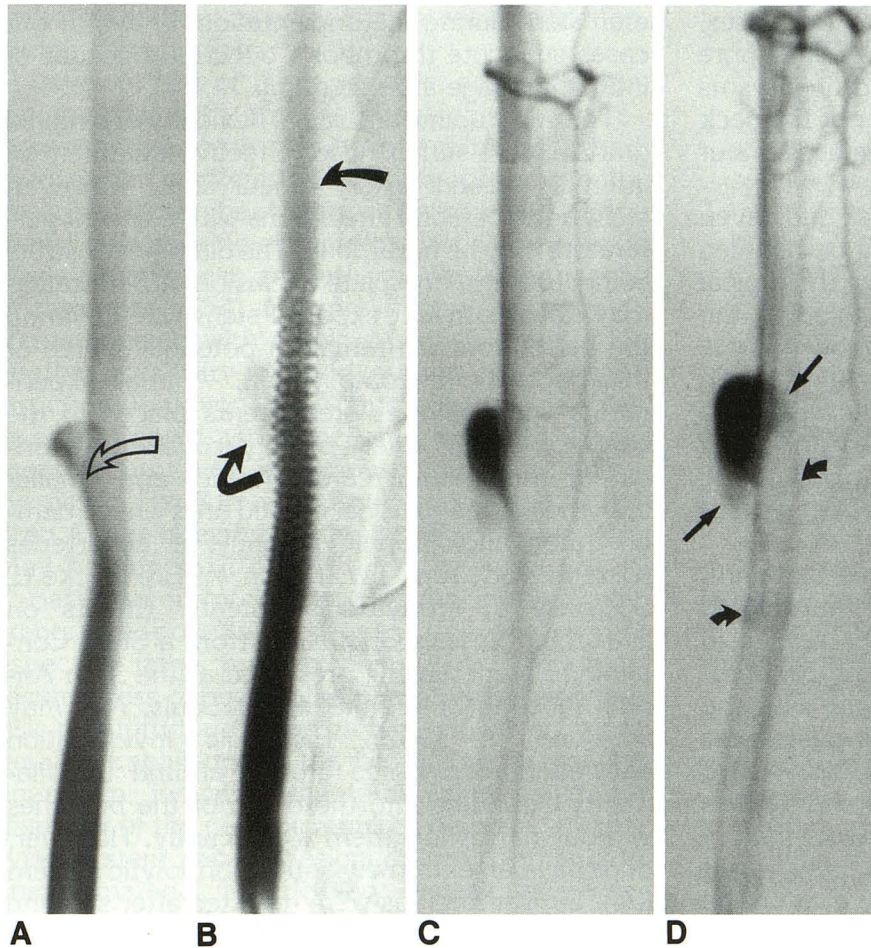


Fig. 8. Right common carotid angiograms (6 frames per second) before and after deployment of a nitinol self-expanding stent in a dog.

A, Early phase in angiogram demonstrates typical flow pattern in the aneurysm and parent vessel with inflow at the distal part of the ostium (*open arrow*).

B, By bridging the aneurysm neck with the stent, flow is diverted toward the distal part of the parent vessel (*arrow*) with decreased (channeling effect of the stent) and disturbed inflow. The inflow zone is shifted toward the proximal part of the ostium (*curved arrow*). Late-phase carotid angiogram shows delayed outflow of contrast material (*straight arrows*) after placement of prosthesis (C before and D after stenting). Note part of the contrast material trapped in filaments protruding into the vessel (*small curved arrows*).

aneurysm, a spontaneous thrombosis during the endovascular intervention seems unlikely.

In most of our cases, complete ablation of the carotid aneurysm occurred after the covering of the aneurysm orifice with a stent ($n = 10/14$). From analyzing our videotaped angiograms we determined that stents seem to induce a change in the typical flow pattern in the aneurysm and parent vessel, which may encourage thrombosis of the aneurysm. The typical inflow zone at the distal wall of the lateral aneurysm neck as stated in previous reports (13, 39, 40) is disturbed by the mesh of the endoprosthesis. The endovascular prosthesis, by bridging the aneurysm neck, directs the blood toward the distal part of the parent vessel, thus reducing the flow into the aneurysm (blood diversion or channeling effect). Stenting the ostium, however, also reduces the outflow (blood trapping). These hemodynamic changes decrease the blood circulation, the aneurysm inside which ultimately may promote formation of an aneurysmal clot.

Another factor that may promote occlusion of the aneurysm is formation of thrombus around the struts of the stent including those parts covering the orifice. The net surface charge of metals commonly used for vascular stents is electropositive, and most blood particles have a net negative surface charge. Because of a thin layer of inert tantalum pentoxide (Ta_2O_5), however, tantalum stents are negatively charged and repel platelets. This property is lost when tantalum turns electropositive after contact with electrolytic solutions and air (41). Subsequently plasma proteins are attracted and cover the filaments with a 5- to 20-nm layer of fibrinogen in a few seconds (42). Nevertheless, for complete occlusion of aneurysms to be achieved, the hemodynamic parameters such as flow velocity and direction, and the diameter of the neck and the location, must be studied carefully for proper selection of the stent. A relatively coarse network of the tantalum endoprosthesis in relation to the volume of the aneurysm and its neck diameter may be why complete obliteration of the aneu-

rysm did not occur with this stent in two cases. In contrast, the nitinol stent has a greater pore density. Both incompletely occluded aneurysms did not differ significantly in diameter of the neck and size of the aneurysm from others used in our study.

Wall shear stress at the proximal and, even more so, at the distal neck (13) may be reduced by stent placement by breaking down the typical flow pattern without completely occluding the aneurysm. This will impact considerably on progression. Additionally, the thin layer of fibrocellular tissue covering the stent, especially those parts over the ostium of aneurysm, may strengthen the proximal and distal parts of the neck as well as the adjacent parts of the parent vessel.

Compared with balloon-expandable tantalum, recently developed self-expanding heat-treated nitinol endoprosthesis showed better results in treating aneurysms and induced less intimal fibrosis. These observations are consistent with the recently published results of placing stainless steel stents in swine iliac arteries (43). Proliferative reactions were more remarkable in the vessels containing the balloon-expandable stents than in the self-expanding prosthesis. This may result from intimal-medial injury caused by dilating the stent toward the arterial wall (44–46). Other factors such as poor distal blood flow as seen in small arteries increases the amount of thrombus deposit on the stent and the danger of spontaneous occlusion, unlike in large vessels such as the iliac artery (24, 44, 47, 48). Most of the occlusions are documented within the first 14 days after implantation. Hence, many investigators recommend concomitant anticoagulation during the stenting with heparin and continuation with low-dose aspirin (47). We adopted this scheme and treated the dogs with heparin and aspirin. Slight improvement of the stenosis was documented on control angiograms after 6 months. This has been observed in animal experiments with tantalum and stainless steel stents placed in the aorta, common iliac artery, and the coronary artery (49, 50). The thickest neointimal build-up was found at 8 weeks, which then decreased at 26 weeks after completion of the reparative process.

In many of our histologic investigations a few areas of discrete intimal fibrosis of the parent artery proximal to the stented segment were seen. This may reflect intimal injury caused by the balloon catheter or by the surface of the uncov-

ered stent during the implantation. In two of our cases subacute thrombosis occurred because of intimal damage after stenting.

The longitudinal and radial flexibility of a nitinol graft may be sufficient for effective treatment of internal carotid artery aneurysms. However, stenting of cerebral aneurysms with adjacent perforators may be hazardous. The diameter of struts being 100 μm , complete occlusion of perforators may not occur, but exposed stent wire covering the perforators will remain a potential source of thromboembolic complication. Animal experiments with stainless steel stents placed in the common carotid artery of dogs covering the origin of the internal carotid artery and smaller branches of the external carotid artery have demonstrated angiographic patency of all arteries (Geremia GK, Kim TW, Haklin M, Brennecke L, Douglass J, *Intravascular Stents: Effects on Branching Vessels Originating from a Stent Containing Parent Artery*, presented at the 30th Annual Meeting of the ASNR, St Louis, Mo, May 31–June 5, 1992). Histologic investigation showed fibrotic tissue growth around the filaments extending into the origin of the branches without narrowing them significantly. However, dogs have an extremely active fibrinolytic system (34). Similar findings were reported after stenting abdominal aorta of canine. The lumbar arteries were not occluded, but a few of the ostia were covered partly with endothelium, as seen on a scanning electron photomicrograph (49).

Unlike in atherosclerotic disease, the primary goal of a stent in treating aneurysms should be to change the hemodynamic factors, thus promoting thrombosis rather than preventing restenosis. Hence, different requirements are placed on the geometry and material of the stent. Improvement of stents may include modifications to the shape, flexibility, elasticity, and strut diameter in order to reduce the part of the prostheses protruding into the arterial lumen. The total amount of metal surface covering the artery, which is responsible for the deposit of fibrin and platelets, must be reduced (48, 51). However, a significant loss of radiopacity will have to be avoided by proper plating of the stent material. For an exact placement, minimal shortening of the stent during expansion is mandatory. This remains an intrinsic problem in most of the available stents. Helix-shaped nitinol stents, as proposed first by Dotter (52), should be considered for cerebral aneurysms. For tortuous vessels more flexible alloys may facilitate the use of a smaller introducer

catheters without an additional increase in friction during deployment.

Development of biodegradable, nonparticulating material with antithrombogenic coating reduces the high rate of subacute thrombosis and myointimal proliferation (47, 48, 53). Recently described data about stents covered with endothelial cells capable of secreting large amounts of tissue plasminogen activator may reduce the risk of thrombosis (54). Our preliminary results with stents covered with autologous vein grafts offer another possibility for endovascular vessel reconstruction (Wakhloo AK, Schumacher M, de Vries J, et al, Coated and Noncoated Stents in Treatment of Carotid Arteriovenous Fistulas and Aneurysms: an Experimental Study, presented at the 30th Annual Meeting of the ASNR, St Louis, Mo, May 31–June 6, 1992).

Based on our preliminary results, intravascular stents are potential treatment for aneurysms, especially large, fusiform aneurysms. They may result in less danger to the parent vessel and less risk of rupturing the aneurysm. However, more detailed knowledge of the hemodynamics of the aneurysm, including the total volume and the diameter of the neck, is required before a suitable type of stent can be designed. Improvements in shape, material, and delivery system are necessary to reduce the intimal fibrosis and to simplify the implantation. An appropriate animal model has yet to be described for studying the potential risk of thromboembolic complications.

Acknowledgments

We thank E. P. Strecker, MD, and B. Schneider, MD, for introducing us to the crochet, K. Schweheimer, MD, and F. O. Tio, MD, for histologic studies, and H. Roth, DVM, for assisting with the animal experiments. We also thank Dana H. Evans, MS, (BNI), for editorial assistance.

References

- Higashida RT, Halbach VV, Barnwell SL, et al. Treatment of intracranial aneurysms with preservation of the parent vessel: results of percutaneous balloon embolization in 84 patients. *AJNR Am J Neuroradiol* 1990;11:633–640
- Guglielmi G, Vinuela F, Dion J, Duckwiler G. Electrothrombosis of saccular aneurysms via endovascular approach. Part 2: preliminary clinical experience. *J Neurosurg* 1991;75:8–14
- Guglielmi G, Viñuela F, Duckwiler G, et al. Endovascular treatment of posterior circulation aneurysms by electrothrombosis using electrically detachable coils. *J Neurosurg* 1992;77:515–524
- Halbach VV, Higashida RT, Hieshima GB, et al. Aneurysms of the petrous portion of the internal carotid artery: results of treatment with endovascular or surgical occlusion. *AJNR Am J Neuroradiol* 1990;11:253–257
- Graves VB, Strother CM, Partington CR, Rappe A. Flow dynamics of lateral carotid artery aneurysms and their effect on coils and balloons: an experimental study in dogs. *AJNR Am J Neuroradiol* 1992;13:189–196
- Guglielmi G. *Endovascular therapy of intracranial aneurysms with GDC coils*. Presented at the 30th Annual Meeting of the American Society of Neuroradiology, St Louis, May 31–June 6, 1992
- Fox AJ, Drake CG. Aneurysm neck remnant following balloon embolization. *J Neurosurg* 1987;67:321–322
- Suzuki J, Ohara H. Clinicopathological study of cerebral aneurysms. Origin, rupture, repair and growth. In: Suzuki J, ed. *Cerebral aneurysms*. Tokyo: Neuron Publishing Co, 1979:35–44
- Ferguson GG. Physical factors in the initiation, growth and rupture of human intracranial saccular aneurysms. *J Neurosurg* 1972;37:666–677
- Kwan ESK, Heilman CB, Shucart WA, Klucznik RP. Enlargement of basilar artery aneurysms following balloon occlusion—"water-hammer effect." Report of two cases. *J Neurosurg* 1991;75:963–968
- Heilman CB, Kwan ESK, Wu JK. Aneurysm recurrence following endovascular balloon occlusion. *J Neurosurg* 1992;77:260–264
- Lin T, Fox AJ, Drake CG. Regrowth of aneurysm sacs from residual neck following aneurysm clipping. *J Neurosurg* 1989;70:556–560
- Gonzalez CF, Cho YI, Ortega HV, Moret J. Intracranial aneurysms: flow analysis of their origin and progression. *AJNR Am J Neuroradiol* 1992;13:181–188
- Varsos V, Heros RC, DeBrun G, Zervas NT. Construction of experimental "giant" aneurysms. *Surg Neurol* 1984;22:17–20
- Higashida RT, Halbach VV, Hieshima GB. Treatment of intracranial aneurysms by interventional neurovascular techniques. In: Kadir S, ed. *Current practice of interventional radiology*. Philadelphia: Decker, 1991:150–154
- Erba SM, Horton JA, Latchaw RE, et al. Balloon test occlusion of the internal carotid artery with stable xenon/CT cerebral blood flow imaging. *AJNR Am J Neuroradiol* 1988;9:533–538
- Fox AJ, Viñuela F, Pelz DM, et al. Use of detachable balloons for proximal artery occlusion in the treatment of unclippable cerebral aneurysms. *J Neurosurg* 1987;66:40–46
- Higashida RT, Halbach VV, Dowd C, et al. Endovascular detachable balloon embolization therapy of cavernous carotid artery aneurysms: results in 87 cases. *J Neurosurg* 1990;72:857–863
- Eckard DA, Purdy PD, Bonte FJ. Temporary balloon occlusion of the carotid artery combined with brain blood flow imaging as a test to predict tolerance prior to permanent carotid sacrifice. *AJNR Am J Neuroradiol* 1992;13:1565–1569
- Guthikonda M, VanLoveren HR, Gaskill M, Tomsick T. Carotid occlusion tolerance: evaluation by combined balloon test occlusion and HMPAO study. *Skull Base Surg* 1993;3 (suppl):5
- Mathis JM, Barr JD, Horton JA, Jungreis CA, Vincent D. Complications of balloon test occlusion of cerebral arteries: experience in 475 cases. *Skull Base Surg* 1993;3 (suppl):5
- Spetzler RF, Fukushima T, Martin N, Zabramski JM. Petrous carotid-to-intradural carotid saphenous vein graft for intracavernous giant aneurysm, tumor, and occlusive cerebrovascular disease. *J Neurosurg* 1990;73:496–501
- Dotter CT, Buschmann RW, McKinney MK, Rösch J. Transluminal expandable nitinol coil stent grafting: preliminary report. *Radiology* 1983;147:259–260
- Palmaz JC, Richter GM, Noeldge G, et al. Intraluminal stents in atherosclerotic iliac artery stenosis: preliminary report of a multicenter study. *Radiology* 1988;168:727–731
- Palmaz JC, Garcia OJ, Schatz RA, et al. Placement of balloon-expandable intraluminal stents in iliac arteries: First 171 procedures. *Radiology* 1990;174:969–975

26. Günther RW, Vorwerk D, Bohndorf K, Peters I, El-Din A, Messmer B. Iliac and femoral artery stenoses and occlusions: treatment with intravascular stents. *Radiology* 1989;172:725-730
27. Strecker EP, Liermann D, Barth KH, et al. Expandable tubular stents for treatment of arterial occlusive diseases: experimental and clinical results. *Radiology* 1990;175:97-102
28. Becker GJ. Intravascular stents. General principles and status of lower-extremity arterial applications. *Circulation* 1991;83 (suppl 1):122-136
29. Mali WPTM, Geyskes GG, Thalman R. Dissecting renal artery aneurysm: treatment with an endovascular stent. *AJR Am J Roentgenol* 1989;153:623-624
30. Trent MS, Parsonnet V. A balloon-expandable intravascular stent for obliterating aortic dissection. *J Vasc Surg* 1990;11:707-717
31. Raillat C, Rousseau H, Joffre F, Roux D. Treatment of iliac artery stenoses with the wallstent endoprosthesis. *AJR Am J Roentgenol* 1990;150:613-616
32. Mirich D, Wright KC, Wallace S, et al. Percutaneously placed endovascular grafts for aortic aneurysms: feasibility study. *Radiology* 1989;170:1033-1037
33. Cragg AH, Lund G, Rysavy JA, Salomonowitz E, Castaneda-Zuniga WR, Amplatz K. Percutaneous arterial grafting. *Radiology* 1984;150:45-49
34. Sauvage LR, Berger KE, Wood SJ, Yates SG, Smith JC, Mansfield PB. Interspecies healing of porous arterial prostheses. *Arch Surg* 1974;109:698-705
35. Geremia GK, Hoile RD, Haklin MF, Charletta DA. Balloon embolization of experimentally created aneurysms: an animal training model. *AJNR Am J Neuroradiol* 1990;11:659-662
36. Graves VB, Partington CR, Rüfenacht DA, Rappe AH, Strother CM. Treatment of carotid artery aneurysms with platinum coils: an experimental study in dogs. *AJNR Am J Neuroradiol* 1990;11:249-252
37. Konishi Y, Maemura E, Shiota M, Hara M, Takeuchi K, Saito I. Treatment of vasospasm by balloon angioplasty: experimental studies and clinical experiences. *Neurol Res* 1992;14:273-281
38. Black SPW, German WJ. Observations on the relationship between the volume and the size of the orifice of experimental aneurysms. *J Neurosurg* 1960;60:984-990
39. Ferguson GG. Turbulence in human intracranial saccular aneurysms. *J Neurosurg* 1970;33:484-497
40. Strother CM, Graves VB, Rappe A. Aneurysm hemodynamics: an experimental study. *AJNR Am J Neuroradiol* 1992;13:1089-1095
41. DePalma VA, Baier RE, Ford JW, Gott VL, Furuse A. Investigation of three-surface properties of several metals and their relationship to blood compatibility. *J Biomed Mater Res* 1972;3:37-75
42. Palmaz JC. Intravascular stents: tissue-stent interactions and design considerations. *AJR Am J Roentgenol* 1993;160:613-618
43. Chuapetcharasopon C, Wright KC, Wallace S, Dobben RL, Gianturco C. Treatment of experimentally induced atherosclerosis in swine iliac arteries: a comparison of self-expanding and balloon-expanded stents. *Cardiovasc Intervent Radiol* 1992;15:143-150
44. Duprat G, Wright KC, Charnsangavej C, Wallace S, Gianturco C. Self-expanding metallic stents for small vessels: an experimental evaluation. *Radiology* 1987;162:469-472
45. Zollikofer CL, Redha FH, Bruhlmann WF, et al. Acute and long-term effects of massive balloon dilatation on the aortic wall and vasa vasorum. *Radiology* 1987;164:145-149
46. Waller BF, Orr CM, Pinkerton CA, VanTassel JW, Pinto RP. Morphologic observations late after coronary balloon angioplasty: mechanisms of acute injury and relationship to restenosis. *Radiology* 1990;174:961-967
47. Sigwart U, Puel J, Mirkovitch V, Joffre F, Kappenberg L. Intravascular stents to prevent occlusion and restenosis after transluminal angioplasty. *N Engl J Med* 1987;316:701-706
48. Serruys PW, Strauss BH, Beatt KJ, et al. Angiographic follow-up after placement of a self-expanding coronary artery stent. *N Engl J Med* 1991;324:13-17
49. Barth KH, Virmani R, Strecker EP, et al. Flexible tantalum stents implanted in aortas and iliac arteries: effects in normal canines. *Radiology* 1990;175:91-96
50. Schatz RA, Palmaz JC, Tio FO, Garcia F, Garcia O, Reuter SR. Balloon-expandable intracoronary stents in the adult dog. *Circulation* 1987;76:450-457
51. Escorcía E, Hollman J. Current status of stents. *Am J Cardiol* 1992;69:687-689
52. Dotter CT. Transluminally-placed coil spring endarterial tube grafts: long-term patency in canine popliteal artery. *Invest Radiol* 1969;4:329-332
53. Rees CR, Palmaz JC, Becker GJ, et al. Palmaz stent in atherosclerotic stenoses involving the ostia of the renal arteries: preliminary report of a multicenter study. *Radiology* 1991;181:507-514
54. Flugelman MY, Virmani R, Leon MB, Bowman RL, Dichek DA. Genetically engineered endothelial cells remain adherent and viable after stent deployment and exposure to flow in vitro. *Circ Res* 1992;70:348-354