

# The Magnetization Transfer Effect In Cerebral Infarction

Jordan M. Prager, Jordan D. Rosenblum, Daniel C. Huddle, Cheryl K. Diamond, and Charles E. Metz

**PURPOSE:** To estimate the age of cerebral infarcts using magnetization transfer. **METHODS:** Twelve patients with radiographically and clinically documented cortical and subcortical cerebral infarctions underwent MR imaging on a 0.1T magnet. Magnetization transfer contrast images were generated by application of off-resonance pulses to every other repetition time on intermediate-weighted images. The magnetization transfer effect was calculated by obtaining an intensity value in the region of interest within the infarcted area. **RESULTS:** The data show a pattern in which the magnetization transfer effect decreases as the chronicity of the infarct increases. Infarcts less than 1 week old had an average magnetization transfer effect of 0.35. Those more than 1 week and less than 1 month old average 0.30. Infarcts more than 1 month and specifically those more than 1 year old averaged 0.16 or less. **CONCLUSION:** Magnetization transfer offers the potential to estimate the age of cerebral infarcts.

**Index terms:** Brain, infarction; Brain, magnetic resonance; Magnetic resonance, technique

*AJNR Am J Neuroradiol* 15:1497-1500, Sep 1994

Strokes are the third most common cause of death after heart disease and cancer and are a major cause of chronic disability (1, 2). Acute thrombus formation and arterial occlusion account for approximately 70% of these (3).

The risk factors and pathophysiology of strokes are well documented. Classification systems for acute strokes based on etiology have even been implemented (4, 5). There are exhaustive data on treatment of strokes, but clinicians have yet to agree on a standardized form of therapy. This stems in part from the potential hazards of anticoagulation or thrombolytic agents and inconclusive data on their effectiveness (6, 7). Underlying this controversy is the commonly shared belief that outcome can

be altered significantly by early initiation of therapy (3, 4, 8).

Magnetic resonance (MR) has significantly aided in earlier detection of lesions; however, current imaging methods often do not provide an accurate estimate of infarct age (especially for subcortical lesions), which is very important when planning treatment strategy. A tool that could separate acute infarcts from chronic infarcts has potential to help guide therapeutic decisions concerning anticoagulation in the acute setting. Recently, magnetization transfer was introduced as a new way to generate contrast with MR (9). The contrast-to-noise ratio is increased over conventional MR. We examined magnetization transfer as a means of estimating the age of cerebral infarcts.

## Materials and Methods

Patient selection was based on demonstration of infarct(s) by routine MR or computed tomography (CT) and appropriate clinical history. Fourteen studies were performed on 12 patients (7 men, 5 women, ranging in age from 39 to 80 years) with infarcts of known age. All patients had been admitted to the neurology service before entering the study. Lesions were classified as cortical or subcortical. When possible, sequential studies were obtained.

All studies were performed on a 0.1T magnet (Instrumentarium, Helsinki, Finland). Routine T1 sagittal images

---

Received June 16, 1993; accepted after revision December 29.

This paper was presented in part at the American Society of Neuroradiology annual meeting, Vancouver, British Columbia, Canada, May 1993, and the Society for Magnetic Resonance Imaging Workshop for MTC, July 1993.

From the Department of Radiology, Division of Neuroradiology, University of Chicago Hospitals.

Address reprint requests to Jordan M. Prager, MD, Evanston Hospital, Northwestern University Medical School, 2650 Ridge Ave, Evanston, IL 60043.

*AJNR* 15:1497-1500, Sep 1994 0195-6108/94/1508-1497

© American Society of Neuroradiology



were obtained as localizers with T2 axial images obtained through the region of infarction. A gradient-echo sequence (1700/30 [repetition time/echo time], flip angle  $90^\circ$ ) was used with application of an off-resonance pulse alternately, to every other repetition time. The off-resonance pulse was centered 7.2 kHz from the Larmor frequency with an amplitude of 0.35G for 300ms. Intensity values were obtained by placing a cursor on the region of interest within the area of infarction. The largest region of interest possible was used; when a lesion was irregular in shape, an average value was obtained from multiple random samples. Values with the lowest standard deviation were selected when regions of interest were near the periphery of a lesion to minimize partial volume effects. The imaging effect from a saturating off-resonance pulse is a decrease in signal intensity; the decrease in signal varies according to tissue type. The magnetization transfer effect (MTe) was described by the index  $[I(m)-I(mt)]/I(m)$ , where  $I(m)$  is the lesion intensity on the mask (no off-resonance pulse) and  $I(mt)$  is the intensity on the magnetic transfer image. The MTe number reflects the percent signal decrease caused by the off-resonance pulse. The MTe number corresponds to the value magnetization transfer ratio described by other authors (10). MTe is more descriptive and not confused with the ratio used by physicists to describe magnetization transfer, that is  $I_{mt}/I_m$ .

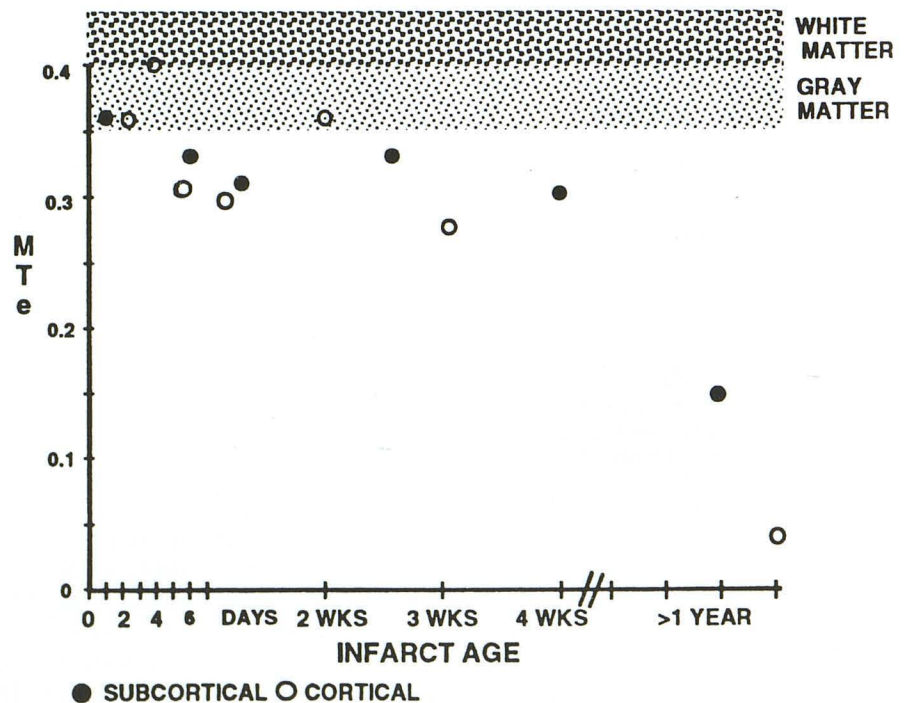
## Results

Results are shown graphically and demonstrate a pattern in which MTe decreases with increasing infarct age (Fig 1). The MTe value for infarcts less than 1 week of age averaged 0.35

(0.30 to 0.40), whereas those between 1 week and 1 month averaged 0.30 (0.28 to 0.36). Infarcts more than 1 year old showed the most substantial decrease in MTe, measuring less than 0.16. Areas of chronic encephalomalacia/porencephaly showed no appreciable MTe with values of approximately 0.01 to 0.03, similar to measurements of cerebral spinal fluid (CSF). A previous study of five healthy volunteers on this unit showed the range of normal gray matter to be 0.36 to 0.39 and normal white matter 0.40 to 0.45. MTe for cortical lesions was within the normal range in two patients and below normal values in the remaining lesions. MTe for subcortical lesions was always below normal values. Although no difference between acute, subacute, and chronic subcortical infarcts often is evident on visual analysis, there is a difference in the numerical value of the calculated MTe. Typical subcortical and cortical lesions are shown in Figures 2A and B.

The data were analyzed to assess the statistical significance of the apparent decrease in MTe value with infarct age. Because the number of infarcts in acute, subacute, and chronic categories was limited and the exact age of some chronic infarcts was not known, a nonparametric approach using Spearman's rank-order correlation coefficient was used (11) to test the statistical significance of its difference from

Fig 1. MTe versus infarct age. There is a decrease in MTe with increase in infarct age. Lesions older than 1 year show the most significant decrease in MTe. The range of MTe for normal gray and white matter is indicated by the shaded areas.





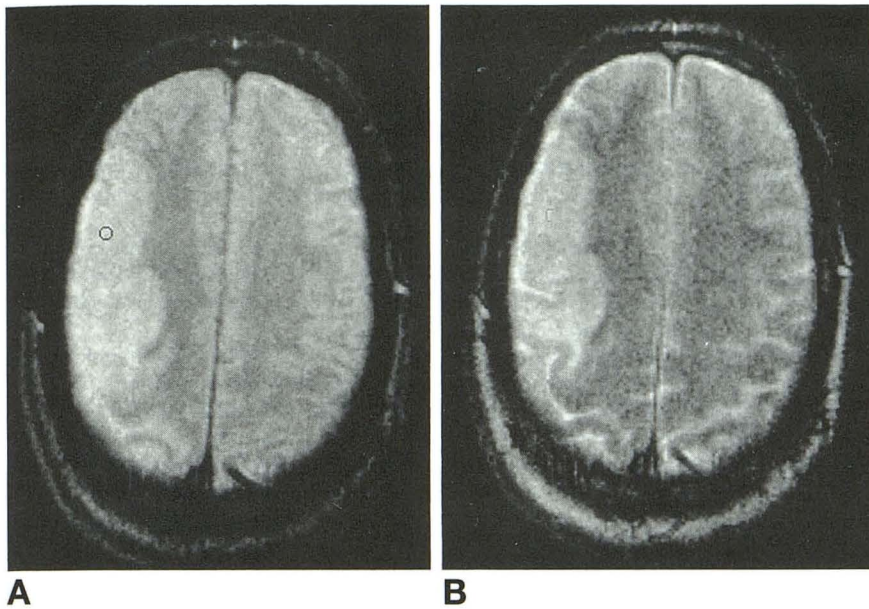


Fig 2. Sixty-four-year-old man with an 8-day-old infarct. The intermediate-weighted image (A) and the magnetization transfer image (B) demonstrate a large infarct in the distribution of the right middle cerebral artery. Mild effacement of sulci indicates an early subacute infarct.

zero. This tests the possibility that the ranking of infarcts in order according to MTe is attributable to chance. The corresponding Student's *t* statistic has a value of 2.243, corresponding to *P* equal to or less than .05 with a two-tailed test. Therefore, when looking at the entire group, it can be concluded with 95% confidence that the MTe value varies significantly with infarct age. Examination of the group of patients with infarcts less than 4 weeks old does not show such a significant relationship, although a trend toward declining MTe with infarct age is suggested. Differences based on age or sex were not taken into account in calculation of the MTe values.

### Discussion

MR imaging is based on the relative difference in magnetic relaxation rates and signal emission from the pool of "free" or unbound protons within tissues. Magnetization transfer is based on the interaction between populations of these mobile protons and restricted protein-bound protons (12, 13). Magnetization transfer is generated by applying radio frequency pulses to saturate the bound protons at a frequency that varies 5 to 10 kHz from the resonance frequency of hydrogen protons (9, 12). In this study, the off-resonance pulse is applied to every other repetition time during acquisition of intermediate-weighted images. Magnetization of the mobile protons is not significantly affected by the off-resonance pulse. Because of

chemical exchange and cross-relaxation between the bound and mobile protons, there is a decrease in the signal emitted from the mobile protons (9, 13, 14). This effect is greatest in tissues having a high protein/water ratio.

The contrast-to-noise ratio between gray matter and CSF is increased by more than 200% with magnetization transfer than with conventional MR (9). Lesions containing a high water content appear bright on long-repetition-time images in relation to the surrounding tissues, in which signal is suppressed. This is similar to the appearance of disease on conventional T2-weighted images. However, lesions will have greater signal relative to surrounding tissues than on conventional T2-weighted images. Although there is a quantitative difference between acute and chronic infarcts, often it is not seen on the images (Fig 2A and B).

The MTe results of this study correlate with the histopathologic findings (14) of evolving cellular to acellular lesions seen with infarction. Histologic changes are not evident for at least 6 to 12 hours after the initial injury. Ischemia results in disorganization and disarrangement of the cytoplasm within the cells. At approximately 24 to 48 hours, neutrophils pass through the damaged vascular walls into the surrounding tissues. This is followed by infiltration of lymphocytes and monocytes over the next few days. The result of cellular and fluid accumulation is increased volume of the infarct, which reaches a peak by the end of the second week. As the infarct evolves further, there is progres-



sive loss of protein and fluid with clearing of the necrotic debris. By the end of the third week the volume of the infarct approaches baseline. During the fifth and sixth week, cavitation of the tissue occurs, with reactive astrocytes surrounding the damaged tissue. In the final stages of infarction, fibrillary gliosis develops around the region of necrosis. At this stage, there is relatively little protein-bound water remaining. Therefore, during the acute stages of infarction there is a relatively greater concentration of "bound" protons, resulting in greater MTe than what occurs in the chronic stage where there are more mobile protons. The early changes resulting from edema and mass effect and, later, tissue loss, are usually quite apparent with cortical lesions on routine CT and MR but may be invisible with subcortical lesions.

The major limitation of this study is the small number of patients. Although a large number of patients presented with a history of either "acute" or "chronic" stroke, an inability to date these accurately by either CT, MR, or clinical history precluded inclusion of these in the study. Patients with hemorrhagic lesions were excluded. Patients who were MR-incompatible because of metallic implants or other metallic devices or claustrophobia also were excluded.

In summary, the preliminary data, although limited, show a pattern in which MTe decreases with infarct age. Infarct age potentially can be quantitated by this method, thereby providing a tool that may prove useful in clinical management, because appropriate treatment frequently depends on the age of these lesions. The method may be especially helpful in the evaluation of subcortical lesions, because the age of these lesions is often more obscure than the age of cortical lesions.

## References

1. Advanced report of final mortality statistics 1990. *Monthly Vital Statistics Report*. January 1993;41
2. Mortality patterns—United States 1989. *MMWR*. 1992;41:121–125
3. Broot TG, Haley EC, Levy DE, et al. Urgent therapy for stroke. Pilot study of tissue plasminogen activator administered within 90 minutes, I, II. *Stroke* 1992;23:632–640
4. Adams HP, Bendixen BH, Kappelle LJ, et al. Classification of subtype of acute ischemic stroke: definitions for use in a multicenter clinical trial. TOAST: trial of Org 10172 in acute stroke treatment. *Stroke* 1993;24:35–41
5. Anderson CS, Jamrozik KD, Burvill PW, et al. Determining the incidence of different subtypes of stroke: results from the Perth Community Stroke Study, 1989–1990. *Med J Aust* 1993;158(2):85–89
6. World Health Organization (WHO) task force on stroke and other cerebrovascular disorders special report: recommendations on stroke prevention, diagnosis, and therapy. *Stroke* 1989;20:1407–1424
7. Marsh EE, Adams HP, Jr., Biller J, et al. Use of antithrombotic drugs in the treatment of acute ischemic stroke: a survey of neurologists in practice in the United States. *Neurology* 1989;39:1631–1634
8. Rosen DM. New directions for acute stroke therapy. *Med J Aust* 1993;158(2):78–80
9. Wolff SD, Eng J, Balaban RS. Magnetization transfer contrast: method for improving contrast in gradient-recalled-echo images. *Radiology* 1991;179:133–137
10. Lexa FJ, Grossman RI, Rosenquist AC. Detection of early axonal degeneration in the mammalian central nervous system by magnetization transfer techniques in magnetic resonance imaging. *Ann N Y Acad Sci*, 1993;679:336–340
11. Hays WL. *Statistics*. Fort Worth: Holt Rinehart & Winston, 1988: 835–836
12. Hajnal JV, Baudouin CJ, Oatridge A, et al. Design and implementation of magnetization transfer pulse sequences for clinical use. *J Comput Assist Tomogr* 1992;16:7–18
13. Balaban RS, Ceckler TL. Magnetization transfer contrast in magnetic resonance imaging. *Magn Reson Q* 1992;8(2):116–137
14. Robbins SL, Cotran RS, Kumar V. *Pathologic Basis of Disease*. 3rd ed. Philadelphia: WB Saunders, 1984:1389–1391