

# Blinded Comparison of Cranial CT and MR in Closed Head Injury Evaluation

William W. Orrison, Lindell R. Gentry, Gary K. Stimac, Ronald M. Tarrel, Mary C. Espinosa, and Loren C. Cobb

**PURPOSE:** To compare CT and MR in the evaluation of acute head injury. **METHODS:** One hundred seven consecutive patients who were referred to the emergency department and underwent both MR and CT cranial examinations within 48 hours were retrospectively reviewed. The films were interpreted by two neuroradiologists blinded to all patient information. **RESULTS:** The sensitivity of MR was significantly higher than that of CT for the detection of contusion, shearing injury, subdural and epidural hematoma, and sinus involvement. The sensitivity of CT was significantly higher than that of MR for the evaluation of fracture. The sensitivities of MR and CT were statistically equivalent for the detection of superficial soft-tissue injury. The overall sensitivity of MR for the detection of abnormalities in acute head trauma was 96.4%, and for CT was 63.4%. **CONCLUSIONS:** CT and MR are complementary studies in the evaluation of acute head trauma. MR is necessary to define or exclude contusions, deep shearing injury, and extraaxial fluid collections in acute head trauma.

**Index terms:** Head, injuries; Head, computed tomography; Head, magnetic resonance; Magnetic resonance, comparative studies; Computed tomography, comparative studies; Efficacy studies

*AJNR Am J Neuroradiol* 15:351-356, Feb 1994

Previous studies comparing computed tomography (CT) and magnetic resonance (MR) in the evaluation of acute head injury have demonstrated distinct advantages for MR over CT in cerebral contusions, deep white matter lesions (shearing injury and diffuse axonal injury), extraaxial fluid collections (particularly isodense subdural hematomas), corpus callosum, and brain stem injury (1-13). In general, emergency patients with head injury continue to be evaluated by CT. The reasons for this are logistical and clinical. Most MR scanners are located a considerable distance from emergency rooms because of siting requirements. Furthermore, acutely injured patients cannot be effectively managed in

most MR scanners. The availability of MR in our emergency department enabled us to evaluate readily patients with acute head injury. We were, thus, able to compare a large number of patients who underwent examination by both modalities.

## Materials and Methods

The radiographic findings in an unselected, consecutive series of head trauma patients who had undergone both cranial CT and MR were evaluated. The study consisted of a retrospective review of emergency room-referred head trauma patients. One hundred seven of these underwent MR. All of these patients had MR examinations performed within 48 hours of the CT. A repeat CT scan for direct comparison was not performed at the time MR imaging was performed. All patients were referred for evaluation between May 15, 1988, and June 30, 1989. The study consisted of a retrospective review of emergency room-referred head trauma patients.

Imaging was performed on a 0.064-T permanent magnet (MTP Access, Toshiba America MRI, South San Francisco, Calif) and a high-resolution CT system (9800 Quick, General Electric, Milwaukee, Wis). Two hundred fourteen examinations were read independently and randomly by two senior members of the American Society of Neuroradiology (L.R.G. and G.K.S.). Both readers had recent experience using 1.5-T superconducting MR systems and high-reso-

---

Received July 31, 1992; accepted pending revision October 14; revision received February 4, 1993.

From the Departments of Radiology (W.W.O., M.C.E.), Community Medicine (L.C.C.), and Neurology (W.W.O., R.M.T.), University of New Mexico School of Medicine, Albuquerque, NM; Department of Radiology (L.R.G.), Clinical Science Center, University of Wisconsin, Madison, Wis; and First Hill Diagnostic Center (G.D.S.), Seattle, Wash.

Address reprint requests to William W. Orrison, MD, Department of Radiology, University of New Mexico School of Medicine, Albuquerque, NM 87131-5336.

*AJNR* 15:351-356, Feb 1994 0195-6108/94/1502-0351

© American Society of Neuroradiology

MRI-CT HEAD TRAUMA STUDY

Study # \_\_\_\_\_ MR \_\_\_\_\_ CT \_\_\_\_\_

Reader \_\_\_\_\_ Normal \_\_\_\_\_ Abnormal \_\_\_\_\_

If abnormal:

_____ Soft Tissue Injury	_____ Sinus Disease/Injury	_____ Cortical Contusion
_____ Subdural Hematoma	_____ Epidural Hematoma	_____ Fr
_____ Shearing Injury	_____ Edema	_____ Pneumocephalus
_____ Intracerebral Hem.	_____ Transientorial Hem.	_____ Intraventricular Hem.
_____ Subarachnoid Hem.	_____ Infarct	_____ Post-op
_____ Atrophy	_____ Hydrocephalus	

Patient # \_\_\_\_\_ Sex \_\_\_\_\_

Exam Date \_\_\_\_\_

Fig. 1. Reader tabulation form.

lution CT scanners, and neither had previously used a 0.064-T scanner for clinical care. The readers were blinded to patient history; all identifying data such as name, date, age, and sex were covered. All MR studies included a T1-weighted spin-echo sequence (400–600/20–40/2–4 [repetition time/echo time/excitations]) or a gradient-echo sequence (68/24/3) with a flip angle of 60°, and more T2-weighted spin-echo images (1500–2500/30–105/2). Imaging planes included sagittal and axial in all patients and coronal images in selected cases. CT examinations used conventional gantry angulation, section thickness (3 to 10 mm), radiographic techniques, and contrast enhancement (when clinically indicated). Images using intermediate windows were available for review. A standard-of-reference diagnosis for each patient was supplied independently of the neuroradiologist’s blinded readings by two of the investigators (W.W.O. and R.M.T.) who used complete patient information consisting of patient records, pathology reports, and all available images including follow-up examinations. Standard-of-reference diagnoses included a determination of abnormal or normal and specific indications of sub/epidural hematoma, shearing injury, sinus disease,

contusion, soft tissue injury, or fracture (Fig 1). Results were tabulated and used for statistical analysis by an independent statistician. This statistical analysis included calculations of sensitivities and McNemar tests. Sensitivity is defined as the probability of a radiologic finding being positive for a disease given that the patient has that disease. Interreader reliability was evaluated using phi, a nonparametric coefficient of correlation.

In this study, one imaging modality was judged to be better than another with respect to a given diagnosis if its sensitivity was greater and if the significance of the comparison was less than 5%. Two imaging modes were judged to be roughly equivalent if their sensitivities were not significantly different and if the power of the comparison was at least 80% for finding differences of moderate size; that is, there was an 80% or greater chance of detecting a degree of difference between 62% and 82%.

**Results**

The sensitivity of MR was significantly higher than CT for the detection of contusion ( $P < .001$ ) (Fig 2), subdural and epidural hematoma ( $P < .001$ ) (Fig 3), shearing white matter injury ( $P < .001$ ) (Fig 4), and sinus involvement ( $P < .001$ ). Sinus involvement included any evidence of sinus disease.

The sensitivity of CT was significantly higher than that of MR in the detection of fracture ( $P < .001$ ) (Fig 3). CT and MR were equivalent in sensitivity for the detection of superficial soft tissue injury (scalp swelling). The overall sensitivity of MR for the detection of abnormalities in acute head trauma was 96.4% and for CT was 63.4%. Interreader correlation (phi) for finding abnormalities was high at 0.72 (Tables 1 and 2). Table 2 displays the rates of agreement by scan-

TABLE 1: Statistical comparison of sensitivities

Diagnosis	Conclusion	Z Test <sup>a</sup>	McNemar <sup>b</sup>	Ratio <sup>c</sup>	Sensitivity (%)	
					MR	CT
Abnormal	MR > CT	8.11 ( $P < .001$ )	56.70 ( $P < .001$ )	67:3	96	63
Subdural and epidural hematoma	MR > CT	11.71 ( $P < .001$ )	75.87 ( $P < .001$ )	89:4	97	31
Shearing injury	MR > CT	8.66 ( $P < .001$ )	34.57 ( $P < .001$ )	42:2	97	20
Sinus	MR > CT	5.92 ( $P < .001$ )	30.68 ( $P < .001$ )	56:10	79	45
Contusion	MR > CT	5.53 ( $P < .001$ )	22.40 ( $P < .001$ )	32:3	96	68
Soft tissue injury	MR = CT	0.51 (NS)	0.09 (NS) <sup>d</sup>	24:21	60	56
Fracture	CT > MR	-6.32 ( $P < .001$ )	22.32 ( $P < .001$ )	1:27	36	94

<sup>a</sup> Z test for comparing two proportions from independent samples. One-tailed significance levels are given in parentheses.

<sup>b</sup> McNemar  $\chi^2$  test for symmetry in a two-by-two table, with correction for continuity for standard of reference positive findings only. A significant value indicates that one method was significantly more sensitive than the other. McNemar test is preferred to the Z test when both CT and MR scans are performed on the same patients (as is the case in this study).

<sup>c</sup> The ratio of readings in which MR was correct and CT incorrect to readings in which CT was correct and MR incorrect.

<sup>d</sup> The power of this test was 88%. For the purposes of this study, power was defined as the probability of detecting a difference between two proportions of at least 0.2 at midscale using a one-tailed significance level of 0.05. NS indicates nonsignificant.

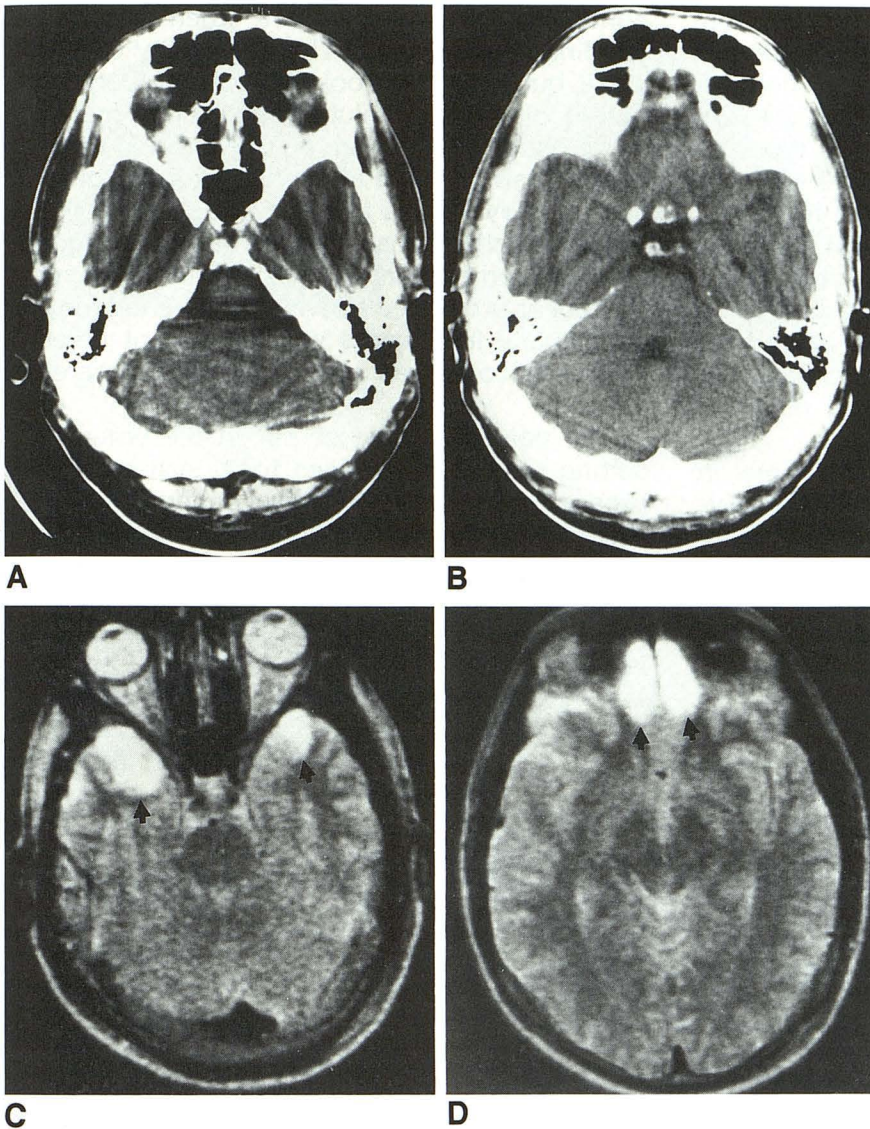


Fig. 2. Case 1. Thirty-one-year-old man who was involved in a motor vehicle accident.

A and B, Axial CT scans which were interpreted as normal.

C and D, Axial T2-weighted (2000/105) MR images demonstrate an abnormal signal intensity in the temporal lobes and the frontal lobes (arrows) that were not identified on the CT scan.

ning modality between individual readers and the standard of reference.

In this study there were too few standard-of-reference diagnoses of subarachnoid hemorrhage, intracerebral hematoma, midline shift, pneumocephalus, intraventricular hemorrhage, hydrocephalus, and infarct to analyze these conditions.

**Discussion**

Previous studies of MR imaging indicate that this modality is more sensitive than CT in detecting many types of traumatic lesions (1-13). The current blinded study supports the contention that a positive MR is more predictive of actual trauma than a positive CT for all forms of traumatic injury, with the exception of fracture. MR

has been previously noted to be particularly more sensitive in the detection of nonhemorrhagic lesions (4-6). This has been attributed to alterations in local concentrations of water, resulting in both intracellular and extracellular edema (4, 6, 14).

CT continues to be the diagnostic modality of choice for determining the appropriate acute surgical management in cases of head trauma (15-19). The current study would support CT as the initial diagnostic test in the comatose or dramatically neurologically impaired head-injured patient

TABLE 2: Percent agreement with standard of reference by reader

Reader	MR	CT	Both Modes
1	92% (98/107)	65% (70/107)	78% (168/214)
2	97% (104/107)	65% (70/107)	81% (174/214)
Both readers	94% (202/214)	65% (140/214)	80% (342/428)

because of speed and accessibility. Nonetheless, significant discrepancies exist between some patients' clinical evaluations and their CT findings when they have acute head injury (4, 6, 20–23). The inability of CT to detect multiple types of cerebral injury has been substantiated by pathologic confirmation (4, 14, 22, 23). MR is a more sensitive imaging modality and can improve quantitative and qualitative analysis of the extent of acute brain injury. A normal CT scan is no longer adequate evidence that a head-injured patient may not suffer severe neuropsychologic or delayed neurologic impairments as a result of undetected cerebral lesions.

The finding of diffuse or deep contusions in patients with entirely normal or minimally abnormal CT scans has both significant medical-management and medicolegal implications. Our study would indicate that previous reports suggesting a superiority of MR over CT in this area are correct (2, 4, 7) (Figs 1 and 3). Over half of the significant head injuries occurring in the United States are a result of motor vehicle accidents (24). It is often difficult to sort out the relevance of persistent

complaints after an accident when litigation is pending or in process. The availability of a sensitive but objective tool to measure better the extent of cerebral injury may clarify many of these issues. In addition, an alteration in medical care of patients with acute head injuries may be indicated by lesions that are undetected by CT. Fluid restriction, closer observation, more aggressive and earlier rehabilitation efforts, and a more gradual or prolonged convalescent period may be appropriate in patients with significant cerebral lesions as compared with those with no cerebral damage.

The potential value of MR in the emergency setting results in the need for a systematic approach to acutely head-injured patients. The clinical protocol established by our neurosurgical and neuroradiology divisions advises that all patients receive initial CT scans as soon as possible to be followed by MR within the first 24 hours. The MR is occasionally performed before the CT scan but is more typically obtained within the first 4 to 16 hours afterward. When MR imaging is performed and CT scans are not available, an axial T1-

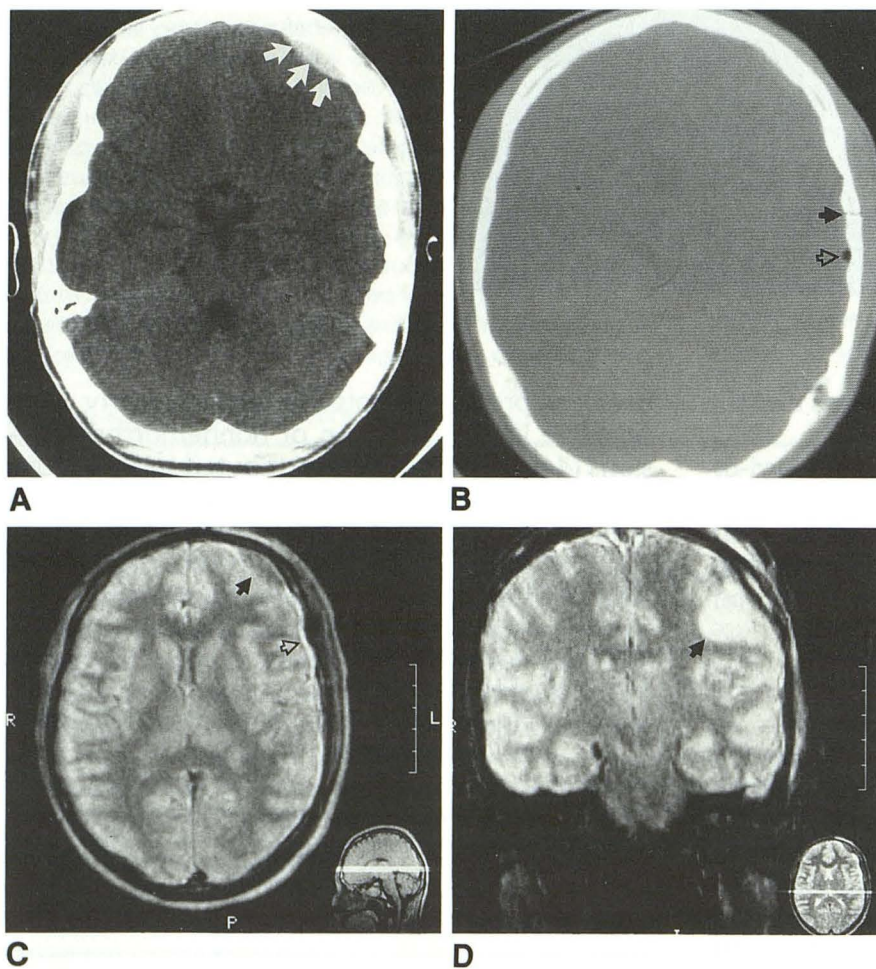


Fig. 3. Case 2. Twenty-year-old woman who was involved in a motor vehicle accident.

A, Intermediate-window CT scan demonstrates an epidural hematoma (arrows). Note that no subdural hematoma is visible.

B, Axial CT scan with bone windows demonstrates a skull fracture (closed arrow) and pneumocephalus (open arrow) which are less well defined on the MR images.

C, Axial proton density-weighted MR (2000/30) demonstrates decreased signal intensity in the region of the known epidural hematoma (arrow) and increased signal from an associated subdural hematoma/hygroma (open arrow).

D, Coronal T2-weighted MR (145/53, flip angle of 20°) demonstrates a large cortical and subcortical contusion not identified on the CT scan (arrow). Note the abnormal signal and contour of the adjacent calvarium.

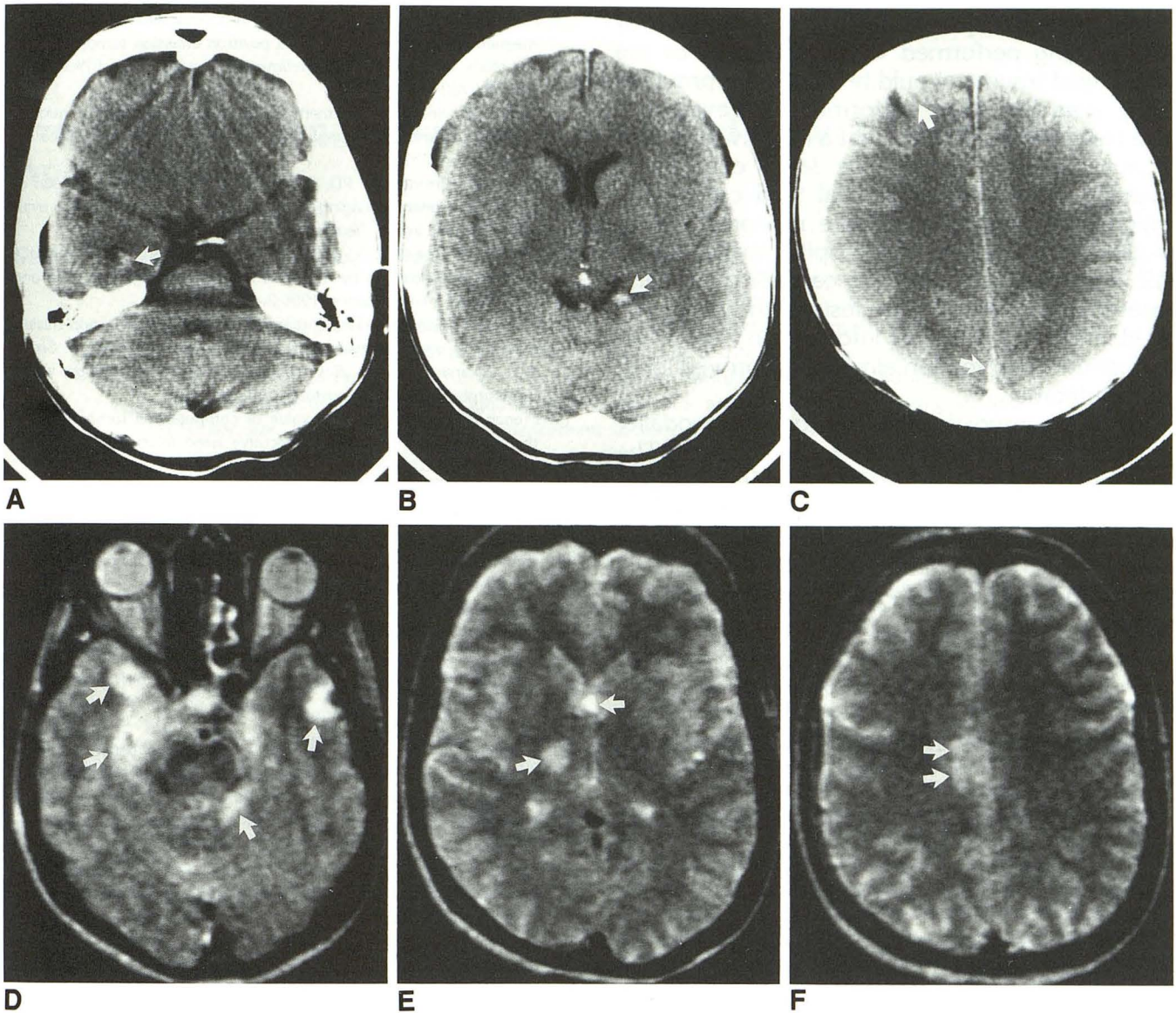


Fig. 4. Case 3. Thirty-year-old woman who was thrown from a horse. The patient was deeply comatose and respirator dependent. A-C, Axial CT scans demonstrate a small amount of hemorrhagic change adjacent to the right temporal horn, in the quadrigeminal plate cistern, interhemisphere fissure, and superficially over the frontal cortex bilaterally (arrows). D-F, Axial T2-weighted MR scans (2000/105) demonstrate bilateral temporal lobe contusions, deep white matter shearing injury in the region of the internal capsule on the right, and involvement of the corpus callosum. Note that none of these lesions is identified on the concurrent CT scan (arrows).

weighted scan is routinely performed. This significantly improves the detection of subarachnoid and intraventricular hemorrhage at lower field strengths (25-27). In order to accommodate the large number of cranial MR referrals from this protocol, we have established a limited MR examination, which consists of axial proton density- and T2-weighted images. This limited MR examination is performed only when a CT scan is available from the preceding 24 hours, and is charged as a combination study. This combination CT/MR represents an approximate 50% re-

duction in cost of the two examinations performed separately. Because the vast majority of these combination CT/MR studies are performed back-to-back, there is little effect on patient handling within the department. Repeat CT and MR examinations are then obtained as clinically indicated.

In our series of 107 consecutive patients, acute surgical management was altered in only one case by information provided on MR. This change was for a patient with an unsuspected neoplasm. Neurosurgical intervention within the first 24

hours was not required. Our study indicates that MR imaging performed within 24 hours of the initial head trauma should be adequate, provided a CT scan has been performed. However, it is also clear from this study that a negative CT scan is not sufficient to exclude large contusions, shearing injury, and extraaxial fluid collections, which may require less acute neurosurgical or medical intervention. The hospital availability of MR scanners provides the capability of early assessment of intracranial lesions that may not be identified by CT. This information may direct therapeutic intervention aimed at improved long-term outcome.

MR is an important neurodiagnostic modality in the emergency and trauma departments. The additional information obtained by MR may alter patient care significantly. CT and MR are complementary in the evaluation of head trauma; however, MR is significantly more sensitive for a broad range of common posttraumatic brain insults.

## References

- Zimmerman RA, Bilaniuk LT, Hackney DB, Goldberg HI, Grosman RI. Head injury: early results comparing CT and high-field MR. *AJNR Am J Neuroradiol* 1986;7:757-764
- Gentry LR, Godersky JC, Thompson BH. Traumatic brain stem injury: MR imaging. *Radiology* 1989;171:177-187
- Gentry LR, Godersky JC, Thompson BH. MR imaging of head trauma: review of the distribution and radiopathologic features of traumatic lesions. *AJNR Am J Neuroradiol* 1988;9:101-110
- Gentry LR, Godersky JC, Thompson B, Dunn VD. Prospective comparative study of intermediate-field MR and CT in the evaluation of closed head trauma. *AJNR Am J Neuroradiol* 1988;9:91-100
- Han JS, Kaufman B, Alfidi RJ, et al. Head trauma evaluated by magnetic resonance and computed tomography: a comparison. *Radiology* 1984;150:71-77
- Hesselink JR, Dowd CF, Healy ME, Hajek P, Baker LL, Luerssen TG. MR imaging of brain contusions: a comparative study with CT. *AJNR Am J Neuroradiol* 1988;9:269-278
- Gentry LR, Thompson B, Godersky JC. Trauma to the corpus callosum: MR features. *AJNR Am J Neuroradiol* 1988;9:1129-1138
- Moon KL Jr, Brant-Zawadzki M, Pitts LH, Mills CM. Nuclear magnetic resonance imaging of CT-isodense subdural hematomas. *AJNR Am J Neuroradiol* 1984;5:319-322
- Levin HS, Handel SF, Goldman AM, Eisenberg HM, Guinto FC. Magnetic resonance imaging after "diffuse" nonmissile head injury. *Arch Neurol* 1985;42:963-968
- Langfitt TW, Obrist WD, Alavi A, et al. Computerized tomography, magnetic resonance imaging, and positron emission tomography in the study of brain trauma: preliminary observations. *J Neurosurg* 1986;64:760-767
- Gandy SE, Snow RB, Zimmerman RD, Deck MDF. Cranial nuclear magnetic resonance imaging in head trauma. *Ann Neurol* 1984;16:254-257
- Snow RB, Zimmerman RD, Gandy SE, Deck MDF. Comparison of magnetic resonance imaging and computed tomography in the evaluation of head injury. *Neurosurgery* 1986;18:45-52
- Jenkins A, Teasdale G, Hadley MDM, MacPherson P, Rowan JO. Brain lesions detected by magnetic resonance imaging in mild and severe head injuries. *Lancet* 1986;2:445-446
- Adams JF, Genneralli TA, Graham DI. Brain damage in non-missile head injury observations in man and subhuman primates. In: Smith WT, Cavanagh JB, eds. *Recent advances in neuropathology*. vol 2. Edinburgh: Churchill Livingstone, 1982:165-190
- French BN, Dublin AB. The value of computerized tomography in the management of 1000 consecutive head injuries. *Surg Neurol* 1977;7:171-183
- Zimmerman RD, Danziger A. Extracerebral trauma. *Radiol Clin North Am* 1982;20:105-121
- Moseley IF, Zilkha E. The role of computerised axial tomography (EMI-scanning) in the diagnosis and management of cranio-cerebral trauma. *J Neuroradiol* 1976;3:277-296
- Bricolo AP, Pasut LM. Extradural hematoma: toward zero mortality. *Neurosurgery* 1984;14:8-12
- Seelig JM, Becker DP, Miller JD, Greenberg RP, Ward JD, Choi SC. Traumatic acute subdural hematoma: major mortality reduction in comatose patients treated within four hours. *N Engl J Med* 1981;304:1511-1518
- Lanksch W, Grumme T, Kazner E. Correlations between clinical symptoms and computerized tomography findings in closed head injuries. In: Frowein RA, Wilcke D, Karimi-Nejad A, Brock M, Klingner M, eds. *Advances in neurosurgery*. vol 5. New York: Springer-Verlag, 1978:27-29
- Snoek J, Jennett B, Adams JH, Graham DI, Doyle D. Computerised tomography after recent severe head injury in patients without acute intracranial haematoma. *J Neurol Neurosurg Psychiatry* 1979;42:215-225
- Adams JH, Graham DI, Scott G, Parker LS, Doyle D. Brain damage in fatal non-missile head injury. *J Clin Pathol* 1980;33:1132-1145
- Cooper PR, Maravilla K, Kirkpatrick J, et al. Traumatically induced brain stem hemorrhage and the computerized tomographic scan: clinical, pathological, and experimental observations. *Neurosurgery* 1979;4:115-124
- Baker SP. Injury science comes of age (editorial). *JAMA* 1989;262:2284-2285
- Yoon HC, Lufkin RB, Vinuela F, Bentson J, Martin N, Wilson G. MR of acute subarachnoid hemorrhage. *AJNR Am J Neuroradiol* 1988;9:404-405
- Janousek A. Head injuries: three years' experience with ultra-low-field MRI. *Neuroradiology* 1991;33 (suppl):616-617
- Chaney RK, Taber KH, Orrison WW, Hayman LA. Magnetic resonance imaging of intracerebral hemorrhage at different field strengths. *Neuroimaging Clin North Am* 1992;2:25-51