

# Skull-Base Foramina of the Middle Cranial Fossa: Reassessment of Normal Variation with High-Resolution CT

Lawrence E. Ginsberg, Steven W. Pruett, Michael Y. M. Chen, and Allen D. Elster

**PURPOSE:** To evaluate by means of high-resolution CT the anatomic variations of the middle cranial fossa foramen. **METHODS:** We examined 123 CT studies of the temporal bone in patients with no evidence of disease that might alter foramina anatomy. A checklist of known variants and suspected structures was used as each case was systematically examined for the presence or absence of these foramina; variations in size, shape, and location; and relationship of structures to each other. Inclusion criteria were established to eliminate error. **RESULTS:** The foramen rotundum had a constant appearance. We identified the inferior rotundal canal in 16% of patients and the lateral rotundal canal in 8%. The foramen of Vesalius was present, at least unilaterally, in 80% of our cases. Asymmetry of the foramen of Vesalius did not indicate disease in our patient group. We did not find an inverse relationship between the size of the foramen of Vesalius and that of the ipsilateral foramen ovale. We found variations in the size and shape of the foramen ovale and its confluence with the foramen spinosum ( $n = 2$ ) and the foramen of Vesalius ( $n = 8$ ). We did not find an inverse relationship between the size of the foramen ovale and that of the foramen spinosum. The canaliculus innominatus for the lesser superficial petrosal nerve was identified in 16.3% of our patients. Variations of the foramen spinosum that we found include a medial bony defect (26.8%) and absence (3.2%). **CONCLUSION:** Although it is unlikely that well-formed foramina will be misinterpreted as diseased, it is nonetheless important to recognize foramina variants and associated neurovascular anatomy.

**Index terms:** Cranial fossa, middle; Foramina, ovale; Foramina, rotundum; Foramina, spinosum; Skull, anatomy; Skull, base; Skull, computed tomography

*AJNR Am J Neuroradiol* 15:283-291, Feb 1994

Along the medial floor of the middle cranial fossa, the greater wing of the sphenoid bone yields numerous openings or foramina that transmit vital neural and vascular structures. Many normal variants of these foramina have been well described in the early anatomic and radiologic literature. High-resolution computed tomography (CT), with its superb delineation of bone, seems uniquely suited to display the rich spectrum of anatomic variation in this region. Recognition of these variants is important not only for understanding the complex regional neurovascular anatomy but also for distinguishing normal from potentially abnormal structures.

Using high-resolution CT, we studied the appearance and prevalence of these variant foramina

in a large group of patients. With regard to some of the lesser known foramina, although anatomic confirmation was unavailable, our assertions as to their identity are based on the close correlation between imaging findings and established anatomic knowledge.

## Subjects and Methods

High-resolution unenhanced CT scans of the temporal bone in 140 consecutive patients were retrospectively reviewed to assess the prevalence of anatomic variants on the floor of the middle cranial fossa. Studies were acquired using 1.5-mm contiguous sections in an axial plane parallel to the infraorbitomeatal line. All scans were performed on a General Electric 9800 scanner (General Electric Medical Systems, Milwaukee, Wis) and reconstructed using a bone algorithm and zooming each side separately to a 9.6-cm field of view. Although this protocol was designed principally to detect temporal bone disorders, the more anteromedially situated skull-base foramina also were generally well visualized.

Exclusion criteria were: 1) technically suboptimal scans; 2) severe traumatic or destructive neoplastic or inflammatory lesions that rendered the anatomy uninterpretable; and 3) patient age less than 1 year, because of the difficulty in discerning some structures in very small skulls. The final study group included 123 patients of whom 61 were male and 62 were female, with an age range of 1-78 years.

---

Received December 21, 1992; accepted pending revision February 2, 1993; revision received February 23.

From the Department of Radiology (L.E.G., M.Y.M.C., A.D.E.), Bowman Gray School of Medicine of Wake Forest University, Winston-Salem, NC; and Department of Diagnostic Radiology, Winthrop University Hospital, Mineola, NY (S.W.P.).

Address reprint requests to Lawrence E. Ginsberg, MD, Department of Radiology, Bowman Gray School of Medicine, Medical Center Boulevard, Winston-Salem, NC 27157-1088.

*AJNR* 15:283-291, Feb 1994 0195-6108/94/1502-0283

© American Society of Neuroradiology

TABLE 1: Findings of middle cranial fossa foramina variants

	Number of patients
Foramen rotundum (n = 98)	
Inequality of size	0
Inferior rotundal canal	16
Lateral rotundal canal	8
Persistent foramen lacerum arterius	0
Foramen of Vesalius (n = 123)	
Presence unilaterally	38
Presence bilaterally	60
Bilateral, equal	45
Bilateral, unequal	15
Duplication	17 (bilateral in 2 patients)
Absence	25
Foramen ovale (n = 123)	
Inequality of size	38
Asymmetry	29
Absence of medial wall (confluence with sphenopetrosal synchondrosis)	2
Confluence with foramen of Vesalius	8
Confluence with foramen spinosum	2
Persistent foramen lacerum medius	0
Abnormal location	0
Ipsilaterally smaller foramen ovale with unilateral foramen of Vesalius	6 of 38
Posterolateral groove for accessory meningeal artery	14
Ipsilaterally larger foramen ovale with unilaterally smaller or absent foramen spinosum	4 of 20
Absence	0
Canaliculus Innominatus	
Presence	20 (bilateral in 1 patient)
Foramen spinosum	
Inequality of size	20
Small or absent foramen spinosum with larger ipsilateral foramen ovale	4
Medial defect (confluence with sphenopetrosal synchondrosis)	33
Confluence with foramen ovale	2
Duplication	1
Absence	4

Imaging was performed for the following indications: suspected acute infection (n = 12), suspected cholesteatoma (n = 15), chronic infection (n = 17), known or suspected neoplasm (n = 12), suspected cochlear deformity or otosclerosis (n = 9), nonspecified hearing loss (n = 25), trauma (n = 10), tinnitus or vertigo (n = 6), cerebrospinal fluid leak (n = 3), ear pain (n = 2), Bell palsy (n = 1), Meniere disease (n = 1), cochlear implant planning (n = 1), suspected facial nerve lesion (n = 1), and unstated or unknown (n = 8). No patients had known abnormalities in or around the region of interest, and none had vascular lesions that might influence blood flow in the region of the middle cranial fossa foramen. Information regarding the foramen rotundum was available for only 98 patients because of exclusion of the anterior aspect of the field related to zooming.

All scans were reviewed using a checklist of predetermined foramina variants (Table 1) suggested by the avail-

able literature. Because surgical or autopsy correlation could not be obtained, a foramen was defined as a round or ovoid structure with a sclerotic rim and a lucent center seen on at least two adjacent sections. Questionable structures such as sclerotic dots were excluded. Confluence of two foramina was defined as a complete lack of bony separation on all sections. Similarly, for any foramen considered open or continuous medially with a fissure, lack of separation by bone from this fissure was required on every image. Inequality of size was defined as foramina diameter exceeding 1.25 times the greatest diameter of the contralateral foramen. To define the canaliculus innominatus, a line was drawn through the long axis of the foramen ovale and through the foramen spinosum so that only the canals between the two, lying medially to this line, were included.

## Results and Discussion

The results are described in Table 1. The foramina are presented in an anterior to posterior fashion.

### Foramen Rotundum

The foramen rotundum is situated along the medial root of the greater wing of the sphenoid bone, just lateral to the inferior aspect of the superior orbital fissure and separated from it by a thin bar of bone (Fig 1). The foramen rotundum is generally 3.4 mm long and forms a communication between the middle cranial fossa and the pterygopalatine fossa through which the second or maxillary division of the trigeminal nerve is transmitted (1). This nerve provides sensory innervation to the skin of the middle third of the

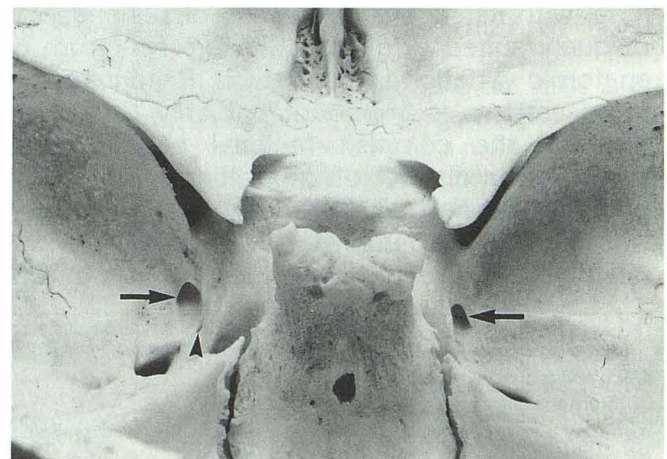


Fig. 1. Photograph of "normal" skull from above and behind. Both foramen rotunda are well seen (arrows). No variant foramen are seen within the left foramina rotundum, but several faintly seen emissary foramina are present in the floor of the right foramen rotundum. A left-sided foramen of Vesalius is noted (arrowhead).

face, lower eyelid, and upper lip; the mucous membranes of the nasopharynx, maxillary sinus, and upper gingiva; and teeth (1). This foramen also contains emissary veins (1, 2). The foramen rotundum originates embryologically as the foramen lacerum anterius, a hiatus between the orbitosphenoid and alisphenoid, which are precursors of the lesser and greater sphenoidal wings, respectively (2). Development of a bony spur from the greater wing to the lateral aspect of the body of the sphenoid bone separates the foramen rotundum from the superior orbital fissure (Figs 1 and 2). Failure of this spur to form results in a persistent foramen lacerum anterius, which is seen in some lower mammals (ie, rodents) but is quite rare in humans (1–3). We detected neither this rare variant nor significant asymmetry of the foramina rotunda in any of our patients.

A more common variant of the foramen rotundum is the presence of a small (1- to 3-mm) opening in the floor of this foramen, which leads to the infratemporal fossa or to the space between the pterygoid plates. In anatomic dissections, Sondheimer (1) detected these openings in five of 50 skulls and speculated that they transmitted emissary veins. We became particularly interested in this foramen because we could not find a description of its CT appearance and because a research skull owned by one of the authors contained this variant bilaterally (Fig 2). This finding is striking on gross specimen when compared with a "normal" skull (Fig 1). We observed this foramen/canal in 16 (16%) of 98 patients (Fig 3). Given the proximity of the inferior openings to the pterygoid venous plexus and the known existence of small emissary veins within

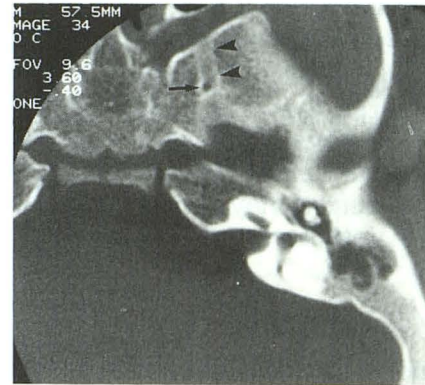


Fig. 3. Left inferior rotundal canal (arrow) arises from the floor of foramen rotundum (arrowheads).

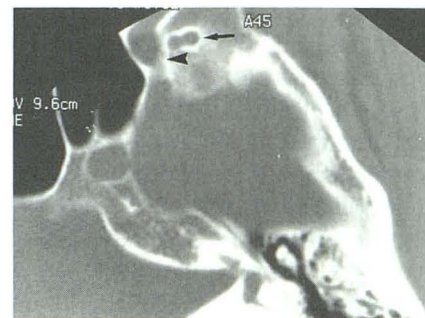


Fig. 4. Left lateral rotundal canal. A peanut-shaped foramen (arrow) is seen lateral to foramen rotundum (arrowhead).

the foramen rotundum, we, like Sondheimer, believe this structure transmits emissary veins. Because this variant is commonly seen on CT, we propose that a name be established for it and suggest the term *inferior rotundal canal*. In eight (8%) of 98 patients, we also observed a canal lateral to the foramen rotundum that could not

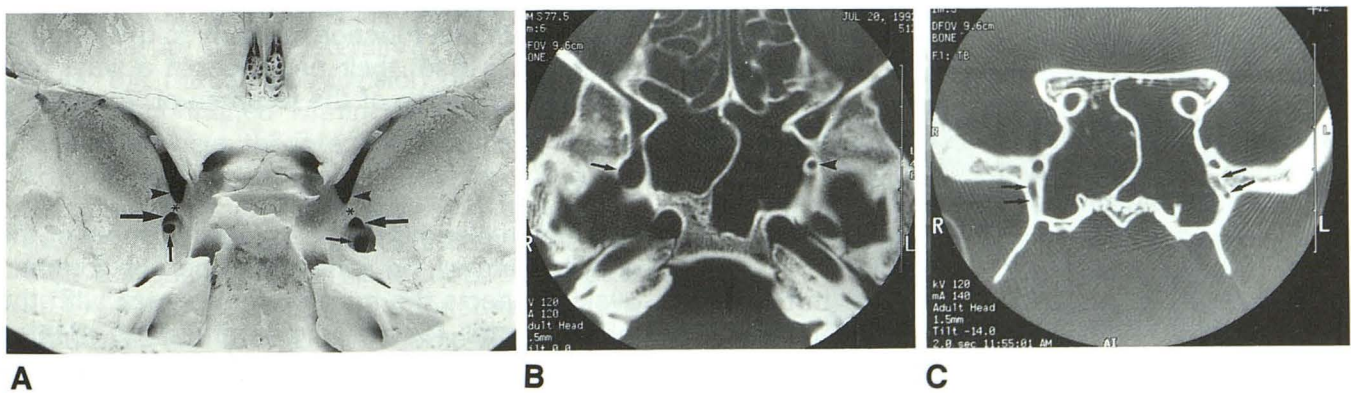


Fig. 2. A, Photograph of research skull from above and behind. Bony spur (asterisk) separates superior orbital fissure above (arrowheads) and foramen rotundum below (large arrows). Bilateral small openings at the floor of foramen rotundum represent the inferior rotundal canal (small arrows).

B, CT scan of research skull. Axial image shows larger right inferior rotundal canal (arrow) and smaller left canal (arrowhead) arising from the floor of foramen rotundum.

C, Coronal image shows the inferior rotundal canal coursing through sphenoid bone laterally to sphenoid sinuses (arrows).

clearly be linked to it (Fig 4). We propose calling this the *lateral rotundal canal*. It generally had an inferolateral course and opened to the infratemporal fossa. Neither the precise nature of this canal nor its transmitted structures are known, but we believe it probably transmits an emissary vein and therefore may function similarly to the foramen of Vesalius (see following discussion).

#### *Foramen of Vesalius*

Also known as the sphenoid emissary foramen, this small variable structure allows communication between the middle cranial fossa and the scaphoid fossa. It transmits an emissary vein that connects the cavernous sinus to the pterygoid venous plexus (1, 2, 4, 5). Work by Henderson (6) in 1966, however, suggests that this structure is actually a dural sinus rather than a vein. The foramen of Vesalius is generally anteromedial to the foramen ovale and is unique to humans (Fig 1) (7). It is typically less than 2 mm in diameter (5, 8, 9). Earlier literature suggested a prevalence of this structure, either unilaterally or bilaterally, of approximately 40% of patients. These figures stem primarily from Boyd's examination of 1500 skulls (9). More recently, radiologic work by Lanzieri et al (5) suggested a higher incidence after observing the foramen of Vesalius in 39 (72.2%) of 54 patients. We observed that the foramen of Vesalius was present unilaterally in 38 (30.8%) and bilaterally in 60 (48.7%) of our patients. Therefore, this foramen was present at least unilaterally in 80% of our patients. Our findings agree more closely with those of Lanzieri and colleagues than with earlier work and suggest that this variant foramen is more common than previously thought. To some extent, our higher figure probably reflects the greater sensitivity and resolution of the zoomed, high-resolution bone studies we reviewed. Variants specifically sought included asymmetry of size (when bilateral), duplication, confluence or assimilation with the foramen ovale, and relationship to the foramen ovale (see Table 1).

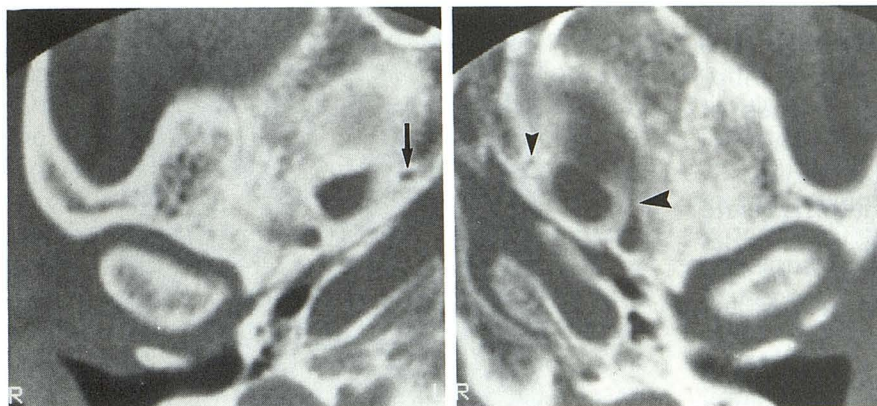
Lanzieri et al (5) suggested that asymmetry of size was a likely indicator of underlying disease. In four of their six cases, asymmetry was associated with an abnormality, including a carotid-cavernous fistula with inferior venous drainage through the foramen of Vesalius, destruction by tumor, and neurofibromatosis. In contrast, none of our 15 cases of bilaterality with asymmetry of size was associated with any detectable abnor-

mality (Fig 5). Therefore, asymmetry of the foramina of Vesalius may not be particularly worrisome, although an explanation should be sought. Confluence or partial assimilation of the foramen of Vesalius with the foramen ovale was observed in eight cases, all unilateral (Fig 6). Recognizing the potential for overestimation of confluence in this group, we included only cases in which the foramen of Vesalius and foramen ovale were clearly in intimate relationship with each other, almost sharing the same foramen. A bony separation was grounds for exclusion. Confluence of the foramen of Vesalius with the foramen ovale is easily understood, considering that they transmit similar venous structures. In fact, when the foramen of Vesalius is not present, the sphenoid emissary vein is thought to pass through the foramen ovale (1, 6, 7). Indeed, the foramen of Vesalius may form by the development of a bony spicule in the anterior aspect of the foramen ovale, thus dividing it into two separate foramina (7). Therefore, varying degrees of confluence or separation of these two structures may be explained by what is essentially their common goal.

The possible secondary effects of the foramen of Vesalius on the size of the ipsilateral foramen ovale will be addressed in the following section. Duplication of the foramen of Vesalius was observed in 17 (17.3%) of our 98 patients who had a foramen of Vesalius (Fig 7) and was bilateral in two patients. The possibility of duplication is known from anatomic studies (7), but the relatively high incidence in our study was surprising. We postulate that the canals we identified lateral to the foramen rotundum but not draining directly from it, which we called the lateral rotundal canals, may in fact function similarly to the foramen of Vesalius. If so, their presence, in a way, represents duplication of the foramen of Vesalius.

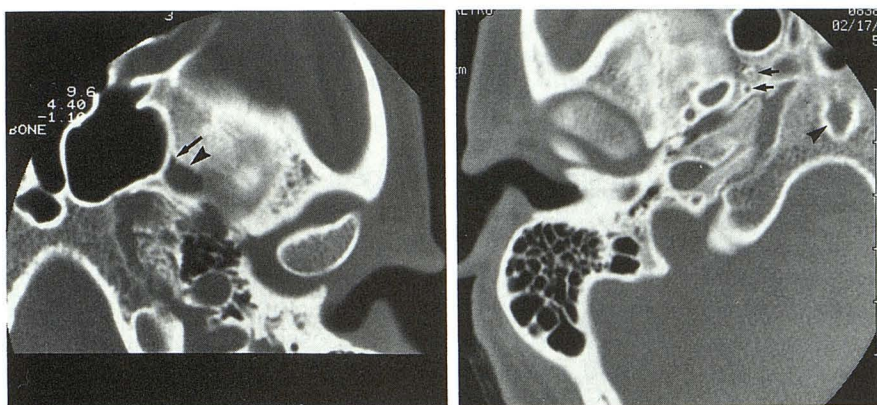
#### *Foramen Ovale*

Situated along the posteromedial aspect of the greater wing of the sphenoid bone, the foramen ovale connects the middle cranial fossa with the infratemporal fossa. This foramen is oriented slightly ventrally and laterally, corresponding to the direction of the mandibular division of the trigeminal nerve, its main transmitted structure. This nerve provides motor supply to the masticatory muscles, as well as sensory innervation of the skin of the temporal region, lower face, and lips, the lower teeth and gums, the mandible, the



5

Fig. 5. Asymmetry of the foramina of Vesalius. The right foramen of Vesalius (*arrow*) is larger than the left (*small arrowhead*). No explanation was found. On the *left*, the groove for the exiting middle meningeal artery branch is present anteriorly (*large arrowhead*).



6

7

Fig. 6. Confluence of foramina. Antero-medially, the foramen of Vesalius (*arrow*) is confluent with the foramen ovale (*arrowhead*).

Fig. 7. Duplication of the foramina of Vesalius. Two right foramina of Vesalius are present (*arrows*). Bony defect in clivus may represent a large craniopharyngeal canal or transphenoidal encephalocele (*arrowhead*).

temporomandibular joint, and a portion of dura (1). The foramen ovale is believed to develop from the primitive foramen lacerum medius, which in lower mammals is the space between the alisphenoid (precursor of the greater sphenoid wing), the basisphenoid, and the petrotic capsule or petrous bone (2, 7). In humans, this space persists as the foramen lacerum after formation of the carotid canal medially and the sphenopetrosal fissure posterolaterally (7). In lower mammals, the mandibular division of the trigeminal nerve is contained within the foramen lacerum medius between the internal carotid and stapedial arteries (2). As the mandibular nerve sinks into the greater wing of the sphenoid bone, first a groove, then a notch, and ultimately a true foramen develop (7). This transitional development of the foramen ovale is demonstrable in lower mammals and may explain some of the variants of this foramen observed in humans.

Deficiency of the medial bony wall or communication with the foramen lacerum or sphenopetrosal fissure was seen in two (1.6%) of our patients (Fig 8). In one patient this finding was bilateral. We did not observe more primitive variants in our patients, such as nearly complete

absence of the foramen ovale as a separate orifice, the so-called persistent foramen lacerum medius (2, 7). The fact that a relatively well-formed foramen ovale was seen in each of our cases suggests constancy of this foramen (except for occasional absence of its medial wall). Likewise, we did not observe any variation in the location of the foramen ovale, such as an aberrant anterior or lateral position (2, 7). Because the foramen spinosum develops in a manner similar

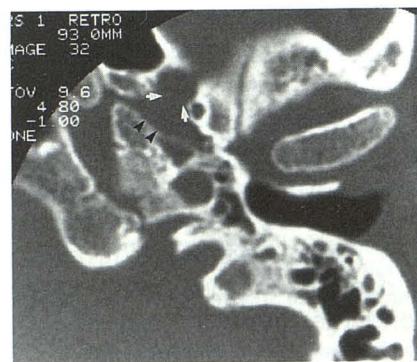

Fig. 8. Medial foramen ovale defect. The medial wall is absent in the left foramen ovale (*arrows*), and the foramen communicates with the sphenopetrosal fissure (*arrowheads*).

to that of the foramen ovale, confluence of these two foramina is a well-described variant but was seen only in two (1.6%) of our patients. Confluence of the foramen ovale and the foramen of Vesalius occurred in eight (6.5%) of 123 patients and has been described in more detail above.

Other variants of foramen ovale anatomy relate to the other neurovascular structures it transmits in addition to the mandibular division of the trigeminal nerve. When the foramen of Vesalius is absent, the sphenoid emissary vein exits through the anterior aspect of the foramen ovale (2). Previous reports (2, 7) indicated that when the foramen of Vesalius is present unilaterally, the ipsilateral foramen ovale is consequently smaller. Although this concept has both a logical and an empirical basis, we observed that in our 38 cases of unilateral foramen of Vesalius, the ipsilateral foramen ovale was smaller in only six (15.7%) patients. Regarding the 32 cases in which the ipsilateral foramen ovale was at least equal in size or larger, it is presumed that the size of the foramen ovale was influenced by the presence of other vascular structures. Lindblom (8) showed that a plexus of veins is transmitted through the foramen ovale. He believed that these veins accounted for variations in size and shape of the foramen ovale. Henderson (6) demonstrated that these structures histologically were dural sinuses consisting of a wall of dura lined by endothelium. Therefore, venous asymmetry probably accounts for asymmetry in the size and shape of the foramina ovale. We observed asymmetry in shape (round versus oval) in 29 (23.5%) of our patients and asymmetry of size in 38 (30.9%) of our patients. In no case was either asymmetry attributable to disease. To our knowledge, complete absence of the foramen ovale has not been described.

Additional structures are known to traverse the foramen ovale, but because of their small size they probably do not significantly influence its size or shape. An accessory meningeal branch of the internal maxillary artery may enter the skull through the foramen ovale in its posterolateral aspect (1). It supplies the gasserian ganglion and a portion of dura. A separate foramen for this artery was described in one case, as was a slit or groove along the lateral aspect of the foramen ovale (1). However, in his series, Lindblom (8) could not identify vascular grooves. We saw grooving along the posterolateral aspect of the foramen ovale in 14 (11.4%) of our patients (Fig

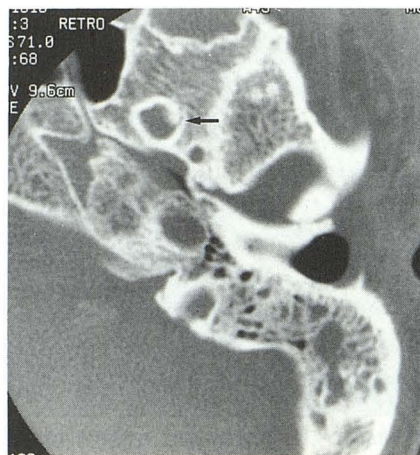

Fig. 9. Posterolateral groove in the foramen ovale. A small groove is seen along the posterolateral aspect of the left foramen ovale (arrow), accommodating the accessory meningeal artery.

9) and suspect that it represents the course of the accessory meningeal artery.

An inverse relationship has been reported (8) between the relative sizes of the foramen ovale and the foramen spinosum. If the foramen spinosum is small or absent, increased dural blood supply from a larger accessory meningeal artery could conceivably enlarge the foramen ovale. In our study, the foramen spinosum was smaller or absent in 24 patients, yet was associated with a larger foramen ovale in only four cases (16%). Therefore, this inverse relationship does not appear to be valid. Finally, the lesser superficial petrosal nerve exits via the foramen ovale in the absence of a canaliculus innominatus (1, 2, 4). Because of its extremely small caliber, this nerve is not likely to influence the size or shape of the foramen ovale.

#### *Canaliculus Innominatus*

Also known as the canal of Arnold, the canaliculus innominatus is a very small canal situated medially between the foramen ovale and the foramen spinosum (1, 4). When present, this canal transmits the lesser superficial petrosal nerve, a tiny nerve originating from the tympanic branch of the glossopharyngeal nerve but also containing several fibers from the facial nerve (4). The lesser superficial petrosal nerve exits the petrous bone from its superior surface via a small hiatus immediately lateral to the hiatus for the greater superficial petrosal nerve. Coursing anteriorly and inferomedially, the lesser superficial petrosal nerve exits either through the canaliculus innominatus or, in its absence, through the fora-

men ovale (4). This nerve provides preganglionic parasympathetic fibers that synapse in the otic ganglion immediately inferior to the foramen ovale. Postganglionic fibers then continue along the auriculotemporal nerve (a branch of V3) to innervate the parotid gland. Sondheimer (1) observed the canal of Arnold as a slit-like opening between the foramen spinosum and the sphenopetrosal fissure or as a more rounded, true foramen in approximately 20% of 50 base-view skull radiographs. Believing grooves or slit-like structures were too nonspecific, we included only clearly well-formed foramina seen on two adjacent sections. We also required that this structure be medial to a line drawn along the long axis of the foramen ovale extending through the foramen spinosum. Using these criteria, we observed the canaliculus innominatus in 20 (16.3%) of our patients (Figs 10 and 11). Given the paucity of pertinent imaging literature and the lack of anatomic confirmation, some doubt remains in describing this structure. Nonetheless, because numerous anatomic references (4, 8, 10) and at least one radiologic reference (1) describes the location of the canaliculus innominatus precisely where we have identified it, we believe it is an accurate finding. To our knowledge, this relatively obscure anatomic structure has not been reported previously in the CT literature.

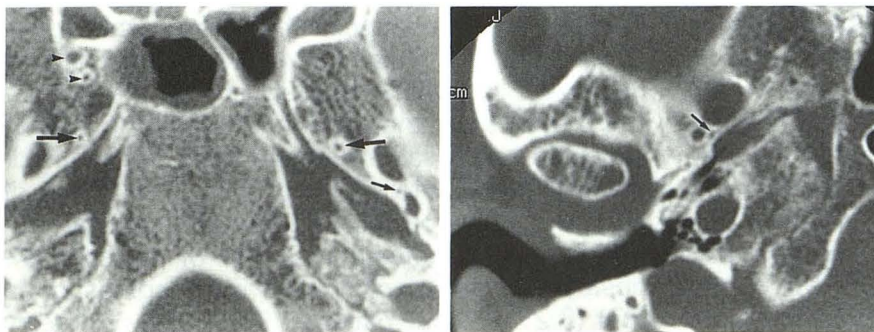
### Foramen Spinosum

This small opening is located posterolaterally to the foramen ovale, along the posteromedial aspect of the greater wing of the sphenoid bone. It is generally 2 to 4 mm long with an average diameter of approximately 1.5 to 3.0 mm (1). It is usually round or oval in shape. The foramen spinosum allows communication between the middle cranial fossa and the infratemporal fossa. Its exocranial opening may be within or just anterior to the sphenoid spine (1). Transmitted

structures include the middle meningeal branch of the external carotid artery, the middle meningeal vein(s), and a recurrent branch of the mandibular nerve (nervus spinosus) (1, 2).

Congenital variants of the foramen spinosum are generally related to defects in osteogenesis or to maldevelopment of the middle meningeal artery (1). Defects in osteogenesis relate to the development of the foramen spinosum in the presence of a middle meningeal artery. Embryologically this artery originates as a supraorbital branch of the stapedia artery, coursing between the petrous bone and the alisphenoid, and intimately related to the mandibular nerve. With atrophy of the stapedia artery, the middle meningeal artery forms an anastomosis with the external carotid artery (7). Thus the middle meningeal artery enters the cranial cavity within the primitive foramen lacerum medius, analogously to the mandibular nerve. Similarly, the foramen spinosum forms as the artery sinks into the alisphenoid (7). As with the foramen ovale, the foramen spinosum may exhibit varying degrees of incomplete formation ranging from a small notch or groove in the greater wing of the sphenoid bone to merely absence of a medial wall, allowing communication with the sphenopetrosal fissure. We observed a medial defect in 33 (26.8%) of our patients (Fig 12). The similarity of development of the foramen ovale and the foramen spinosum accounts for the possible confluence of these foramina. As mentioned above, this occurrence was observed in two (1.6%) of our patients (Fig 13). An extremely primitive variant, persistence of the foramen lacerum medius, is defined as confluence of the foramen ovale and the foramen spinosum and absence of a medial bony separation from the foramen lacerum (1). We did not observe this configuration in any of our patients and assume it to be quite uncommon.

The other source of variation of foramen spinosum anatomy relates to maldevelopment of

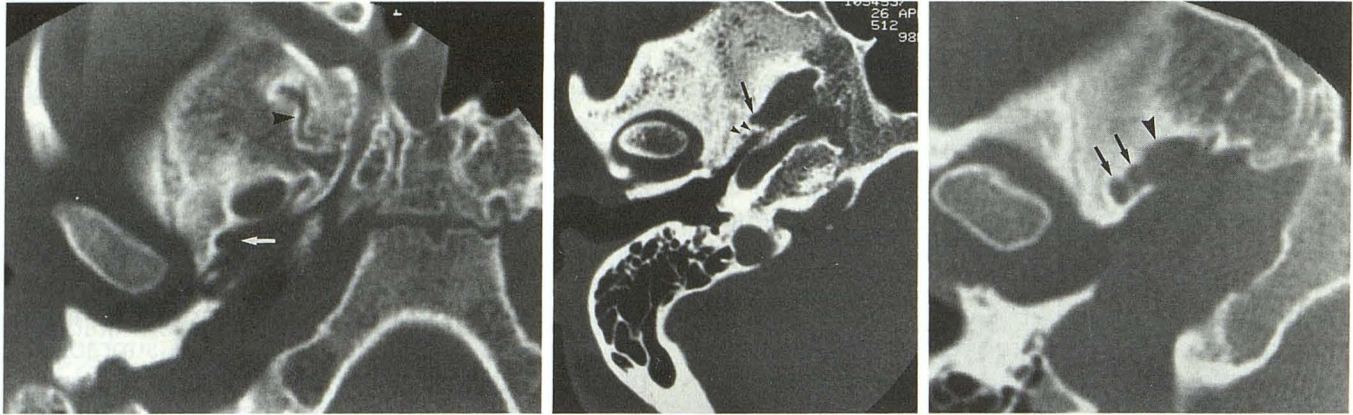


10

11

Fig. 10. Canaliculus innominatus. A small foramen on the *left* between the foramen ovale and the foramen spinosum represents the canaliculus innominatus (*small arrow*). Foramina lateral to right sphenoid sinus represent inferior and/or lateral rotundal canals (*arrowheads*). Foramina of Vesalius are present bilaterally and are asymmetric (*large arrows*).

Fig. 11. Canaliculus innominatus. A right-sided canaliculus innominatus is present (*arrow*).



12

Fig. 12. Medial spinal defect. The medial wall of the foramen spinosum is absent (*arrow*), and the foramen communicates with the sphenopetrosal fissure. Note the very tortuous course of the lateral rotundal canal (*arrowhead*).

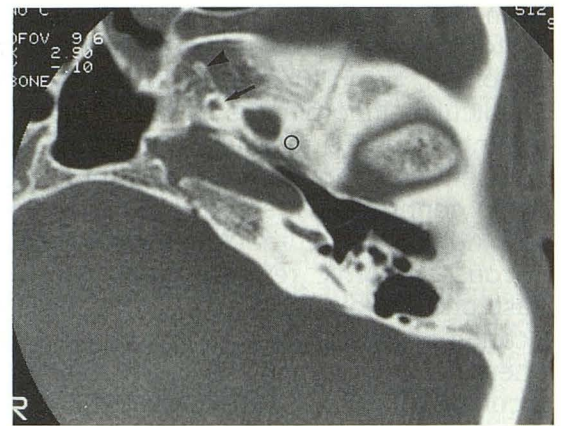
13

Fig. 13. Confluence of right foramen spinosum and foramen ovale. The right foramen spinosum (*arrow*) appears to be confluent with the foramen ovale. Two smaller posterior foramina (*arrowheads*) are of uncertain origin but may represent an accessory middle meningeal artery foramen or canaliculus innominatus.

14

Fig. 14. Duplication of right foramen spinosum (*arrows*). The foramen ovale (*arrowhead*) is probably confluent with the more anterior foramen spinosum.

Fig. 15. Absence of foramen spinosum. No foramen is observed posterolaterally to the left foramen ovale, where a foramen spinosum would be expected (*circle*). Note the prominent foramen of Vesalius (*arrow*). A smaller anterior canal probably represents a lateral rotundal canal or duplicated foramen of Vesalius (*arrowhead*).



15

the middle meningeal artery. Lindblom (8) stated that in rare cases, early division of the middle meningeal artery into an anterior and posterior division may result in duplication of the foramen spinosum; this variation also was observed by Sondheimer (1). We observed this duplication in only one patient (Fig 14). The foramen spinosum may be hypoplastic or absent in the case of an aberrant middle meningeal artery. Curnow (11) first described hypoplasia of the foramen spinosum in association with origin of the middle meningeal artery from the ophthalmic artery. Fisher (12) and Greig (10) have explained the embryologic development of the middle meningeal artery. The stapedia artery originates as a dorsal branch of the second aortic arch and is therefore part of the internal carotid system. Its superior or supraorbital branch is destined to become the middle meningeal artery. In the 15-mm embryo, the infraorbital and mandibular divisions of the stapedia artery fuse with the external carotid artery, destined to become the internal maxillary artery (10, 12). At the same time, the main trunk of the stapedia artery atrophies and loses its origin from the internal carotid

artery. Therefore, the bulk of the stapedia distribution (including its supraorbital branch) is then fed by the external carotid artery (10, 12). If the communication to the external carotid system fails to develop, the middle meningeal artery may arise from the ophthalmic artery (10). In this case, the middle meningeal artery enters the skull through the superior orbital fissure (10, 11). Lindblom (8) observed this anomaly in 0.4% of his cases. In other cases, failure of the stapedia artery to regress results in a persistent stapedia artery (13, 14). This vessel may or may not be associated with an aberrant internal carotid artery. The persistent stapedia artery courses through the tympanic cavity between the crura of the stapes and enters the facial nerve canal distal to the geniculate ganglion. It then enters the middle cranial fossa via the facial hiatus (for the greater superficial petrosal nerve) and becomes the middle meningeal artery (13, 14). In both cases of aberrant origin of the middle meningeal artery, the foramen spinosum is tiny or absent. We observed absence of the foramen spinosum in four (3.2%) of our patients (Fig 15). Asymmetry of size was observed in 20 (16%) of our patients,



but as mentioned in the discussion of the foramen ovale, a smaller foramen spinosum usually did not correlate with a larger ipsilateral foramen ovale.

### Conclusion

In interpreting CT scans of the skull base and temporal bone, one is often faced with small holes in the skull base of which the nature may be unclear. Many of these holes are probably small emissary foramina. Some, such as the foramen of Vesalius, are named because they are present in large numbers of patients in a relatively constant location. However, others that are less well known could be mistaken for abnormalities, especially in patients who have neoplastic or vascular lesions. These foramina could certainly be a source of curiosity or uncertainty. Recognition of variants is therefore important to avoid potential confusion. We hope that recognition of the inferior rotundal canal, the lateral rotundal canal, and the canaliculus innominatus or canal of Arnold will result in a better understanding of skull-base neurovascular anatomy and diminish speculation as to their true nature during interpretation of CT examinations.

### Acknowledgments

We gratefully acknowledge the assistance of Julianne Berckman, Donna Garrison, and Nancy Ragland in the preparation of this manuscript.

### References

1. Sondheimer FK. Basal foramina and canals. In: Newton TH, Potts DG, eds. *Radiology of the skull and brain: the skull*. Vol 1, Book 1. St. Louis: Mosby, 1971:287-347
2. Shapiro R, Robinson F. The foramina of the middle fossa: a phylogenetic, anatomic and pathologic study. *AJR Am J Roentgenol* 1967;101:779-794
3. LeDouble AF. *Traité des variations de os du crâne de l'homme*. Vol 1. Paris: Vigot Frères, 1903
4. Williams PL, Warwick R, Dyson M, Bannister LH, eds. *Gray's anatomy of the human body*. 37th ed. New York: Churchill Livingstone, 1989:362-377
5. Lanzieri CF, Duchesneau PM, Rosenbloom SA, Smith AS, Rosenbaum AE. The significance of asymmetry of the foramen of Vesalius. *AJNR Am J Neuroradiol* 1988;9:1201-1204
6. Henderson WR. A note on the relationship of the human maxillary nerve to the cavernous sinus and to an emissary sinus passing through the foramen ovale. *J Anat* 1966;100:905-908
7. Wood-Jones F. The non-metrical morphological characters of the skull as criteria for racial diagnosis. Part 1: general discussion of the morphological characters employed in racial diagnosis. *J Anat* 1931;65:179-195
8. Lindblom K. A roentgenographic study of the vascular channels of the skull, with special reference to intracranial tumors and arteriovenous aneurysms. *Acta Radiol [Suppl] (Stockh)* 1936;30:1-146
9. Boyd GI. The emissary foramina of the cranium in man and the anthropoids. *J Anat* 1930;65:108-121
10. Greig DM. Congenital anomalies of the foramen spinosum. *Edinburgh Med J* 1929;36:363-371
11. Curnow J. Two instances of irregular ophthalmic and middle meningeal arteries. *J Anat* 1873;8:155-156
12. Fisher AGT. A case of complete absence of both internal carotid arteries with a preliminary note on the developmental history of the stapedia artery. *J Anat* 1914;48:37-46
13. Guinto FC Jr, Garrabrant EC, Radcliffe WB. Radiology of the persistent stapedia artery. *Radiology* 1972;105:365-369
14. Lasjaunias P, Moret J. Normal and non-pathological variations in the angiographic aspects of the arteries of the middle ear. *Neuroradiology* 1978;15:213-219