

MR Appearance of Virchow-Robin Spaces along Lenticulostriate Arteries: Spin-Echo and Two-Dimensional Fast Low-Angle Shot Imaging

Norio Hirabuki, Norihiko Fujita, Keiko Fujii, Tsutomu Hashimoto, and Takahiro Kozuka

PURPOSE: To delineate the appearance of normal Virchow-Robin spaces on routine spin-echo images and demonstrate the lenticulostriate arteries within them with a flow-sensitive fast low-angle shot (FLASH) pulse sequence. **METHODS:** Seventy subjects, free of cerebrovascular diseases and other neurologic disorders, ranging in age from 1 to 75 years, were examined. On a 1.5-T MR system, axial spin-echo images of 5 mm thickness were obtained in all subjects. In 45 of 70 subjects axial two-dimensional FLASH images of 3 mm thickness were contiguously imaged. **RESULTS:** On T1- and spin density-weighted images Virchow-Robin spaces were detected as small foci of cerebrospinal fluid intensity around the anterior commissure in all subjects (100%), and in the basal ganglia at the level of the foramen of Monroe in 40 (57%). T2-weighted images equally showed Virchow-Robin spaces around the anterior commissure but were less sensitive than T1- and spin-density weighted images at the level of the foramen of Monroe (14%). Virchow-Robin spaces identified on T2-weighted images should be isointense with cerebrospinal fluid. However, one or two spaces in 11 younger subjects were hypointense relative to adjacent brain tissue. On FLASH images most Virchow-Robin spaces identified on spin-echo images were delineated as high-intensity foci, corresponding to lenticulostriate arteries. **CONCLUSIONS:** Normal Virchow-Robin spaces along the lenticulostriate arteries are frequently detected on spin-echo images. Their appearance, affected by the flow of associated lenticulostriate arteries, varies from hyper- to hypointensity to brain tissue on T2-weighted images. The two-dimensional FLASH sequence can demonstrate the flow of the arteries, thereby helping confirm that these are truly Virchow-Robin spaces.

Index terms: Brain, anatomy; Brain, magnetic resonance; Lentiform nucleus; Virchow-Robin spaces; Magnetic resonance, technique; Magnetic resonance, tissue characterization

AJNR Am J Neuroradiol 15:277-281, Feb 1994

The Virchow-Robin spaces are now understood as extensions of the subarachnoid space around perforating arteries penetrating into brain parenchyma (1, 2). Although recognized in the anatomic literature, the development of high-field magnetic resonance (MR) permitted the precise observation of these spaces in the living brain (3-6). Large Virchow-Robin spaces around the len-

ticulostriate arteries were demonstrated as cerebrospinal fluid (CSF)-intensity foci at the anterior commissure in MR imaging, and were distinguishable from lacunar infarcts and demyelination based on anatomic location and intensity (3).

The MR imaging appearance of normal Virchow-Robin spaces along the lenticulostriate arteries has not been covered in detail. Because dilated lenticulostriate arteries in the basal ganglia are seen as flow voids in moyamoya disease (7-10), it was hypothesized that the arterial flow might affect the appearance of normal Virchow-Robin spaces. The aims of this study are to delineate the appearance of the Virchow-Robin spaces in routine spin-echo imaging and to demonstrate the lenticulostriate arteries within them, using a flow-sensitive fast low-angle shot (FLASH) pulse sequence.

Received December 22, 1992; accepted pending revision February 9, 1993; revision received March 3.

From the Department of Radiology, Osaka University Medical School, Osaka Japan.

Address reprint requests to N. Hirabuki, MD, Department of Radiology, Osaka University Medical School, 1-1-50 Fukushima, Fukushima-ku, Osaka 553, Japan.

AJNR 15:277-281, Feb 1994 0195-6108/94/1502-0277

© American Society of Neuroradiology

Subjects and Methods

MR images of 70 subjects, free of cerebrovascular diseases and other neurologic disorders, were studied. Subjects ranged in age from 1 to 75 years (1 to 25 years, $n = 20$; 26 to 50 years, $n = 24$; older than 51 years, $n = 26$).

All studies were performed on a 1.5-T MR system with a circular-polarizing coil. T1-, spin density- and T2-weighted axial images of the entire brain were obtained using spin-echo sequences 630/15/2 (repetition time/echo time/excitations) for T1-weighted images, and a double-echo sequence 2500/15,90/1 for spin density- and T2-weighted images. Other scan parameters were 5-mm section thickness with a 0.5- to 1-mm intersection gap, 21-cm field of view, and 192×256 acquisition matrix.

Simultaneously in 45 selected subjects a set of contiguous axial sections covering the lenticulostriate arteries were imaged with a two-dimensional FLASH pulse sequence with 3-mm-thick sections. The sequence was first-order gradient moment nulled in the read and section-select directions, and a 90° flip angle was used for maximum flow-related enhancement and adequate suppression of background tissue. Other parameters were 80/7/1, 21-cm field of view, and 192×256 acquisition matrix.

On spin-echo images those areas around the anterior commissure and in the basal ganglia were defined as normal Virchow-Robin spaces only if several criteria were met. The spaces had to be isointense relative to CSF on both T1- and spin density-weighted images. They had to be round, oval, or curvilinear with well-defined margins and conform to the path of perforating arteries. Five millimeters was chosen as the upper limit of normal because areas of this size and smaller are frequent normal neuropathologic findings at autopsy (5).

Results

On T1- and spin density-weighted images, Virchow-Robin spaces of CSF intensity, usually one to three in number on each side, were demonstrated around the anterior commissure in all subjects (100%), and fewer Virchow-Robin spaces were scattered in the basal ganglia at the level of the foramen of Monroe on at least one side in 40 (57%) (Fig 1, A and B). On T2-weighted images comparable foci were seen around the anterior commissure in all subjects, but at the level of the foramen of Monroe in only 10 (14%).

Such foci identified on T2-weighted images should be of CSF (high) intensity (Fig 1, C and D). However, one or two foci were hypointense relative to adjacent brain tissue in 11 of 20 subjects younger than 26 years old (Fig 2). Although the number and size of Virchow-Robin spaces had no apparent correlation with age, a large Virchow-Robin space over 5 mm was found in one subject age 68 years (Fig 3). There were very few Virchow-Robin spaces detected above the level of the foramen of Monroe even on T1- and spin density-weighted images.

On FLASH images, most Virchow-Robin spaces identified on spin-echo images were delineated as high-intensity foci, corresponding to lenticulostriate arteries (Fig 1, E and F).

Discussion

The Virchow-Robin spaces are extensions of the subarachnoid space accompanying penetrating vessels to the level of capillaries (1, 2). The high soft-tissue sensitivity of MR imaging allows for the detection of such small CSF-filled spaces in the anterior perforated substance and less frequently in the vertex and brain stem, and the intensity of the spaces shows the characteristic CSF signal pattern (3-5). The anterior commissure is an important landmark for locating spaces along the lenticulostriate arteries (5).

In our series some Virchow-Robin spaces around the anterior commissure were always detected in all spin-echo sequences (100%); whereas Virchow-Robin spaces in the basal ganglia at the level of the foramen of Monroe were detected in about half the subjects on T1- and spin density-weighted images and were seldom detected on T2-weighted images. The frequency of the detection of Virchow-Robin spaces in our study was higher than in a previous report in which the overall frequency of detection was 59% (5). The reasons possibly stem from the fact that our observations were based on T1- and spin density-weighted images, which enabled detection of smaller foci.

A Virchow-Robin space contains CSF and a perforating artery. CSF and arteries have similar low intensity on routine T1- and spin density-weighted images, and the detection of the space depends on the size. On one hand, tapering of the Virchow-Robin space explains the lower detectability in the higher location. On the other hand, CSF and arteries have high and low intensity, respectively, on T2-weighted images. The

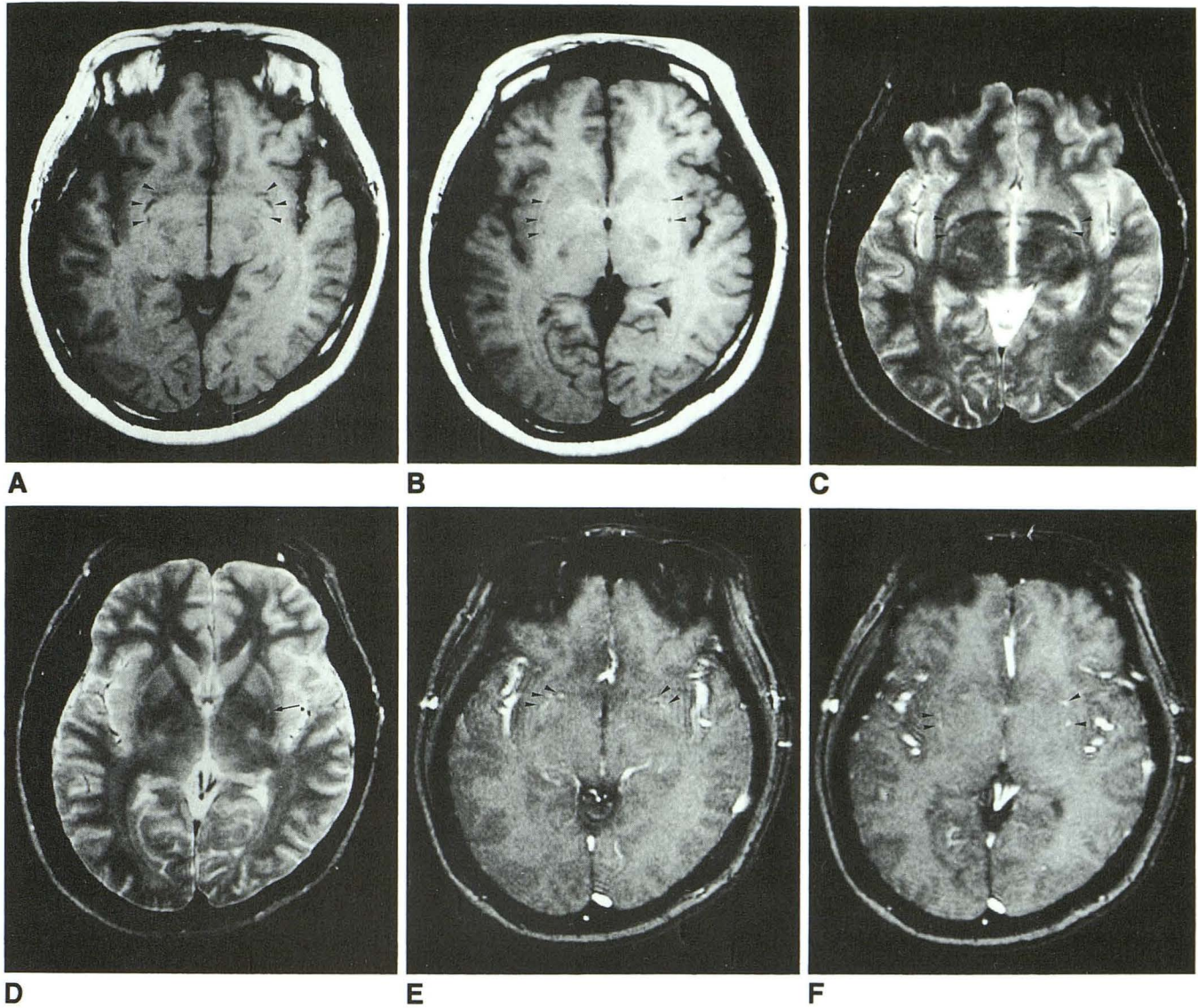


Fig. 1. Spin-echo and FLASH images in a 30-year-old woman. On T1-weighted images (630/15/2) several Virchow-Robin spaces of low-intensity (*arrowheads*) are seen around the anterior commissure (A) and in the basal ganglia of both sides (B). On T2-weighted images (2500/90/1) comparable foci of CSF (high)-intensity are seen around the anterior commissure (*arrows*) (C) and in the left basal ganglia (*arrow*), but not in the right basal ganglia (D). Most Virchow-Robin spaces are delineated as high intensity on FLASH sequence images (80/7/1) because of flow of lenticulostriate arteries (*arrowheads*) (E, F).

detection and appearance of the Virchow-Robin space on T2-weighted images are expected to be also dependent on the proportion of both components. The proportion of an artery to its surrounding CSF is very small in large Virchow-Robin spaces and the artery itself is smaller than the pixel size; therefore, those spaces are demonstrated as high intensity on T2-weighted images (3, 5) (Fig 3). Actually, the diameters of the arteries are 250 to 400 μm despite the fact that in-plane voxel areas in our study are 0.8 mm \times 1.1 mm. However, in a tapered Virchow-Robin space, which contains smaller volume of CSF,

the high intensity of CSF and the flow void of a lenticulostriate artery may cancel out to result in isointensity with background tissue. A long echo-time on T2-weighted images will allow such flow effects to greater extent. This is a likely explanation for the lowest detectability of the Virchow-Robin spaces in the basal ganglia on T2-weighted images. Likewise, hypointense foci seen on T2-weighted images are attributable to large lenticulostriate arteries with relatively less CSF.

Our two-dimensional FLASH imaging could demonstrate the lenticulostriate arteries despite their smaller size. The result is further evidence

Fig. 2. Spin-echo images in a 12-year-old girl. Virchow-Robin spaces (*arrowheads*) are seen in the basal ganglia on a spin density-weighted image (2500/15/1) (A). One of them (*arrow*) is hypointense; the others are not seen on a T2-weighted image (2500/90/1) (B).

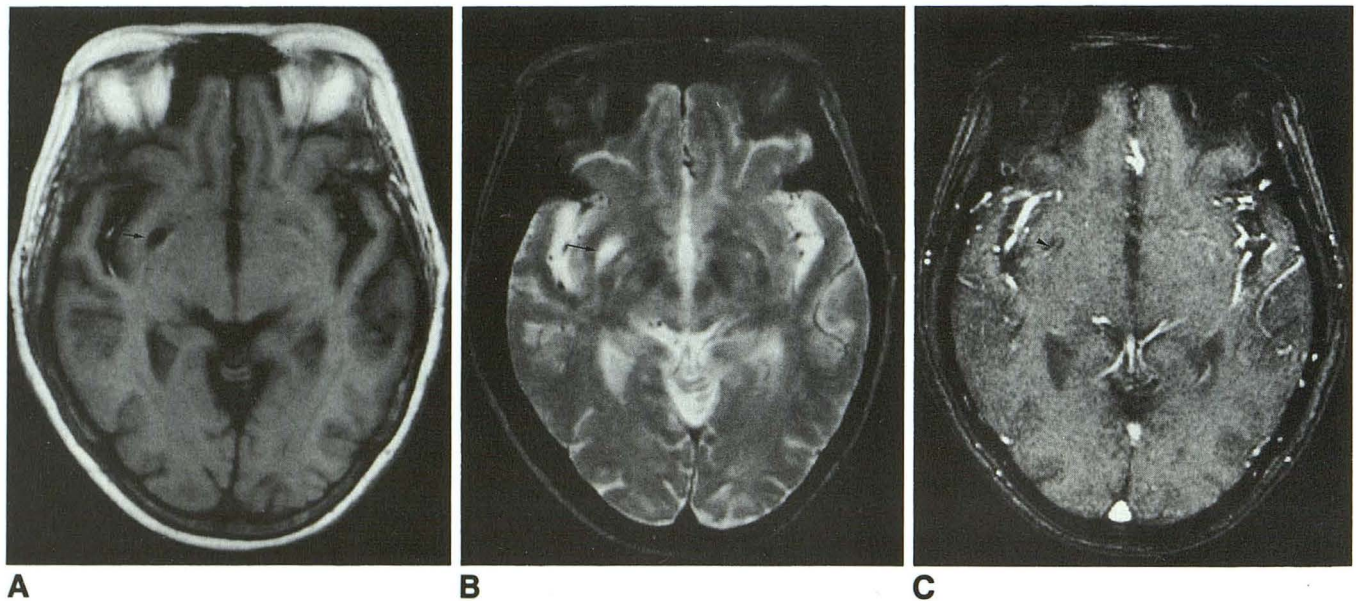
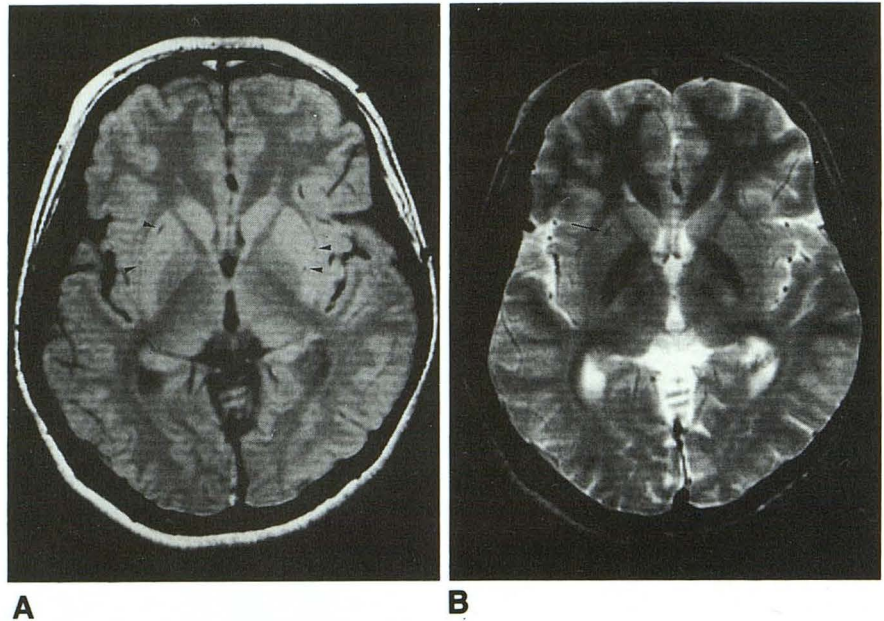


Fig. 3. Large Virchow-Robin space in a 68-year-old man. A large Virchow-Robin space over 5 mm (*arrow*) is seen in the right basal ganglia, which is isointense with CSF on both T1- (630/15/2) (A) and T2-weighted images (2500/90/1) (B). A high-intensity curve across the space (*arrowhead*) is seen on a FLASH image (80/7/1), corresponding to a lenticulostriate artery (C).

of the considerable effects of flow on the appearance of the Virchow-Robin spaces. Meanwhile, the demonstration of the arteries was not perfect in our study. Although this is partly because the section position of a FLASH image did not always coincide with that of comparable spin-echo images, to ensure the demonstration, further improvement of techniques is required.

Large Virchow-Robin spaces are related to aging, as is the enlargement of the subarachnoid space elsewhere (3). Even without atherosclero-

sis, vessels become larger and more tortuous with aging (11, 12). After age 30 years, the tortuosity of the lenticulostriate arteries abruptly increases (13). The unfolding of these tortuous vessels may account for the enlarged perivascular spaces (14). However, in our series, the size of Virchow-Robin spaces was not significantly different in each age group. Instead, hypointense Virchow-Robin spaces on T2-weighted images were seen exclusively in younger people. This fact indicates that the substantial flow of a lenticulostriate artery is

relatively greater in youth, possibly because of less tortuosity of the artery.

The dilation of the lenticulostriate arteries in the basal ganglia, demonstrated as flow voids with MR imaging, is a characteristic finding of moyamoya disease (7–10). This finding can be the only evidence of the disease on MR imaging (9). However, as described above, even hypointense foci on T2-weighted images do not always mean dilated arteries (Fig 2). Caution is needed in the diagnosis of moyamoya disease, especially when the occlusive change in the circle of Willis is not apparent.

The differentiation between a Virchow-Robin space and lacunar infarction and demyelination is a problem among elderly patients because such pathologic lesions increase with aging (5, 6, 15–18). Pathologically, a Virchow-Robin space differs from a small infarction in respect to its site, state of the associated blood vessel, and cell content within the cavity (14, 19). In MR imaging, lacunar infarction is typically higher in signal intensity than CSF on T1- and spin density-weighted images, and the differentiation can be made based on the intensity and anatomic location (3, 5). However, at times, differentiation from true pathologic foci may not be possible (5). For such instances, the flow-sensitive FLASH sequence, which can demonstrate the presence of perforating arteries within such foci, may help confirm Virchow-Robin spaces (Fig 3C).

In conclusion, the Virchow-Robin spaces around the lenticulostriate arteries are more frequently detected on spin-echo images than previously reported. Their appearance on T2-weighted images varies from hyperintensity to isointensity to hypointensity to brain tissue depending on the size of the spaces and the flow of associated lenticulostriate arteries. The two-dimensional FLASH sequence can demonstrate the flow of the arteries, thereby helping confirm the presence of Virchow-Robin spaces, and may distinguish them from lacunar infarctions and moyamoya disease.

References

1. Woollam DHM, Millen JW. Perivascular spaces of the mammalian CNS. *Biol Rev* 1954;29:251–283
2. Jones EG. On the mode of entry of blood vessels into the cerebral cortex. *J Anat* 1970;106:507–520
3. Heier LA, Bauer CJ, Schwartz L, Zimmerman RD, Morgello S, Deck MDF. Large Virchow-Robin spaces: MR-clinical correlation. *AJNR Am J Neuroradiol* 1989;10:929–936
4. Elster AD, Richardson DN. Focal high signal on MR scans of the midbrain caused by enlarged perivascular spaces: MR-pathologic correlation. *AJNR Am J Neuroradiol* 1990;11:1119–1122
5. Jungreis CA, Kanal E, Hirsch WL, Martinez AJ, Moosy J. Normal perivascular spaces mimicking lacunar infarction: MR imaging. *Radiology* 1988;169:101–104
6. Braffman BH, Zimmerman RA, Trojanowski JQ, Gonatas NK, Hickey WF, Schlaepfer WW. Brain MR: pathologic correlation with gross and histopathology. 1. lacunar infarction and Virchow-Robin spaces. *AJNR Am J Neuroradiol* 1988;9:621–628
7. Fujisawa I, Asato R, Nishimura K, et al. Moyamoya disease: MR imaging. *Radiology* 1987;164:103–105
8. Hasuo K, Yasumori K, Yoshida R, et al. Magnetic resonance imaging compared with computed tomography and angiography in moyamoya disease. *Acta Radiol* 1990;31:191–195
9. Brown WG, Graves VB, Chun RWM, Turski PA. Moyamoya disease: MR findings. *J Comput Assist Tomogr* 1989;13:720–723
10. Wilms G, Marchal G, Van Fraeyenhoven L, et al. Unilateral moyamoya disease: MRI findings. *Neuroradiology* 1989;31:442
11. Nelson MD Jr, Gonzalez-Gomez I, Gilles FH. The search for human telencephalic ventriculofugal arteries. *AJNR Am J Neuroradiol* 1991;12:215–222
12. Adams RD, Victor M. *Principles of neurology*, 4th ed. New York: McGraw-Hill Information Services Company, Health Professions Division; 1989;488–497
13. Kodama N, Suzuki J. Cerebrovascular moyamoya disease. 3rd report: The study on the aging of the perforating branches and the possibility of collateral pathway. *Neurol Med Chir (Tokyo)* 1975;15:55–67
14. Blackwood W, Corsellis JAN, eds. *Greenfield's neuropathology*, 3rd ed. Chicago: Year Book Medical, 1976:111–113
15. Fazekas F. Magnetic resonance signal abnormalities in asymptomatic individuals: their incidence and functional correlates. *Eur Neurol* 1989;29:164–168
16. Kirkpatrick JB, Hayman LA. White matter lesions in MR imaging of clinically healthy brains of elderly subjects: possible pathologic basis. *Radiology* 1987;162:509–511
17. Fazekas F, Kleinert R, Offenbach H, et al. The morphologic correlate of incidental punctate white matter hyperintensities on MR images. *AJNR Am J Neuroradiol* 1991;12:915–922
18. Drayer BP. Imaging of the aging brain. part I. normal findings. *Radiology* 1988;166:785–796
19. Benhaïem-Sigaux N, Gray F, Gherardi R, Roucayorol AM, Poirier J. Expanding cerebellar lacunes due to dilatation of the perivascular space associated with Binswanger's subcortical arteriosclerotic encephalopathy. *Stroke* 1987;18:1087–1092