

Leukoencephalopathy in Normal and Pathologic Aging: 2. MRI of Brain Lucencies

Ajax E. George¹
 Mony J. de Leon²
 Andrew Kalnin³
 Lisa Rosner³
 Albert Goodgold⁴
 Norman Chase¹

A pilot study was performed to test the ability of MR to evaluate the brain lucencies shown by CT in Alzheimer disease patients and in normal control subjects. Eight patients with presumed Alzheimer disease and 47 normal controls, 12 over the age of 45 years and 35 under age 45, were studied. Each group included subjects with and without CT evidence of leukoencephalopathy. Inversion recovery, saturation recovery, and spin-echo scans were obtained using a 0.3-T permanent magnet prototype unit.

Results indicated that MR was more sensitive than CT to parenchymal disease. Seven of the eight patients with Alzheimer disease showed patches of increased signal intensity on SE scans; only three had lucencies on their CT studies. None of the normal subjects under the age of 45 showed periventricular patches of increased SE signal intensity. T2-weighted SE imaging was performed in nine of the 12 normal subjects over 45 years old. Eight of the nine demonstrated periventricular patches of increased SE signal intensity. Faint CT lucencies were present in only one of these. The configuration of the patches of increased signal intensity was similar for both the normal and Alzheimer groups, but the extent of white-matter involvement was greater in the Alzheimer group.

In part 1 (see the preceding article) we report that leukoencephalopathy as shown by CT is common in demented patients as well as in normal elderly individuals [1]. A large group of patients with such lesions demonstrate no evidence of hypertension, diabetes, or previous stroke. The presence of lucencies in the CT studies of normal controls is of particular interest because they may herald the onset of vascular disease. The introduction of MRI to clinical investigation has provided the means to further study both physiologic and pathologic brain-water distributions *in vivo* [2–5] beyond the capabilities of CT. Increased T2 regions, typically at the anterolateral angles of the lateral ventricles, have been reported in the MR studies of consecutively studied elderly patients [6] and normal elderly subjects [7–8]. Using CT, we found a consistently higher though not statistically significant incidence of brain lucencies in patients with Alzheimer disease [1]. In this pilot study, we evaluated the potential use of MR in the study of leukoencephalopathy seen in Alzheimer disease and compared these changes with those seen in normal controls.

Subjects and Methods

Two groups of subjects were studied. The first group, described in Table 1, included five women and three men, aged 61 to 85 years, with presumed Alzheimer disease. These patients were derived from the overall group of study patients described in part 1, who, in addition to CT, received extensive psychiatric, medical, and neurologic examination and psychometric testing [1].

The second group consisted of 47 normal subjects, 12 over the age of 45. These 12, eight men and four women, aged 46 to 78 years, are described in Table 2. The MR scans of the remaining 35 normal volunteers, who were under the age of 45 years, were also reviewed.

The normal volunteers were part of the clinical trials performed at the MR facility used for these studies. MR studies were performed on a prototype unit (Fonar Corporation, Melville,

Received July 2, 1985; accepted after revision February 4, 1986.

Presented in part at the 22nd annual meeting of the American Society of Neuroradiology, Boston, June 1984.

This work was supported by Grant MH36969 awarded by the National Institute of Mental Health, Dept. of Health and Human Services.

¹Department of Radiology (Neuroradiology), New York University Medical Center, 560 First Ave., New York, NY 10016. Address reprint requests to A. E. George.

²Department of Psychiatry (Geriatric Study and Treatment Program), New York University Medical Center, New York, NY 10016.

³New York University School of Medicine, New York, NY 10016.

⁴Department of Neurology, New York University Medical Center, New York, NY 10016.

AJNR 7:567–570, July/August 1986
 0195–6108/86/0704–0567
 © American Society of Neuroradiology

TABLE 1: Leukoencephalopathy Ratings of Alzheimer Subjects

Case No.	Age Gender	History	CT	IR	SR	SE
1	61 M	Dementia	0	0	0	0
2	75 M	Dementia	0	0	NA	Mild
3	69 M	Dementia	0	0	NA	Minimal
4	71 F	Dementia/Parkinson's	0	NA	0	Mild
5	77 F	Dementia/Gait impairment	0	0	NA	Mild
6	75 F	Dementia/Hypertension	Minimal	0	NA	Mild
7	85 F	Dementia/Gait impairment	Severe	0	0	Severe
8	77 F	Dementia/Cardiac	Moderate	0	NA	Moderate

Note.—CT ratings refer to lucencies; SE ratings refer to areas of increased signal intensity; NA = study not performed or results not available; 0 = no evidence of leukoencephalopathy.

TABLE 2: Leukoencephalopathy Ratings of Normal Subjects

Case No.	Age Gender	History	CT	IR	SR	SE
1	60 F	Normal	0	0	0	NA
2	61 F	Normal	0	0	0	NA
3	64 M	Cardiac	0	NA	0	Minimal
4	62 M	Hypertension	0	0	0	NA
5	68 M	Cardiac	Minimal	0	NA	Mild
6	67 M	Normal	0	0	NA	Minimal
7	78 M	Normal	NA	NA	NA	Minimal
8	70 M	Hypertension	0	NA	NA	Moderate
9	66 F	Normal	0	NA	0	Minimal
10	63 M	Hypertension	0	NA	0	Minimal
11	62 M	Normal	0	NA	0	Minimal
12	46 F	Normal	0	0	0	0

Note.—CT ratings refer to lucencies; SE ratings refer to increased signal intensity; NA = study not performed or results not available; 0 = no evidence of leukoencephalopathy.

Long Island, New York) that had a 0.3-T permanent magnet and an 11.9 MHz headcoil. The following scan sequences were used: inversion recovery (IR), echo time (TE) = 48 msec, inversion time (TI) = 370 msec, repetition time (TR) = 1280 msec; saturation recovery (SR), TE = 48 msec, TR = 670 msec; and spin echo (SE), TE = 110 msec, TR = 1800 msec. Seven simultaneous noncontiguous scans were obtained. Slice thickness was 8 mm and slice spacing was 1.2 cm. Image reconstruction was done on a 256 × 256 image matrix and a 2D Fourier transform. Studies were obtained in the axial plane, typically requiring two overlapping scan sequences to cover the entire head from the base to the vertex.

The Alzheimer group had CT in routine fashion, with 10-mm axial cuts at 10-mm intervals, as described in part 1 [1]. The 12 normal subjects who had CT scans are listed in Table 2. The normal subjects under the age of 45 did not have CT scans.

All CT scans were evaluated for the presence or absence of white-matter lucencies and, when present, for the severity of these changes. A rating scale was applied with a range from no evidence of leukoencephalopathy to evidence of severe leukoencephalopathy. MR studies were subjectively rated for the presence or absence of increased-intensity signals and for evidence of structural lesions. A comparison of MR images of the normal vs the Alzheimer group was made in order to determine whether the pattern of changes differed in the two groups.

Results

Alzheimer Disease (Table 1)

Of the eight patients with Alzheimer disease, three had CT evidence of leukoencephalopathy. MR changes were present in seven of the eight. The findings ranged from small regions of increased signal intensity to involvement of all white matter (Fig. 1). None of the eight patients had clinical or CT evidence of infarct. SR and IR scans (Fig. 1B) were unremarkable and failed for the most part to identify the CT lucencies.

The MR scans of the three patients in whom CT lucencies were seen showed periventricular patches of increased signal intensity on SE, which corresponded to the lucencies present in the CT scans. In one of the three patients the changes were more extensive on MR than on CT (subject 6).

Four of the five patients who showed no CT evidence of lucencies did show numerous foci of increased signal intensity on SE images. These changes were of minimal to mild severity.

In summary, of the group of patients with presumed Alzheimer disease (Table 1), in five patients MR showed patches of increased signal intensity that were greater in number and extent than that of the lucencies shown by CT. In the remaining three patients, the changes were of similar severity on MR and CT.

Normal Subjects (Table 2)

In the 35 normal subjects under the age of 45, none of the MR studies showed patches of increased signal intensity or evidence of white-matter disease on any of the pulse sequences obtained. Of the 12 normal subjects over the age of 45 years, nine received SE scans. Eight of these showed single or multiple patchy areas of increased signal intensity in the periventricular white matter (Table 2). White-matter abnormalities were only shown on SE scans. Only one of these nine subjects showed CT evidence of leukoencephalopathy (Fig. 2). This patient showed more clearly discernible lesions on MR than on CT. For example, the CT scan at the ventricular body level demonstrated questionable presence of faint lucencies adjacent to the frontal horns (Fig. 2A) and lucencies adjacent to the trigones (Fig. 2C). The MR SE sequence showed patches of increased signal intensity adjacent to the frontal horns (Fig. 2B) and involving the peritrigonal areas bilaterally (Fig. 2D). The IR scan (Fig. 2E) was unremarkable for parenchymal changes. Ventricular and cortical atrophy were shown both on CT and MR, perhaps better on the IR sequences (Fig. 2E).

In comparing the MR changes between the normal subjects and the patients with Alzheimer disease, the lesions were similar in appearance in both groups but were more extensive in the Alzheimer group.

Discussion

In part 1 of this study [1], we reported that 16% of normal controls and 30% of clinically diagnosed patients with Alz-

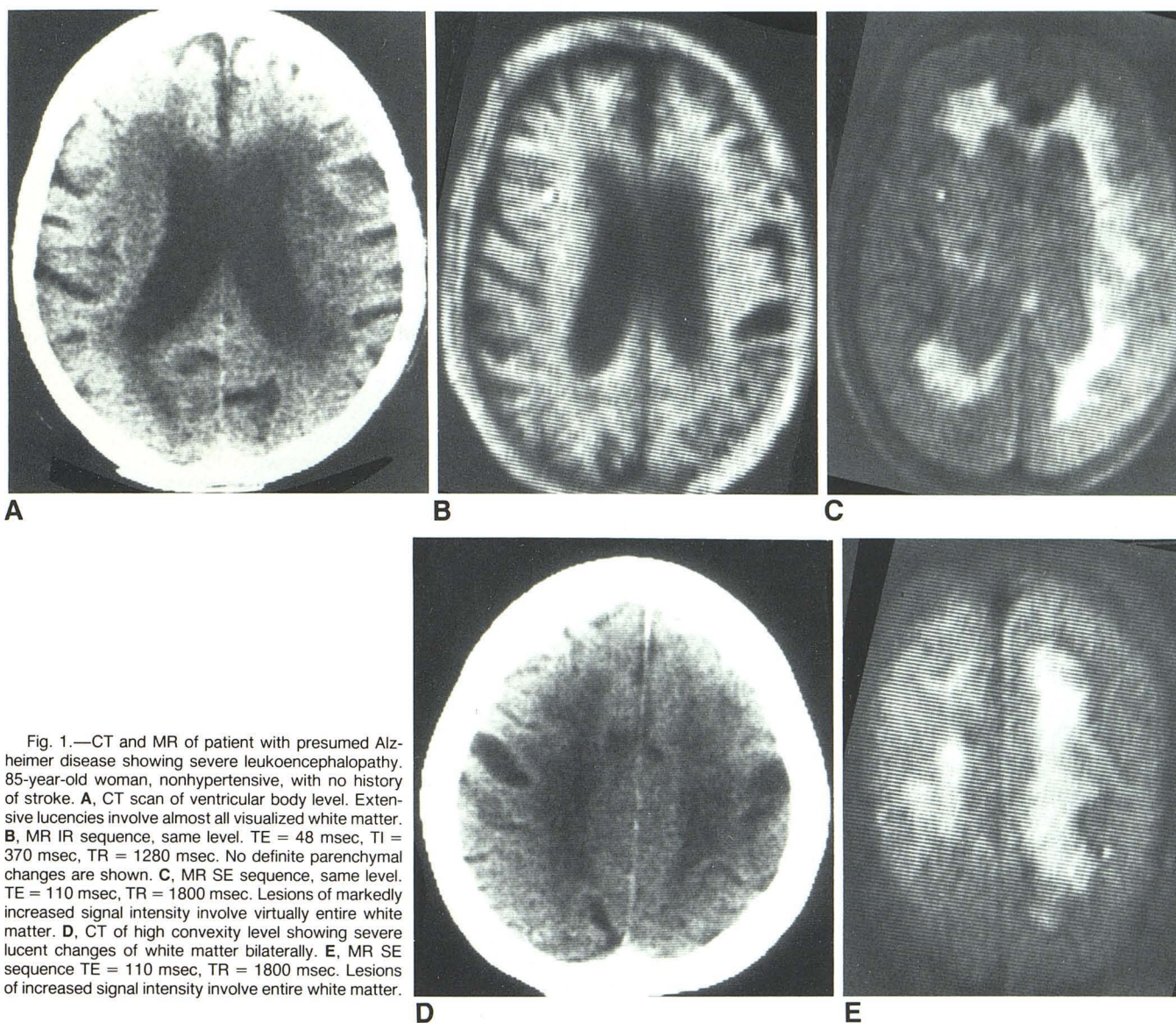


Fig. 1.—CT and MR of patient with presumed Alzheimer disease showing severe leukoencephalopathy. 85-year-old woman, nonhypertensive, with no history of stroke. **A**, CT scan of ventricular body level. Extensive lucencies involve almost all visualized white matter. **B**, MR IR sequence, same level. TE = 48 msec, TI = 370 msec, TR = 1280 msec. No definite parenchymal changes are shown. **C**, MR SE sequence, same level. TE = 110 msec, TR = 1800 msec. Lesions of markedly increased signal intensity involve virtually entire white matter. **D**, CT of high convexity level showing severe lucent changes of white matter bilaterally. **E**, MR SE sequence TE = 110 msec, TR = 1800 msec. Lesions of increased signal intensity involve entire white matter.

heimer disease had evidence of leukoencephalopathy on CT. This part of the study, which describes a subset of these patients, has shown that MR was more sensitive than CT in demonstrating the white-matter parenchymal changes both in normal and pathologic aging. The frequent occurrence of MR changes in normal controls over the age of 45 (eight of nine subjects who had SE sequences) indicates that parenchymal disease is far more common in older patients than suggested by CT. Increased T2 regions at the anterolateral angles of the lateral ventricles have been reported in normal volunteers [7–8]. Ependymitis granularis, a normal anatomic variant characterized by discontinuity of the frontal horn ependymal lining has been implicated as the cause of these findings [8]. Bradley et al. [6], using MR, found patchy periventricular white-matter lesions in 30% of 20 consecutive patients over

the age of 60. In our study we found a similar MR pattern consisting of multiple patches of increased signal intensity, shown best on T2-weighted spin-echo sequences. These patches were scattered throughout the white matter with a predilection for the periventricular regions. Interestingly, in our study, neither IR nor SR scans showed the lucencies seen with CT. It should be noted that our SR scans were obtained with TR = 670 msec. Scanning with a longer TR should prove more effective in demonstrating leukoencephalopathy.

To determine whether SE patches may be a normal variant, the MR scans of 35 younger volunteers (ages 25 to 45) were also reviewed. None showed SE patches.

In summary, MRI, as expected, was more sensitive than CT in detecting and determining the extent of leukoencephalopathy in an elderly population. Patches of increased signal

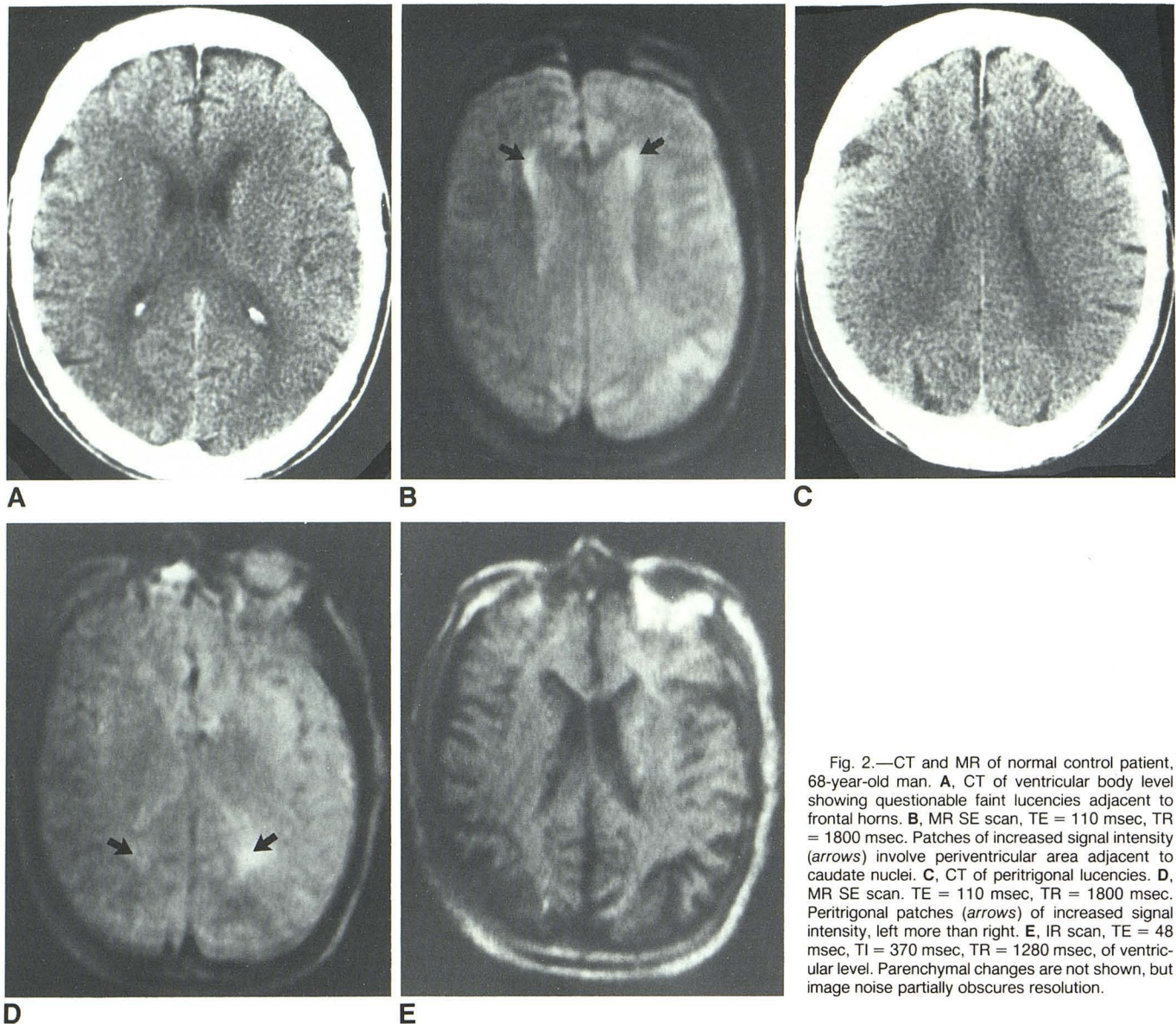


Fig. 2.—CT and MR of normal control patient, 68-year-old man. **A**, CT of ventricular body level showing questionable faint lucencies adjacent to frontal horns. **B**, MR SE scan, TE = 110 msec, TR = 1800 msec. Patches of increased signal intensity (arrows) involve periventricular area adjacent to caudate nuclei. **C**, CT of peritrigonal lucencies. **D**, MR SE scan. TE = 110 msec, TR = 1800 msec. Peritrigonal patches (arrows) of increased signal intensity, left more than right. **E**, IR scan, TE = 48 msec, TI = 370 msec, TR = 1280 msec, of ventricular level. Parenchymal changes are not shown, but image noise partially obscures resolution.

intensity on SE sequence scans were present in patients with presumed Alzheimer disease and were similar in configuration but more extensive than those in normal control subjects.

ACKNOWLEDGMENT

We thank Joan Askew for her assistance in the preparation of this manuscript.

REFERENCES

- George AE, de Leon MJ, Gentes CI, et al. Leukoencephalopathy in normal and pathologic aging. 1. CT of brain lucencies. *AJNR* 1986;7:561-566
- Doyle FH, Gore JD, Pennock J. Imaging of the brain by nuclear magnetic resonance. *Lancet* 1981;8237(2):53-57
- Bydder GM. Magnetic resonance imaging of the brain. *Radiol Clin North Am* 1984;22(4):779-793.
- McCullough EC, Baker Jr HL. Nuclear magnetic resonance imaging. *Radiol Clin North Am* 1982;20(1):3-7
- Young IR, Randell CP, Kaplan PW, et al. Nuclear magnetic resonance (NMR) imaging in white matter disease of the brain using spin echo sequences. *J Comput Assist Tomogr* 1983;7(2):290-294
- Bradley WG, Waluch V, Brant-Zawadzki M, Yadley RA, Wyckoff RR. Patchy periventricular white matter lesions in the elderly: a common observation during NMR imaging. *Noninvasive Medical Imaging* 1984;1(1):35-41
- Young IR, Randell CP, Kaplan PW, James A, Bydder GM, Steiner RE. NMR imaging in white matter disease of the brain using spin-echo sequences. *J Comput Assist Tomogr* 1983;7:290-294
- Sze G, DeArmond S, Brant-Zawadzki M, et al. "Abnormal" MRI foci anterior to the frontal horns. Presented at the 23rd annual meeting of the American Society of Neuroradiology, New Orleans, February 1985; *AJNR* 1985;6:467-468 (abstr)