

# Treatment of Carotid Artery Aneurysms with Platinum Coils: An Experimental Study in Dogs

Virgil B. Graves<sup>1</sup>  
 Curtis R. Partington  
 Daniel A. Rufenacht  
 Alan H. Rappe  
 Charles M. Strother

The objectives of this study were to investigate the consistency, patency, and natural history of a vein graft canine aneurysm model and to determine the effectiveness of various coil designs on inducing aneurysm thrombosis. Twenty-one sacculuslike aneurysms were created in mongrel dogs by anastomosing a vein pouch to the common carotid artery. The model produced wide-neck aneurysms with 100% patency. The canine vein graft aneurysm provided an excellent model for the evaluation of endovascular devices. Three types of specially designed platinum coils were placed in the aneurysms: those with simple curves, those with complex curves, and those with flower petal curves and silk fibers. These coils were placed by the endovascular route by means of microcatheters.

Flower petal coils with silk fibers were effective in producing thrombosis of the aneurysms, suggesting that coils of the appropriate design may be useful in the endovascular treatment of aneurysms. The other coil designs evaluated, those with simple and complex curves without silk fibers, demonstrated insufficient thrombogenicity and spatial stability.

*AJNR* 11:249-252, March/April 1990

There is currently a great deal of interest in the endovascular treatment of aneurysms by the selective placement of devices (coils, balloons, etc.) within the lumen of the aneurysm. The lack of a reproducible animal model of human saccular aneurysms has limited the investigation of possible suitable endovascular devices. Methods for creating aneurysms in animals have included surgical disruption of the adventitia and media [1], injection of chemicals into the media of the artery [2], and surgical creation of pouches [3]. Of these methods only the surgically created pouches appear to produce realistic models of saccular aneurysms. The other methods produce fusiform aneurysms without a true neck. In this article we describe a surgically created vein pouch aneurysm model in the dog produced by using a modification of the technique developed by German and Black [3]. This model was reproducible, producing aneurysms that remained patent and had many of the structural and dynamic characteristics of human saccular aneurysms.

Recent advances in microcatheter technology have made the majority of intracranial aneurysms accessible to endovascular techniques. This article reports our experience in placing a variety of platinum coils that can be delivered through the Tracker-18 catheter (Target Therapeutics, Inc., San Jose, CA) into the lumen of the aneurysms. We evaluated the ease of placement, stability and thrombogenicity of the coils, and histopathologic changes in the aneurysms induced by the coils.

## Materials and Methods

Mongrel dogs weighing approximately 20 kg were used for this study under a protocol approved by the University of Wisconsin Animal Care Committee. The animals were maintained in the Animal Care Facility of the University of Wisconsin. Each surgical procedure was

Received June 27, 1989; revision requested August 11, 1989; revision received August 30, 1989; accepted August 31, 1989.

Presented at the annual meeting of the American Society of Neuroradiology, Orlando, March 1989.

This work was supported in part by a grant from Target Therapeutics, Inc., San Jose, CA.

<sup>1</sup> All authors: Department of Radiology, University of Wisconsin Clinical Science Center, 600 Highland Ave., Madison, WI 53792. Address reprint requests to V. B. Graves.

0195-6108/90/1102-0249  
 © American Society of Neuroradiology



performed under sterile conditions and with general anesthesia. Anesthesia was initiated with IV 5% pentothal (1 ml/5 lbs) and, after endotracheal intubation, maintained with 1.0–2.0% isoflurane and 100% oxygen.

An 8-cm incision in the anterior lateral aspect of the neck was made and the external jugular vein isolated. The external jugular vein was ligated proximally and distally and a 4-cm segment of the vein harvested. The common carotid artery was exposed and temporary vascular clamps were placed both proximally and distally, isolating a 5-cm segment. A Hancock vascular punch was used to make a 5-mm circular opening in a single wall of the carotid artery. A 2-cm segment of the external jugular vein was anastomosed end to side to the carotid artery with 7-0 prolene suture. The free end of the vein graft was ligated with 7-0 prolene suture. The vascular clamps were removed and transfemoral carotid angiography performed to determine patency of the vein pouch. One or two aneurysms were constructed on each common carotid artery. Two weeks were allowed for the aneurysms to mature before any interventional procedures were done.

Platinum coils (0.014–0.015 outside diameter; 4–10 cm length) with simple and complex curves without silk fibers and with complex curves (flower petal) with silk fibers (Fig. 1) were placed in the aneurysms via the transfemoral approach by means of a 5-French guiding catheter and a coaxial 2.2-French microcatheter (Tracker-18). One or more coils (maximum of three) were placed in each aneurysm. Follow-up transfemoral carotid angiography was done for evaluation of aneurysms with coils and control aneurysms without coils at varied intervals between 5 and 158 days. All interventional procedures were done by using the same anesthesia protocols as were used in the construction of the aneurysms.

At the completion of the study each animal was euthanized with Beuthenasia (1 ml/10 lbs). The aneurysms were removed and fixed in formalin. The coils were removed prior to sectioning, as it was impossible to section the platinum coils in situ. Histopathologic evaluation was performed on 10- $\mu$ m-thick sections stained with H and E, Trichrome, and EVG. Reduction in volume of the aneurysm after the placement of the coils was made by measurement on follow-up angiograms and gross inspection after removal.

## Results

Twenty-one aneurysms were created in seven dogs; 15 aneurysms received coils and six were used as controls. Additional control data were obtained from observation of the 15 aneurysms prior to coil placement. This method produced wide-neck, 8-mm-diameter aneurysms with 100% patency.

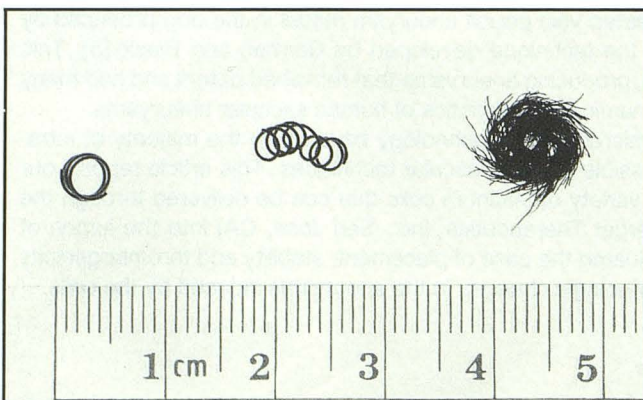


Fig. 1.—Platinum coils, simple and complex, without silk fibers, and complex curve (flower petal) coil with silk fibers.

Less than 10% (two of 21) showed any spontaneous decrease in size in the follow-up period (13–158 days).

The control aneurysms had wide necks and were patent without evidence of thrombus in the parent artery (Fig. 2). There was highly organized thrombus composed of collagenized fibrin and fibrous tissue adherent to the dome of the aneurysm in every control aneurysm. The lumen of the aneurysm and surface of the organized thrombus in the dome of the aneurysm was covered by a lining of cells that had the appearance of endothelial cells and were continuous with the endothelial cells lining the lumen of the parent artery (Fig. 3). No inflammatory reaction (polymorphonuclear or giant cells) was noted, except for small foreign-body granulomas around the prolene sutures. There were minimal areas with evidence of vascular recanalization of the thrombus in the dome of the aneurysm. These changes were noted and present to a similar degree in all control aneurysms.

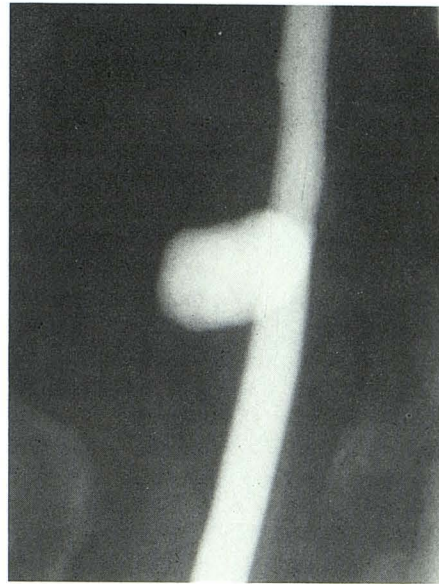
Simple coils without silk fibers were difficult to position in the aneurysm and were generally unstable (Table 1). The only stable position was in the dome of the aneurysm. Only partial thrombosis of the aneurysm lumen occurred in the domes of the aneurysms, producing an average reduction of only 10% in the volume of the aneurysms (Table 2). Histopathologic evaluation showed highly organized mature thrombus composed of collagenized fibrin and fibrous tissue adherent to the wall of the aneurysm. There was limited inflammatory reaction present and minimal areas with evidence of vascular recanalization within the thrombus. The free edge of the thrombus was lined with a cell layer continuous with the endothelial cells lining the lumen of the parent artery.

Complex coils without silk fibers were less stable than the simple curved coils (Table 1). These coils produced only partial thrombosis of the aneurysm lumen with an average reduction of 30% in the volume of the aneurysm (Table 2). Histopathologic evaluation showed highly organized mature thrombus composed of collagenized fibrin and fibrous tissue adherent to the wall of the aneurysm. There was limited inflammatory reaction present and minimal areas with evidence of vascular recanalization within the thrombus. The free edge of the thrombus was lined with a cell layer continuous with the endothelial cells lining the lumen of the parent artery.

Flower petal coils with silk fibers were very stable (Table 1). Complete thrombosis of the aneurysm with patency of the parent artery (Fig. 4) occurred in four of 10 cases (Table 2). Extraaneurysmal thrombus in the parent artery and the distal branches of the parent artery was present in five (50%) of 10 aneurysms (Fig. 5). In every case of complete aneurysm occlusion with patency of the parent artery there was some extraaneurysmal thrombus detected angiographically in the parent artery and/or its distal branches at some time. This was temporary and resolved in all cases within 21 days after coil placement. One complete parent artery occlusion occurred. Flower petal coils with silk fibers induced more thrombosis of the aneurysm lumen than did the other coils used in the study. Histopathologic evaluation showed highly organized mature thrombus composed of collagenized fibrin and fibrous tissue adherent to the wall of the aneurysm. There was limited inflammatory reaction present and minimal areas with evidence of vascular recanalization within the thrombus (Fig. 6). The free edge of the thrombus was lined with a cell

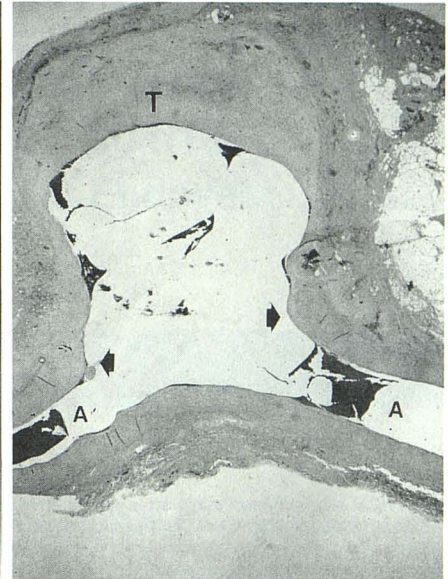


Fig. 2.—Control aneurysm, 60 days after construction, has wide neck, patent parent artery, and no angiographic evidence of thrombus.



2

Fig. 3.—Control aneurysm, 10- $\mu$ m-thick section, 30 days after construction, has patent parent artery (A), wide neck (arrows), and organized thrombus adherent to aneurysm dome (T) (H and E stain).



3

TABLE 1: Coil Stability

	Simple Curves	Complex Curves	Flower Petal + Silk
Stable coil position	3/7		13/14
Poor coil placement	1/7		
Coil migration (immediate)	3/7	2/5	
Coil migration (delayed)		1/5	1/14
Coil position change		2/5	

TABLE 2: Coil Thrombogenicity

	Simple Curves	Complex Curves	Flower Petal + Silk
Complete aneurysm thrombosis			4/10
Partial aneurysm thrombosis	3/3	1/2	3/10
No thrombosis of aneurysm		1/2	2/10
Parent artery occlusion			1/10
Extraaneurysmal thrombus	1/3		5/10
Average % reduction of aneurysm	10%	30%	70%

layer continuous with the endothelial cells lining the lumen of the parent artery (Fig. 7).

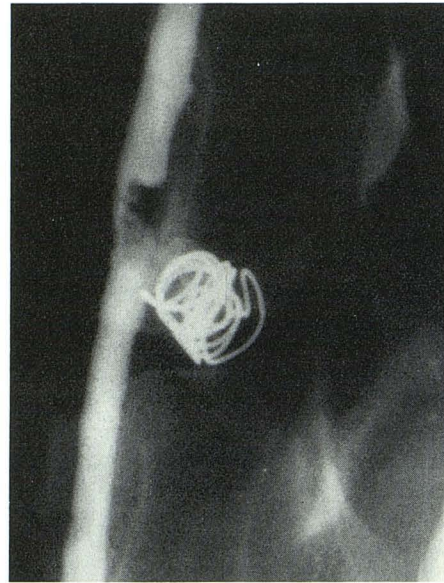## Discussion

This canine aneurysm model is easy to construct, requiring about 30 min per aneurysm. No significant morbidity and no mortality was encountered in our study. This technique provided consistently reproducible 8-mm aneurysms with wide necks and 100% patency. We believe the consistency and patency of this aneurysm model is related to the surgical anastomosis. The use of a 5-mm Hancock vascular punch to construct a circular orifice for the aneurysm and the end-to-side anastomosis of the vein graft pouch to the parent artery appears to be a major factor in maintaining patency. The relative size of the orifice of the aneurysm to the volume of the vein graft pouch is also an important factor [4]. Our attempts to use side-to-side anastomosis and different size and shaped orifices in the parent artery produced considerable variability in aneurysm size and patency. While these vein graft aneurysms differ histologically from human saccular aneurysms, they appear to provide a reasonable structural and dynamic facsimile [3, 5, 6]. The availability of an aneurysm model to investigate and develop devices for ablation of aneurysms is a necessity for developing endovascular therapeutic techniques. This surgical technique provides an excellent aneurysm model for these purposes.

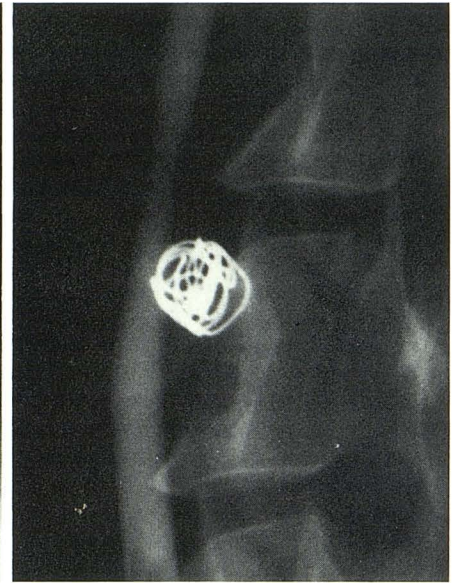
All coil designs used could be delivered via the coaxial catheter system. All coils became more difficult to deliver through the microcatheter as their length approached 10 cm. The last few millimeters, or the "tail," of the coil are difficult to place within the aneurysm lumen so that it does not protrude into the lumen of the parent artery. This can be accomplished by placing the catheter near the center of the aneurysm lumen and delivering the "tail" of the coil as the catheter is withdrawn. The simple coils and complex curved coils without silk fibers were unstable and six of 12 migrated out of the lumen of the aneurysm after placement. All coils without silk fibers produced insufficient thrombosis. Thrombosis induced by platinum coils without silk fibers seems to be dependent on mechanical interruption of flow and the resulting stasis. None produced complete occlusion of the aneurysm lumen. The flower petal coils with silk fibers were stable, with only one in 14 migrating out of the aneurysm lumen after placement. The flower petal coil design allows the coil to more closely approximate the shape of the lumen of the aneurysm and allows more coil material to be placed within the aneurysm lumen. We believe these factors account for the increased stability of the flower petal coils. The addition of the silk fibers to the coils dramatically increased the amount of thrombosis induced in the aneurysm lumen, with only two of 10 aneurysms failing to show any significant thrombosis within the aneurysm lumen after coil placement. The thrombogenic effects of the coils with and without silk paralleled the results of other



Fig. 4.—Aneurysm 30 days after placement of flower petal coil with silk fibers. Note thrombosis of aneurysm lumen with patent parent artery.

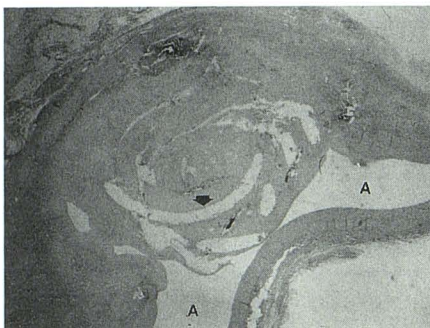


4

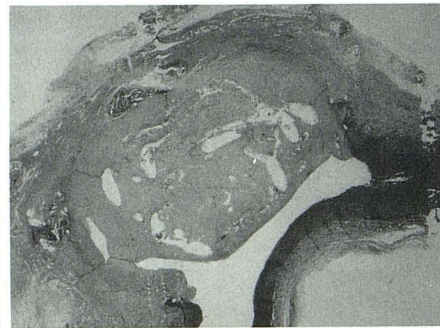

5

Fig. 5.—Aneurysm 7 days after placement of flower petal coil with silk fibers. Note partial thrombosis of aneurysm lumen and extraaneurysmal thrombus in parent artery.



A



B

Fig. 6.—A, Aneurysm, 10- $\mu$ m-thick section, 30 days after placement of flower petal coil with silk fibers. Note thrombosis of aneurysm lumen (coil tracks, arrow) and patent parent artery (A) (H and E stain).

B, Section 2 mm from A shows patent parent artery (EVG stain).

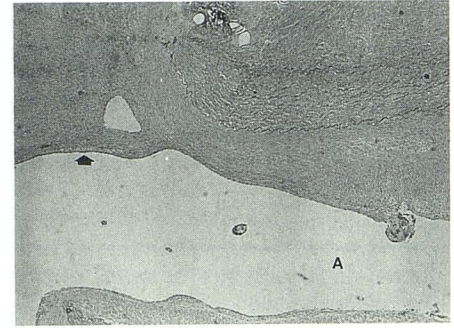


Fig. 7.—Aneurysm neck, 10- $\mu$ m-thick section, 30 days after placement of flower petal coil with silk fibers. Note free margin of thrombus lined with cell layer (arrow) continuous with endothelial cells lining lumen of parent artery (A) (H and E).

investigators [7]. The flower petal coils with silk fibers produced excellent thrombotic reaction within the aneurysm lumen, but the degree and extent was somewhat variable, often overshooting the desired endpoint (i.e., parent artery occlusion and extraaneurysmal thrombus). Thrombus outside the lumen of the aneurysm extending into the parent artery occurred with only one exception with coils with silk fibers. In all cases there was angiographic evidence of thrombus in the vascular territory distal to the aneurysm, which resolved on follow-up angiography. No postmortem examination of the brain was done. Postmortem gross evaluation of the adjacent vascular territory showed no evidence of thrombus except in the case of complete artery occlusion. This represents a major concern in using coils with silk fibers to occlude aneurysms. The ability to deliver small coils to the arteries of the brain and spine via microcatheters makes them an attractive endovascular device. For these small coils to be useful in the endovascular treatment of vascular lesions of the brain and

spine further advances in the stability, retrievability, and thrombogenicity need to be made.

#### REFERENCES

1. Young PH, Fischer VW, Guity A, Young PA. Mural repair following obliteration of aneurysms: production of experimental aneurysms. *Microsurgery* 1987;8:128-137
2. White JC, Sayre GP, Whisnant JP. Experimental destruction of the media for the production of intracranial arterial aneurysms. *J Neurosurg* 1961;18:741-745
3. German WJ, Black SPW. Experimental production of carotid aneurysms. *New Engl J Med* 1954;3:463-468
4. Black SPW, German WJ. Observations on the relationship between the volume and the size of the orifice of experimental aneurysms. *J Neurosurg* 1960;17:984-987
5. Perktold K, Gruber K, Kenner T, Florian H. Circulation of pulsatile flow and particle paths in an aneurysm-model. *Basic Res Cardiol* 1984;79:253-261
6. Perktold K. On paths of fluid particles in an axisymmetrical aneurysm. *J Biomech* 1987;20:311-317
7. Barth KH, Strandberg JD, Kaufman SL, White RI. Chronic vascular reaction to steel coil occlusion devices. *AJR* 1978;131:455-458