

CT Multiplanar Reconstruction in 253 Cases of Lumbar Spondylolysis

Stephen L. G. Rothman¹
William V. Glenn, Jr.¹

Two hundred fifty-three patients with lumbar pars interarticularis defects were studied by multiplanar high-resolution computed tomographic scanning (CT/MPR). Two hundred thirty patients had one or more pars defects at L5, 21 at L4, and two at L3. Within this group of patients, 21% had more than 5 mm of disk bulge or herniation, 34% had foraminal encroachment, and 34% had indentation on the neural canal from soft-tissue or bony callus formation.

Spondylolysis is a common condition found in about 5% of the general population [1]. A fibrous cleft within the pars interarticularis divides the vertebral arch into two segments. The anterosuperior segment consists of the pedicles, the transverse processes, and the superior facets. The posterior inferior segment consists of the inferior facets, the laminae, and the spinous process. This paper describes the multiplanar computed tomographic (CT/MPR) findings in a series of 253 patients with spondylolysis without dislocation or with dislocations from pars disruption. This represents 5% of the almost 5000 lumbar spine patients scanned at our facility. Our purpose was to document the variety of abnormal conditions associated with pars defects, which are definable by CT scanning.

Materials and Methods

All of the patients in this study were seen because of back pain or radiculopathy. They were examined on GE 8800 CT scanners with the gantry perpendicular to the plane of the x-ray table (zero gantry angle). Five-mm-thick sections were obtained with 2 mm of overlap. A standard study extended from the top of the sacrum through the lower end-plate of the L3 vertebral body. All the cases were reformatted routinely into sagittal and coronal planes, and the images were magnified to actual life-size for measuring the amount of disk herniation. Two sets of digital radiographs were made: one taken for soft tissue and the other for bone detail [2].

Two hundred fifty-three consecutive cases of pars interarticularis defects with or without spondylolisthesis were reviewed retrospectively, and the abnormalities were quantitated. The amount of forward slippage was measured on midsagittal reformations, except where the dislocation was asymmetric; in those cases, the largest dislocation was measured on the appropriate sagittal image.

The amount of foraminal stenosis also was graded on the appropriate sagittal films. A value of 1 was assigned to a normal foramen, and 5 was allotted to a foramen reduced in both height and transverse diameter. The amount of soft tissue or bony callus at the site of the pars defect was estimated from the axial images and specified as either absent; present, but probably not significant; or prominent and likely to be significant. These abnormalities will be discussed in detail in a later section.

Results

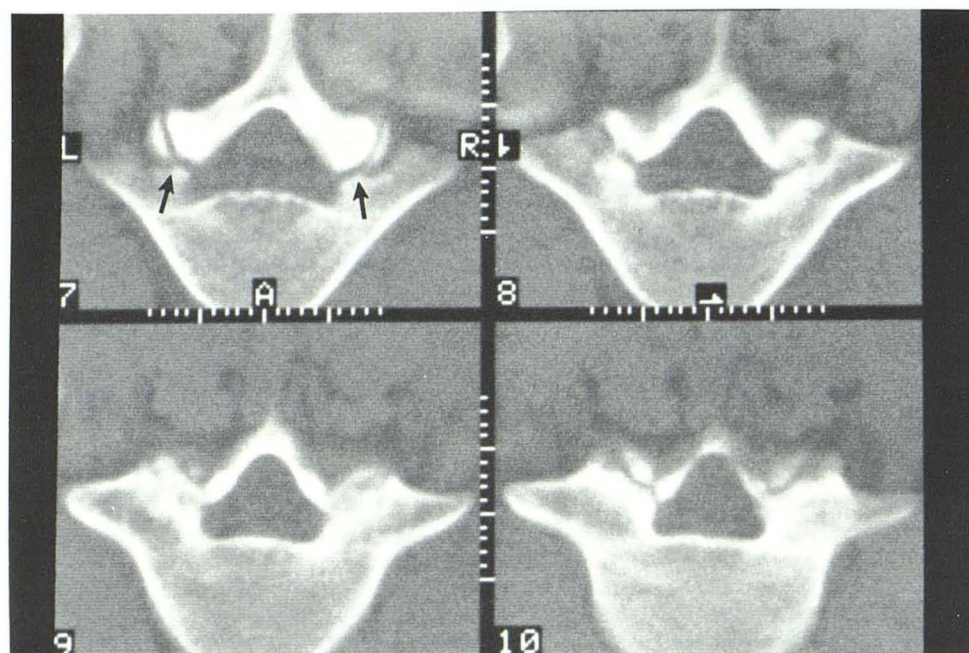
Bilateral pars defects without significant dislocation were noted in 75 patients:

Received November 22, 1982; accepted after revision May 17, 1983.

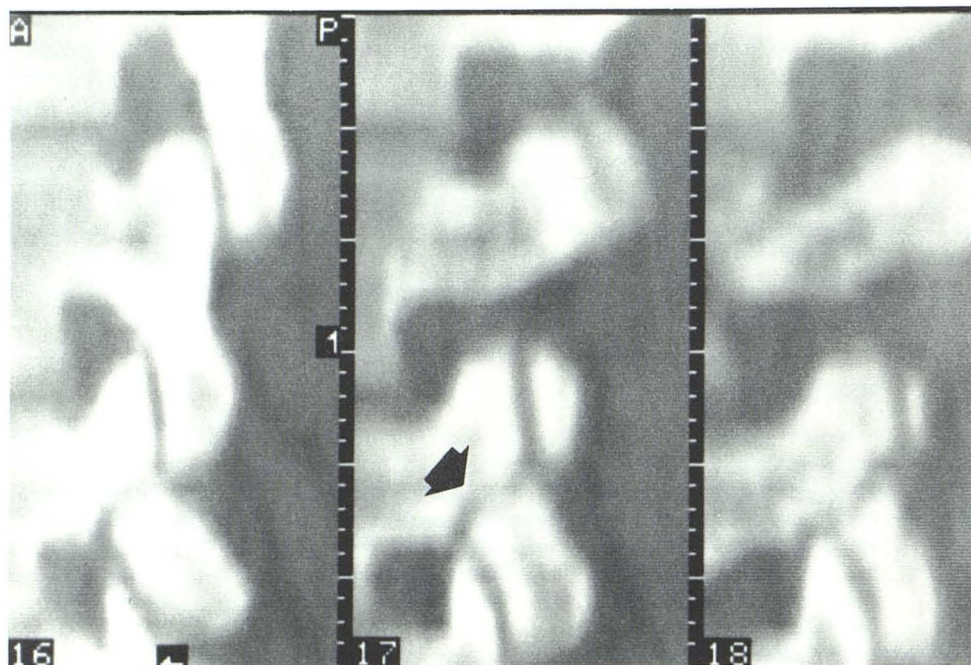
Presented at the Symposium Neuroradiologicum, Washington, DC, October 1982.

¹ Multi-Planar Diagnostic Imaging, Inc., 2730 Pacific Coast Highway, Torrance, CA 90505. Address reprint requests to S. L. G. Rothman.

AJNR 5:81-90, January/February 1984
0195-6108/84/0501-0081 \$00.00
© American Roentgen Ray Society



A



B

Fig. 1.—Pars interarticularis defect. **A**, Axial scans demonstrate pars interarticularis defects (*arrows*) without vertebral displacement. **B**, Sagittal reformatted image through pars interarticularis defect (*arrow*).

66 were at L5, seven were at L4, and two were at L3 (table 1). Pars defects with dislocation spondylolisthesis were noted in 136 patients: 126 at L5 and 10 at L4. Unilateral clefts were demonstrated in 42 patients: 38 at L5 and four at L4. Minor amounts of asymmetric rotatory spondylolisthesis were seen in 11 patients with unilateral pars defects.

Disk protrusion or herniations defined as anterior extradural defects of 5 mm or more, as seen on sagittal reformatted images, were noted in 53 patients. Significant herniation was

noted far more often at L4–L5 than at L5–S1, and was rare at the level of the pars defect. Characteristic deformity of the neural foramina, best described as a flattening of the foramen with anteroposterior deformity, was encountered in 84 patients.

Congenital anomalies of the upper sacrum or the affected vertebral arch were noted in 85 cases. The actual incidence may be slightly higher because the posterior elements of the sacrum were not visualized in many of the examinations.

TABLE 1: Distribution of Pars Defects

Types of Pars Defects	Total No. of Cases	No. Defects by Level		
		L5	L4	L3
Bilateral, no subluxation	75	66	7	2
Bilateral, with subluxation	136	126	10	0
Unilateral, no subluxation	31	27	4	0
Unilateral, with subluxation	11	11	0	0
Totals	253	230	21	2

Lateral indentation or compression from soft tissue or bony callus was demonstrated in 51 patients; in half it was believed to be potentially significant. Bony stenosis of the lateral recesses was defined in 11 cases. In our clinical series there were no rare congenital lumbosacral dysplastic or acute traumatic defects.

Spondylolysis

The typical CT appearance of a vertebra with spondylolysis without spondylolisthesis is demonstrated in figure 1. Nondisplaced pars fractures lie just anterior to the facets and are seen on axial scans as horizontal lucencies extending into the spinal canal. In the sagittal plane, jagged defects separating the vertebral body and superior facet from the inferior facet are noted.

There were 103 patients with at least one pars defect but no dislocation. All of these patients were symptomatic. In 62% of these patients, no abnormality was demonstrated except the pars fractures. In the other 38%, one or more pathologic findings were recognized that were thought to be the cause of the patient's back pain or radiculopathy. Twenty-six patients had more than 5 mm of disk herniation, three had significant lateral callus formation, eight had foraminal stenosis, and two had lateral recess stenosis.

Spondylolisthesis

Axial CT scans become increasingly difficult to interpret as the amount of vertebral dislocation increases. The axial scans take on a "double-canal" appearance. This is a geometric distortion of the canal caused by the increase in lordosis that accompanies the spondylolisthesis and the abnormal relation of the vertebra and a narrowed disk space. The L5 disk space is angled so caudally that even maximal gantry tilt is unable to produce scans parallel to the disk. Sagittal images are most useful in these patients in evaluating the diameter of the spinal canal and the degree of dislocation (fig. 2).

Unilateral pars defects were seen in 16% of cases. Frequently they are associated with anomalies of the neural arch or sacrum. Assuming the microfracture hypothesis is also correct in this category, then one must explain why a fracture occurs in only one pars. It has been suggested that there may have been fracture of the opposite pars with healing or with attempted healing. Some support for this hypothesis is found in patients similar to the one in figure 3. This shows a

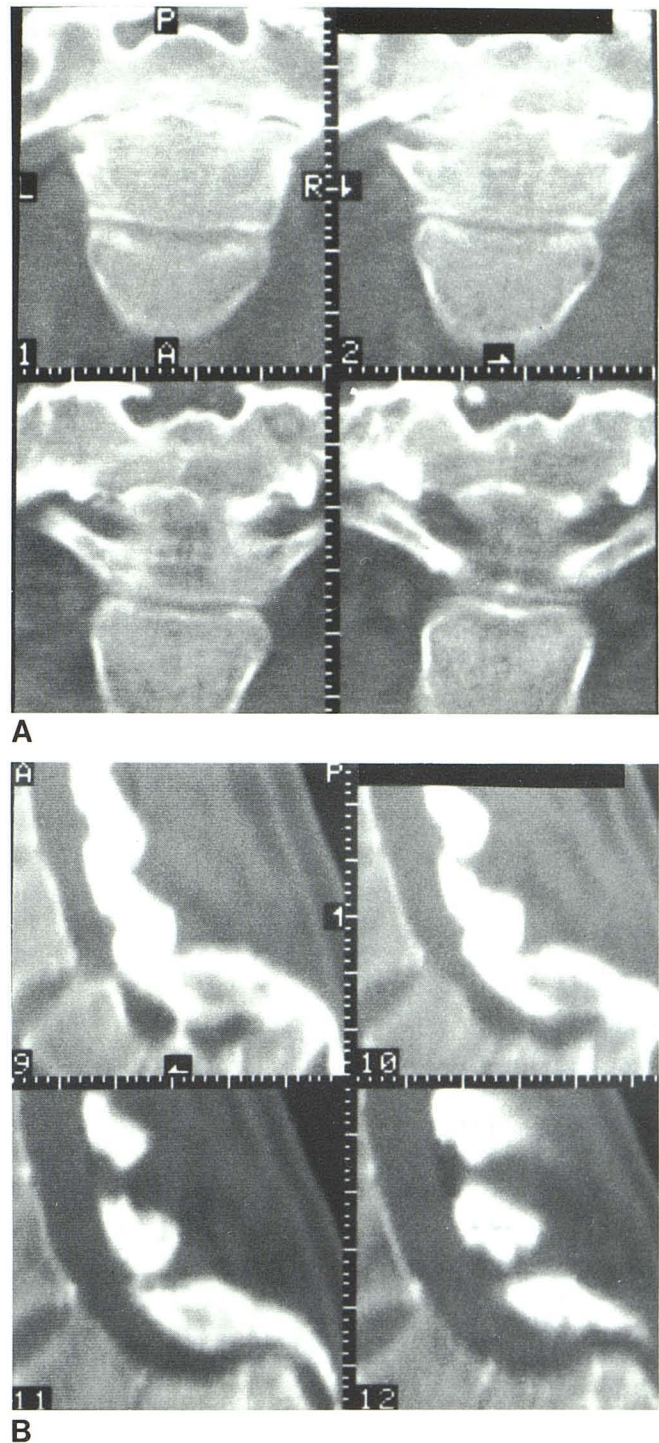
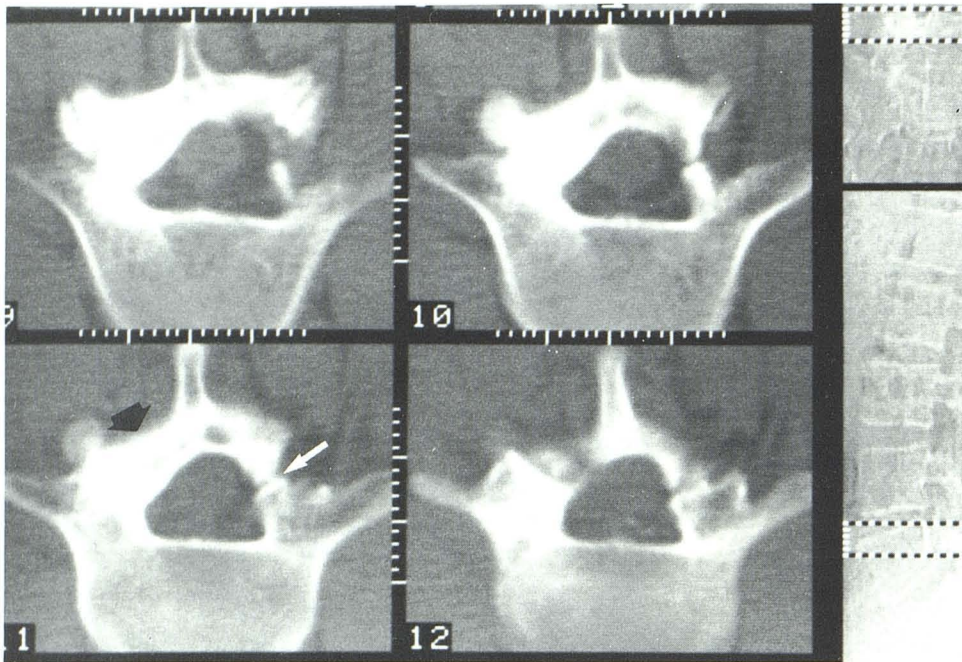
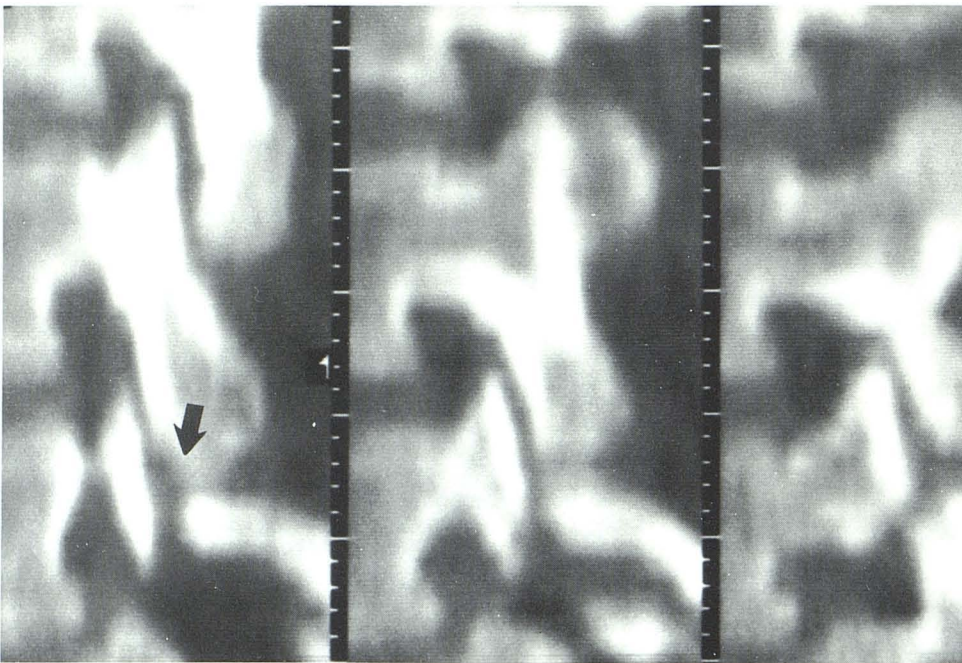


Fig. 2.—Severe juvenile spondylolisthesis. A, Axial scans. Three vertebral bodies are partly visualized on each section. B, Sagittal reformatted images demonstrate deformity of spinal canal.

typical right-sided pars defect, but the left pars and lamina are hypertrophied and sclerotic. The sagittal reformations demonstrate thickness of the bone and lower definition of the corticomedullary junction of the pars on the enlarged side. This may represent healing of microfractures and hypertrophy of bone along lines of stress.



A



B

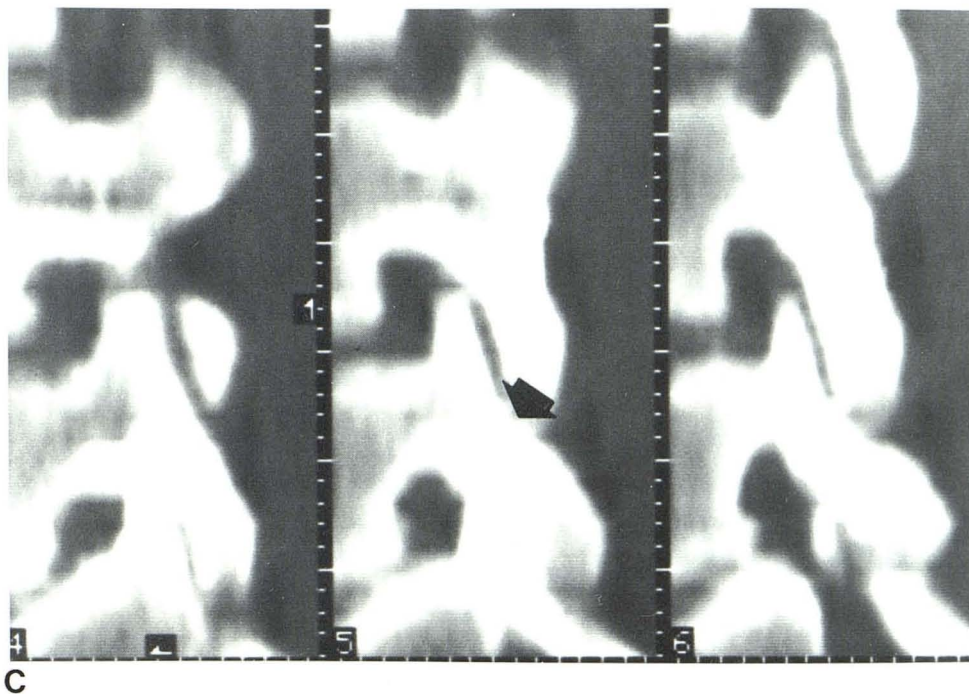
Fig. 3.—Unilateral pars defect with hypertrophy of opposite lamina. **A**, Pars defect (*white arrow*). Left lamina is hypertrophied (*black arrow*), neural arch is asymmetric, and spinous process is tilted toward left. **B**, Sagittal reformatted scan through right pars defect (*arrow*). Right pars and lamina are somewhat thinned. **C**, Sagittal reformatted scans (next page) through thickened pars interarticularis on left side (*arrow*).

Discussion

The etiology of spondylolysis has been the source of much controversy in the literature. The main point of contention is whether the pars interarticularis defect is developmental or acquired. Currently the most popular theory is that spondylolysis is a traumatic lesion, similar to stress fractures. The evidence revolves around the fact that the incidence of pars

defects is very low in young children and continues to increase with age until it reaches about 6% in the adult population. Also, in some children with acute back pain, nuclear bone scans will be positive, suggesting the acute nature of the fracture.

Spondylolisthesis is a condition whereby there is true anterior slippage of one vertebra on its next lowest mate from a defect(s) in the pars interarticularis. Its clinical significance,



aside from the obvious malalignment and malformation, rests mainly on the extent of functional disability and impairment of activity.

The following classification of spondylolisthesis was proposed by Wiltse [3, 4]:

Dysplastic. A congenital abnormality of the upper sacrum and/or the neural arch of L5 allows the lower lumbar vertebra to slide forward on the sacrum. The pars interarticularis is elongated and the facets dislocate. This is a very rare entity.

Isthmic. Type A: This is the most common type. The pars defect tends to appear at age 5½–6½ and has a definite familial propensity. It is not clear whether the lesion is from flexion or extension trauma. *Type B:* In type B, the pars interarticularis is not fractured, but elongated. This is thought to be from repeated but healed stress fractures. The deformity is found occasionally in a family whose other members show signs of classical pars defects. *Type C:* This is an acute, severe, traumatic injury to the vertebrae. It is the least common type of the group.

Degenerative. This disorder occurs at middle age. It is caused by severe degeneration of the facet joints and disk and results from intervertebral joint instability. The affected segment may be subluxed forward or backward, with concomitant cauda equina compression.

Pathologic. In this type, slippage occurs because of some generalized disorder of bone, such as Paget disease.

Iatrogenic. Dislocation of vertebrae may occur as a sequel to laminectomy with facetectomy, with subsequent loss of stability.

In his comprehensive study of spondylolisthesis, Wiltse [5] formulated a concept of pathogenesis. He suggested that the defect in the pars is caused by two factors: (1) a hereditary propensity, or dysplasia of the pars, probably present at more

than one anatomic level; and (2) unusual stress on the pars interarticularis in the lower lumbar spine from the erect stance and lumbar lordosis in man. He further suggested that, in most cases, stress will not produce dissolution of the pars without the familial dysplasia. The character of the dysplasia has not been elucidated completely, but the effect of the dysplasia appears to be an incomplete or inappropriate attempt at healing these microstress fractures.

In support of the fracture theory, Wiltse et al. [6] presented a series of 17 patients whose lumbar radiographs were thought to be normal, but later radiographs revealed pars interarticularis defects. All but one of these patients had been involved in some type of vigorous physical exercise. In five of these patients, the defect progressed to significant spondylolisthesis. A number of patients in this series were treated with body casts or corsets, and some were followed to complete healing.

Disk Herniation

Many patients with spondylolysis and spondylolisthesis demonstrate radiographic abnormalities without ever having significant back pain. It is clear, therefore, that the mere demonstration of the defect on CT does not necessarily indicate that the anatomic deformity is the cause of the patient's pain. According to Wiltse [4], pain in children is either from degeneration of the disk at the level of the spondylolisthesis or from acute pars fracture. He suggests that many, but certainly not all, degenerating disks are painful.

Degenerating disk at the level of the isthmic defect is more likely to be a cause of pain in adults [4]. However, true disk herniation is quite uncommon at the level of the pars defect; Briggs and Keats [7] and Wiltse [4] both reported an incidence

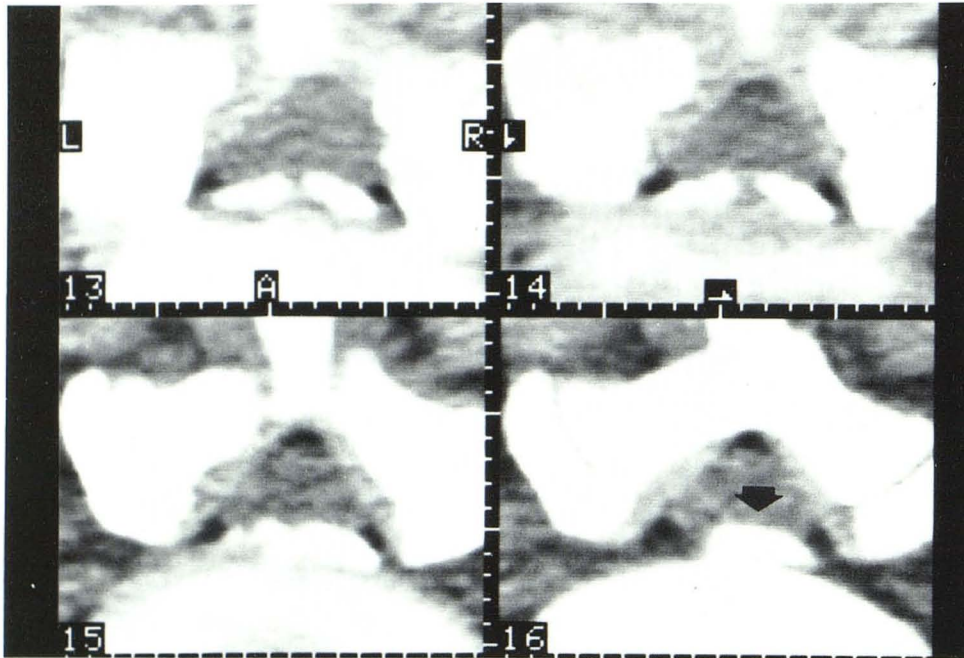
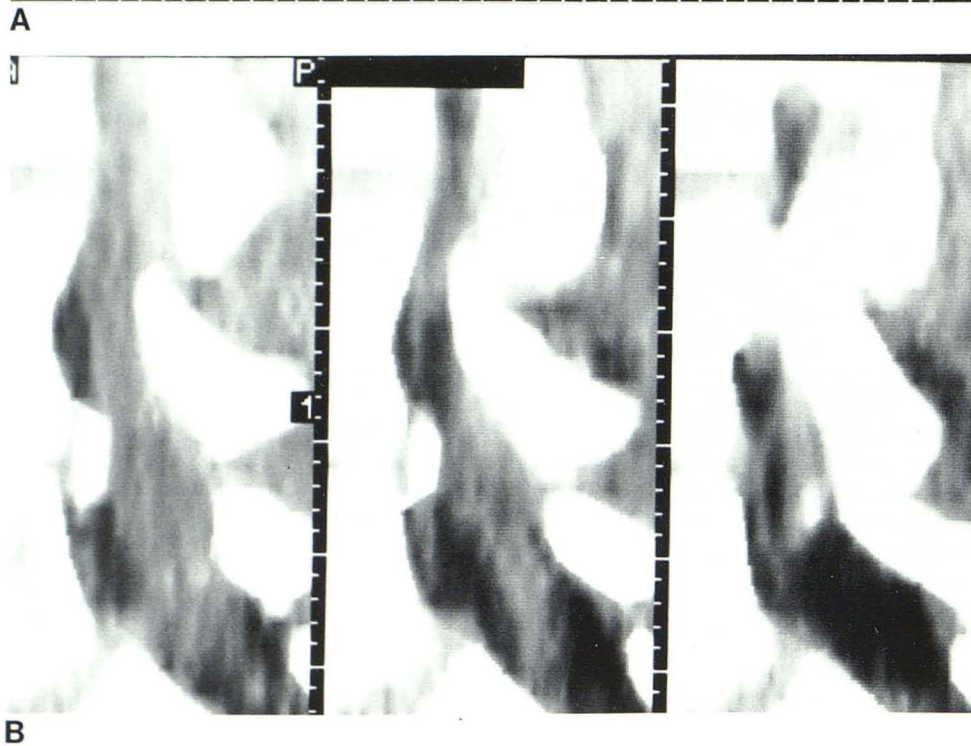


Fig. 4.—Unilateral left pars interarticularis defect with disk herniation. Axial scans (A) and sagittal reformatted scans (B) show herniated calcified disk (arrow).



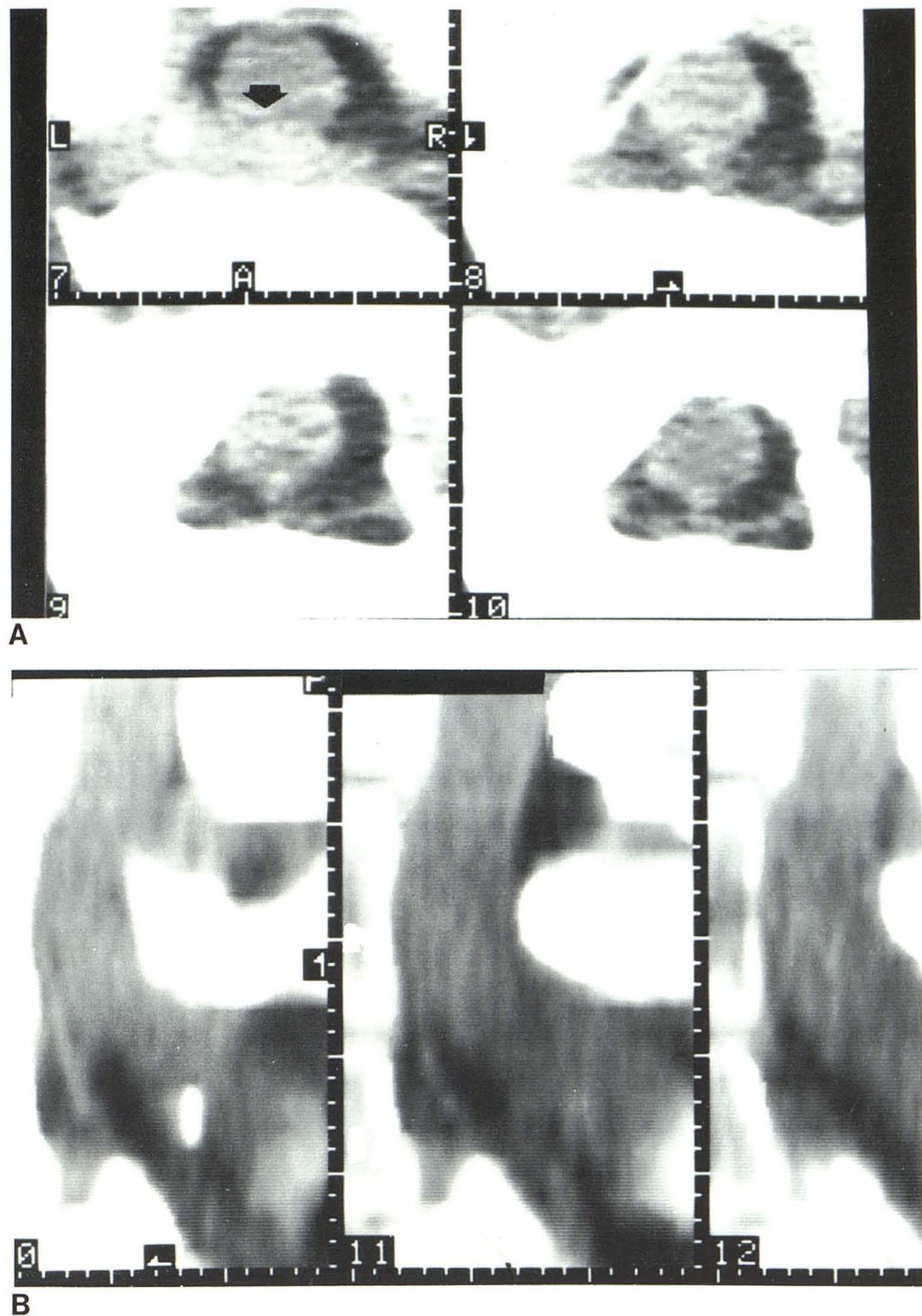
of 4%. In our series, only 6% of patients had more than 5 mm of anterior extradural soft-tissue defects at the level of the spondylolisthesis. Removal of the offending disk in these patients with or without concomitant spinal fusion may be curative. Back pain may also be from degeneration and abnormal motion at the disk space and abnormal traction on the anulus fibrosus.

Disk herniation at the interspace above the pars defect occurs much more often. MacNab [8] found abnormal L4 disk

in 31% of patients with spondylolisthesis at L5-S1. Significant disk herniation on CT may mean that the pars defect is asymptomatic and simple L4 discectomy will be curative.

At present, CT appears to be the most sensitive radiographic procedure for the estimation of disk protrusion or herniation. Sagittal reformations allow one to measure bulging of the anulus, which may be invisible on myelography, especially in patients with a wide epidural space. Definite disk protrusion is thought to have occurred when there is anterior

Fig. 5.—Apparent disk herniation. **A**, On axial scan 7 there is prominent soft-tissue bulge anterior to dura (*arrow*). **B**, Sagittal reformatted images clearly demonstrate that apparent soft-tissue defect is from beam angulation artifact.



epidural bulge of 5 mm or more. That is not to say that severe symptoms of disk herniation may not occur with lesser degrees of herniation or that all 5 mm bulges cause symptoms. Clinically, however, our experience has shown that patients operated for 5 mm disks have significant pathology. Fifty-three patients had 5 mm or more of disk herniation. Two patients had changes at two levels. A series of scans on a patient with central calcified disk herniation is shown in figure 4.

Caution must be used if the amount of disk herniation is being estimated only from the axial scans. In many of these patients, especially those who display the "double-canal" artifact, the axial scans tend to overestimate the amount of canal compression by bulging or extruded disks. On the axial view of figure 5, there appears to be a very prominent extradural defect caused by bulging disk. The sagittal images clearly demonstrate that the anulus is distorted, but no disk-material bulge is posterior to the plane of the back of the

sacrum. True disk herniation at the level of spondylolisthesis is uncommon, as noted above.

Foraminal Narrowing

When the L5 vertebral body slips forward on the sacrum, the neural arch can rotate on the pivot formed by its articulation with the sacrum, thereby compressing the foramen. Multiple small bone fragments at the upper end of the defect may add to the compression. Symptomatic nerve-root entrap-

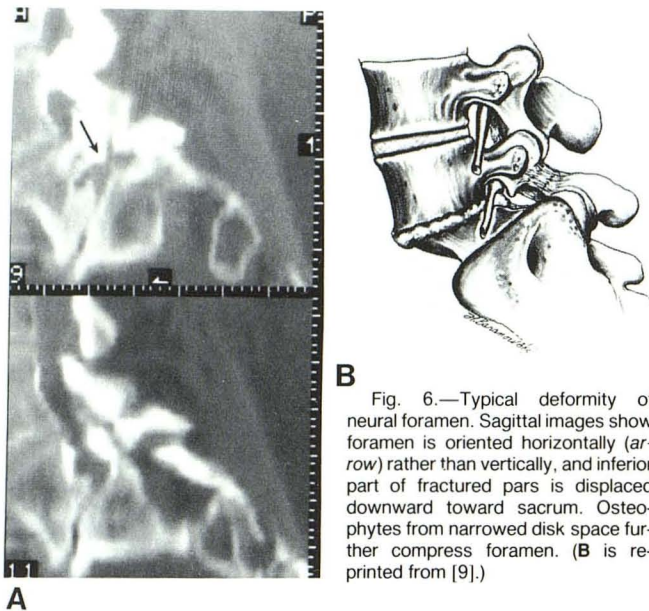
ment is more likely to occur if osteophytes have formed secondary to the disk degeneration.

In many of our cases, it appears that the foraminal narrowing was caused primarily by downward displacement of the inferior pole of the fractured pars rather than by the floating neural arch (figs. 6 and 7). This deformity looks more ominous as the disk space narrows and the spondylolisthesis increases.

Characteristic deformity of the neural foramina was seen in 84 of our patients. The height of the foramen at the involved segment is reduced, and the pedicle forming the roof of the foramen is positioned inferiorly, abnormally close to the sacrum (fig. 6). The orientation of the foramen becomes horizontal rather than vertical. This may be noted in patients with little or no forward subluxation, but the degree of flattening of the foramen appears to parallel the amount of slippage in most instances.

Associated with flattening of the foramen is a combination of anterior and posterior bony indentation. Indentation on the posterior-superior aspect of the foramen is caused by downward displacement of the inferior tip of the base of the fractured pars. This gives the foramen a horizontally bilobed appearance. The descending inferior tip of the fractured pars forms a central bony septum within the horizontally oriented canal. As the amount of spondylolisthesis increases, or the height of the affected disk space decreases, the central indentation on the foramen becomes more severe.

The foramen becomes further compromised by the presence of lateral osteophytes, which often occur as changes secondary to the narrowing and deformity of the disk space. On sagittal images optimized for soft tissue, one almost always can see that the deformed foramen is filled with



B Fig. 6.—Typical deformity of neural foramen. Sagittal images show foramen is oriented horizontally (arrow) rather than vertically, and inferior part of fractured pars is displaced downward toward sacrum. Osteophytes from narrowed disk space further compress foramen. (B is reprinted from [9].)

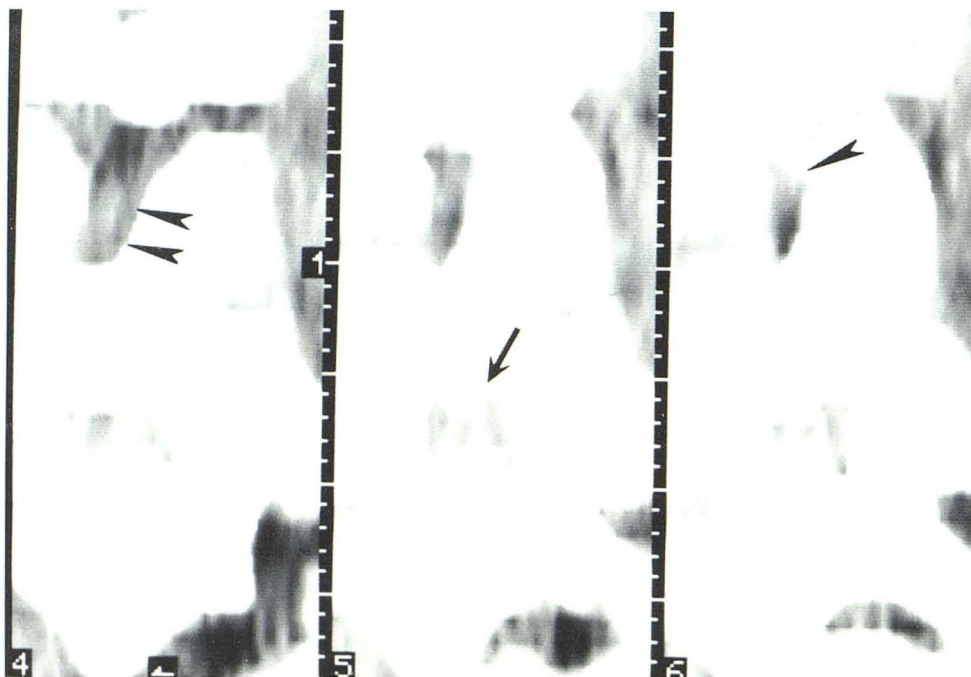


Fig. 7.—Sagittal scans through neural foramen displayed for soft-tissue detail. In L4–L5 foramen a normal nerve is surrounded by fat (arrowheads). At level of spondylolisthesis (L5–S1), the entire foramen is filled with soft-tissue density material, most likely bulging anulus (arrow).

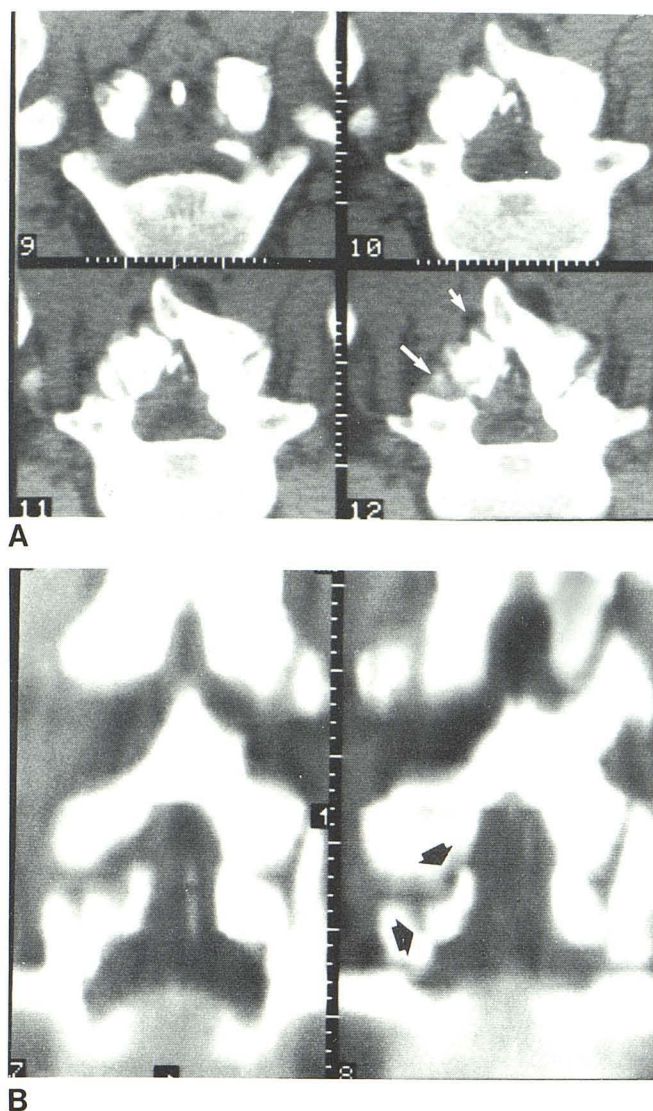


Fig. 8.—Anomaly of posterior arch of L5 (*short white arrow*) associated with bilateral pars interarticularis defects (*long white arrow*). **A**, Axial scans, **B**, Coronal reformation: free-floating bone fragment is visualized on left side extending medially into canal (*black arrows*).

abnormal soft tissue (fig. 7). The perineural fat is usually totally replaced by high-density soft tissue. It is not clear what this represents. Possibilities include lateral bulging of the annulus fibrosus, "callus" surrounding the pars defect, or a combination of the two. In any case, these findings of a deformed soft-tissue-filled foramen were noted in almost half of our cases, and very likely are symptom-producing.

Associated Anomalies

Spondylolysis is associated with a wide variety of congenital vertebral anomalies. The most common include spina bifida, hypoplastic facets, anomalous lamina, and combinations of the above.

Figure 8 shows a complex anomaly in a patient with bilateral

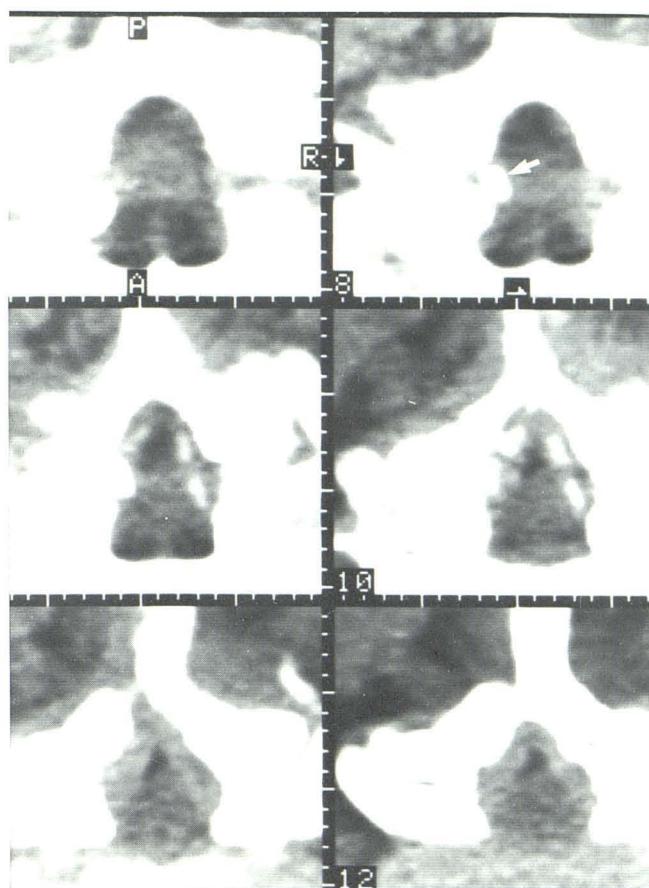


Fig. 9.—Compression of lateral aspect of theca by fibrocartilaginous mass arising from pars defect (*arrow*). This typically protrudes from anterior side of pars fracture and may compress theca or exiting nerve root.

pars defects. A prominent lateral bulge indenting the theca is noted on the soft-tissue views. A prominent cleft is noted through the left half of the neural arch, there is asymmetry of the posterior elements, and a free-floating bone fragment is seen posteriorly on the coronal scans. From these and similar examples, one is tempted to suggest that the pars defect is congenital in origin, at least in patients with major ring anomalies. It certainly is possible, however, that the defect is secondary to minor trauma and congenital weakness from the anomaly.

Lateral Canal Compression

Soft-tissue or bony indentation or compression of the lateral aspect of the spinal canal was noted in 49 patients. This defect has not been emphasized in the radiologic literature, but is described frequently in surgical articles as a fibrocartilaginous mass. Typically, there is a prominent soft-tissue bulge projecting medially from the site of the pars defect (fig. 9). In some patients there may be calcification or true ossification within or abutting the pars defect. These lateral soft-tissue or bony masses may indent the dura, and occasionally severely compromise the spinal canal. These changes can be

thought of as callus formed at the fracture site; the soft-tissue or bony sequel to pseudarthrosis formation. The axial plane is best for evaluating the presence and extent of this deformity.

Lateral Recess

Osseous indentation of the lateral recesses was seen in 11 cases. When present, the compression usually was at the site of the pars defect, and frequently, but not always, it was associated with callus formation.

REFERENCES

1. Roche MB, Rowe GG. Incidence of separate neural arch and coincident bone variations. *Anat Rec* **1951**;109:233-255
2. Glenn WV Jr, Rothman SLG, Rhodes ML. Computed tomography/multiplanar reformatted (CT/MPR) examinations of the lumbar spine. In: Genant HK, Chafetz N, Helms CA, eds. *Computed tomography of the lumbar spine*. San Francisco: University of California, **1982**:87-123
3. Wiltse LL. Spondylolisthesis: classification and etiology. *American Academy of Orthopedic Surgeons symposium on the spine*. St. Louis: Mosby, **1969**:143-167
4. Wiltse LL. Spondylolisthesis and its treatment. In: Ruge D, Wiltse LL, eds. *Spinal disorders*. Philadelphia: Lea & Febiger, **1977**:193-217
5. Wiltse LL. The etiology of spondylolisthesis. *J Bone Joint Surg [Am]* **1963**;44:539-569
6. Wiltse LL, Widell EH Jr, Jackson DW. Fatigue fracture the basic lesion in isthmic spondylolisthesis. *J Bone Joint Surg [Am]* **1975**;57:17-22
7. Briggs H, Keats S. Laminectomy and foramenotomy with chip fusion. Operative treatment for the relief of low back pain and sciatic pain associated with spondylolisthesis. *J Bone Joint Surg* **1947**;29:328-334
8. MacNab I. The management of spondylolisthesis. *Prog Neurol Surg* **1971**;4:246-276
9. Rothman SLG, Glenn WV Jr. Spondylolysis and spondylolisthesis. In: Newton TH, Potts DG, eds. *Modern neuroradiology*, vol 1, *Computed tomography of the spine and spinal cord*. San Anselmo, CA: Clavadel, **1982**:267-280