

Magnetic Resonance Imaging in Huntington Disease

J. Thayer Simmons¹
 Behram Pastakia¹
 Thomas N. Chase²
 Clifford W. Shults²

Four patients with Huntington disease were imaged using CT and inversion-recovery magnetic resonance (MR) imaging. In all four patients the caudate nucleus and corpus striatum were well demonstrated and noted to be atrophic. MR is believed to be superior to CT for imaging morphologic changes of Huntington disease.

Huntington disease is a progressive neurodegenerative disorder characterized by movement disorder, progressive dementia, and emotional disturbances. Morphologically it is characterized by diffuse atrophy, with the greatest loss of neurons seen in the caudate nucleus and putamen. The basal ganglia at death weigh about 50% of normal [1] and also demonstrate neuronal loss and gliosis. Receptor binding studies of postmortem specimens suggest that certain intrinsic striatal neurons and their efferent pathways to globus pallidus and substantia nigra are the major sites of pathologic disruption [2]. The pneumoencephalographic [3,], CT [4, 5], and positron emission ¹⁸F¹⁸FDG findings [6] in Huntington disease have been described. We describe the magnetic resonance (MR) findings in four patients with known Huntington disease.

Subjects and Methods

MR imaging was performed in four patients with Huntington disease at the National Institute of Health. A recent head CT study was performed on a GE 9800 or 8800 scanner in each case. Measurements of the caudate-caudate to outer table (CC/OT) ratio were performed as described by Barr et al. [5]. These were compared with age-matched normal volunteers (figs. 1 and 2).

MR was performed in coronal and axial planes, with a nominal slice thickness of 10 mm and a 2 mm gap between slices. Images were obtained on a superconducting MR imager (Picker Vistaview) operating at a field strength of 0.5 T. Scans were obtained using the inversion-recovery (IR) pulse sequence with an inversion time (TI) of 600 msec, and repetition time (TR) of 2500 msec, using 256 views with two averages. A series of eight sections was obtained in an examination time of 10 min. Scans were obtained in both the axial and coronal projections. T2-weighted images using a TE of 120 msec and TR of 2833 msec were then obtained. Assessment of the corpora striata and caudate nucleus was made in the coronal projection on the scan slice closest to or including the pituitary gland. On the axial scan, assessment was made from three adjacent slices, the middle of which included the frontal horns of the lateral ventricles. Atrophy of these structures, when compared with age-matched controls, was judged as mild, moderate, or severe.

Case Reports

Case 1

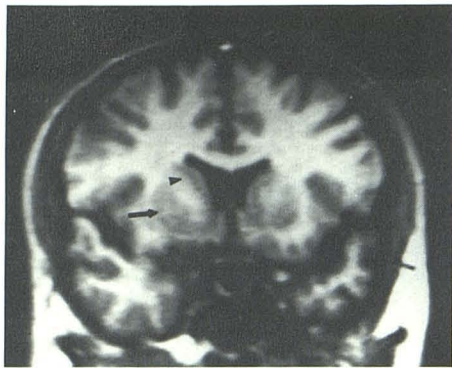
A 40-year-old right-handed man was diagnosed as having Huntington disease 9 years

Received February 22, 1985; accepted after revision May 21, 1985.

¹ Department of Diagnostic Radiology, National Institutes of Health, Clinical Center, Bldg. 10, Room 1C660, Bethesda, MD 20205. Address reprint requests to J. T. Simmons.

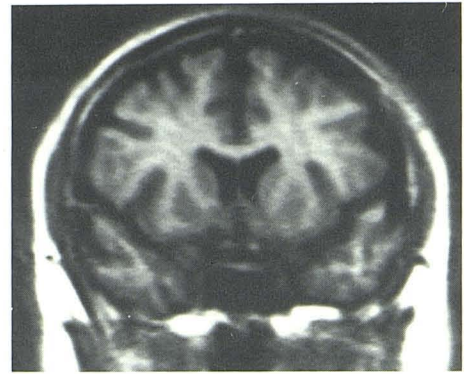
² National Institute of Neurological and Communicative Disorders and Stroke, Experimental Therapeutic Branch, Intramural Research Program, National Institutes of Health, Bethesda, MD 20205.

AJNR 7:25-28, January/February 1986
 0195-6108/85/0701-0025

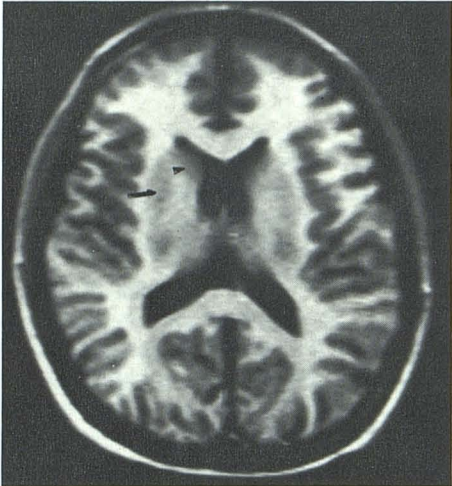


A

Fig. 1 (left).—Coronal (A) and axial (B) sections from 33-year-old normal male volunteer. Caudate nucleus (arrowheads) and putamen (arrows).

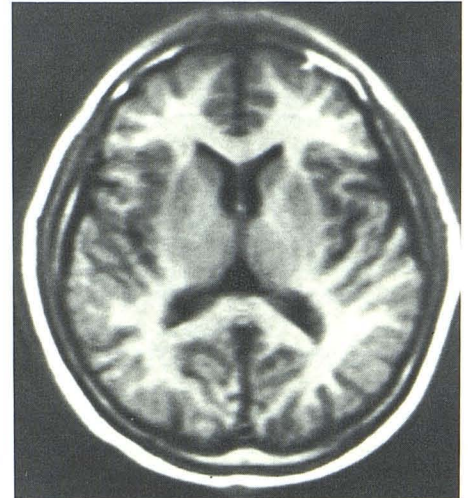


A

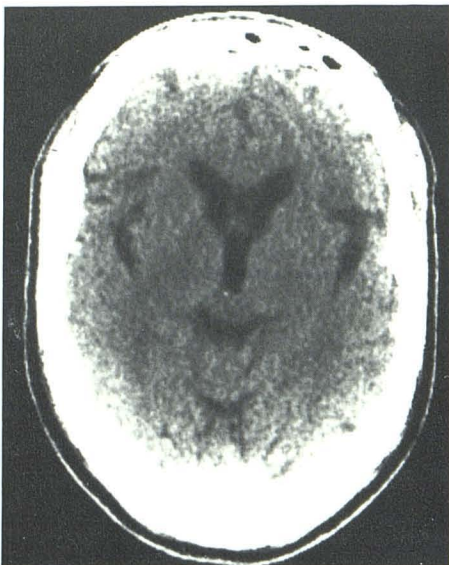

B

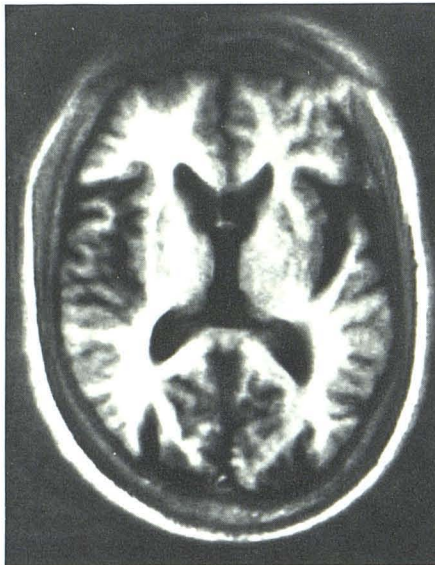
Fig. 2 (right).—Coronal (A) and axial (B) sections from 52-year-old normal male volunteer.



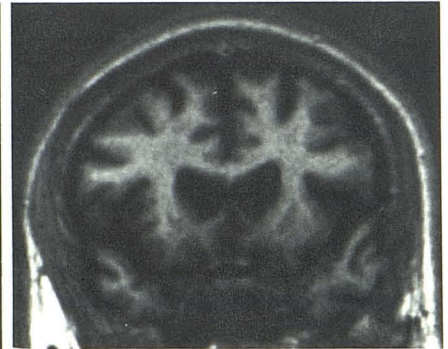B



A



B



C

Fig. 3.—Case 1. A, Axial CT scan through head of caudate nucleus. Axial (B) and coronal (C) MR scans. Moderate atrophy of caudate and corpus striatum.

before the study. His father and three of six siblings had died of Huntington disease. Neurologic examination revealed moderate dementia and inappropriate affect. The patient had severe chorea of the head, trunk, and limbs. CT (fig. 3A) revealed a CC/OT ratio of 0.153, the smallest of the four patients, with mild diffuse atrophy. Coronal and axial IR scans (figs. 3B and 3C) demonstrated moderate thinning of the putamina and caudate nuclei. In addition, there was moderate diffuse cortical atrophy.

Case 2

A 50-year-old right-handed man had a 12 year history of Huntington disease. The patient's mother died of the disease and six of the patient's seven siblings had developed it. Neurologic examination showed profound dementia and mild chorea of the face, neck, hands, and feet. CT (fig. 4A) demonstrated a CC/OT ratio of 0.167 with mild

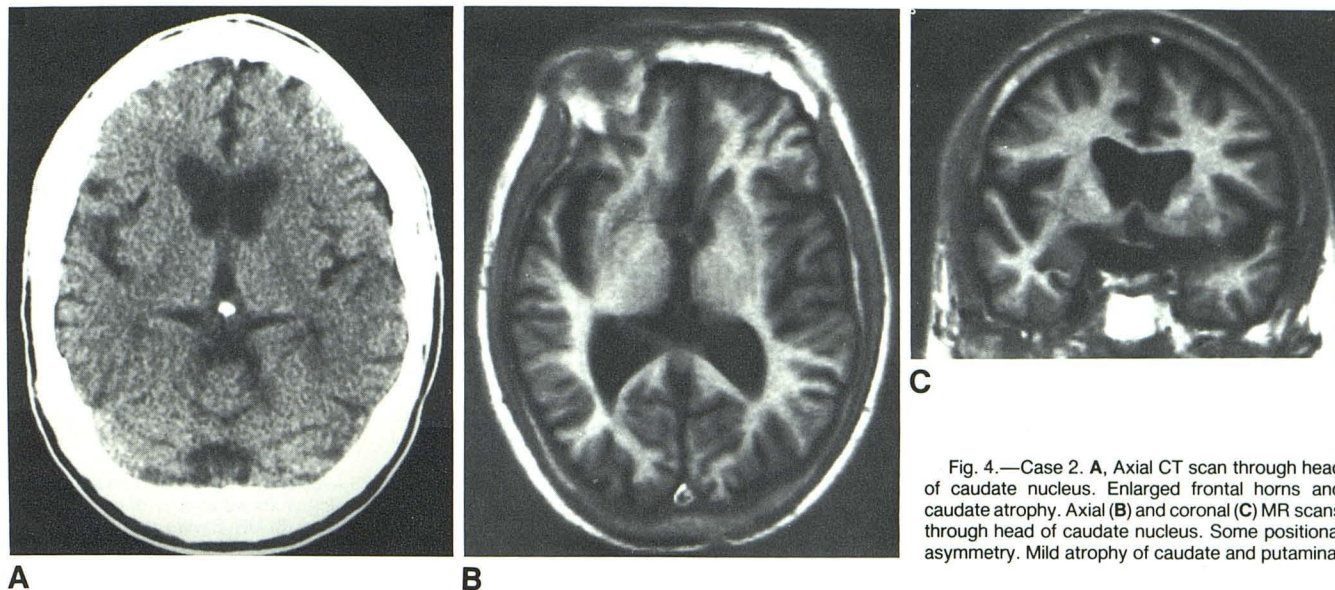


Fig. 4.—Case 2. A, Axial CT scan through head of caudate nucleus. Enlarged frontal horns and caudate atrophy. Axial (B) and coronal (C) MR scans through head of caudate nucleus. Some positional asymmetry. Mild atrophy of caudate and putamina.

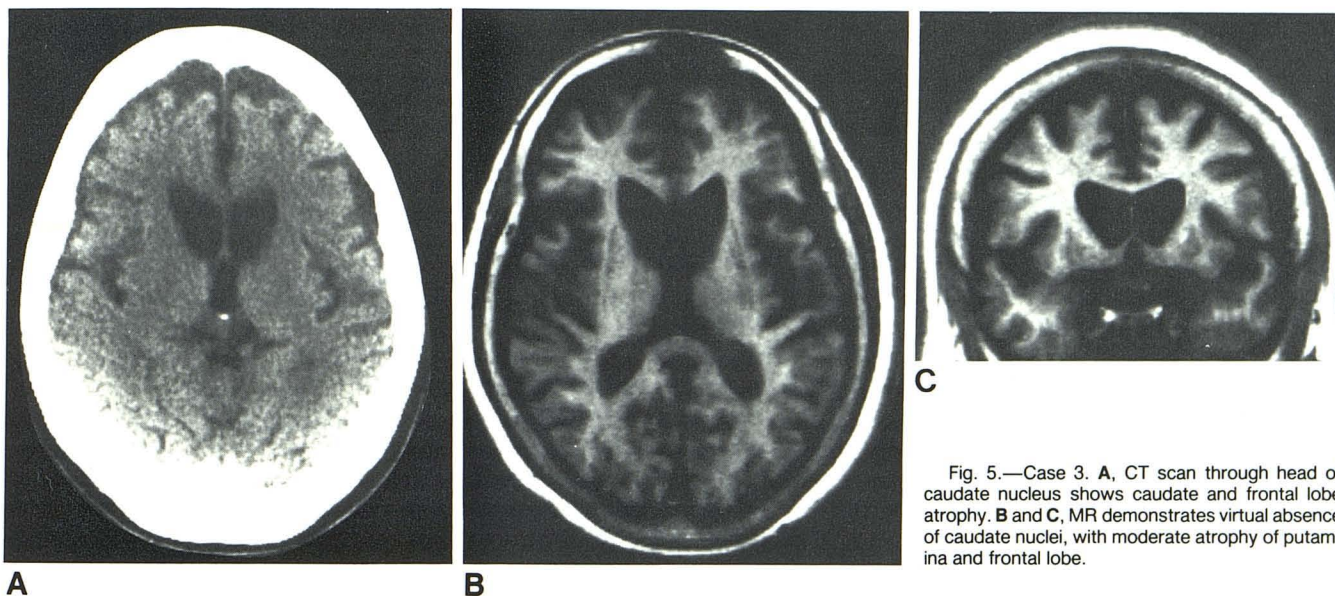


Fig. 5.—Case 3. A, CT scan through head of caudate nucleus shows caudate and frontal lobe atrophy. B and C, MR demonstrates virtual absence of caudate nuclei, with moderate atrophy of putamina and frontal lobe.

diffuse atrophy. On MR (figs. 4B and 4C), mild atrophy of the caudate nuclei and putamina was evident, as was mild diffuse cortical atrophy.

Case 3

A 52-year-old left-handed woman had a 4 year history of Huntington disease. Her father died in his fifties with dementia and abnormal movements. Neither of the patient's two sisters had clinical evidence of Huntington disease. The patient had mild memory loss and chorea, most prominent in her face and hands. CT (fig. 5A) revealed a CC/OT of 0.231, the largest of our four patients. In addition, frontal lobe atrophy was seen. Coronal and axial IR scans (figs. 5B and 5C) demonstrated severe atrophy of the caudate nuclei and moderate atrophy of the putamina and frontal lobes.

Case 4

A 28-year-old right-handed woman was diagnosed as having the rigid form of Huntington disease 3 years before admission. The patient's father had died of the disease at age 48. Eight of the father's 13 siblings had Huntington disease. Neurologic examination revealed

increased muscle tone with cogwheel rigidity in her arms. CT (fig. 6A) revealed a CC/OT ratio of 0.169 with mild diffuse atrophy. MR (figs. 6B and 6C) showed severe atrophy of the caudate nuclei, with relative sparing of the putamina, as seen on the coronal view. The frontal lobes were mildly atrophic.

Results

In all four of our patients, MR imaging clearly demonstrated the characteristic atrophy of the caudate nuclei and the putamina, as well as cortical atrophy. The globus pallidus could not be separated reliably from the putamen using this particular pulsing sequence, a sacrifice necessary to keep the examination time relatively short.

T2-weighted images were obtained using a TE of 120 msec and TR of 2833 msec. Images of the basal ganglia were judged inferior to the IR, probably because of the examination time, and the lower contrast-to-noise ratio inherent to the field strength of 0.5 T. Our more recent experience with non-Huntington-disease patients on a 1.5 T system has demon-

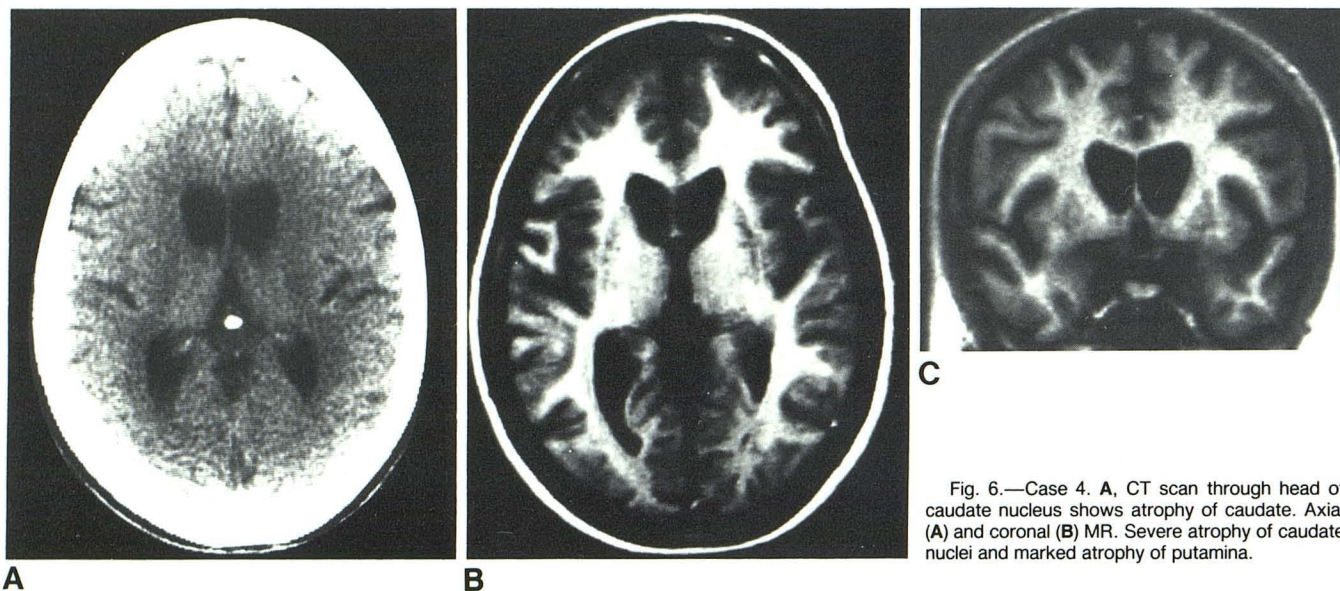


Fig. 6.—Case 4. A, CT scan through head of caudate nucleus shows atrophy of caudate. Axial (A) and coronal (B) MR. Severe atrophy of caudate nuclei and marked atrophy of putamina.

strated excellent T2-weighted images of the basal ganglia. This has been corroborated by other investigators [7].

Discussion

Huntington disease is an inheritable disorder that is autosomal dominant with complete penetrance. It has a worldwide prevalence rate of 5–10/100,000 with areas of increased prevalence in western Scotland and Venezuela, where prevalence reaches 7000/100,000 [2]. Molecular genetic studies of the families in Venezuela have recently linked genetic expression of Huntington disease to a locus on chromosome 4 [8].

Clinical manifestations of Huntington disease usually become apparent in the fifth and sixth decades, with a less common juvenile form presenting often as early as childhood. Unlike the choreiform movements of the former, the juvenile form is characterized by a Parkinson-like movement disorder.

The characteristic caudate and cortical atrophy was first described radiographically using pneumoencephalography [3]. Terrence et al. [4] and Barr et al. [5] described ratios of frontal horn to bicaudate diameter and bicaudate diameter to outer table diameter, respectively, as reliable CT criteria for Huntington disease. Atrophy of the caudate nuclei is usually seen on CT with the clinical appearance of the first motor sign. Cortical atrophy then begins, usually in the frontal lobe, and then advances posteriorly as the disease progresses [9]. In that same study, chorea was positively correlated with caudate atrophy, and functional and cognitive impairments were strongly related to the degree of atrophy [9]. Nevertheless, CT has been shown to be relatively insensitive in early detection of Huntington disease [10].

More recently, Kuhl et al. [6] demonstrated hypometabolic areas in the caudate and putamen that precedes bulk tissue loss. In 15 patients with normal CT scans and who were at risk for Huntington disease, six had hypometabolic areas in the caudate. This suggests that ^{18}F FDG positron emission scanning may be more sensitive than CT in Huntington disease.

In our limited series, correlation between neurologic examination and MR findings, and the respective sensitivities of MR versus CT, could not be evaluated. When compared with CT, MR demonstrated the putamina and caudate nuclei with much improved definition, and the addition of coronal views further enhanced the three-dimensional assessment of these nuclei. With further scanning experience, it is not unreasonable to assume that MR will prove to be more sensitive than CT in Huntington disease, and perhaps it will help in detecting changes in clinically asymptomatic patients.

REFERENCES

1. Bird E. Brain in Huntington's chorea. *Psychol Med* 1978;8:357–360
2. Shoulson I. Huntington's disease. *Neurol Clin* 1984;2:515–526
3. Blinderman EE, Weidner W, Markham CH. The pneumoencephalogram in Huntington's chorea. *Neurology* 1964;28,14:601–607
4. Terrence CF, Delaney JF, Alberts MC. CT for Huntington's disease. *Neuroradiology* 1977;13:173–175
5. Barr AN, Heinze WJ, Dobben GD, Valvassori GE, Sugar O. Bicaudate index in CT of Huntington's disease and cerebral atrophy. *Neurology* 1978;28:1196–1200
6. Kuhl DE, Phelps ME, Markham CH, Metter EJ, Riege WH, Winter J. Cerebral metabolism and atrophy in Huntington's disease determined by ^{18}F FDG and CT scan. *Ann Neurol* 1982;12:425–434
7. Smith A, Modic MT, Kozachuk W, Weinstein ML, Chou SC, Duchesneau PM. Imaging of the basal ganglia and brain stem at 1.5 tesla: an anatomic and MR study. Presented at the annual meeting of the American Roentgen Ray Society, Boston, April 1985
8. Grisella JF, Wexler NS, Conneally PM, et al. A polymorphic DNA marker genetically linked to Huntington's disease. *Nature* 1983;306:234–238
9. Sax DS, O'Donnell B, Butters N, Menzer L, Montgomery K, Kayne HL. CT, neurologic and neuropsychological correlates of Huntington's disease. *Int J Neurosci* 1983;18:21–36
10. Oepen G, Ostertag CH. Diagnostic value of CT in patients with Huntington's chorea and their offspring. *J Neurol* 1981;225:189–196