

NMR Imaging of Acute Experimental Cerebral Ischemia: Time Course and Pharmacologic Manipulations

Robert M. Levy,¹ Isamu Mano,² Antonio Brito,² and Yoshio Hosobuchi¹

Nuclear magnetic resonance (NMR) imaging was used to evaluate the intracerebral changes over time in gerbils after unilateral carotid artery ligation. Each animal was imaged during one of three stated periods 3–28 hr after surgery and again after administration of dexamethasone, morphine, or naloxone, agents reported to affect the clinical outcome of ischemic cerebral lesions. Asymptomatic animals exhibited no differences between the occluded and control hemispheres in relative signal intensity or in T_1 or T_2 relaxation times, but symptomatic animals demonstrated significant differences in these parameters between hemispheres. The ischemic lesion was detected at the earliest imaging time, 3 hr after surgery. A linear increase was observed in the relative interhemispheric signal intensity in three of four intensity images and in T_1 and T_2 relaxation times over the 24 hr experiment. No effect was noted on any image parameter as a result of pharmacologic manipulations. The results suggest that NMR may be of significant diagnostic importance for acute cerebral ischemia and infarction in man.

Despite the clinical importance of early diagnosis and follow-up of acute cerebral ischemia, current imaging modalities are inadequate to perform these functions. Radioisotope techniques are hampered by poor spatial resolution, while computed tomography is unable to reliably detect acute cerebral infarction within 24 hr, even with contrast enhancement [1–4]. Nuclear magnetic resonance (NMR) is a new, noninvasive technique for obtaining cross-sectional images of the brain [5, 6]. Both normal and pathologic tissues can be identified on NMR images *in vivo*. Because NMR imaging appears to be acutely sensitive to changes in the water content of tissues, and since edema secondary to prolonged anoxia is one of the primary pathophysiologic concomitants of cerebral ischemia [7–9], NMR may be exceptionally well suited for the early diagnosis and evaluation of acute cerebral ischemia [10].

Gerbils have long been used as an experimental model of cerebral ischemia and ischemic cerebral edema [11, 12]. These animals lack both a complete circle of Willis and a posterior communicating artery. In addition, about 40% of gerbils also lack an anterior communicating artery or have insufficient collateral perfusion to provide compensatory protection after unilateral carotid artery ligation; these animals will develop hemispheric ischemia and stroke. We used this animal model to evaluate the ability of NMR imaging to detect acute ischemic cerebral lesions. We also administered agents reported to have significant effects on the clinical outcome of ischemic lesions to determine whether these effects were apparent on subsequent NMR images.

Materials and Methods

Surgical and Pharmacologic Manipulations

One hundred thirty-two adult male gerbils weighing 55–70 g were anesthetized with 40 mg/kg intraperitoneal pentobarbital. With the aid of the operating microscope, the right common carotid artery was isolated, coagulated with microbipolar forceps, and divided. The incisions were then closed and the animals returned to their cages. Within 3 hr after surgery, all gerbils had recovered from anesthesia. The animals were then evaluated for neurologic deficit by the method of Hosobuchi et al. [12].

The gerbils were divided into two major groups: those that were asymptomatic and those demonstrating clear neurologic deficits. On the basis of pathologic analyses [11, 13], the gerbils with neurologic deficits were presumed to have sustained ischemic cerebral infarcts. During three periods commencing 3–24 hr after carotid occlusion, subgroups of animals were again anesthetized with pentobarbital and NMR images were obtained according to the technique of Crooks et al. [5]. NMR images of five unoperated control animals were also obtained.

After the initial imaging procedure, pharmacologic agents were administered. One subgroup of symptomatic animals was given 2 mg/kg naloxone by intraperitoneal injection immediately after imaging during all three periods. These animals underwent repeat imaging 6–10 min postinjection. A second subgroup of symptomatic animals was given intraperitoneal injections of 5 mg/kg dexamethasone immediately after imaging during the 3–7 hr period. This dose and interval replicated those reported to increase survival rates and improve neurologic deficits in other studies [14, 15]. These animals underwent repeat NMR imaging 60–90 min after injection, and the dose of dexamethasone was repeated twice at 8 hr intervals. Twenty-four hr after carotid occlusion, after three doses of dexamethasone, animals were reanesthetized and underwent NMR imaging a third time. The asymptomatic group was given 10 mg/kg morphine sulfate by intraperitoneal injection immediately after initial imaging. These animals underwent repeat imaging 60–90 min after morphine injection.

NMR Imaging Technique

Each gerbil underwent initial NMR imaging either 3–7, 12–16, or 24–28 hr after carotid occlusion. Animals underwent repeat imaging as described. Animals were wrapped loosely in plastic sheeting for immobilization and placed in a supine position in the imaging field. The gerbil brain was imaged in the coronal plane bisecting both hemispheres symmetrically.

¹ Department of Neurological Surgery, University of California School of Medicine, San Francisco, CA 94143. Address reprint requests to R. M. Levy at the department's editorial office, Suite 807, 350 Parnassus Ave., San Francisco, CA 94117-3690.

² Radiologic Imaging Laboratory, University of California School of Medicine, San Francisco, CA 94143.

The NMR imager used for this study has been described in detail elsewhere [5, 6]. It has a resistive magnet that produces a 0.35 Tesla magnetic field with a useful aperture of 6.5 cm in diameter, which corresponds to a hydrogen nucleus resonant frequency of 15 MHz. Each imaging procedure produces five contiguous sections 5 mm thick with a spatial resolution of 1×1 mm.

The approximate intensity of the image at each location is given by the equation $I = Hf(v) \exp(-a/T_2) [1 - \exp(-b/T_1)]$, in which I is the NMR intensity in a particular region of the image; H is the local hydrogen density; a is the T_2 parameter of the instrument, measured in milliseconds; b is the T_1 parameter of the instrument, measured in seconds (T_1 and T_2 parameters of the instrument should not be confused with the T_1 and T_2 relaxation times of tissues); and $f(v)$ is a function of both the speed with which hydrogen nuclei move through the region being imaged and the fraction of the total number of nuclei.

The imager supplied four spin-echo images for each of the five sections within a total scanning time of 6.5 min, using the four different T_1 and T_2 parameter combinations given by $a = 28$ or 56 msec and $b = 0.5$ or 1.0 sec [16]. The four resulting intensity images were used to calculate four additional images from the above equation. These represent the distribution of tissue T_1 , T_2 , $Hf(v)$, and asymptote A . The latter image was obtained by calculating I when $b = \text{infinity}$. Thus, eight images were obtained for each image slice.

$Hf(v)$ was not included in the current study because of the tremendous variability in this parameter. It is important to note that although T_1 and T_2 relaxation times are absolute and therefore are valid for comparisons among gerbils imaged on the same machine, the signal intensity is tuned for each imaging procedure. Thus, the intensity value is valid only for hemispheric comparison within each image.

NMR Image Analysis

To determine which image section included the greatest surface area of gerbil brain, the five contiguous intensity images were first displayed. The optimal image was then magnified. Since the NMR imager has insufficient resolution to isolate small regions of focal infarction, and since the region of image abnormality usually encompassed the whole right hemisphere, we defined the regions of interest (ROI) as each entire hemisphere. Using a track ball-driven cursor, these ROI were defined, and an ROI program calculated the average signal intensities and, from these, the average T_1 , T_2 , and $Hf(v)$ values for the tissue.

Results

Neurologic Evaluation

Of the 132 operated gerbils, 44 exhibited clear neurologic deficits. This represents a stroke rate of 33%, which is generally in agreement with that reported in the literature [9, 11, 12]. Histologic analysis confirmed the presence of right-sided ischemic infarction in symptomatic animals. The symptomatic gerbils began to manifest signs of stroke as soon as they recovered from anesthesia. No animals developed neurologic deficits more than 4 hr after surgery. The most frequently observed neurologic deficit was hemiparesis, as manifested by a paucity of left-sided movement and failure to resist forced lateral pulsion with the extremities of the left side. Many symptomatic animals displayed a rapid, sporadic circling movement, usually toward the side of the lesion.

NMR Imaging

Asymptomatic gerbils exhibited no differences between the occluded and control hemispheres in relative signal intensity or in T_1

or T_2 times. The T_1 and T_2 times in these animals were comparable with those obtained for control gerbils (figs. 1 and 2). These times remained at control levels throughout the experiment.

In contrast, symptomatic animals demonstrated significant differences, both between hemispheres and as compared with asymptomatic controls, in T_1 and T_2 times (figs. 1 and 2). Significant differences were also noted in many of the intensity images (fig. 3). The ischemic lesion could be detected reliably as early as 3 hr after surgery, the earliest imaging time, in the T_2 ($p < 0.05$) and in three of the four intensity images ($p < 0.001$).

Of the intensity images, all except I ($a = 28$ msec, $b = 0.5$ sec) had relative signal intensities consistently elevated in the ischemic hemisphere (fig. 3). Significant differences in the interhemispheric signal intensity were first seen at the 3–7 hr imaging time and appeared to increase over the 24 hr period of the experiment. The most marked difference was noted in the I ($a = 56$ msec, $b = 1.0$ sec) image at 24–28 hr, in which the occluded hemisphere produced a signal intensity 122.3% that of the control side ($p < 0.001$).

T_1 and T_2 relaxation times appeared to increase in a linear manner over the 24 hr period of the experiment. The increase in T_2 relaxation times reached significance at the 3–7 hr imaging time, and by 12–16 hr was highly significant ($p < 0.001$). By the 24–28 hr imaging times, the mean T_2 value for the ischemic hemisphere was about 130% that for asymptomatic controls (70.8 ± 4.2 vs. 55.2 ± 0.7 ; $p < 0.001$).

The mean T_1 relaxation time was elevated approximately 11% and 17% as compared with that of controls at the 3–7 hr and 12–16 hr imaging times, respectively, although these differences were not statistically significant because of large sample variations. By the 24–28 hr imaging time, the mean T_1 time for the occluded hemisphere rose to 147% that of the control side (1.413 ± 0.90 vs. $0.961 \pm .044$; $p < 0.001$).

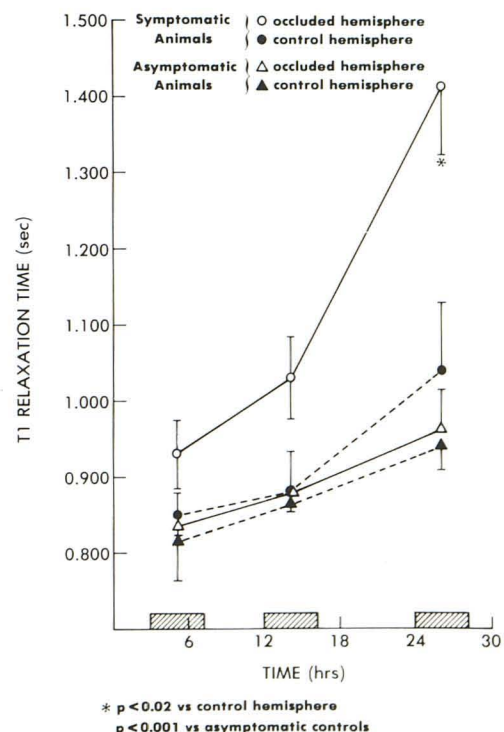


Fig. 1.— T_1 relaxation times versus time after unilateral carotid artery occlusion in gerbils.

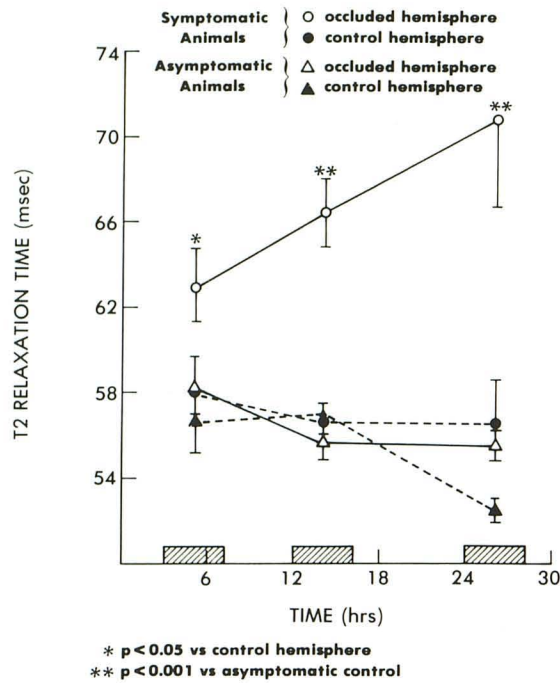


Fig. 2.—T₂ relaxation times versus time after unilateral carotid artery occlusion in gerbils.

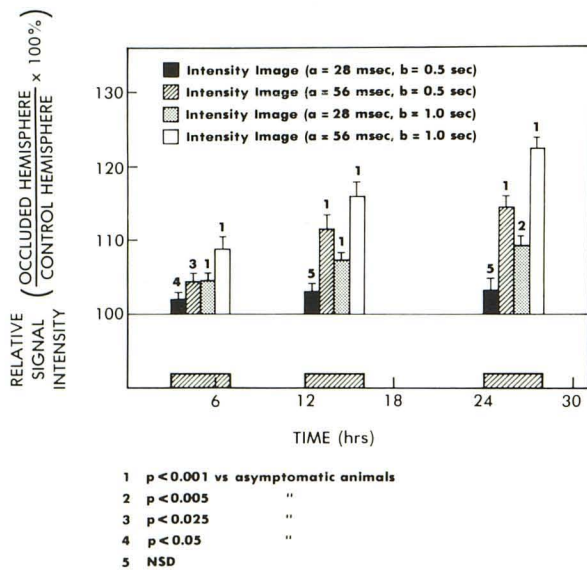


Fig. 3.—Interhemispheric contrast in signal intensity of four different intensity images versus time after unilateral carotid artery ligation in gerbils. a = T₁ parameter of image; b = T₂ parameter of image.

Pharmacologic Study

Despite reports that naloxone administration reverses the neurologic deficits seen in animals after acute cerebral ischemic lesions, preliminary results failed to demonstrate an effect of this opiate antagonist on any of the NMR imaging parameters evaluated. In comparing the initial NMR image with those obtained 6–10 min after injection of 2 mg/kg naloxone, no significant differences between the prenaloxone and postnaloxone conditions were ob-

served at any of the three imaging times during the 24 hr testing period. Morphine sulfate administration, which has been reported to precipitate neurologic symptoms in previously asymptomatic animals, also failed to affect any of the NMR imaging parameters evaluated. Dexamethasone treatment was not associated with any changes in the NMR images of the ischemic hemisphere. Sixty to 90 min after the administration of 5 mg/kg dexamethasone, no significant changes in T₁ or T₂ relaxation times were noted as compared with untreated animals. NMR images of animals treated with dexamethasone every 8 hr for 24 hr were also unchanged as compared with untreated animals at this same time. However, it was observed that dexamethasone apparently had a negative effect on the 24 hr survival rate for experimentally infarcted gerbils: Whereas five of 11 untreated symptomatic gerbils scheduled for NMR imaging 24–28 hr after surgery died before NMR imaging could be accomplished, seven of 11 gerbils treated with dexamethasone died within the same time period.

Discussion

Cerebral ischemia secondary to unilateral carotid artery ligation in the experimental gerbil model appears to be reflected in T₁ and especially T₂ relaxation times, as well as in the relative interhemispheric signal intensity, over the first 24 hr after surgery. The physiologic significance of these changes remains to be elucidated. The increases in T₁ and T₂ relaxation times and the increasing interhemispheric difference in signal intensity after unilateral carotid artery occlusion probably reflect the focal edema that develops as a result of ischemic cerebral lesions [7–9, 13]. This hypothesis gains support from the observation that the ischemic hemisphere in infarcted gerbils contains significantly more water than the control side [8, 17]. Schuier and Hossmann [18] reported a 3% increase in cerebral water content within 4 hr of experimentally induced ischemic lesions in cats. This increase appears to be progressive over several days [4]. We observed that 14 hr after carotid occlusion in symptomatic gerbils (n = 10), water content of the infarcted hemisphere was 105.5% ± 0.9% that of the control side, whereas in asymptomatic animals (n = 8), this difference was nonexistent (100.4% ± 0.4%; p < 0.001).

The effect of naloxone in reversing neurologic deficit secondary to cerebral ischemia has been well documented in several species [12, 19–22]. In the current experiment, no changes in any of the parameters of the NMR image were noted 6–10 min after naloxone administration. While the lack of observable effect may be attributable to the concurrent pentobarbital anesthesia, it is also quite possible that the behavioral effect reported for naloxone is not precipitated by a lessening of ischemic cerebral edema. The rapid onset and rapid cessation of naloxone action in this system tends to support this hypothesis.

Hosobuchi et al. [12] reported that the administration of morphine sulfate precipitates ischemic neurologic deficits in 30–60 min in previously asymptomatic animals. In our experiment, administration of 10 mg/kg morphine sulfate produced no effect on the subsequent NMR images. As in the case of the opiate antagonist naloxone, it appears that the reported behavioral effects of opiates on neurologic deficits secondary to cerebral ischemia are not accompanied by alterations in ischemic cerebral edema.

Harrison et al. [14, 15] reported that intraperitoneal injection of 5 mg/kg dexamethasone in gerbils after unilateral carotid artery ligation had a beneficial effect in reducing neurologic symptoms and increasing survival rates. The results of our study did not support these findings. The survival rate of untreated symptomatic animals at 24 hr was six (55%) of 11, whereas for animals treated with 5 mg/kg dexamethasone the survival rate was four (36%) of

11. The rate of survival thus decreased with dexamethasone administration. NMR images of steroid-treated animals were not significantly different from images of untreated symptomatic animals at any of the three imaging times.

In gerbils with neurologic deficits secondary to unilateral carotid artery ligation, NMR imaging appears to effectively reflect the cerebral ischemic insult in vivo. The ability of NMR to detect changes in the ischemic brain was evident at our earliest experimental imaging time, 3 hr after carotid occlusion. T_1 and especially T_2 relaxation times, as well as relative signal intensity between hemispheres, appear to increase over the first 24 hr after ischemic insult. These changes appear to reflect the development of postischemic cerebral edema. NMR images were unaffected by the pharmacologic agents tested, all of which have been reported to significantly affect the clinical course of cerebral ischemia. NMR imaging may prove to be an extremely valuable tool for the early detection of cerebral ischemia in man and its response to pharmacologic therapy in vivo.

REFERENCES

1. Wall SD, Brant-Zawadzki M, Jeffrey RB, Barnes B. High frequency CT findings within 24 hours after cerebral infarction. *AJNR* **1981**;2:553-557, *AJR* **1982**;138:307-311
2. Kawase T, Mizukami M, Araki G. Mechanisms of contrast enhancement in cerebral infarction: computerized tomography, regional cerebral blood flow, fluorescein angiography, and pathological study. *Adv Neurol* **1981**;30:149-158
3. Drayer BP, Dujovny M, Boehnke M, et al. The capacity for computed tomography diagnosis of cerebral infarction. *Radiology* **1977**;125:393-402
4. Inoue Y, Takemoto K, Miyamoto T, et al. Sequential computed tomography scans in acute cerebral infarction. *Radiology* **1980**;135:655-662
5. Crooks L, Hoenninger J, Arakawa M, et al. Tomography of hydrogen with nuclear magnetic resonance. *Radiology* **1980**;136:701-706
6. Kaufman L, Crooks L, Margulis AR, eds. *Nuclear magnetic resonance imaging in medicine*. New York: Igaku-Shoin, **1981**
7. Plum F, Posner JB, Alvord EC. Edema and necrosis in experimental cerebral infarction. *Arch Neurol* **1963**;9:563-570
8. O'Brien MD. Ischemic cerebral edema: a review. *Stroke* **1979**;10:623-628
9. Katzman R, Clasen CR, Klatzo I, et al. Brain edema in stroke: report of Joint Committee for Stroke Resources. *Stroke* **1977**;8:512-538
10. Buonanno FS, Pykett IL, Kistler JP, et al. Cranial anatomy and detection of ischemic stroke in the cat by nuclear magnetic resonance imaging. *Radiology* **1982**;143:187-193
11. Yanagihara T. Experimental stroke in gerbils: correlation of clinical, pathological and electroencephalographic findings and protein synthesis. *Stroke* **1978**;9:155-159
12. Hosobuchi Y, Baskin DS, Woo SK. Reversal of induced ischemic neurologic deficit in gerbils by the opiate antagonist naloxone. *Science* **1982**;215:69-71
13. Kahn K. The natural course of experimental cerebral infarction in the gerbil. *Neurology (NY)* **1972**;22:510-516
14. Harrison MJG, Russel RWR. Effect of dexamethasone on experimental cerebral infarction in the gerbil. *J Neurol Neurosurg Psychiatry* **1972**;35:520-521
15. Harrison MJG, Brownbill D, Lewis PD, Russell RWR. Cerebral edema following carotid artery ligation in the gerbil. *Arch Neurol* **1973**;28:389-391
16. Crooks L, Arakawa M, Hoenninger J, et al. Nuclear magnetic resonance whole-body imager operating at 3.5k Gauss. *Radiology* **1982**;143:169-174
17. Hoppe WE, Waltz AG, Jordan MM, Jacobson RL. Effects of dexamethasone on distributions of water and pertechnetate in brains of cats after middle cerebral artery occlusion. *Stroke* **1974**;5:617-622
18. Schuier FJ, Hossmann KA. Experimental brain infarcts in cats. II: ischemic brain edema. *Stroke* **1980**;11:593-602
19. Baskin DS, Hosobuchi Y. Naloxone reversal of ischaemic neurological deficits in man. *Lancet* **1981**;2:272-275
20. Baskin DS, Kieck CF, Hosobuchi Y. Naloxone reversal of ischemic neurological deficits in baboons is not mediated by systemic effects. *Life Sci* **1982**;31:2201-2204
21. Levy RM, Feustel P, Severinghaus J, Hosobuchi Y. Effect of naloxone on neurologic deficit and cortical blood flow during focal cerebral ischemia in cats. *Life Sci* **1982**;31:2205-2208
22. Levy R, Feustel P, Severinghaus J, Hosobuchi Y. Focal cerebral ischemia in the cat: effect of naloxone on cortical blood flow and neurological deficit following middle cerebral artery occlusion. *J Cerebral Blood Flow Metab* (in press)