

Stereotaxic Laser Ablation of Intracranial Lesions

George Alker,¹ Patrick J. Kelly,² Bruce Kall,³ and Stephan Goerss⁴

A technique is described which combines computed tomography-based stereotaxic localization and CO₂ laser ablation of certain intracranial lesions with a high degree of accuracy. In 24 patients operated on with this technique, total ablation of the lesion was achieved in 19 and incomplete ablation in the other five. Though not perfect, this method is a new approach to intracranial lesions that promises to be more efficacious as future developments occur.

The neuroradiologist and neurosurgeon work as a team. The aim of the neuroradiologist is to diagnose intracranial lesions early with the greatest possible precision; that of the neurosurgeon to ablate them with minimum damage to normal brain. We developed a technique at the State University of New York at Buffalo that we believe allows us to achieve these goals as completely as currently available technology permits. Though far from perfect, it represents a new approach to the treatment of certain intracranial lesions, and we believe it will be used more extensively in the future.

Materials and Methods

The lesion is first localized with the aid of a computed tomography (CT)-based stereotaxic system [1-4]. Our method was initially developed using the Pfizer 0200FS scanner available at one of our hospitals, and subsequently adapted to use with the GE-8800 scanner at another hospital. A Todd-Wells stereotaxic frame was modified for this purpose (fig. 1) by replacing its metallic vertical supports with molybdenum disulfide and carbon fiber pins to reduce undesirable artifacts on the scan. The pins are used to attach the frame to the skull. Three sets of carbon fiber rods are used, one anteriorly, the others on each side of the head arranged in an N shape similar to systems used by Rhodes et al. [5], Brown [6], and Perry et al. [7]. An adapter was constructed for the base ring of the Todd-Wells stereotaxic frame that allows it to be attached to the headrest of the Pfizer and GE scanners.

A set of axial CT scans is obtained using high-volume contrast enhancement for maximum visualization of the lesion. Five mm contiguous slices are obtained on the GE scanner and 8 mm slices at 5 mm increments on the Pfizer 0200 unit.

The patient is then transferred to the operating room. The computer tape containing the CT data goes to a GE independent physicians' display console in the operating suite. Localization of the lesion in the x and y coordinates is provided by the normal

operating program of the CT scanner as well as by the program developed for the stereotaxic localizer. Localization in the third dimension, the z axis (that is, the height of a given point relative to the base of the skull), is accomplished with the use of the carbon fiber filaments which produce nine easily identifiable marks on the scan (fig. 2). These marks are automatically digitized by the stereotaxic program and used in calculating the location of the plane of the section. The lesion is thus identified in all three dimensions. On the basis of measurements using phantoms, the accuracy of our system has been determined to be within 1 mm in the x and y axes and always within the slice along the z axis.

The physician then digitizes the outline of the lesion on each slice. The computer, using this data, constructs 1 mm contiguous slices and generates a three-dimensional image of the lesion which is displayed on the screen of the independent viewing console. It may then be rotated to any angle desired.

The patient is placed on the operating table with his head still in




Fig. 1.—Modified Todd-Wells stereotaxic frame. All components between base ring and rectangular metal plate near vertex are nonmetallic, allowing scanning of entire head without artifacts caused by metallic components. Adaptation of base ring allows frame to fit on headrest of CT scanner.

¹Department of Radiology, State University of New York at Buffalo, School of Medicine, Buffalo, NY 14215. Address reprint requests to G. Alker, Department of Radiology, Erie County Medical Center, 462 Grider Street, Buffalo, NY 14215.

²Department of Neurosurgery, State University of New York at Buffalo, School of Medicine, Buffalo, NY 14215.

³Research Computer Programmer, Sisters of Charity Hospital, Buffalo, NY 14214.

⁴Laboratory Technician, Sisters of Charity Hospital, Buffalo, NY 14214.

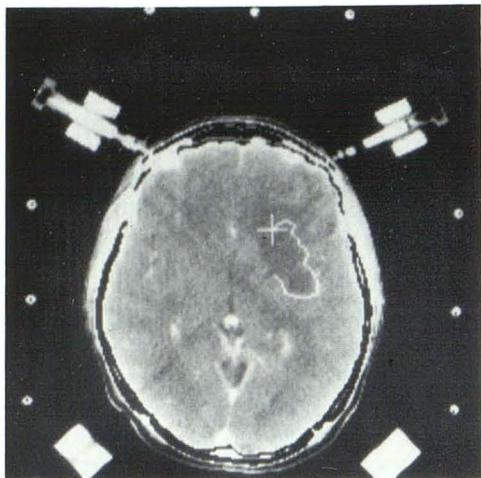


Fig. 2.—Axial section through a left frontal lesion. Note nine high-density marks made by localizing rods. Image of lesion is digitized by identifying its margins.

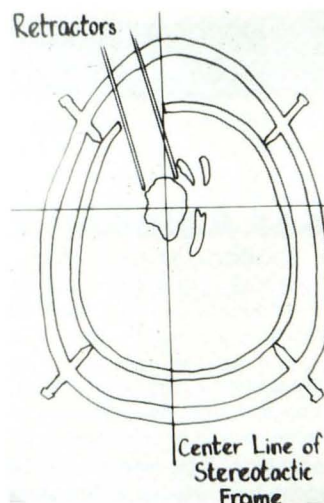


Fig. 4.—Shaftlike access is provided for neurosurgeon to direct laser at lesion.

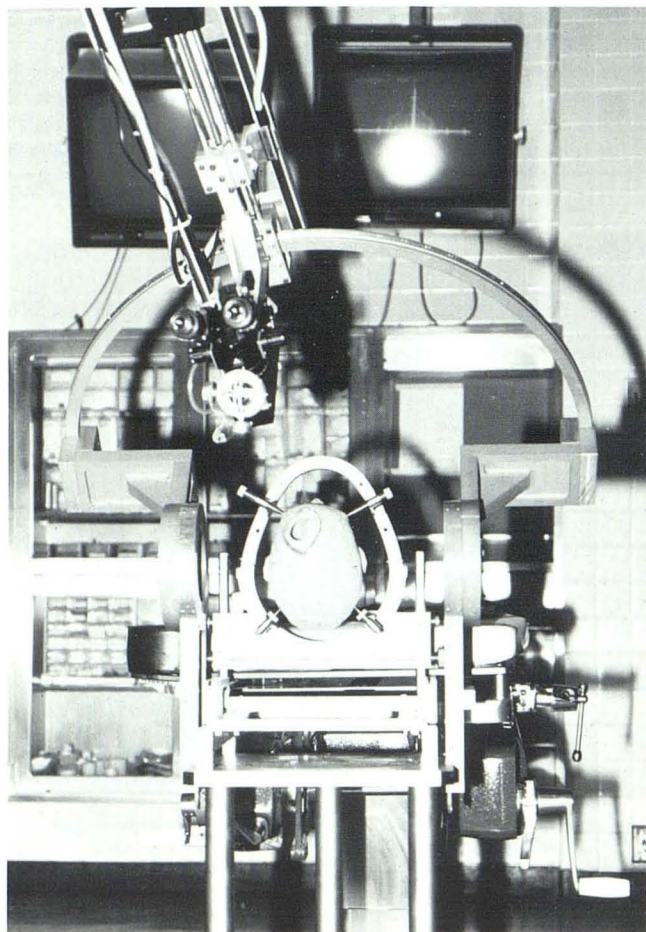


Fig. 3.—Operating neurosurgeon's view. Patient's head is fixed in base ring of stereotaxic frame. Operating microscope is positioned over patient's head. Surgeon is able to view reconstructed image of lesion on television monitor suspended from ceiling above operating table.

the stereotaxic frame (fig. 3). Controls of the frame interface with the computer, which allows precise adjustment of the frame so that the center of the tumor lies in the geometric center of the stereotaxic frame. A craniotomy is performed under general anesthesia and the lesion approached through relatively nonessential brain tissue using a CO₂ laser and operating microscope. The controls of the laser and of the microscope interfaced with the computer allow precise positioning relative to the lesion. When the surface of the lesion is reached it is undercut on each side and a self-retaining retractor is placed, providing a shaftlike access through the craniotomy (fig. 4), the diameter of which corresponds to the maximum diameter of the tumor.

The lesion is then vaporized slice by slice, using 65–80 W of defocused laser power progressing from the most superficial to the deepest layer. The laser is coupled to the computer so that at all times the position of its beam can be monitored on the display screen of the computer and its movement controlled very precisely by the use of a "joy stick." This allows extremely precise destruction of abnormal tissue, with thermal damage limited to within 300 μ m of the laser beam.

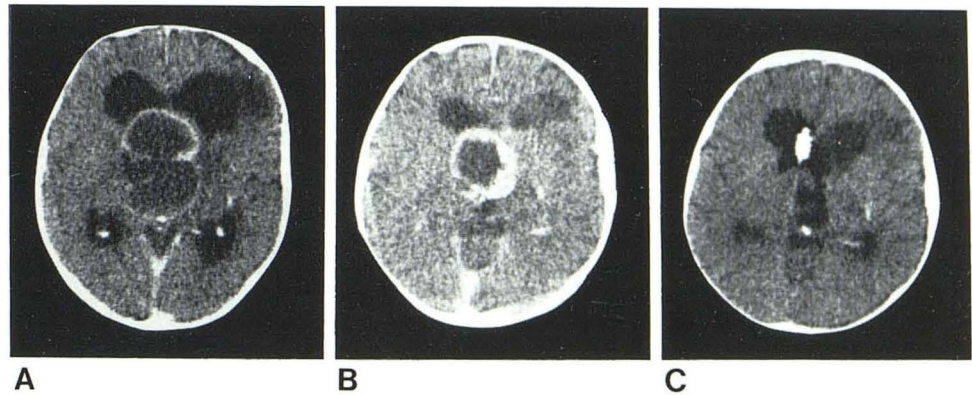
To date, 24 patients have been operated on using this technique. Twenty-three of the lesions were intracranial neoplasms, and the other a deep-seated arteriovenous malformation [8]. Three of the lesions were within the third ventricle, six in the thalamus, four in the basal ganglia, two in the corpus callosum, three in the parietal lobe, four in the frontal lobe, and two in the temporal lobe.

Histologically, there have been 11 glioblastomas, five metastatic tumors, three astrocytomas, one meningioma, one ganglioglioma, one teratoma, and one cavernous hemangioma. One patient had an arteriovenous malformation in the left parietal lobe below the surface.

Results

There was no intraoperative mortality in this series of patients. The neurologic assessment 1 week after surgery showed 11 patients improved, five patients deteriorated, and seven patients unchanged compared with their preoperative state.

Fig. 5.—26-year-old man with glioma of third ventricle. **A**, Preoperative CT scan. **B**, 6 months after incomplete removal of tumor, in preparation for second laser procedure. **C**, 1 month after second laser procedure, in which all but a small tumor nodule was removed.



Postoperative CT within a few days of surgery showed no demonstrable lesion in 19 patients and some residual glioblastoma in five (fig. 5). The arteriovenous malformation was no longer seen.

Eight of the 11 patients with glioblastoma on whom at least 3 months of follow-up is available showed recurrence 3–11 months after surgery. The recurrence was always in the area that appeared to be low-density edema surrounding the lesion on the preoperative CT scan. One patient with grade III astrocytoma of the frontal lobe and adjacent corpus callosum is free of demonstrable disease 2 years after surgery (fig. 6).

No patient with metastatic tumor or meningioma has shown focal recurrence in the operative site thus far (fig. 7). Two patients with metastatic tumors, however, developed metastases elsewhere and died.

Discussion

We believe that the system described in this paper offers significant advantages over the conventional surgical approach to intracranial lesions. In the conventional surgical technique three-dimen-

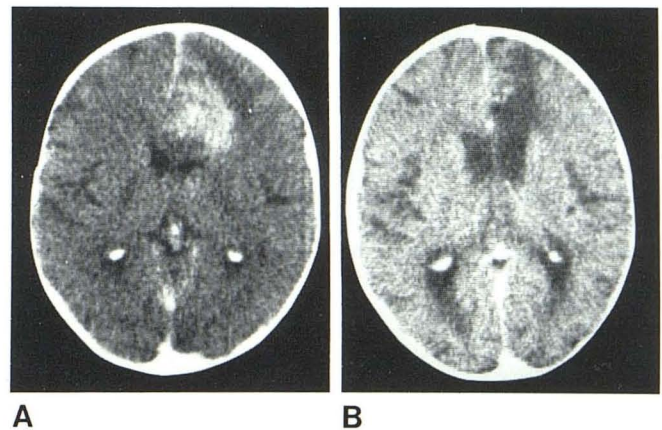
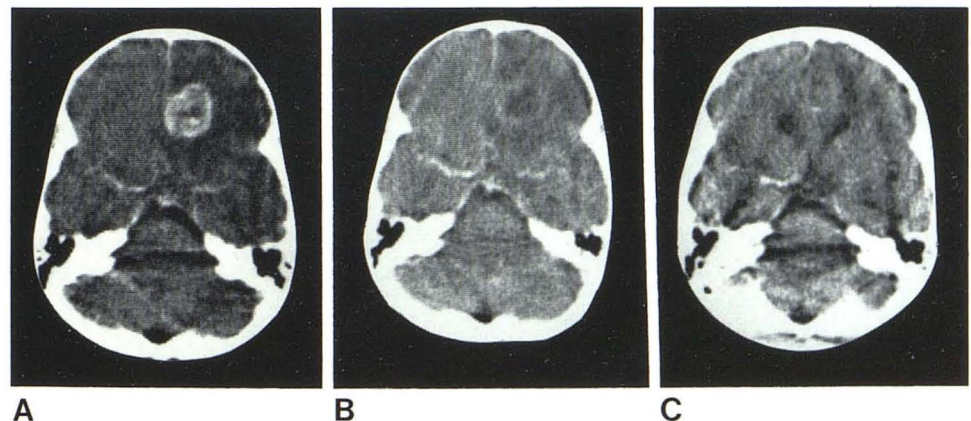


Fig. 6.—Grade III astrocytoma of right posterior frontal area infiltrating corpus callosum. **A**, Preoperative scan. **B**, 6 months after laser ablation. No residual tumor. This patient had no evidence of recurrence 2 years after initial laser surgery.

Fig. 7.—Metastatic adenocarcinoma in right frontal lobe. **A**, Preoperative scan. **B**, Residual cavity 1 week after laser ablation of tumor. **C**, Follow-up after 1 year. No evidence of residual or recurrent tumor. This patient subsequently died of metastatic tumor elsewhere.



sional orientation is often difficult when the surgeon approaches a deep-seated lesion within the brain. Our technique allows precise, three-dimensional orientation of the lesion within the landmarks of the stereotaxic frame at all times. Differentiation of tumor from

edema and from surrounding normal brain is often difficult when the surgeon relies on visual inspection of the lesion in the operating room. In our system, the surgeon ablates a predetermined volume of tissue based on the preoperative CT scan.

The high recurrence rate in the case of primary parenchymal neoplasms is apparently due to our inability to visualize (even with good quality CT scans) the full extent of the lesion as it infiltrates the surrounding normal brain. This remains a significant obstacle to complete ablation of the tumor. We hope that with improved and new CT techniques (especially with nuclear magnetic resonance imaging) this can be overcome in the future.

REFERENCES

1. Goerss S, Kelly PJ, Kall B. A simple CT stereotactic adaptation system. *Neurosurgery* **1982**;10:375-379
2. Kelly PJ, Alker GJ, Goerss S. Computer assisted stereotactic laser microsurgery for the treatment of intracranial neoplasms. *Neurosurgery* **1982**;10:324-331
3. Kelly PJ, Alker GJ. A method for stereotactic laser microsurgery in the treatment of deep-seated CNS neoplasms. *Appl Neurophysiol* **1980**;43:210-215
4. Kelly PJ, Alker GJ. A stereotactic approach to deep-seated central nervous system neoplasms using the carbon dioxide laser. *Surg Neurol* **1981**;15:331-334
5. Rhodes ML, Glenn WV, Azzawi YM, Slater R. Stereotactic neurosurgery using 3-D image data from computed tomography. *J Med Syst* **1982**;6:105-119
6. Brown RA. A computerized tomography-computer graphics approach to stereotaxic localization. *J Neurosurg* **1979**;50:715-720
7. Perry JH, Rosenbaum AE, Lunsford D, Swink CA, Zorub DS. Computed tomography-guided stereotactic surgery: conception and development of a new stereotactic methodology. *Neurosurgery* **1980**;7:376-381
8. Kelly PJ, Alker GJ, Zöll JG. A microstereotactic approach to deep-seated arteriovenous malformations. *Surg Neurol* **1982**;17:260-262