

# Dynamic CT in Patients with Superficial Temporal–Middle Cerebral Artery Anastomosis

Nobuaki Takahashi,<sup>1,2</sup> Haruhiko Kikuchi,<sup>1</sup> and Jun Karasawa<sup>1</sup>

Using dynamic computed tomographic (CT) scanning and an iodinated contrast material, changes in cerebral hemodynamics in cerebrovascular occlusive disease were studied before and after anastomosis of the superficial temporal artery and the middle cerebral artery. Because the iodinated contrast material is a nondiffusible indicator, it does not pass through the blood-brain barrier. Thus, this method is capable of measuring the relative tissue blood flow (intravascular blood flow) but incapable of measuring the absolute cerebral blood flow. However, it does allow the three-dimensional measurement of cerebral hemodynamics by a simple procedure, and when the primarily clear brain structure seen with CT is considered, it is a very useful diagnostic method.

Superficial temporal artery—middle cerebral artery (STA–MCA) anastomosis is a frequent surgical approach to cerebrovascular occlusive disease. The development of rapid-sequence computed

tomographic (CT) scanning has made possible the morphologic examination of the brain structure, and has opened up new methods for investigation of cerebral hemodynamics [1–5]. We studied sequential changes in cerebral hemodynamics by means of dynamic CT scanning in patients with cerebrovascular occlusive disease who had undergone STA–MCA anastomosis, in an effort to determine more accurately the effects of this procedure on cerebral hemodynamics.

## Subjects and Methods

Ten patients with chronic end-stage cerebrovascular occlusive disease but without disruption of blood-brain barrier or brain edema were selected as subjects. Seven of them had arteriosclerotic lesions and three had adult moyamoya disease. Of the seven with arteriosclerotic lesions, four had bilateral lesions and three of the four were operated on bilaterally.

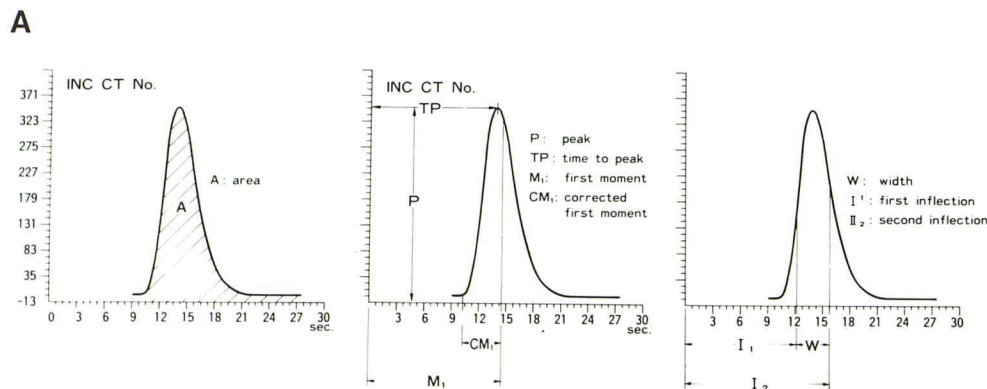
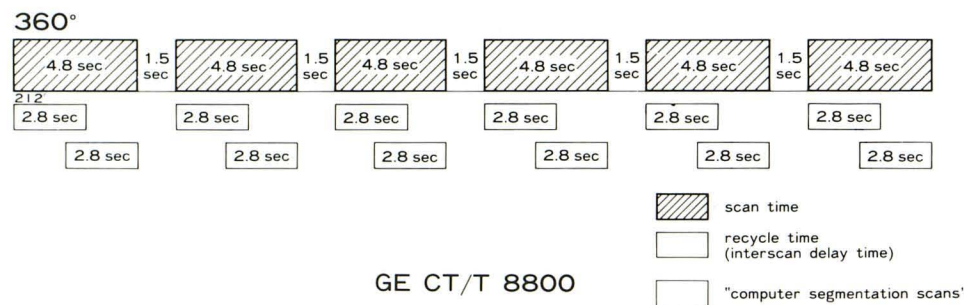


Fig. 1.—Rapid sequential research scan (A) and dilution curve (B). Area A = integrated amount of increased CT number, or total blood volume;  $M_1$ , graphically, center of gravity of curve is equal to vascular volume divided by flow, or mean transit time;  $CM_1$ , arrival time is subtracted from mean transit time through capillaries or tissue, or relative tissue perfusion; P, peak CT number for each pixel; TP, time to peak CT number for each pixel; and W, duration of effective perfusion, obtained by first differentiating dilution curve and subtracting time to maximum blood inflow rate from time to maximum blood outflow rate.

<sup>1</sup> Department of Neurosurgery, National Cardio-Vascular Center, Suita, Japan.

<sup>2</sup> Department of Neurosurgery, Seikeikai Hospital, Sakai, Japan. Address reprint requests to N. Takahashi.



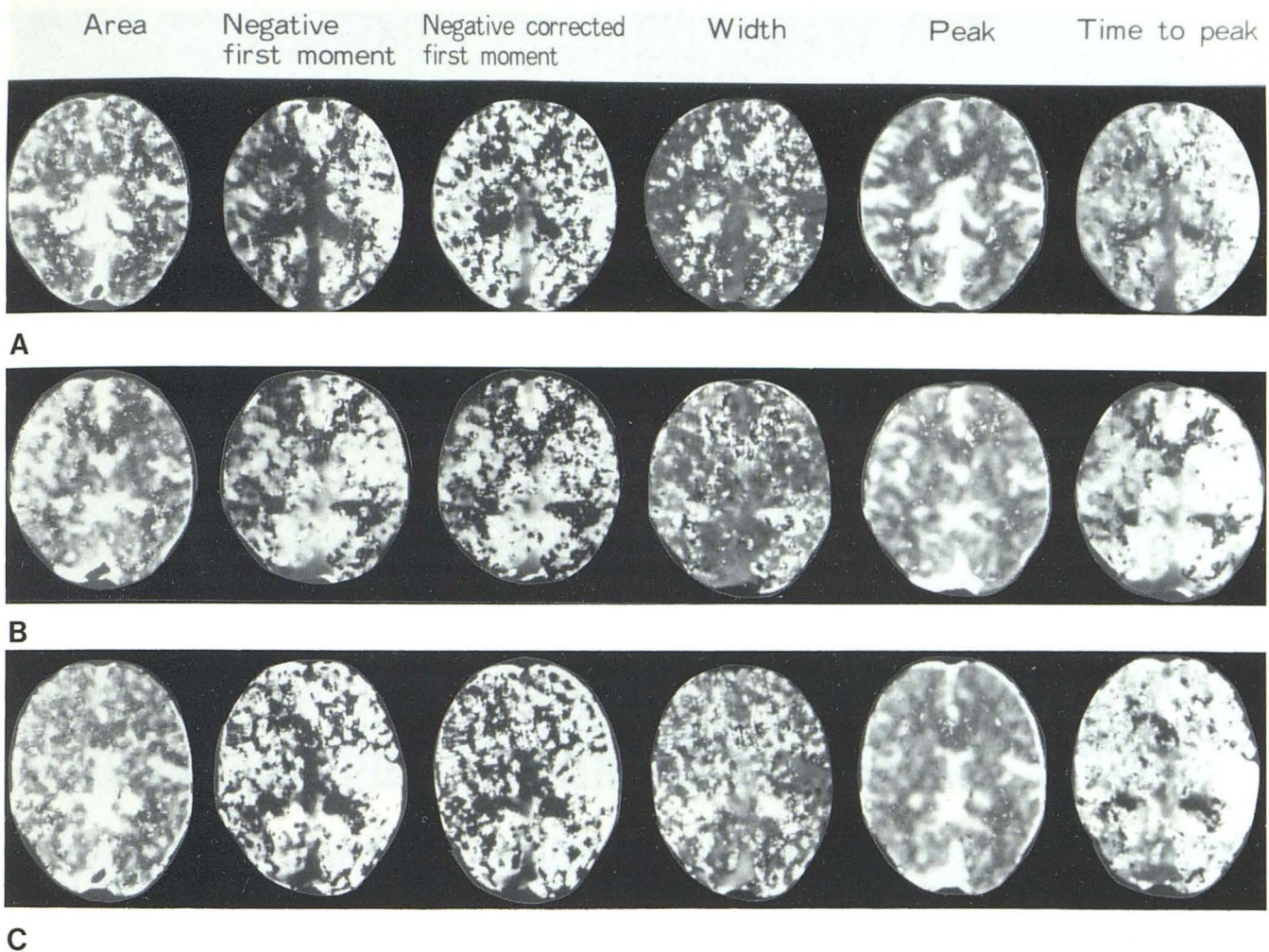


Fig. 2.—63-year-old man with mild hemiparetic manifestations. Angiogram showed occlusion of right internal carotid artery, with right MCA opacified via ophthalmic artery from external carotid artery, via posterior communicating artery, or retrogradely from posterior cerebral artery in vertebrobasilar system. Right STA-MCA anastomosis was performed 2 months after last ischemic attack. **A**, Plain CT before surgery. Low-density area in right frontal lobe. Practically no difference in A, negative  $CM_1$ , W, or P between hemispheres except in right frontal lobe, however, differences in negative  $M_1$  and

TP between hemispheres were striking (i.e., total blood volume was well maintained in right hemisphere through well developed collateral circulation). There was no difference in relative tissue perfusion between hemispheres, but route by which blood reached cerebral tissue was impaired. **B**, 1 month after surgery. Blood-brain barrier may still be disrupted, but there is less difference in either negative  $M_1$  or TP between hemispheres, and total blood volume is greater on right side. **C**, 3 months after operation. Differences further diminished, and time to arrival of blood at right hemisphere reduced.

Cerebral angiograms showed greatly varying locations of occlusion and stenosis and the development of many different collateral circulations. For these reasons, patients were not examined for cerebral angiographic changes, but for the presence or absence of infarction on plain CT and for changes in cerebral hemodynamics resulting from anastomosis. A GE CT/T 8800 scanner was used.

Each patient was given a bolus injection into the antecubital vein of 25 ml of amidotrizoate sodium meglumine (60% Urografin) warmed to 37°C at the rate of 7 ml/sec, using a Medrad Mark IV autoinjector. Scanning was begun at the same time.

To prepare the functional image (fig. 1), area (A), first moment ( $M_1$ ), corrected first moment ( $CM_1$ ), peak height (P), time to peak (TP), and width (W) were obtained from the dilution curve. To represent the blood flow of the middle cerebral artery, parenchymal first moment ( $PM_1$ ) (in the area with the sylvian fissure in the center) and arterial first moment ( $AM_1$ ) (of the arteries inside the sylvian fissure) were obtained by gamma variate fit technique. These pa-

rameters of the basal ganglia were also studied in the patients with adult moyamoya disease. Post-STA-MCA anastomosis examinations were generally performed 1 and 3 months after the operation.

## Results

The data obtained were first tested and proved to be reproducible.

The subjects included four patients in whom plain CT revealed no or a very small infarction (lacuna). The difference in  $AM_1$  between the side on which there were manifestations and the contralateral side was 1–1.5 sec in two patients, and less than 0.5 sec in the other two, while the difference was not less than 1.5 sec in all six patients with infarctions. The difference in  $PM_1$  between the side on which there were manifestations and the contralateral side was not more than 1.0 sec in the patients without infarction and those with very small infarctions, while there was a lag of 1.6–5.8 sec in the patients with infarction. The difference in  $CM_1$  between the right



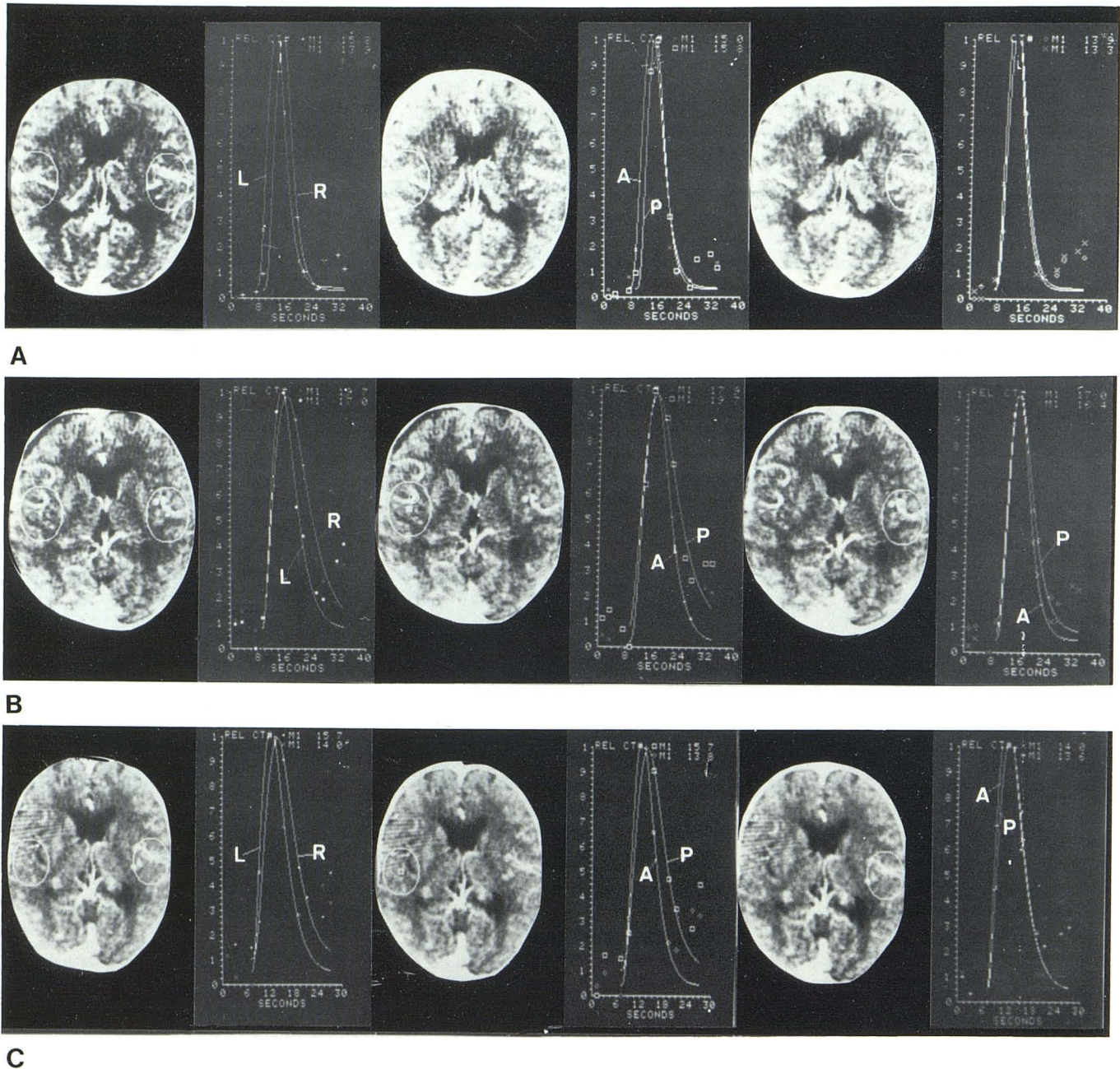


Fig. 3.—Difference in  $CM_1$  between hemispheres was practically unchanged postoperatively (as noted in fig. 1). Difference in  $AM_1$  between hemispheres did not change much during month after operation, while it reduced greatly 3 months after the operation. Readings (in sec) for A–C,

respectively, were: right  $PM_1$ —15.8, 19.7, and 15.7; left  $PM_1$ —13.9, 17.0, and 14.0; right  $AM_1$ —15.0, 17.9, and 13.8; and left  $AM_1$ —13.3, 16.4, and 13.6.

and left cerebral hemispheres was not more than 1.0 sec in all patients, except in the patient with a large infarction.

One month after STA–MCA anastomosis, the difference in  $AM_1$  between the right and the left cerebral hemispheres was reduced in all patients with arteriosclerotic cerebrovascular lesions. The differences in  $PM_1$  and in  $CM_1$  between the right and the left cerebral hemispheres were greater in the two patients with infarctions. No changes were noted in neurologic manifestations compared with the preoperative manifestations. Three months after the anastomosis, cerebral hemodynamics had improved in one of the two

patients who had demonstrated lags in tissue perfusion time 1 month after the anastomosis, but it had been aggravated by new bilateral lesions in one of the other patients.

One month after surgery on the patients with adult moyamoya disease,  $PM_1$  and  $CM_1$  were markedly reduced on the side where the anastomosis had been performed. The differences in these parameters between the ipsilateral and the contralateral side were greater, and the ipsilateral cortical hemodynamics were strikingly improved. The ipsilateral  $PM_1$  and  $CM_1$  of the basal ganglia were slightly prolonged. Typical cases are presented in figures 2 and 3.



## Discussion

Many reports have commented on the increase in cerebral blood flow not only on the side operated on but also on the contralateral side after STA-MCA anastomosis [6-9]. Morawetz et al. [8] observed a mean increase of 14% on the ipsilateral side and a mean increase of 8% on the contralateral. They suggested it was a reversal of the interhemispheric steal phenomenon. Laurent et al. [6] and Little et al. [7] demonstrated that the cerebral blood flow increased most after the operation in the areas where it had been lower preoperatively. CT scans revealed such changes clearly in some of our patients. However, Morawetz et al. [8] also reported cases where the cerebral blood flow did not greatly increase post-operatively, but in which CO<sub>2</sub> reactivity to hypocapnia was markedly improved. In other words, they found an increase in homeostatic cerebrovascular reserve or an improvement in cerebrovascular metabolic reserve, rather than an increase in the absolute volume of cerebral blood flow due to the STA-MCA anastomosis.

Xenon, which is used as an indicator in dynamic CT scanning, is a diffusible agent, while iodinated contrast material is nondiffusible, incapable of passing through the blood-brain barrier. For this reason, the method used in our study measures the relative intravascular blood flow, but is incapable of measuring the absolute blood flow; however, it does permit the easy three-dimensional measurement of changes in cerebral hemodynamics. When the primarily clear brain structure image obtained by CT scanning is considered, this method can be a very useful diagnostic tool.

But we must stress that this method is of poor reliability in patients with disruption of the blood-brain barrier, with the mean transit time prolonged. Furthermore, the intravenous bolus injection of the iodinated contrast material involves contraindication problems in patients with poor tolerance to contrast material, or in whom right heart contrast dilation occurs.

In this study, STA-MCA anastomosis was performed for cerebrovascular occlusive disease and the relative intravascular blood flow was measured with the passage of time, to obtain more accurate measurements of cerebral hemodynamics in such cases. As a result, it was found that the changes in the measured parameters correspond to the changes noted on the angiogram.

## REFERENCES

1. Drayer BP, Wolfson S Jr, Boehnke M, Dujovny M, Cook E, Rosenbaum AE. Xenon enhanced cranial computed tomography. Presented at the annual meeting of the American Society of Neuroradiology, New Orleans, February 1978
2. Heinz ER, Dubois P, Osborne D, Drayer B, Barrett W. Dynamic computed tomography study of the brain. *J Comput Assist Tomogr* 1978;3:641-649
3. Norman D, Berninger W, Boya D, Levin V, Newton T. Dynamic computed tomography. Presented at the annual meeting of the American Society of Neuroradiology, New Orleans, February, 1978
4. Norman D, Axel L, Berninger WH, Edwards MS, Cann CE, Redington RW, Cox L. Dynamic computed tomography of the brain. Techniques, data analysis and applications. *AJNR* 1981;2:1-12, *AJR* 1981;136:759-770
5. Traupe H, Heiss WP, Hoeffken W, Zülch KJ. Hyperperfusion and enhancement in dynamic computed tomography of ischemic stroke patients. *J Comput Assist Tomogr* 1979;3:627-632
6. Laurent J, Lawner P, O'Connor M, et al. Correction of intracerebral steal by extracranial/intracranial anastomosis. *Acta Neurol Scand [Suppl]* 1979;72:491-497
7. Little JR, Yamamoto YL, Feindel W, Meyer E, Hodge CP. Cerebral blood flow in superficial temporal artery to middle cerebral artery anastomosis. In: Peerless S, McCormick CW, eds. *Microsurgery for cerebral ischemia*. New York: Springer-Verlag, 1980:59-66
8. Morawetz RB, Halsey JH, Willis EL, Blauenstein UW, Wilson EM. The use of STA-MCA bypass in the evaluation of rCBF. In: Peerless S, McCormick CW, eds. New York: Springer-Verlag, 1980:47-55
9. Yamamoto YL, Little J, Thompson C, Meyer E, Feindel W. Positron tomography with krypton-77 for evaluation of topographical rCBF changes following EC-IC bypass surgery. *Acta Neurol Scand [Suppl]* 1979;72:522-523