

Intraoperative Sonography in the Nonstereotaxic Biopsy and Aspiration of Subcortical Brain Lesions

James E. Knake,¹ William F. Chandler,² Trygve O. Gabrielsen,¹ Joseph T. Latack,¹ and Stephen S. Gebarski¹

Deep-seated brain lesions, especially small ones, present a neurosurgical challenge to achieve tissue diagnosis with minimal damage to intervening normal brain. Needle biopsy is often indicated but has been a relatively arduous procedure using stereotaxic frame methods. Tissue sampling is greatly simplified by the use of intraoperative real-time sonography for needle guidance. The technique is also applicable to cyst or abscess drainage and ventricular decompression. Of 37 cases in which intraoperative brain sonography was used, 19 included sonographic guidance of a needle, probe, or wire-stiffened catheter into the lesion. Sonography is an easy and accurate substitute for stereotaxic guidance procedures. It is also useful for reexamination of the brain after interventions such as biopsy, resection, and drainage.

In a previous communication [1] we reported that portable real-time cranial sonography used intraoperatively had proven very successful in localizing brain lesions prior to biopsy and/or excision. The technique is especially valuable when the lesion is neither visible nor palpable at the time of craniotomy. In our growing series of cases, the usefulness of sonographic guidance for accurate passage of a brain probe or biopsy needle to relatively deep-seated lesions has become increasingly apparent. The current report emphasizes this simple nonstereotaxic technique and presents the results of its use in 19 cases.

Materials and Methods

The portable sonographic equipment, sterile transducer coverings, and general method of brain lesion localization have been detailed elsewhere [1-3]. Lacking a commercially available adapter for guidance of brain needles and probes, we designed and constructed our own such adapter (fig. 1) [1] to fit the standard transducer of our Mark III sonographic unit (Advanced Technology Labs., Bellevue, WA). More recently, we have used a Neurosector scanner made by the same company specifically for portable neurosurgical sonography; a clamp-on instrument guide is currently being produced commercially for that unit. With any transducer/guide combination, the path the needle will follow can be visualized on the television monitor by immersing the transducer face in sterile saline solution with the needle fully inserted in its guide channel. As long as the needle angle and the image magnification remain unchanged, the needle will follow the same path, which can be traced on the television screen with a wax pencil. When the transducer is returned to the brain surface and oriented with the

target lesion superimposed on this pathway, the needle will intercept the target.

Results

Of 37 cases in which intraoperative brain sonography has been used, 19 have included the sonographically guided passage of a brain needle, blunt probe, or wire-stiffened catheter. In 12 cases, tissue biopsy by needle was done, with tissue diagnoses of metastatic carcinoma (two cases), grades I-II astrocytoma (five cases), grades III-IV astrocytoma (three cases), ungraded astrocytoma (one case), and ganglioneuroma (one case). In another case of metastasis and in two cases of thrombosed arteriovenous malformation, a blunt probe was sonographically guided to the surface of the lesion to provide a tract for dissection, and the tissue sample was then taken under direct visualization. Three other cases involved sonographic guidance of a needle to decompress cystic components of a metastasis, a grade I astrocytoma, and an abscess. In the remaining case, a wire-stiffened shunt catheter was guided to the partially obstructed lateral ventricles to decompress them before resection of an intraventricular giant cell astrocytoma in a patient with tuberous sclerosis.

In all 12 instances of needle biopsy with sonographic guidance and without exposure of the lesion by dissection, the tissue sample provided the final diagnosis. In 10 of these cases accurate pathologic diagnosis of the lesion was obtained by laboratory analysis while surgery was still in progress and was confirmed by postsurgical histology. In the other two cases the tissue sample revealed no definite abnormality, but the operation was concluded because sonography had clearly demonstrated the appropriate biopsy site. In both cases the final histologic report was unequivocally positive for tumor.

Representative Case Reports

Case 1

A 34-year-old man had a 6-week history of paresthesias beginning in the right leg and progressing to involve the right arm and face. Cranial computed tomography (CT) (fig. 2A) revealed a 2.5 × 3 cm contrast-enhanced deep left paraventricular lesion with negligible edema and little mass effect for its size. Angiography was not considered necessary. The depth of the lesion within the dominant cerebral hemisphere dictated needle biopsy as the preferred method of tissue diagnosis. Transdural sonography through a left parietal craniotomy identified the hyperechoic mass (fig. 2B). An

¹ Department of Radiology, Box 13, University of Michigan Hospitals, Ann Arbor, MI 48109. Address reprint requests to J. E. Knake.

² Department of Surgery, University of Michigan Hospitals, Ann Arbor, MI 48109.

aspiration needle was advanced directly to the lesion in a single pass through a small dural incision. Pathologic diagnosis of a frozen section of the core sample was high-grade glioma. The needle tract and biopsy site were reexamined sonographically for evidence of hemorrhage (fig. 2C) and the craniotomy was closed. The patient had an uneventful recovery from surgery and was discharged from the hospital on postoperative day 3. The final pathologic diagnosis was grade III astrocytoma, and radiation therapy was scheduled.




Fig. 1.—Transducer with custom-made adapter for needle or cannula guidance. For surgical use, transducer and cable are covered with sterile glove and stockinette before adapter is attached.

Fig. 2.—Case 1: grade III astrocytoma. **A**, Preoperative contrast-enhanced axial CT. Deep-seated 2.5 × 3 cm mass is poorly accessible to dissection but amenable to needle biopsy. **B**, Intraoperative coronal sonogram before needle biopsy. Hyperechoic tumor (T) centered about 2.5 cm from cerebral midline. Choroid plexus in lateral and upper third ventricles produces bright echoes just inferior to falx (F). **C**, Coronal sonogram after needle biopsy. Needle tract (arrowheads) to tumor (T) is clearly shown. (F = falx.)

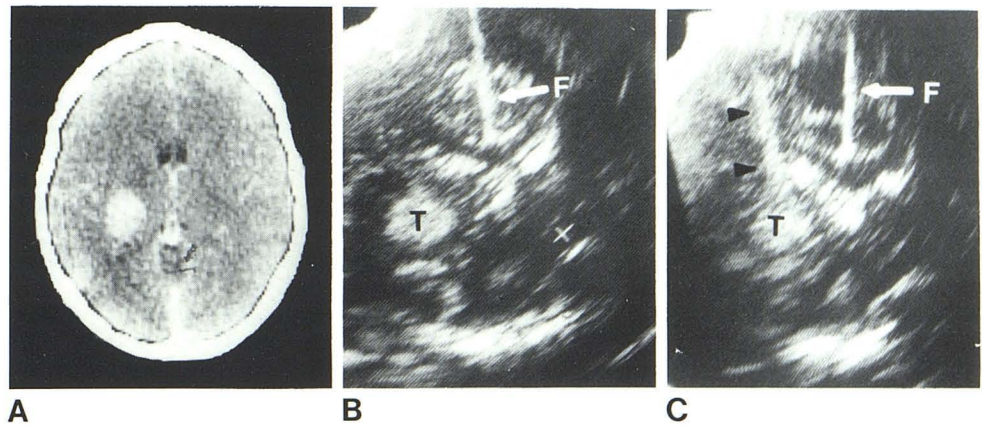
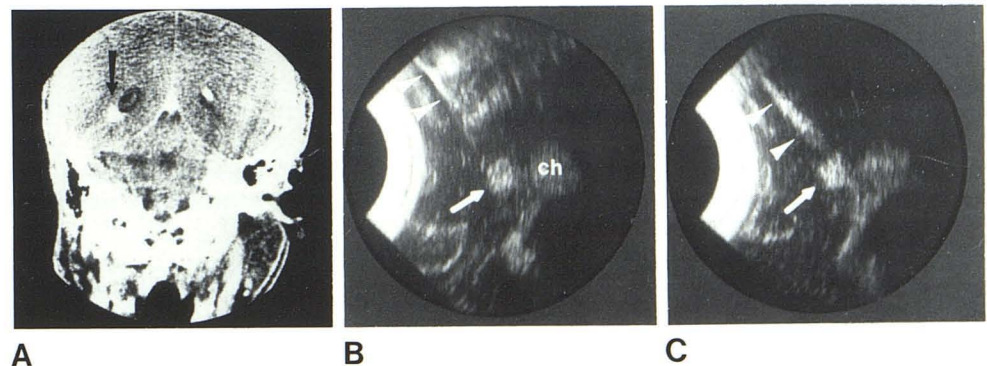


Fig. 3.—Case 2: thrombosed arteriovenous malformation. **A**, Preoperative contrast-enhanced coronal CT. Target tissue for biopsy (arrow) at inferolateral border of left ventricular atrium. **B**, Intraoperative coronal sonogram during passage of blunt cannula. Target tissue (arrow) is distinct from choroid plexus (ch) of atrium and temporal horn. Metal cannula (arrowheads) produces artifactual reverberations on far side from transducer but remains clearly visible during passage. **C**, Coronal sonogram after forceps biopsy demonstrates tract (arrowheads) produced by cannula and shows no apparent growth in lesion size (arrow) to indicate hemorrhage.



Case 2

A 32-year-old man presented with partial complex seizures. The neurological examination was normal. Cranial CT demonstrated a 10 × 12 mm area of faint calcification and moderate contrast enhancement at the inferolateral border of the atrium of the left lateral ventricle (fig. 3A). Although angiography showed no abnormal vascularity, vascular malformation was considered in the differential diagnosis and direct needle entry was judged inadvisable. At surgery, sonography through a left parietal craniotomy identified the uniformly hyperechoic lesion (fig. 3B). A blunt brain cannula was directed to the surface of the lesion in a single pass (fig. 3B), whereupon movement of the cannula could be seen to produce movement of the mass. After removal of the cannula, its tract was gently expanded to provide direct visualization of the purplish, rubbery tissue at the depth of the tract. Forceps biopsy of this tissue yielded a diagnosis of thrombosed arteriovenous malformation. Repeat sonography of the biopsy site and tract (fig. 3C) revealed no hemorrhage, and the craniotomy was closed. The patient had an uneventful recovery.

Discussion

The representative cases exemplify two of the most significant uses of the sonographic guidance technique: tissue sampling and accurate tract placement. Precise guidance of a needle or cannula is also useful for cyst decompression, cyst fluid sampling for cytology, abscess drainage, and ventricular decompression. We anticipate that sonographic guidance of instruments for the introduction of focal destructive lesions or for placement of therapeutic radio-pharmaceuticals would also be feasible. Methods requiring complex

stereotaxic frames and repeated CT scanning might thereby be avoided in these cases.

The immediacy of a real-time sonographic display also permits reexamination of needle tracts and biopsy sites to check for possible hemorrhage before closure of the craniotomy. Although we have encountered no major postbiopsy hemorrhage or other complication, reexamination by sonography did disclose a modest but definitely abnormal widening of the deep portion of a biopsy tract in one case, whereupon postoperative cranial CT confirmed the presence of a small hemorrhage at the biopsy site. Repeat sonography before craniotomy closure therefore appears to be strongly indicated.

Though appropriate needle-guidance adapters remain commercially unavailable for virtually all transducers in current use (with the single exception noted earlier), the construction of a relatively simple clamp-on device with a single needle channel should be

within the capability of any proficient machinist. Freehand needle guidance during sonographic observation can be accomplished, but the enhanced precision and simplicity offered by an adapter make its production a worthwhile undertaking.

REFERENCES

1. Knake JE, Chandler WF, McGillicuddy JE, Silver TM, Gabrielsen TO. Intraoperative sonography for brain tumor localization and ventricular shunt placement. *AJNR* **1982**;3:425-430
2. Chandler WF, Knake JE, McGillicuddy JE, Lillehei KO, Silver TM. Intraoperative use of real-time ultrasonography in neurosurgery. *J Neurosurg* **1982**;57:157-163
3. Knake JE, Silver TM, Chandler WF. Intraoperative cranial sonography for neurosurgical procedures. *Semin Ultrasound* **1982**;2:200-208