

Fenestrations of the Middle Cerebral Artery Associated with Aneurysms

T. Ueda,¹ T. Goya, S. Wakisaka, and K. Kinoshita

Fenestration of the vertebrobasilar artery is well known, but that of the middle cerebral artery (MCA) has been reported rarely [1-8]. We report two cases with fenestration of the MCA associated with cerebral aneurysm. The pathogenesis and clinical significance of fenestration of the MCA in relation to cerebral aneurysms is discussed.

present. Computed tomography (CT) demonstrated an intracerebral hematoma in the right temporal lobe, and right carotid angiography showed an aneurysm arising from the bifurcation of the right MCA and a fenestration at the origin of the same MCA (fig. 1). At surgery marked arteriosclerosis in the vicinity of the aneurysm was found. The aneurysm was clipped at its neck. The fenestrated artery at the origin of the MCA was not exposed surgically.

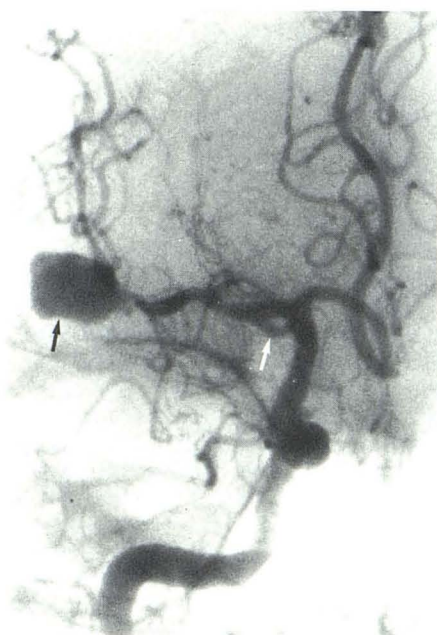

Fig. 1.—Case 1. Anteroposterior view of right carotid angiogram. Fenestration (*white arrow*). Aneurysm arising from bifurcation of MCA (*black arrow*).

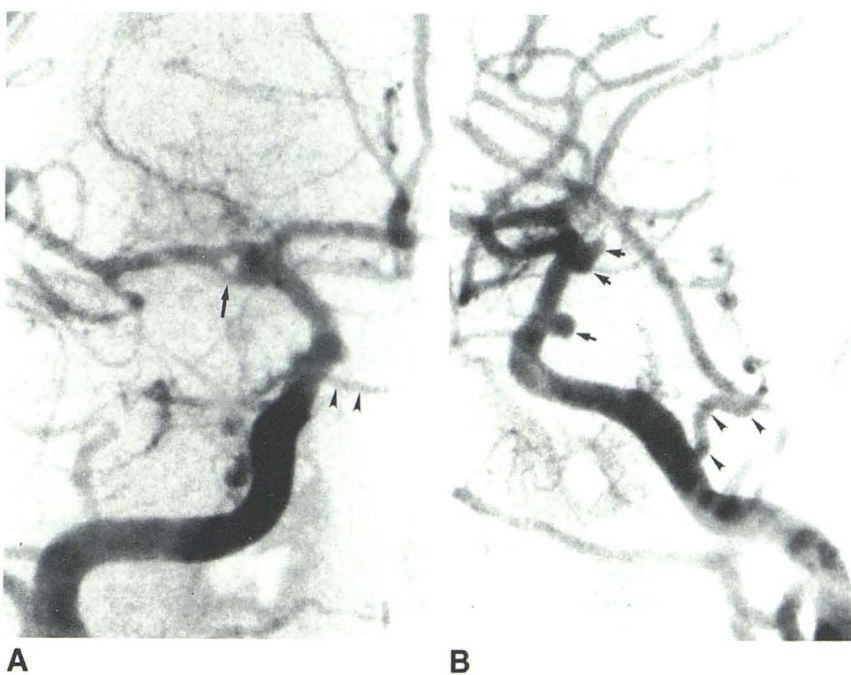


Fig. 2.—Case 2. **A**, Anteroposterior view of right carotid angiogram. Fenestration of MCA (*arrow*) and persistent primitive trigeminal artery (*arrowheads*). Aneurysm is also seen at origin of fenestrated MCA. **B**, Lateral view of right carotid angiogram. Persistent primitive trigeminal artery (*arrowheads*) and aneurysms at internal carotid and posterior communicating artery junction, terminal internal carotid artery, and origin of MCA (*arrows*).

Case Reports

Case 1

A 65-year-old man experienced a sudden, severe headache followed by left hemiparesis. On neurologic examination somnolence, nuchal rigidity, left spastic hemiparesis, and bilateral papilledema were

Case 2

A 45-year-old man had a subarachnoid hemorrhage. On admission bilateral papilledema with retinal hemorrhage and an abducens nerve paresis on the left were present. Cerebral angiography demonstrated a persistent primitive trigeminal artery and four cerebral aneurysms: on the left vertebral artery close to the origin of the posterior inferior

Received April 25, 1983; accepted after revision October 31, 1983.

¹All authors: Department of Neurosurgery, Miyazaki Medical College, Kiyotake, Miyazaki 889-16, Japan. Address reprint requests to T. Ueda.

cerebellar artery, on the left MCA, and on the right internal carotid artery. An aneurysm was also present in the axil of a fenestrated right MCA (fig. 2). CT demonstrated high-density areas in the basal cisterns, both sylvian fissures, and the cavum septi pellucidi and cavum vergae. All the aneurysms were successfully clipped or coated. The aneurysm on the right MCA had originated from the proximal end of the fenestration.

Discussion

Fenestration of the MCA has been rarely reported. The incidence is 0.28% at autopsy [1] and 0.26% on angiography [3]. To our knowledge, 13 such cases have been reported in the literature [1–8] with nine cases in the Japanese. Seven of the nine cases were male and two were female. Cerebral aneurysms were present in six of the 13 cases. In all cases the aneurysms arose in the ipsilateral artery at the fenestration or from the anterior communicating artery. In our case 1 the fenestration and aneurysm were in the same MCA.

Crompton [1] stated that aneurysms could occur at the proximal end of arterial fenestrations independent of any branches. Our case 2 appears to confirm this.

Embryologically a primitive vascular network is formed between the anterior cerebral artery and the MCA, and variations of the cerebral arteries such as fenestrations are explained by the persistence of embryologic transition branches and anastomoses [9]. Kwak et al. [4] considered that the association of fenestration and cerebral aneurysm is incidental. Other investigators [2, 5, 10] reported that fenestrations were apt to accompany cerebral aneurysms. In our case 2, four aneurysms were present in association with fenestration of the MCA and a persistent primitive trigeminal artery. We believe that the association of the middle cerebral

artery fenestrations and aneurysms is from concurrent congenital anomalies.

REFERENCES

1. Crompton MR. The pathology of ruptured middle cerebral aneurysms with special reference to the differences between the sexes. *Lancet* **1962**;2:421–425
2. Baba M, Shimizu T, Kagawa M, Kitamura K, Kobayashi N. A case of multiple anomalies of cerebral vessels—fenestration of the middle cerebral artery aneurysm of the anterior communicating artery and arteriovenous malformation on the frontopolar region. *No Shinkei Geka* **1977**;5:59–64
3. Ito J, Maeda H, Inoue K, Onishi Y. Fenestration of the middle cerebral artery. *Neuroradiology* **1977**;13:37–39
4. Kwak R, Kuwahara K, Niizuma H, Suzuki J. Anomalies of the middle cerebral artery with intracranial saccular aneurysms—duplication and fenestration. *No Shinkei Geka* **1979**;7:691–696
5. Miyazaki Y, Tsuruta J. Clinical studies on the congenital anomalies of the intracranial arteries associated with cerebral aneurysm. *Hokkaido Igaku Zasshi* **1977**;51:111–123
6. Padget DH. The circle of Willis: its embryology and anatomy. In: Dandy WE, ed. *Intracranial arterial aneurysms*. New York: Hafner, **1969**:67–90
7. Teal JS, Rumbaugh CL, Bergeron RT, Segall HD. Angiographic demonstration of fenestrations of the intradural intracranial arteries. *Radiology* **1973**;106:123–126
8. Wollschlaeger G, Wollschlaeger PB, Lucas FV, Lopez VG. Experience and result with postmortem cerebral angiography performed as routine procedure of the autopsy. *AJR* **1967**;101:68–87
9. Padget DH. The development of the cranial arteries in the human embryo. In: *Contributions to embryology*. Washington, DC: Carnegie Institute, **1980**;212:205–261
10. Nakajima K, Ito Z, Hen R, Uemura K, Matsuoka S. Congenital anomalies of cerebral artery and intracranial aneurysms. *No To Shinkei* **1976**;28:197–201