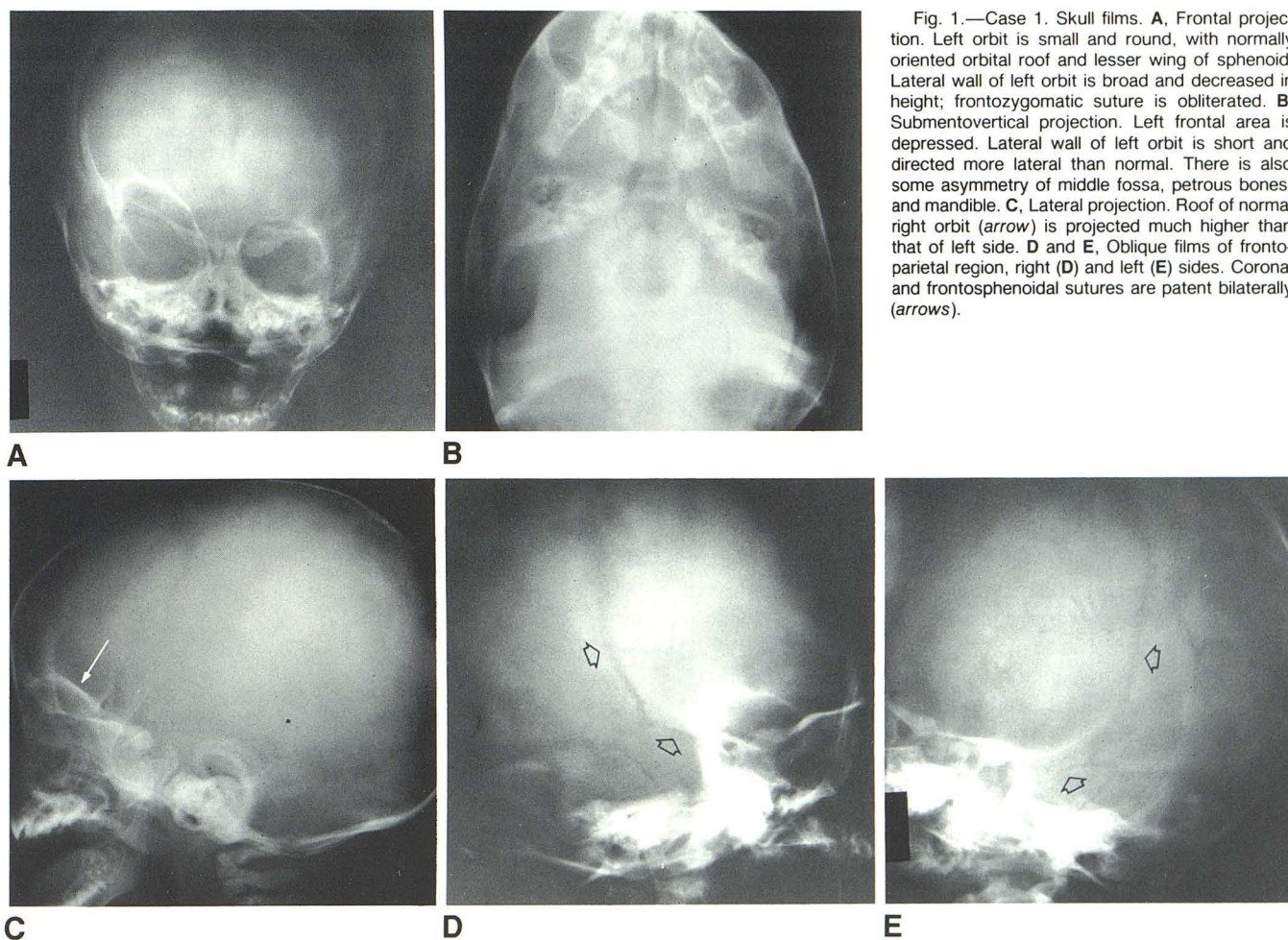


## Premature Closure of the Frontozygomatic Suture: Unusual Frontoorbital Dysplasia Mimicking Unilateral Coronal Synostosis

Guido Currarino<sup>1</sup>

We observed two infants with an unusual craniofacial deformity similar clinically to unilateral coronal synostosis but with different radiographic features. The disorder probably

represents a special type of frontoorbital dysostosis and may be due, at least in part, to premature obliteration of the frontozygomatic suture.



Received February 13, 1984; accepted after revision June 13, 1984.

<sup>1</sup> Department of Radiology, University of Texas Southwestern Medical School, and Children's Medical Center, 1935 Amelia, Dallas, TX 75235.

AJNR 6:643-646, July/August 1985 0195-6108/85/0604-0643 \$00.00 © American Roentgen Ray Society



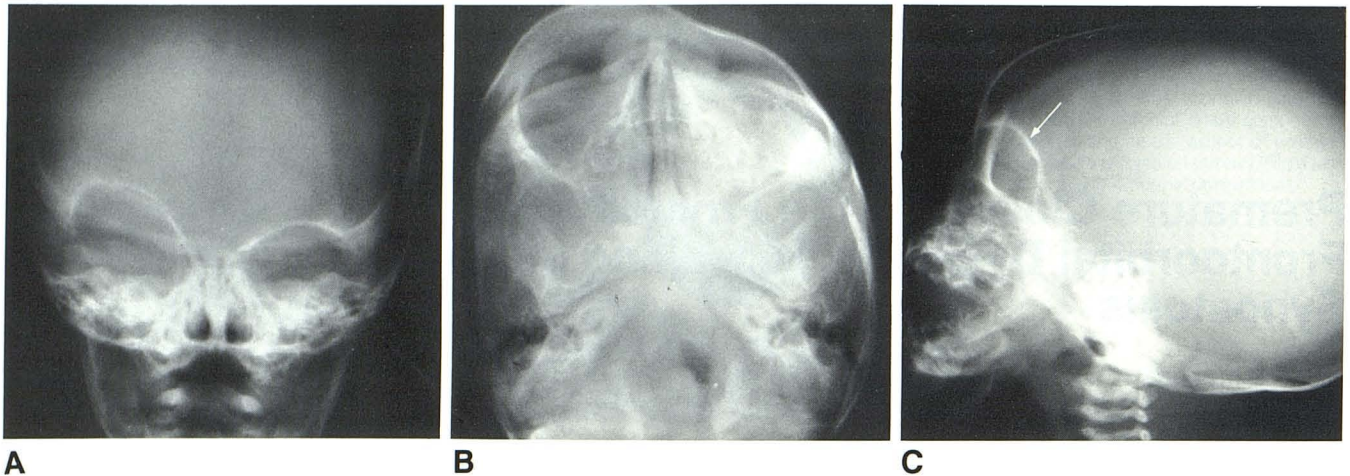


Fig. 2.—Case 2. Skull films. **A**, Frontal projection. Left orbit is small and round with normally oriented orbital roof and lesser wing of sphenoid. Lateral wall of left orbit is broad and decreased in height and frontozygomatic suture is obliterated. **B**, Submentovertical view. Left frontal area is markedly de-

pressed. Lateral wall of left orbit is short and directed more laterad than right. **C**, Lateral projection. Roof of normal right orbit (*arrow*) is projected much higher than that of left side. Coronal and frontosphenoidal sutures are patent (findings better seen in oblique views, not shown here).

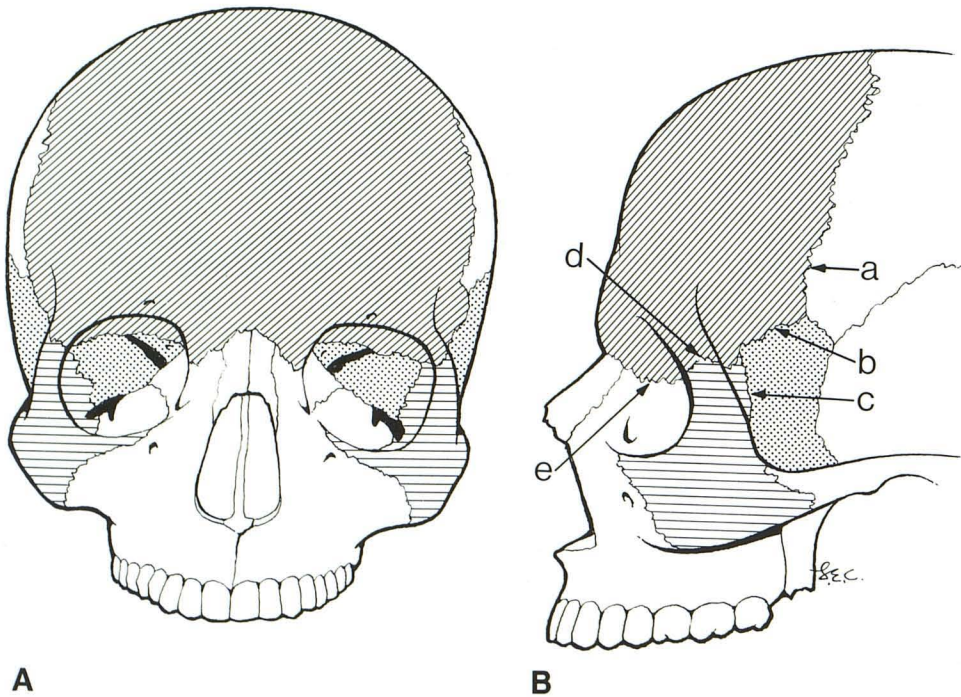


Fig. 3.—Frontal (**A**) and lateral (**B**) projections. Coronal sutures and other cranial sutures bordering on frontoorbital region: coronal (a), frontosphenoidal (b), zygomaticosphenoidal (c), frontozygomatic (d), and frontoethmoidal (e). Frontosphenoidal and zygomaticosphenoidal sutures are also seen through orbit in **A**. Major abnormality in deformity described in this article centers around frontozygomatic suture (d).

## Case Reports

### Case 1

A female infant was 9 months old at the time of her first skull films (fig. 1). She had been followed clinically since birth for Down syndrome, congenital heart disease (endocardial cushion canal with severe pulmonary hypertension), congenital hypothyroidism, and marked flattening and depression of the left frontal region.

### Case 2

A male infant was 1 month old at the time of the skull films shown in figure 2. He had been followed since birth because of flattening and depression of the left frontal area and progressive bulging of the

right side of the forehead. No other congenital abnormalities were recorded. An advancement of the left side of the frontal bone was carried out when the patient was 8 weeks old. At surgery, the coronal suture was found to be normal. The frontosphenoidal suture appeared narrowed near the zygomatic process of the frontal bone, and at this level the bone was found to be quite thick. The zygomaticosphenoidal suture appeared to be completely obliterated.

### Comparison of Radiographic Findings

The findings in the two patients were very similar. In the frontal projection (figs. 1A and 2A), the left orbit, on the side of the frontal flattening shown clinically, was small and round; its lateral wall was



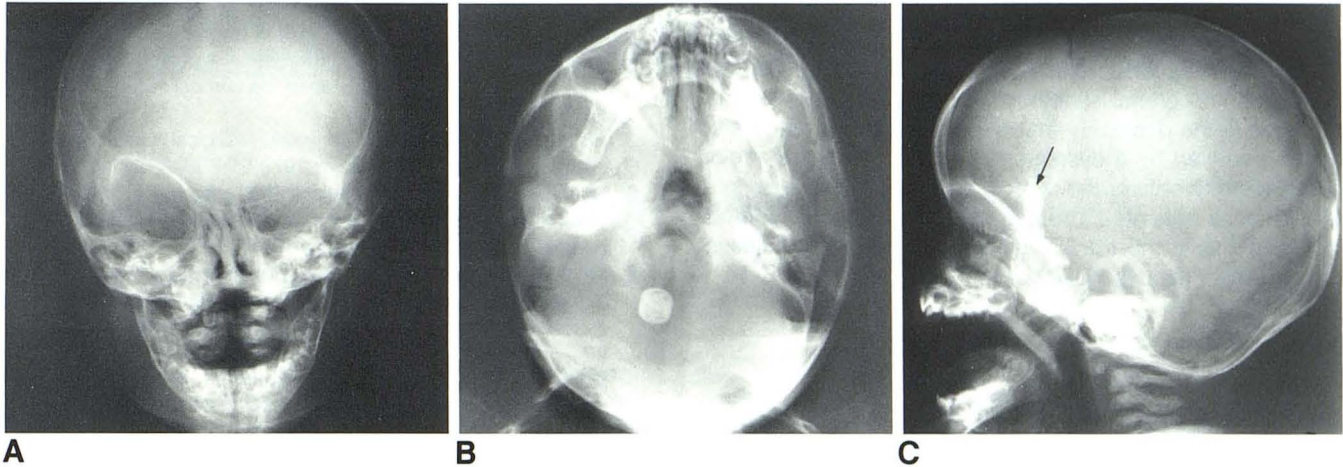


Fig. 4.—Skull films of typical case of unilateral coronal synostosis on right side. **A**, Frontal projection. Right orbit is enlarged, and orbital roof and lesser wing of sphenoid are elevated (harlequin orbit). **B**, Submentovertical projection. Right frontal area is depressed, right orbit is shallow, and right middle fossa is

enlarged and bulges laterally. There is asymmetry of petrous bones and mandible. **C**, Lateral projection. Posterolateral corner of right orbit is elevated (arrow). Right coronal and frontosphenoidal sutures are obliterated (findings best seen on oblique views, not shown here).

short and broad without a frontozygomatic suture; and the lesser wing of the sphenoid bone was normally oriented. On the opposite side, the orbit was slightly elliptic with mild elevation of the lesser wing of the sphenoid, and the cribriform plate was slightly oblique upward and toward the right, mimicking a right coronal synostosis. The petrous ridges were at the same level and there was no definite bulge of either temporal area.

The submentovertical view (figs. 1B and 2B) showed marked flattening of the left frontal area. The lateral wall of the left orbit was short and was directed forward and more laterad than the right, especially in case 1. Also in case 1, the left middle cranial fossa was smaller and more posteriorly placed than the right. In the lateral view (figs. 1C and 2C), the roof of the normal right orbit was projected much higher than that of the small left orbit. In the lateral and oblique (optic canal) views (figs. 1D and 1E), the coronal and frontosphenoidal sutures were patent bilaterally. These views also confirmed the obliteration of the frontozygomatic suture. The sutures at the cranial base could not be evaluated on any of the films. A drawing of the skull in the frontal and lateral projections indicating the various sutures bordering the frontal bone and orbits is shown for reference in figure 3.

## Discussion

### *Differentiation from Unilateral Coronal Synostosis*

Unilateral coronal synostosis and the anomaly described here are very similar clinically; the main features of both are a recessed brow and flattened forehead on one side with a prominent-appearing forehead on the opposite side. In unilateral coronal synostosis there may be also a slight exophthalmos on the affected side attributed to shallowness of the orbit. The radiographic findings of unilateral coronal synostosis are quite distinctive [1–4]. An illustrative example is shown in figure 4. The changes differ from those seen in the cases described in several respects: In unilateral coronal synostosis, the coronal suture on the side of the frontal flattening is obliterated, and the ipsilateral orbit is enlarged in the coronal

plane but diminished in depth. The roof of the orbit and the lesser wing of the sphenoid bone on the affected side are slanted upward and laterad, and the height of the lateral wall of this orbit is increased and the frontozygomatic suture is patent. By contrast, in the disorder we described, on the side of the flattened forehead the coronal suture is normal, the orbit is small and round, there is no elevation of the lesser wing of the sphenoid bone, the lateral wall of the orbit is broad and decreased in height, and the frontozygomatic suture is obliterated.

### *Mechanism of the Anatomic Changes*

The skull changes of unilateral coronal synostosis are generally attributed to a premature obliteration of the coronal suture and, as pointed out by Seeger and Gabrielsen [4], also of the frontosphenoidal suture. An associated premature closure of sutures at the cranial base, particularly the frontosphenoidal and frontoethmoidal, has also been postulated [1, 4–7]. As to the origin of the craniosynostosis, the suggestion has been made that the synostosis may be a secondary process resulting from a more basic malformation of the skull base, mediated by an alteration in the fibrous organization of the dura mater [5–9]. Some of the craniofacial deformities seen in unilateral coronal synostosis are undoubtedly due to the local effect of sutural synostosis, whereas others, involving a much wider area of the cranium and face, may result from a redirection of the growth vector forces of the growing brain, transmitted by the tensile fibers of the dura mater [8–11].

In the two cases reported here, the coronal suture was patent and normal in appearance so that an abnormality of this suture can be excluded as a primary cause for the deformity. A more likely theory, suggested by the findings, is that of a developmental abnormality of the frontozygomatic

suture and possibly also of the zygomaticosphenoidal suture and part of the frontosphenoidal suture (fig. 3). The presence of a more basic lesion at the base of the skull of the type postulated in coronal synostosis is not excluded. Also not excluded is the possibility that the two disorders are related and are caused by a dysgenesis of the frontoorbital region affecting preferentially the coronal-sphenoidal-ethmoidal system in some patients (unilateral coronal synostosis) and affecting primarily the frontozygomatic process and adjacent area in others (as described here).

#### REFERENCES

1. Carmel PW, Luken MG, Ascherl GF Jr. Craniosynostosis: computed tomographic evaluation of skull base and calvarial deformities and associated intracranial changes. *Neurosurgery* **1981**;9:366-372
2. Fauré C, Bonamy P, Rambert-Misset C. Les craniosténoses par fusion prématurée unilatérale de la suture coronale. *Ann Radiol (Paris)* **1967**;10:32-42
3. Nathan MH, Collins VP, Collins LC. Premature unilateral synostosis of the coronal suture. *AJR* **1961**;86:433-446
4. Seeger JR, Gabrielsen TO. Premature closure of the frontosphenoidal suture in synostosis of the coronal suture. *Radiology* **1971**;101:631-635
5. Hoffman HJ, Hendrick EB. Early neurosurgical repair in craniofacial dysmorphism. *J Neurosurg* **1979**;51:796-803
6. Hoffman HJ, Mohr G. Lateral canthal advancement of the supraorbital margin: a new corrective technique in the treatment of coronal synostosis. *J Neurosurg* **1976**;45:376-381
7. Mohr G, Hoffman HJ, Munro IR, Hendrick EB, Humphreys RP. Surgical management of unilateral and bilateral coronal craniosynostosis: 21 years of experience. *Neurosurgery* **1978**;2:83-92
8. Moss ML. The pathogenesis of premature cranial synostosis in man. *Acta Anat (Basel)* **1959**;37:351-370
9. Moss ML. Functional anatomy of cranial synostosis. *Childs Brain* **1975**;1:22-33
10. Marsh JL, Schwartz HG. The surgical correction of coronal and metopic craniosynostosis. *J Neurosurg* **1983**;59:245-251
11. Folz EL, Loeser JD. Craniosynostosis. *J Neurosurg* **1975**;43:48-57