

MR Measurement of Normal and Pathologic Brainstem Diameters

P. Ruben Koehler¹
 Victor M. Haughton¹
 David L. Daniels¹
 Alan L. Williams¹
 Zerrin Yetkin¹
 H. Cecil Charles²
 Deborah Shutts²

The dimensions of the brainstem were measured on magnetic resonance (MR) images to provide criteria for detecting brainstem enlargement. Twenty-eight normal adult subjects had MR imaging with sagittal partial-saturation and spin-echo sequences. Four patients with brainstem gliomas and three with cerebellar atrophy were also studied. Five measurements were made: (A) the distance between the interpeduncular fissure and the aqueduct, (B) the distance from the anterior surface of the cerebral peduncles to the aqueduct, (C) the distance between the anterior surface of the pons midway between the mesencephalon and medulla to the fourth ventricular floor, (D) the shortest anteroposterior diameter of the medulla at the pontomedullary junction, and (E) the shortest anteroposterior diameter of the medulla at the medullospinal junction. Pontine diameter could be measured more reproducibly and accurately than mesencephalic or medullary diameters. In four patients with glioma, one or more of the measured diameters were more than 2 SDs above the average in normal volunteers, and abnormally small measurements were found in the patients with atrophy.

The feasibility of linear measurements in magnetic resonance (MR) imaging has not been reported. Therefore, we studied the accuracy of linear measurements in MR and measured brainstem diameters in normal subjects and patients with brainstem tumors. The accuracy of distance measurements on an MR image is dependent on several factors including homogeneity of the fundamental magnetic field and shim system and linearity of the field gradients. If geometric measurements are anticipated, field linearity must be evaluated and the calibration factor calculated.

Materials and Methods

Calibration was performed with a phantom composed of a uniform grid, with known spacing so that nonlinearity would be evident on the phantom image and the calibration factor could be calculated from the image. A phantom consisting of a series of equally spaced tubes 40 mm in diameter was imaged in prototype G.E. 0.5, 1.0, and 1.5 T superconducting magnets, and the image distances between the elements were measured with electronic calipers. The ratio between the number of pixels across a diameter and the true diameter was calculated.

Twenty-eight normal adult volunteers were examined in prototype General Electric MR scanners with 0.5, 1.0, 1.4, or 1.5 T superconductive magnets. Partial-saturation (PS) images with 250–400 msec repetition times (TRs) and 9 or 10 mm slice thickness were obtained in the sagittal plane. Five measurements were made: (A) the distance between the interpeduncular fissure and the aqueduct, (B) the distance from the anterior surface of the cerebral peduncles to the aqueduct, (C) the distance between the anterior surface of the pons midway between the mesencephalon and medulla to the fourth ventricular floor, (D) the shortest anteroposterior diameter of the medulla at the pontomedullary junction, and (E) the shortest anteroposterior diameter of the medulla at the medullospinal junction. The measurements were made on the computer screen with an electronic caliper, which determines the number of picture elements (pixels) between two points (fig. 1).

For comparison, the same measurements were made in four patients with brainstem

Received April 9, 1984; accepted after revision December 5, 1984.

¹ Department of Radiology, Medical College of Wisconsin, Milwaukee, WI 53226. Address reprint requests to V. M. Haughton, Froedert Memorial Lutheran Hospital, 9200 W. Wisconsin Ave., Milwaukee, WI 53226.

² General Electric Medical Systems, Milwaukee, WI 53201.

AJNR 6:425–427, May/June 1985
 0195–6108/85/0603–0425
 © American Roentgen Ray Society

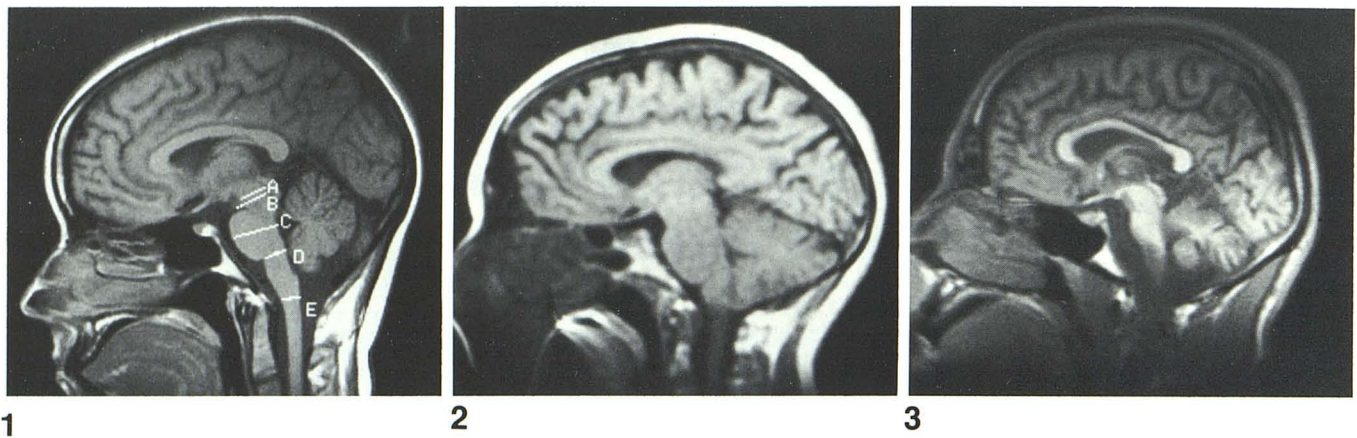


Fig. 1.—Sagittal MR image showing diameters measured.

Fig. 2.—PS scan, 200 msec TR, of midbrain glioma, using 0.3 T, 9 mm slice thickness, and 128 × 256 matrix. Measurement A = 25.1 mm; B = 25.1 mm; C = 30.5 mm; D = 15.3 mm; and E = 6.9 mm.

Fig. 3.—Olivopontocerebellar atrophy. Measurement A = 11.5 mm; B = 17.0 mm; C = 16.0 mm; D = 12.8 mm; and E = 7.4 mm.

TABLE 1: Mean, Maximum, and Minimum Brainstem Diameters Measured in 28 Normal Volunteers

	Normal Measurements (mm)				
	A	B	C	D	E
Minimum (−2 SD)	11.1	15.0	24.5	14.0	8.1
Mean	13.2	18.1	26.6	15.3	9.4
Maximum (+2 SD)	15.3	21.2	28.7	16.6	10.7

gliomas (fig. 2), one with olivopontocerebellar degeneration, and two with idiopathic cerebellar degeneration (fig. 3). PS, 450 msec TR, 25 msec echo time (TE), and spin-echo (SE), 2000 msec TR, 25 msec TE, images were obtained. The diagnoses were made in each case clinically and by computed tomography (CT). Three of the brainstem tumors had biopsy or postmortem verification. In addition to the direct measurements, we calculated the ratios of the pontine measurement to the other diameters.

Results

Measurements of the phantom were reproducible, regardless of the imaging plane, provided the phantom was near the center of the magnetic field. The calibration factor used in these studies was 1.13 mm/pixel. All brainstem measurements reported were calculated with the calibration factor.

The typical appearance of the mesencephalon, pons, and medulla in sagittal PS images is shown in figure 1. The cerebral peduncles are seen in contrast to the mesencephalic cistern. The interpeduncular fissure is partly obscured by the cerebral peduncles because cerebrospinal fluid (CSF) and peduncle are partial-volume averaged. The pons tapers from the cranial to the caudal end. The floor of the fourth ventricle has a shallow concave surface. A groove marks the transition of the pons to medulla. The medulla also tapers gently from the cranial to the caudal end.

TABLE 2: Brainstem Diameters in Patients with Brainstem Gliomas and Atrophy of the Brainstem and Cerebellum

Pathology: Case No.	Measurement (mm)				
	A	B	C	D	E
Glioma:					
1	20.2	22.3	27.0	15.8	9.4
2	24.0	23.5	26.5	22.0	19.4
3	ND	25.1	30.5	15.3	6.9
4	ND	20.9	32.2	17.2	10.5
Atrophy:					
5	11.5	17.0	16.0	12.8	7.4
6	13.8	18.2	21.5	11.6	8.4
7	13.2	18.1	21.5	10.6	10.0

Note.—ND = not done because margins indistinct.

TABLE 3: Ratios of Different Parameters Measured as They Relate to the Diameter of Pons

Group	Ratio			
	C/A	C/B	C/D	C/E
Normals:				
Minimum	2.2	1.6	1.8	3.0
Mean	2.0	1.5	1.7	2.8
Maximum	1.9	1.4	1.7	2.6
Glioma, case no.:				
1	1.4	1.2	1.8	2.8
2	1.1	1.2	1.2	1.4
3	ND	1.2	1.9	4.3
4	ND	1.6	1.9	3.1
Atrophy, case no.:				
5	1.4	0.9	1.3	2.2
6	1.6	1.2	1.9	2.6
7	1.6	1.2	2.0	2.2

Note.—ND = not done because margins indistinct.

Diameters of the mesencephalon (A and B), pons (C), and medulla (D and E) (fig. 1) measured in 28 normal volunteers are shown in table 1. Because the interpeduncular fissure and surface of the cerebral peduncles were often difficult to local-

ize precisely, A and B were not always measured confidently. C, D, and E could be measured more precisely. The average diameters for A, B, C, D, and E were 13.2, 18.1, 26.6, 15.3, and 9.4 mm, respectively. The minimum and maximum, representing 2 SDs from the mean, are listed in table 1.

Discussion

Although many pneumoencephalographic measurements of brainstem diameters have been published [1-8], few correlate with the MR measurements. Robertson [1] reported a normal range of 26-38 mm for diameter C, which we found to be 24-28 mm. Geometric magnification in conventional tomography, and partial-volume averaging in CT, probably explain the differences. The window used for viewing the images may also affect the measurements. The window used for measurement should correspond as closely as possible to the one used for collecting normative data. The window chosen to view the image also affects the measurement obtained. Thinner slices minimizing the effect of partial-volume averaging are probably more accurate than the 10-mm-thick slices we used. Choice of the point where the cursor is placed may result in small errors. When we repeated measurements of identical images, placing the cursor on a different pixel, errors of about 1 mm resulted. Therefore, the measurements reported here should not be considered absolute.

The distance between the interpeduncular fissure to the aqueduct could usually be measured. Because of volume averaging between brain and surrounding CSF, it was not always possible to identify the interpeduncular fissure. The pons was measured with the least ambiguity. It tapers caudally; thus, a slightly larger diameter of the pons near its rostral end is not abnormal. The dorsal surface of the pons normally was slightly concave. This concavity was lost in the four patients with midbrain expanding lesions, but was preserved in the patients with atrophy.

Though in many instances of tumor, MR shows abnormal signal intensity in at least one pulse sequence because of an abnormal T1 or T2 relaxation time, we encountered patients,

studied with PS (250/25, 400/25, and 600/25) and SE (1000/25, 50, 75, 100) in a 0.3 T magnet, in whom no clearly pathologic relaxation characteristics were observed. In the four patients with midbrain tumors, one or more of the measured diameters were more than 2 SD above the average measured in the normal volunteers. Abnormally small measurements were found in patients with atrophy (table 2).

The ratios between the diameters of the pons and medulla helped confirm abnormalities (table 3). The ratios depended on location and extent of the tumor. The patient with glioma involving the pons spreading into the medulla had abnormally small C/D and C/E ratios, while the one with the tumor confined to the pons and the one with the tumor extending from the pons to the mesencephalon had abnormally small C/A and C/B ratios.

Thus, measurements of brain diameter may be valuable in tumors or atrophic processes involving this part of the central nervous system. It is likely that some diffusely infiltrating tumors may be detected by changes in the size of the midbrain rather than by demonstration of differences in the signals due to changes in relaxation times.

REFERENCES

1. Robertson EG. *Encephalography*. Melburn: MacMillan, 1941
2. Last RJ, Tompsett DH. Cast of the cerebral ventricles. *Br J Surg* 1953;40:525-543
3. Davidoff LM, Dyke CG. *The normal encephalogram*. Philadelphia: Lea & Febiger, 1937
4. Sutton D. The radiological assessment of normal aqueduct and 4th ventricles. *Br J Radiol* 1950;23:208-218
5. Dyke CG, Davidoff LM. The pneumoencephalographic appearance of hemangioblastoma of the cerebellum. *AJR* 1940;44:1-8
6. Liliequist B. The subarachnoid cisterns. *Acta Radiol [Suppl]* (Stockh) 1959;185:37-43
7. Amundsen P, Grimsrud OK. Height of fourth ventricle in normal encephalograms. *Acta Radiol [Diagn]* (Stockh) 1966;4:257-261
8. Oberon R, Candardjis G, Raad N. Height of the fourth ventricle. Normal variables during pneumoencephalography. *Acta Radiol [Diagn]* (Stockh) 1969;9:193-198