

# MR Detection of Tumor in the Internal Auditory Canal

David L. Daniels<sup>1</sup>  
 Steven J. Millen<sup>2</sup>  
 Glenn A. Meyer<sup>3</sup>  
 Kathleen W. Pojunas<sup>1</sup>  
 David P. Kilgore<sup>1</sup>  
 Katherine A. Shaffer<sup>1</sup>  
 Alan L. Williams<sup>1</sup>  
 Victor M. Haughton<sup>1</sup>

The MR appearance of 15 tumors within or near the internal auditory canal was analyzed in detail and compared with the subsequent surgical observations. In most cases, nonenhanced MR showed the precise extent of the intracanalicular and extracanalicular tumor despite minor variations in appearance. In a case of facial nerve neurinoma, the extent to which the tumor invaded the canal was underestimated by MR. Gadolinium-DTPA enhancement is expected to eliminate uncertainties in MR imaging of the internal auditory canal.

The normal MR appearance of the internal auditory canals and individual cranial nerves within them has been described [1–3]. MR signs of intracanalicular tumor include obscuring of the seventh and eighth cranial nerves [3–7], abnormally increased signal intensity [1], and enhancement after intravenous administration of Gadolinium-DTPA [8]. This paper discusses the MR detection of tumor within the internal auditory canal.

## Materials and Methods

The records of patients who had surgery for a cerebellopontine angle or intracanalicular tumor at Froedtert Memorial Lutheran Hospital from 1983 to 1986 were reviewed. Those patients who also had preoperative MR examinations of the temporal bones were selected for this study. The surgeons who performed the explorations correlated surgical and MR findings. The extent of tumor within the internal auditory canal found at surgery was compared with the MR appearance of the canal.

The MR studies were performed on research 1.4- or 1.5-T and commercial 1.5-T GE imaging systems. Each study was initiated with a short TR sagittal scan to select optimal axial and coronal slice locations for the temporal bones. Technical factors for the temporal bone imaging included 3- or 5-mm thick slices, a 128 × 256 or 256 × 256 matrix, and spin-echo sequences with a short repetition time (TR 300–800 msec) and a short echo time (TE 20–25 msec). In most cases a long TR sequence (2000 or 2500 msec) with multiple echoes (25–100 msec) was also obtained. For the research system, one to four signal averages and a single-slice acquisition technique were used. For the commercial system, two to four excitations (2–4 NEX) and a multislice acquisition technique (contiguous short TR images, long TR images either contiguous or with 1-mm skips between sections) were used. A head coil or, less commonly, a 3- or 4-in. diameter surface coil placed beside the ear was used to receive the RF signal. Two patients were given Gadolinium-DTPA in a dose of 0.1 mmol/kg via antecubital vein 5 min before scanning.

## Results

Twelve patients with acoustic neurinomas, two with facial nerve tumors, and one with a meningioma were selected. At surgery, the acoustic neurinomas were considered to be entirely or predominantly intracanalicular (five), or both intra- and

This article appears in the March/April 1987 issue of *AJNR* and the June 1987 issue of *AJR*.

Received June 10, 1986; accepted after revision August 8, 1986.

<sup>1</sup> Department of Radiology, Medical College of Wisconsin, Froedtert Memorial Lutheran Hospital, 9200 West Wisconsin Ave., Milwaukee, WI 53226. Address reprint requests to D. L. Daniels.

<sup>2</sup> Department of Otolaryngology, Medical College of Wisconsin, Milwaukee, WI 53226.

<sup>3</sup> Department of Neurosurgery, Medical College of Wisconsin, Milwaukee, WI 53226.

*AJNR* 8:249–252, March/April 1987  
 0195-6108/87/0802-0249  
 © American Society of Neuroradiology

extracanalicular (seven). The facial nerve tumors (one neurofibroma and one neurinoma) had both extra- and intracanalicular components. The neurofibroma and 11 acoustic neurinomas filled the entire canal. The facial nerve neurinoma and one acoustic neurinoma nearly filled the canal; the meningioma was entirely extracanalicular.

The MR appearance of the intracanalicular tumors had minor variations. Short TR and TE images, which showed greater contrast between CSF and tumor than did long TR images, revealed a widened canal and tissue displacing CSF from the internal auditory canal. In eight cases the intracanalicular tumor had a homogeneous intensity slightly less than that of the brainstem (Fig. 1). In five cases the intracanalicular tumor had a central thin band of low signal intensity (Fig. 2). In one acoustic neurinoma and in the cerebellopontine angle meningioma, MR demonstrated edges of the tumors within the internal auditory canal (Fig. 3) and at the porus acusticus (Fig. 4), respectively. In the case of the facial nerve neurinoma, the tumor appeared exclusively extracanalicular in MR but was found in the canal at surgery (Fig. 5). After the intravenous administration of Gadolinium-DTPA, the intra- and extracanalicular components of an acoustic neurinoma and the

neurofibroma enhanced intensely and homogeneously (Figs. 6 and 7).

### Discussion

The inhomogeneous signals from some intracanalicular tumors are of uncertain significance (Fig. 2). No anatomic correlate was found at surgery. All acoustic neurinomas, even those with an inhomogeneous appearance, had thin capsules, probably not identified with MR. One possible explanation for tumor signal inhomogeneity is cellular differences between the central and peripheral parts of small acoustic neurinomas (J. Gail Neely, personal communication). The lower-intensity signal did not appear to represent normal nerves surrounded by tumor, since in each case the nerves appeared at surgery to be eccentrically displaced by the tumor. No cystic spaces or calcifications or vascular structures that might produce a lower-intensity signal were identified in the tumors. An artifact of imaging cannot be excluded.

Determination of intracanalicular tumor was not difficult with nonenhanced MR in most cases. Only in the case of the facial

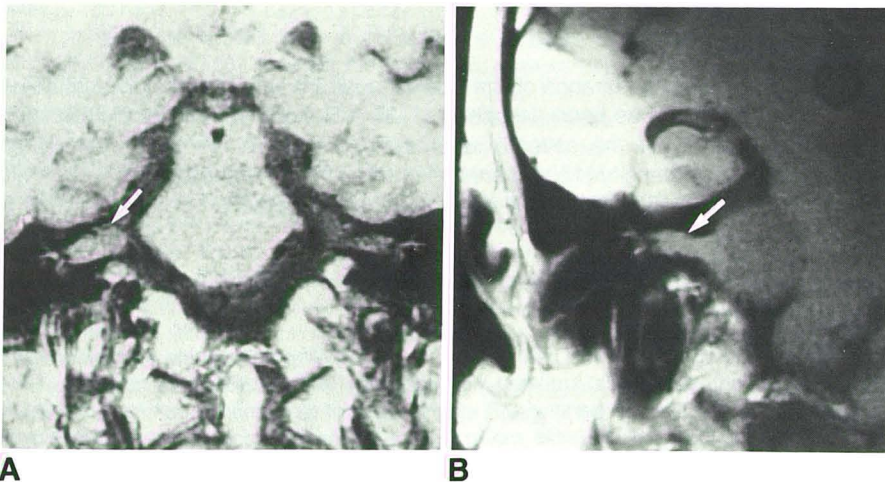


Fig. 1.—Two examples of acoustic neurinomas having homogeneous intracanalicular signals (arrows) in coronal short TR and TE MR images obtained with head (A) and surface (B) coils. The tumors filled the internal auditory canals at surgery. The homogeneous appearance of the canals is typical of intracanalicular tumor.

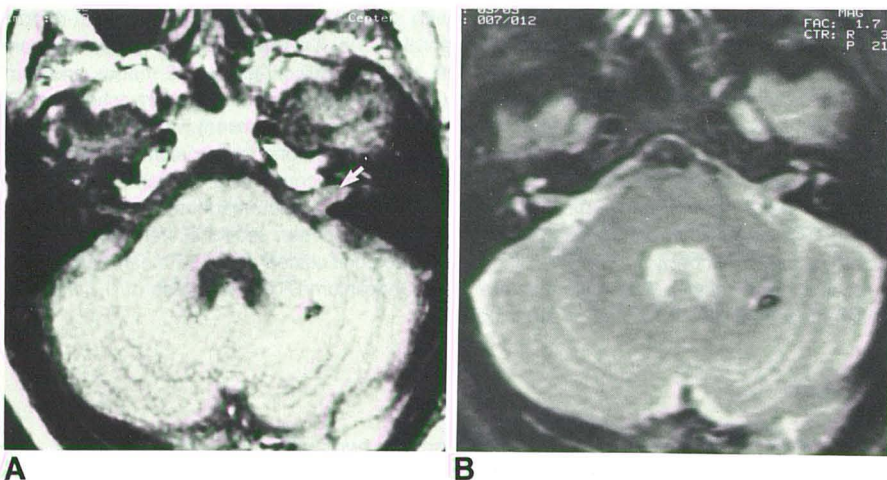
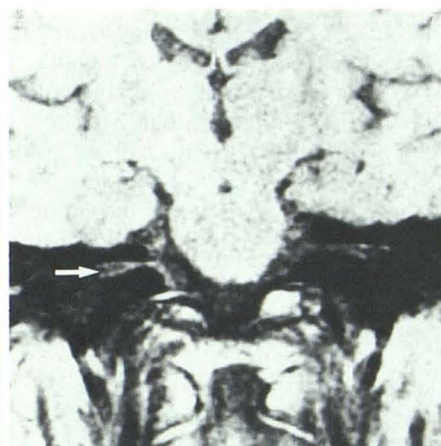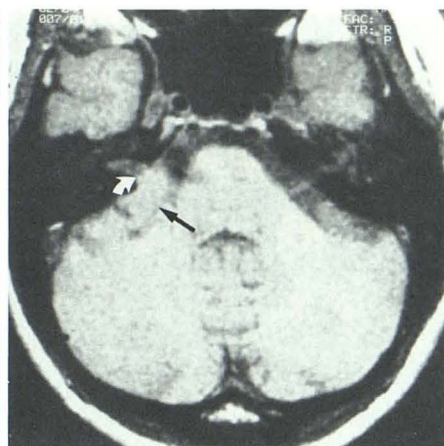
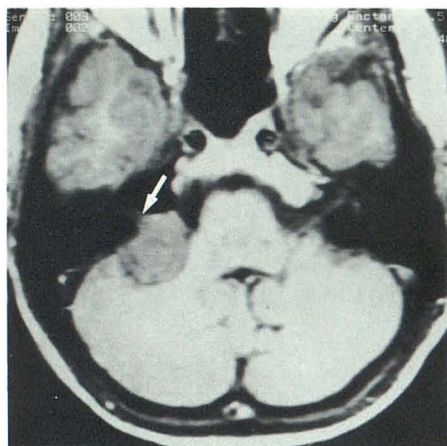


Fig. 2.—Intracanalicular acoustic neurinoma in short TR and TE (A) and long TR and TE (B) axial MR images. The tumor widens the involved canal and displaces CSF. A central thin band of low signal intensity (arrow, A) is demonstrated. In B, the tumor is more difficult to identify because its signal is almost as bright as that of CSF. At surgery, solid tumor that filled the canal without a cyst was found. No anatomic correlate of the tumor's dark central band was identified.



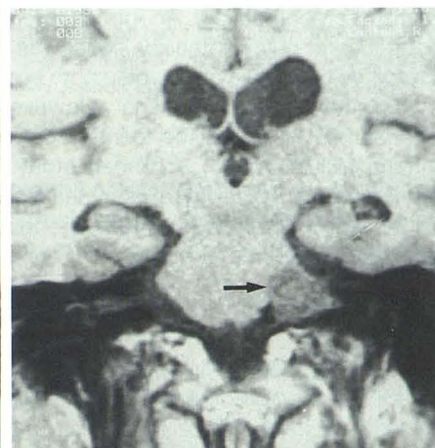
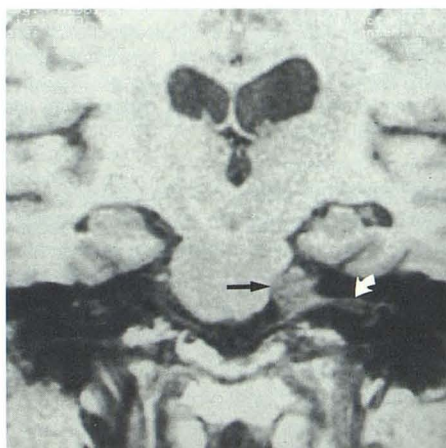
A

B

Fig. 3.—The edge (*arrow*) of an acoustic neuroma within internal auditory canal is seen in an axial short TR and TE MR image. Incomplete filling of canal by tumor was found at surgery.

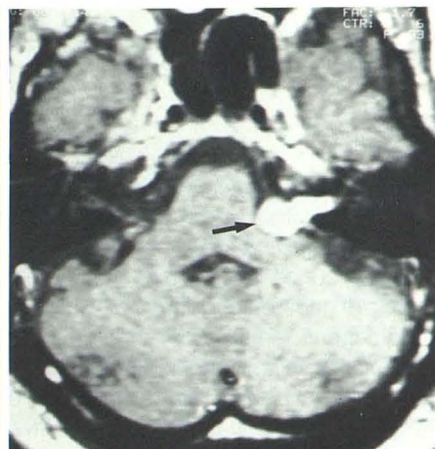
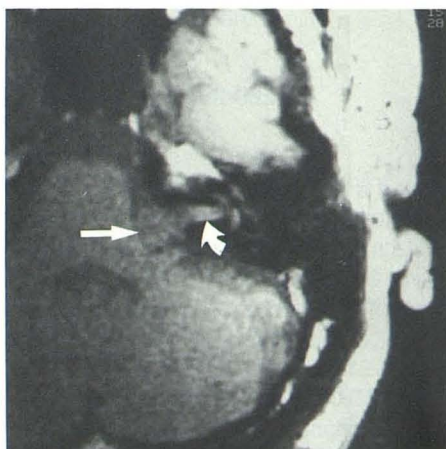
Fig. 4.—Cerebellopontine angle meningioma (*black arrow*) in axial short TR and TE MR image (A) found to be entirely extracanalicular at surgery. Its edge (*curved arrow*) at porus acusticus is shown. In coronal short TR and TE image (B) normal cranial nerves in ipsilateral canal are identified (*white arrow*). Thin region of negligible signal between them probably represents falciform crest. A long TR and TE image was not helpful in defining the extent of tumor.

Fig. 5.—Seventh nerve neurinoma (*black arrow*) misinterpreted with MR as entirely extracanalicular. In short TR and TE contiguous coronal images (A, B), the canals appear completely symmetric with tumor having signals in ipsilateral canal simulating normal nerves and CSF (*curved arrow, A*). At surgery, tumor almost filled the canal.



B

Fig. 6.—A surface-coil short TR and TE MR image (A) of an acoustic neurinoma (*straight arrow*) in which internal auditory canal has inhomogeneous signals (*curved arrow*) with a central dark band resembling normal cranial nerves. In B, a short TR and TE head-coil image after intravenous gadolinium-DTPA, intensely enhancing tumor (*straight arrow*) that completely fills canal (surgically verified) is seen.



A

B

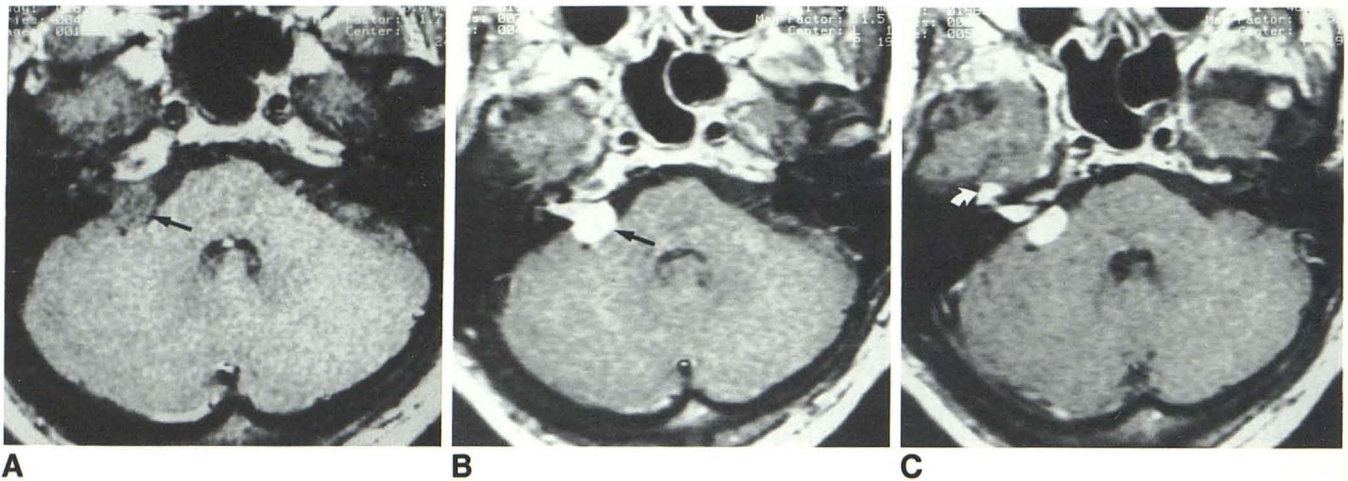


Fig. 7.—Intra- and extracanalicular seventh nerve neurofibroma (*straight arrow*) in axial short TR and TE MR images. Tumor has homogeneous signals before (A) and after (B) Gadolinium-DTPA enhancement. Also shown is intensely enhancing tumor by the geniculate ganglion (*curved arrow*) in C, a section slightly higher than B. This case illustrates that the homogeneously enhancing appearance of the internal auditory canal can be confidently interpreted as tumor.

*arrow*) in C, a section slightly higher than B. This case illustrates that the homogeneously enhancing appearance of the internal auditory canal can be confidently interpreted as tumor.

nerve neurinoma (Fig. 5) was intracanalicular tumor not recognized preoperatively. An intracanalicular mass with a thin central band of low-intensity signal was usually not misinterpreted as normal seventh and eighth cranial nerves and CSF in the internal auditory canal. However, intravenously enhanced MR facilitates the identification of the full extent of intracanalicular tumor. A blinded study is in preparation to determine the sensitivity of nonenhanced and enhanced MR for detecting intracanalicular tumors and differentiating acoustic neurinoma from extracanalicular meningioma.

#### REFERENCES

- Daniels DL, Herfkens R, Koehler PR, et al. Magnetic resonance imaging of the internal auditory canal. *Radiology* 1984; 151:105-108
- Reese DF, Harner SG, Kipert DB, Baker HL Jr. Magnetic resonance display of the internal auditory canal, cochlea, vestibular apparatus and facial nerve. Presented at the annual meeting of the American Society of Neuroradiology, Boston, June 1984
- Daniels DL, Schenck JF, Foster T, et al. Surface-coil magnetic resonance imaging of the internal auditory canal. *AJNR* 1985; 6:487-490
- Bydder GM, Steiner RE, Young IR, et al. Clinical NMR imaging of the brain: 140 cases. *AJNR* 1982; 3:459-480, *AJR* 1982; 139:215-236
- Young IR, Bydder GM, Hall AS, et al. The role of NMR imaging in the diagnosis and management of acoustic neuroma. *AJNR* 1983; 4:223-224
- New PFJ, Bachow TB, Wismer GL, Rosen BR, Brady TJ. MR imaging of the acoustic nerves and small acoustic neuromas at 0.6T: prospective study. *AJNR* 1985; 6:165-170
- Kingsley DPE, Brooks GB, Leung AW-L, Johnson MA. Acoustic neuromas: evaluation by magnetic resonance imaging. *AJNR* 1985; 6:1-5
- Curati WL, Graif M, Kingsley DPE, Niendorf HP, Young IR. Acoustic neuromas: Gd-DTPA enhancement in MR imaging. *Radiology* 1986; 158:447-451