



Since January 2020 Elsevier has created a COVID-19 resource centre with free information in English and Mandarin on the novel coronavirus COVID-19. The COVID-19 resource centre is hosted on Elsevier Connect, the company's public news and information website.

Elsevier hereby grants permission to make all its COVID-19-related research that is available on the COVID-19 resource centre - including this research content - immediately available in PubMed Central and other publicly funded repositories, such as the WHO COVID database with rights for unrestricted research re-use and analyses in any form or by any means with acknowledgement of the original source. These permissions are granted for free by Elsevier for as long as the COVID-19 resource centre remains active.

Forum

Pneumocystis pneumonia in the COVID-19 pandemic era: similarities and challenges

Magdalena Szydłowicz ^{1,*} and Olga Matos ^{2,3}



The clinical picture of the fungal disease, *Pneumocystis* pneumonia, resembles the course of coronavirus disease 2019 (COVID-19), presenting a diagnostic challenge in the pandemic era. We discuss the concern of *Pneumocystis jirovecii* and severe acute respiratory syndrome coronavirus 2 (SARS-CoV-2) coinfection, their similarities, and the impact of immunosuppression, with a suggested diagnostic pathway for their suspected coinfection.

SARS-CoV-2 and *P. jirovecii* coinfection

P. jirovecii is a human-specific, opportunistic fungus that causes *Pneumocystis* pneumonia (PCP). The symptoms of PCP are non-specific and resemble the clinical picture typical of many other infectious agents of the pulmonary tract. A diagnostic challenge occurs when a patient, colonized with *Pneumocystis*, is coinfecting with another pulmonary pathogen, which, in view of the preceding detection of *Pneumocystis*, may be overlooked. It may be unclear which of these agents is actually triggering the clinical manifestations, and failure to detect one of them may lead to improper treatment associated with persistence of symptoms. The other way around, *Pneumocystis* infection can be overshadowed by the detection of coexisting pathogens not necessarily responsible for the observed

respiratory symptoms, such as SARS-CoV-2, whose clinical presentation, known as COVID-19, coincides with PCP symptoms.

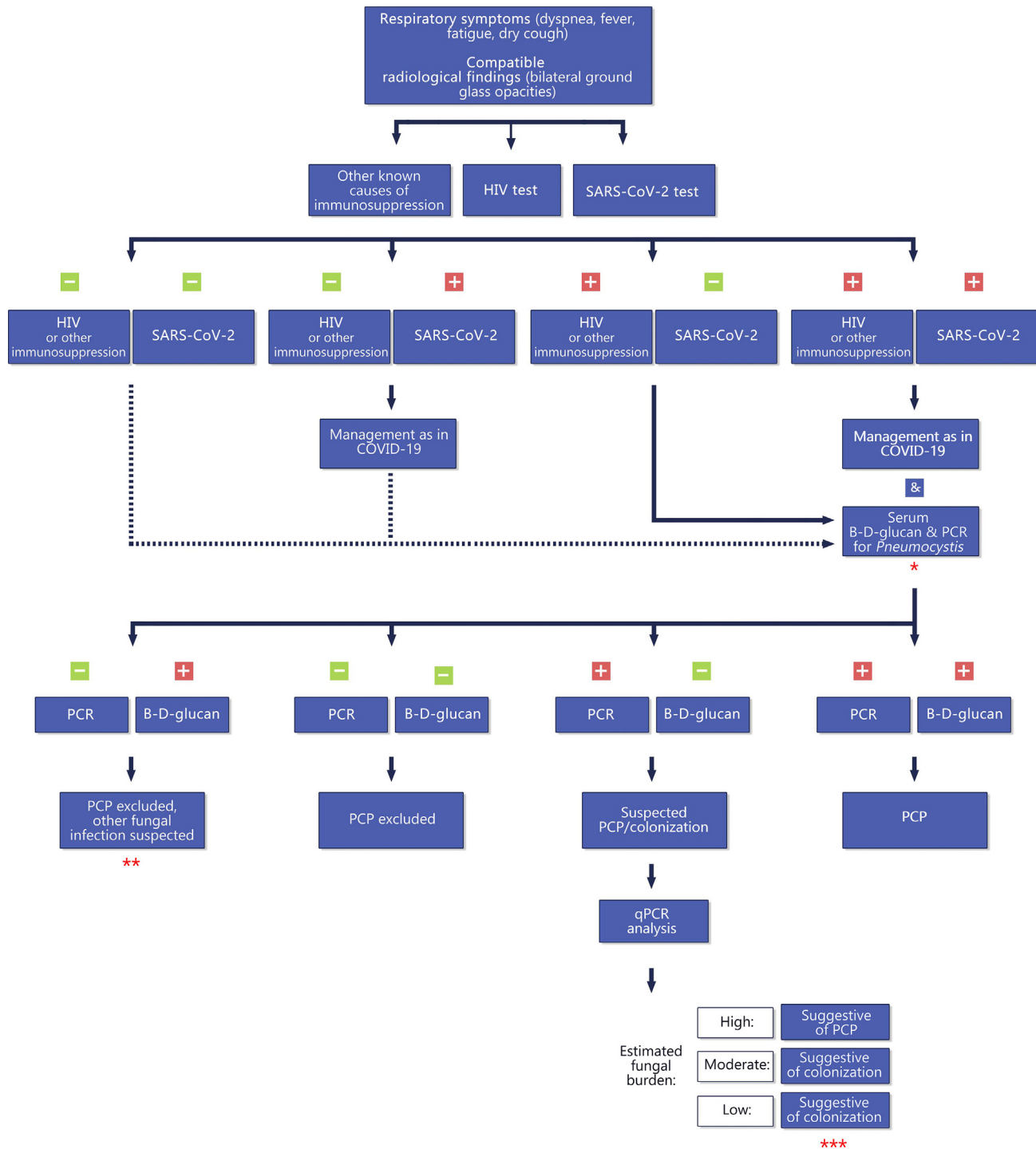
According to the World Health Organizationⁱ, nearly 200 million people around the world have been infected with SARS-CoV-2 since its first presentation in December 2019. Known risk factors for invasive fungal infections, such as corticosteroid treatment or mechanical ventilation, are common in COVID-19 patients hospitalized in intensive care units (ICUs) [1]. In fact, as happened during the SARS-CoV-1 epidemic nearly two decades ago, a high proportion of coinfections with other pathogens has been observed in patients infected with SARS-CoV-2 in the ICUⁱⁱ, including *P. jirovecii* [2–7]. *Pneumocystis* is often detected alongside other respiratory microorganisms in patients with suspected pneumonia, thus its inclusion in routine diagnostic screening should be considered [8]. Since this pathogen is known to be prevalent in a healthy population, such tests – for example, in patients suspected to have, or hospitalized with, COVID-19 – are a good opportunity to estimate the proportion of its colonization in the immunocompetent population.

Coinfections of SARS-CoV-2 and *P. jirovecii* seem to be underestimated, and their causal link is unclear. *Pneumocystis* colonization may be facilitated by lung lesions resulting from the presence of other infections in the pulmonary tract, including post-COVID-19 changes such as pulmonary fibrosis or reduced lung function [7]. Conversely, the host immune response to previous viral infection may mitigate *Pneumocystis* propagation. Likewise, *Pneumocystis* colonization, although asymptomatic, may activate an inflammatory response – high neutrophil counts are observed even in respiratory samples with a low fungal burden [9]. This may potentially provoke lung tissue damage – a condition conducive to secondary infections by other pathogens, such as SARS-CoV-2.

Two studies exploring the incidence of *Pneumocystis* in pulmonary specimens obtained from severe COVID-19 patients have demonstrated rates of 1.4% [10] and over 9% [3]. In both studies, relatively low fungal loads were observed in all *Pneumocystis*-positive specimens, and all patients were considered to be colonized. The development of PCP in the further course of infection cannot be excluded as its control by the host is impaired when coinfecting with other pathogens, highlighting the necessity of testing patients with severe COVID-19 for other infections. Furthermore, a history of corticosteroid treatment for other medical conditions was statistically more common in *Pneumocystis* carriers [3]. These immunomodulatory agents can be used in COVID-19 treatment as well, posing a risk of secondary opportunistic infections and potentially facilitating further *P. jirovecii* colonization, even in patients without prior PCP predisposition [6]. Therefore, the immunosuppressants used for treating SARS-CoV-2 infection – rather than the virus itself – might be considered as risk factors for fungal coinfection.

The impact of immunosuppression

In terms of the COVID-19 and PCP interdependency, immunosuppression seems to have an important, but twofold, meaning. On the one hand, pre-existing immunodeficiency may have a beneficial effect in the context of COVID-19 symptoms due to the weakened host immune response, and thus the decreased inflammation, which plays a key role in the severity of symptoms. For instance, severe forms of COVID-19 are rarely observed in HIV-infected patients, presumably due to the mitigation of acute symptoms by immunosuppression [11]. Special circumstances concern newly diagnosed cases of HIV infection: implementation of antiretroviral therapy in patients simultaneously diagnosed with HIV/AIDS and COVID-19 may even lead to an excessive inflammatory response following the immune



Trends in Parasitology

Figure 1. Proposed diagnostic pathway for suspected SARS-CoV-2 and *Pneumocystis jirovecii* coinfection. *Additional testing for *P. jirovecii* should be considered especially in less common risk groups (e.g., patients with mild immunosuppression) or those with SARS-CoV-2-related lymphopenia. **In view of various factors associated with the intensive care unit (ICU) setting (e.g., host proinflammatory responses, drug administration, blood transfusion, or application of blood

(Figure legend continued at the bottom of the next page.)

system's recovery, associated with the patient's condition worsening [5].

On the other hand, impaired immunity is a main factor predisposing to *Pneumocystis* infection. Pre-existing HIV-related or drug-induced immunosuppression may increase the risk of SARS-CoV-2 and *P. jirovecii* concurrent infection [4,6] and may occur even in individuals outside known risk groups, due to severe COVID-19-related lymphopenia or immunomodulatory treatment applied [3]. These factors may also activate the ongoing asymptomatic *P. jirovecii* infection in colonized patients, leading to the development of PCP.

COVID-19 and its mimics: a diagnostic challenge

During the pandemic, there is a tendency to focus typically on COVID-19 as a diagnostic target; this may lead to other origins of the respiratory symptoms being overlooked, or misdiagnosis associated with imperfect sensitivity of the tests for detecting SARS-CoV-2. Consequently, symptomatic patients are often handled as having COVID-19, while they may actually be infected with other respiratory pathogens which mimic their presentation – a concept known as 'medical chameleon' [12].

In fact, *Pneumocystis* and the new coronavirus have much in common, hindering their differentiation: the route of transmission (PCP spreads directly through air, while droplets or aerosols containing SARS-CoV-2 particles are inhaled or transmitted through the mucous membranes), the primary engagement of the respiratory tract, similar symptoms (fever, dry cough, dyspnea, and fatigue), and signs (bilateral symmetrical ground-glass opacities often seen in computed tomography).

There is a greater chance of suspecting coinfection, or of distinguishing COVID-19 from other respiratory infections with similar clinical courses in patients who are known to be immunocompromised [2,4]. It is more difficult in the case of people who are not in the 'at risk' group or those who are unaware of their immunosuppression – for instance, those with previously undiagnosed HIV infection [5,6,13]. Therefore, it is suggested that HIV screening should be included as a part of the standard admission procedure for patients with acute respiratory symptoms with suspected COVID-19 in order to facilitate the correct differential diagnosis and patient management [6,13].

Another difficulty in correct diagnosis is associated with the procedure for detecting *P. jirovecii*. First of all, invasive collection methods are required for sufficient sensitivity, and such methods are not recommended in patients with severe respiratory failure. Secondly, detection methods pose a risk of overlooking *Pneumocystis* since microscopy may yield false-negative results due to the low fungal burden typical for PCP in non-HIV-infected immunocompromised individuals. Molecular methods (PCR) are commonly used instead; this can confirm infection by indirectly demonstrating the presence of *Pneumocystis* DNA, making the diagnosis uncertain in the event of coinfection with other pathogens. Quantitative PCR (qPCR) allows an estimation of the fungal burden, and although a negative result can definitely rule out the infection, the interpretation of positive results is still ambiguous since clinical cut-off values, enabling *Pneumocystis* colonization to be distinguished from PCP, have not been established so farⁱⁱⁱ. Thus, a high fungal load provides suspicion of PCP, but for

lower values additional indicators should be considered. For example, PCP may be distinguished from colonization by the serum level of the fungal cell-wall component (1,3)- β -D-glucan (BDG), which is significantly elevated in PCP patients [14]. The high negative predictive value of this marker makes it a useful tool for excluding infection, but it should be noted that its level increases with other fungal infections as well, and that various factors may affect its specificity and sensitivity, yielding false-positive or false-negative results [15]. Therefore, an overall clinical picture should be analyzed in each patient, including respiratory symptoms, chest imaging, HIV serological test, and/or other causes of underlying immunosuppression (Figure 1).

Concluding remarks

The severity and mortality of COVID-19 may be increased by coinfections with other pathogens, including *P. jirovecii*. Immunosuppression is an important issue, which, in the context of the relationship between these two pathogens, has a twofold meaning. Individuals with known immunodeficiency are in the main group at risk for opportunistic infections, and coinfections with other pathogens, but such susceptibility may be increased due to the immune defects also emerging in the course of COVID-19. At the same time, pre-existing immunosuppression may favor the milder COVID-19 pattern by silencing the host's immunomodulatory response. Based on the data available for other respiratory viruses, it can be assumed that a significant proportion of the fungal coinfections with SARS-CoV-2 will be misdiagnosed or overlooked. Taking into account the current scale of SARS-CoV-2 cases

products), consider false-positive (1,3)- β -D-GLUCAN (BDG) results. ***Of note, *P. jirovecii pneumonia* (PCP) in non-HIV-infected immunocompromised individuals may be associated with low and moderate fungal burdens; also, false-negative BDG results (e.g., due to treatment with antifungal agents) may be considered. Abbreviations: COVID-19, coronavirus disease 2019; PCR, polymerase chain reaction; qPCR, quantitative PCR; SARS-CoV-2, severe acute respiratory syndrome coronavirus 2.

observed worldwide on a daily basisⁱ, the percentage of such overlooked coinfections is no longer of marginal importance. COVID-19 and PCP share many characteristics, and this may hinder the correct diagnosis and thus affect the development of the patient's general health condition. During the pandemic there is an inclination to focus on combating COVID-19 rather than searching for other causes of respiratory failure.

In the case of suspected coinfection, with clinical data indicative of PCP, additional diagnostic tests should be taken into account in patients with COVID-19. This applies especially to immunocompromised patients, including those who are HIV-infected. Therefore, HIV testing of all individuals admitted to COVID-19 wards should be considered.

Acknowledgments

We are grateful to Marta Kicia from the Department of Biology and Medical Parasitology of Wrocław Medical University for her support in the preparation of the manuscript. We would also like to thank Robin and Barbara Royle for their help in the language correction of the text.

Declaration of interests

The authors declare no competing interests.

Resources

ⁱwww.who.int/emergencies/diseases/novel-coronavirus-2019

ⁱⁱwww.cdc.gov/fungal/covid-fungal.html

ⁱⁱⁱ<https://clinicalinfo.hiv.gov/en/guidelines/adult-and-adolescent-opportunistic-infection/pneumocystis-pneumonia>

¹Department of Biology and Medical Parasitology, Wrocław Medical University, 50-345 Wrocław, Poland

²Unit of Medical Parasitology, Global Health and Tropical Medicine, Instituto de Higiene e Medicina Tropical, Universidade Nova de Lisboa, 1349-008 Lisboa, Portugal

³Environmental Health Institute, Faculdade de Medicina da Universidade de Lisboa, 1649-028 Lisboa, Portugal

*Correspondence:

magdalena.szydłowicz@umed.wroc.pl (M. Szydłowicz).

<https://doi.org/10.1016/j.pt.2021.07.010>

© 2021 Elsevier Ltd. All rights reserved.

References

- Chen, N. *et al.* (2020) Epidemiological and clinical characteristics of 99 cases of 2019 novel coronavirus pneumonia in Wuhan, China: a descriptive study. *Lancet* 395, 507–513
- De Francesco, M.A. *et al.* (2020) *Pneumocystis jirovecii* and SARS-CoV-2 co-infection: a common feature in transplant recipients? *Vaccines* 8, 1–6
- Alanio, A. *et al.* (2021) The presence of *Pneumocystis jirovecii* in critically ill patients with COVID-19. *J. Infect.* 82, 84–123

- Coleman, H. *et al.* (2020) Coronavirus disease 2019 and *Pneumocystis jirovecii* pneumonia: a diagnostic dilemma in HIV. *AIDS* 34, 1258–1260
- Merchant, E.A. *et al.* (2021) Co-infection with coronavirus disease 2019, previously undiagnosed human immunodeficiency virus, *Pneumocystis jirovecii* pneumonia and cytomegalovirus pneumonitis, with possible immune reconstitution inflammatory syndrome. *IDCases* 24, e011153
- Rubiano, C. *et al.* (2021) *Pneumocystis* and severe acute respiratory syndrome coronavirus 2 coinfection: a case report and review of an emerging diagnostic dilemma. *Open Forum Infect. Dis.* 8, 1–5
- Jeican, I.I. *et al.* (2021) COVID-19 and *Pneumocystis jirovecii* pulmonary coinfection – the first case confirmed through autopsy. *Medicina (Buenos Aires)* 57, 302
- Guigue, N. *et al.* (2014) Utility of adding *Pneumocystis jirovecii* DNA detection in nasopharyngeal aspirates in immunocompromised adult patients with febrile pneumonia. *Med. Mycol.* 53, 241–247
- Morris, A. *et al.* (2004) Association of chronic obstructive pulmonary disease severity and *Pneumocystis* colonization. *Am. J. Respir. Crit. Care Med.* 170, 408–413
- Blaize, M. *et al.* (2021) COVID-19-related respiratory failure and lymphopenia do not seem associated with pneumocystosis. *Am. J. Respir. Crit. Care Med.* 202, 1734–1736
- Laurence, J. (2020) Why aren't people living with HIV at higher risk for developing severe coronavirus disease 2019 (COVID-19)? *AIDS Patient Care STDs* 34, 247–248
- Nickel Christian, H. and Bingisser, R. (2020) Mimics and chameleons of COVID-19. *Swiss Med. Wkly.* 150, 2–3
- Kelly, S. *et al.* (2020) *Pneumocystis* pneumonia, a COVID-19 mimic, reminds us of the importance of HIV testing in COVID-19. *Clin. Med. (Northfield, IL)* 20, 590–592
- Esteves, F. *et al.* (2015) Diagnosis of *Pneumocystis* pneumonia: evaluation of four serologic biomarkers. *Clin. Microbiol. Infect.* 21, 379.e1–379.e10
- Azoulay, E. *et al.* (2016) (1, 3)- β -D-glucan assay for diagnosing invasive fungal infections in critically ill patients with hematological malignancies. *Oncotarget* 7, 21484–21495